This is a digital copy of a book that was preserved for generations on library shelves before it was carefully scanned by Google as part of a project to make the world's books discoverable online.

It has survived long enough for the copyright to expire and the book to enter the public domain. A public domain book is one that was never subject to copyright or whose legal copyright term has expired. Whether a book is in the public domain may vary country to country. Public domain books are our gateways to the past, representing a wealth of history, culture and knowledge that's often difficult to discover.

Marks, notations and other marginalia present in the original volume will appear in this file - a reminder of this book's long journey from the publisher to a library and finally to you.

Usage guidelines

Google is proud to partner with libraries to digitize public domain materials and make them widely accessible. Public domain books belong to the public and we are merely their custodians. Nevertheless, this work is expensive, so in order to keep providing this resource, we have taken steps to prevent abuse by commercial parties, including placing technical restrictions on automated querying.

We also ask that you:

+ *Make non-commercial use of the files* We designed Google Book Search for use by individuals, and we request that you use these files for personal, non-commercial purposes.
+ *Refrain from automated querying* Do not send automated queries of any sort to Google's system: If you are conducting research on machine translation, optical character recognition or other areas where access to a large amount of text is helpful, please contact us. We encourage the use of public domain materials for these purposes and may be able to help.
+ *Maintain attribution* The Google "watermark" you see on each file is essential for informing people about this project and helping them find additional materials through Google Book Search. Please do not remove it.
+ *Keep it legal* Whatever your use, remember that you are responsible for ensuring that what you are doing is legal. Do not assume that just because we believe a book is in the public domain for users in the United States, that the work is also in the public domain for users in other countries. Whether a book is still in copyright varies from country to country, and we can't offer guidance on whether any specific use of any specific book is allowed. Please do not assume that a book's appearance in Google Book Search means it can be used in any manner anywhere in the world. Copyright infringement liability can be quite severe.

About Google Book Search

Google's mission is to organize the world's information and to make it universally accessible and useful. Google Book Search helps readers discover the world's books while helping authors and publishers reach new audiences. You can search through the full text of this book on the web at `http://books.google.com/`

LANE MEDICAL LIBRARY STANFORD
N201 .G242 1894 STOR
A textbook of the diseases of women / by
24503433312

36a

LANE

MEDICAL LIBRARY

LEVI COOPER LANE FUND

LANE MEDICAL LIBRARY
STANFORD UNIVERSITY
300 PASTEUR DRIVE
PALO ALTO, CALIF.

LANE MEDICAL LIBRARY
STANFORD UNIVERSITY
300 PASTEUR DRIVE
PALO ALTO, CALIF.

36a

LANE

MEDICAL LIBRARY

LEVI COOPER LANE FUND

LANE MEDICAL LIBRARY
STANFORD UNIVERSITY
300 PASTEUR DRIVE
PALO ALTO, CA 94

LANE MEDICAL LIBRARY
STANFORD UNIVERSITY
300 PASTEUR DRIVE
PALO ALTO, CALIF.

A TEXT-BOOK

OF THE

DISEASES OF WOMEN.

BY

HENRY J. GARRIGUES, A. M., M. D.,

Professor of Obstetrics in the New York Post-Graduate Medical School and Hospital; Gynecologist to St. Mark's Hospital in New York City; Gynecologist to the German Dispensary in the City of New York: Consulting Obstetric Surgeon to the New York Maternity Hospital; Consulting Obstetrician to the New York Infant Asylum (resigned); Ex-President of the German Medical Society of the City of New York: Fellow of the American Gynecological Society; Fellow of the New York Academy of Medicine; etc.

CONTAINING THREE HUNDRED AND TEN ENGRAVINGS AND COLORED PLATES.

LANE MEDICAL LIBRARY
17848
SAN FRANCISCO

PHILADELPHIA:
W. B. SAUNDERS.
925 WALNUT STREET.
1894.

Copyright, 1894, by
W. B. SAUNDERS.

ELECTROTYPED BY
WESTCOTT & THOMSON, PHILADA.

PRESS OF
W. B. SAUNDERS, PHILADA.

N201
G242
1894

TO

ABRAHAM JACOBI, M.D.,

PROFESSOR OF DISEASES OF CHILDREN IN THE NEW YORK COLLEGE OF PHYSICIANS AND SURGEONS; EX-PRESIDENT OF THE MEDICAL SOCIETY OF THE STATE OF NEW YORK; EX-PRESIDENT OF THE NEW YORK ACADEMY OF MEDICINE, ETC., ETC.,

THIS WORK

IS RESPECTFULLY INSCRIBED

BY

THE AUTHOR.

PREFACE.

THE term "Diseases of Women" is understood to designate the affections of the genital organs in the female sex other than those connected with pregnancy, childbirth, and the puerperal state. That branch of medical science and art that is devoted to this subject is called *Gynecology*.

In writing this book I have first had in view the large class of physicians who have not had the advantage of hospital training, and *who go to a post-graduate school* in order to learn gynecology. They can only stay a short time, and they want a full but concise exposition, up to date, of the nature and treatment of the diseases peculiar to women.

Secondly, I have tried to satisfy the requirements of that much larger class who would like to go to such an establishment, but *who find it impossible to leave their practice.* They are busy men, who have to keep abreast of recent progress as best they can in all branches of a general practitioner's work. They want information about the present state of gynecology, but cannot find time to study large works.

If in large cities it is better for the general practitioner, as well as for his patient, to leave the treatment of most gynecological cases to those who have special experience and skill in this line, the same does not always hold good in country practice. The long distances in this immense country make it very difficult, and often impossible, to send patients to places where they can be treated by specialists. American physicians are enterprising, and some men practicing in a village have achieved world-wide renown, and become the leaders of their city confrères.

Finally, I think the book will be found useful by *undergraduates* studying in medical colleges. They will probably at that stage

of their development skip many details about operations, which they will be glad to take up later, when the responsibility of a medical practitioner lies heavy on their shoulders. The division into a general and a special part will presumably be useful for the beginner, and he will hardly care to pay much attention to what has been placed in notes under the text.

This being a book for General Practitioners and Students, I have omitted all reference to the historical development by which gynecology has attained its present stage, as well as all reports of special cases.

The limits and the nature of the work have not allowed me to speak of all methods of treating every disease, but I have striven to give a clear and succinct description of the best modes of treatment; and the reader will in this book find many details which he would look for in vain in larger works.

My aim has been to write a practical work. The reader's time is not taken up by theoretical discussions, and the pathology has been treated very briefly. On the other hand, I have tried to help the reader to make a diagnosis, and to teach him how to treat the different diseases. In this respect I have gone into minute details affording manifold information about points which practitioners who live in large cities learn from one another or by visits to the shops of the instrument-makers.

I have treated so discursively of the anatomy of the female genitals because this subject, to a great extent, has been worked up by the gynecologists themselves, and is not as yet described satisfactorily in the text-books of anatomy, but only in large works of an encyclopedic character or in articles in journals to which many have not access.

I expect to be criticised for having devoted special chapters to Hemorrhage and Leucorrhea. I know well that they are not diseases; but they are symptoms that play so great a part in the diseases of women, and so often require symptomatic treatment, that I take it to be in the interest of the general practitioner to treat them separately; and besides, by so doing infinite repetitions are avoided.

This being a text-book for beginners and a manual for general practitioners, names of authors have been omitted as much as possible from the text, except when it was necessary in order to designate

different methods of operations. In making use of the work of American authors I have, however, given them credit for it in foot-notes, and I trust that it will be found that a large amount of information of this kind has been embodied in the text.

In indicating the treatment of the various affections, I mention always the simpler and innocuous means before the more complicated and dangerous, medical and electrical treatment being accorded precedence over surgical.

Throughout the work a chief object has been to give modes of treatment as they are practiced in America, by which I hope that it will be found more useful for American students and practitioners than the works written by or translated from foreign authors.

The Illustrations form a *complete atlas of the embryology and anatomy of the female genitalia*, and represent numerous operations and pathological conditions. Many come from my own operations, dissections, and microscopical examinations.

155 LEXINGTON AVENUE, New York, January, 1894.

CONTENTS.

GENERAL DIVISION.

PART I.

PAGE

DEVELOPMENT OF THE FEMALE GENITALS 19

PART II.

ANATOMY OF THE FEMALE PELVIC ORGANS 35

PART III.

PHYSIOLOGY 113

CHAPTER I.

PUBERTY 113

CHAPTER II.

MENSTRUATION AND OVULATION 114

CHAPTER III.

COPULATION 120

CHAPTER IV.

FECUNDATION 120

CHAPTER V.

THE CLIMACTERIC 121

PART IV.

ETIOLOGY IN GENERAL 125

PART V.

EXAMINATION IN GENERAL 130

Verbal Examination 130

Age 130

Social Position and Pursuits 130

Duration of Sickness 130

Condition 130

Childbirth and Miscarriages 130

PAGE
Menstruation 131
Discharge 132
Micturition and Defecation 132
Pain 132
Nutrition and Strength 132
Family History 132
Special Questions 133
Physical Examination.
I. Positions 134
II. Examination of the Pelvis 137
A. Inspection 137
B. Digital Examination 137
C. Artificial Prolapse of the Uterus 140
D. Specula 142
E. Sound 150
F. Probe 151
G. Curette 151
H. Dilatation 152
I. Examination of Virgins 155
III. Examination of the Abdomen 155
A. Inspection 155
B. Palpation 155
C. Percussion 156
D. Auscultation 156
E. Menstruation 156
F. Development of Gas and Injection of Water 156
G. Charts 157
IV. Other Means of Investigation common for Pelvic and Abdominal Diseases 157
A. Exploratory Aspiration 157
B. Exploratory Incision 157
C. Urinary Analysis 158
D. Catheterization of the Bladder 159
E. Microscopical Examination 159
F. Chemical Examination 159
G. Examination under Anæsthesia 159
H. Examination of the Ureters 159

PART VI.

TREATMENT IN GENERAL 164
Preventive Treatment 164
External Treatment 165
A. Applications 165
B. Injections 166
Vaginal 166
Intra-uterine 168
Rectal 169
Vesical 170
C. Curetting 171

PAGE
D. Tamponade . . . 172
Pledgets in the Vagina . . . 173
Packing the Vagina . . . 173
The Hemostatic Plug . . . 174
Tamponade of the Uterus . . . 175
Abdominal Tamponade . . . 176
E. Hemostasis . . . 176
Hot Water . . . 177
Styptics . . . 177
Cauterization . . . 177
Ligature . . . 177
Forcipressure . . . 180
F. Dilatation . . . 180
G. Drainage . . . 180
H. Bloodletting . . . 182
I. Heat and Cold . . . 183
J. Counter-irritation . . . 184
K. Tapping and Aspiration . . . 185
L. Abdominal Belt . . . 186
M. Massage . . . 187
N. Gymnastics . . . 188
O. Operations in general . . . 188
1. Time for Operating . . . 188
2. Preparation . . . 190
Room . . . 190
Table . . . 190
Assistants . . . 191
Spectators . . . 192
Patient . . . 192
Vessels and Towels . . . 194
Disinfection . . . 195
Sponges . . . 195
Gauze . . . 196
Silk . . . 196
Catgut . . . 197
Silkworm Gut . . . 199
Silver Wire . . . 199
Iodoform . . . 199
Antiseptic Fluids . . . 199
Bichloride of Mercury . . . 199
Carbolic Acid . . . 200
Creolin . . . 200
Hydronaphthol . . . 200
Borosalicylic Solution (Thiersch's Solution) . . . 200
Thymol . . . 200
3. Anæsthesia . . . 200
Ether . . . 201
Chloroform . . . 202
Cocaine . . . 203

PAGE
4. Common Instruments and their Use 204
Vaginal Retractors 205
Tenacula 205
Volsellæ 205
Tenaculum-forceps 206
Sponge-holders 206
Knives 206
Scissors 206
Pressure-forceps 207
Needles 207
Needle-holders 208
Ligatures 209
Sutures 210
Sponging and Irrigation 215
How to Clean and Keep Instruments 215
Selection of Instruments 215
5. Combination of Operations 215
6. After-treatment 216
C. Internal Treatment 216
Food and Drink 216
Aperients 217
Tonics 217
Anodynes 218
Sedatives 218
Hypnotics 218
Resolvents 218
Hemostatics 218
Antipyretics 220
D. Electric Treatment 220
Franklinism 220
Faradism 221
Galvanism 222
Different Qualities of the Two Poles 225
Apostoli's Method 225
Chemical Galvanocauterization of the Cervix 226
Galvanopuncture 226
Galvanism combined with Aspiration, Irrigation, and Drainage . . . 227
Thermal Galvanocauterization 227

PART VII.

ABNORMAL MENSTRUATION AND METRORRHAGIA 229

CHAPTER I.

AMENORRHEA 229

CHAPTER II.

VICARIOUS MENSTRUATION 232

CHAPTER III.

DYSMENORRHEA 233

PAGE

CHAPTER IV.

PRECOCIOUS AND TARDY MENSTRUATION 235

CHAPTER V.

MENORRHAGIA 236

CHAPTER VI.

METRORRHAGIA 238

CHAPTER VII.

GENERAL MENSTRUAL DISORDERS 238

PART VIII.

LEUCORRHEA 241

SPECIAL DIVISION.

PART I.

DISEASES OF THE VULVA 247

CHAPTER I.

MALFORMATIONS 247

1. Absence of the Vulva 247
2. Hypospadias 247
3. Epispadias 248
4. Abnormalities of the Clitoris 248
5. Abnormalities of the Labia Minora 250
6. Abnormalities of the Labia Majora 250
7. Epithelial Coalescence 250
8. Hermaphrodism 250

CHAPTER II.

RUPTURES (HERNIÆ) 252

1. Anterior Labial, or Inguinolabial, Hernia 252
2. Posterior Labial, or Vaginolabial, Hernia 253

CHAPTER III.

TUMORS CONNECTED WITH THE EXTRAPELVIC PORTION OF THE ROUND LIGAMENT 254

1. Hydrocele 254
2. Hematocele of the Canal of Nuck 255
3. Hematoma of the Round Ligament 255
4. Fibroma of the Round Ligament 256

CHAPTER IV.

INJURIES 257

CHAPTER V.

VULVITIS 258

CHAPTER VI.

INFLAMMATION OF THE URETHRAL DUCTS 262

PAGE

CHAPTER VII.

Gangrene of the Vulva 262

CHAPTER VIII.

Exanthematous Diseases 263
Herpes Progenitalis 263

CHAPTER IX.

Trichiasis 264

CHAPTER X.

Pruritus Vulvæ 264
Burning Sensation in the Genitals and the Abdomen 266

CHAPTER XI.

Hyperæsthesia of the Vulva 267

CHAPTER XII.

Tumors of the Vulva 267
1. Hyperplasia 267
2. Varicose Veins 268
3. Hematoma, or Thrombus 268
4. Papilloma 269
5. Elephantiasis, or Pachydermia 271
6. Fibroma 272
7. Myoma, Myxoma, Lipoma 273
8. Enchondroma of the Clitoris 273
9. Horn of the Clitoris 274
10. Urethral Caruncle, Angioma, and Neuroma of the Vulva 274
11. Cysts 275
12. Cancer 275
13. Lupus; Esthiomène; Chronic Inflammation, Infiltration, and Ulceration 277

CHAPTER XIII.

Tuberculosis 280

CHAPTER XIV.

Progressive Atrophy of the Nymphæ, or Kraurosis 280

CHAPTER XV.

Diseases of the Vulvovaginal Glands 281

CHAPTER XVI.

Venereal Diseases 283
1. Gonorrhea 283
2. Chancroid 283
3. Syphilis 285

CHAPTER XVII.

Prolapse of the Urethra 288

CHAPTER XVIII.

Masturbation 289
Clitoridectomy 292

PAGE

PART II.

DISEASES OF THE PERINEUM 293

CHAPTER I.

INJURIES 293
I. Injuries from Without 293
II. Injuries from Within 293
A. Recent Lacerations 293
Primary Operation 295
Rupture of the Outer Ring 295
Rupture of the Inner Ring 297
Intermediate Operation 299
B. Old Lacerations 299
1. Tait's Flap-splitting Operation 299
a. For Incomplete Laceration 299
b. For Complete Laceration 302
2. Hegar's Colpoperineorrhaphy 303
a. For Incomplete Laceration 303
b. For Complete Laceration 306
3. T. A. Emmett's Operation 308
a. For Incomplete Laceration (the new operation) 308
b. For Complete Laceration 311
Preparation and After-treatment 313

CHAPTER II.

GARRULITY OF THE VULVA, OR FLATUS VAGINALIS 314

CHAPTER III.

COCCYGODYNIA 314

CHAPTER IV.

HYGROMA PERINÆI 316

PART III.

DISEASES OF THE VAGINA 317

CHAPTER I.

MALFORMATIONS 317
A. Malformations of the Hymen 317
1. Absence of the Hymen 317
2. Atresia Hymenalis 317
3. Abnormal Openings in the Hymen 319
4. Double Hymen 319
5. Fleshy Hymen 319
B. Malformations of the Vagina 319
1. Atresia and Stenosis of the Vagina 319
2. Double Vagina 323
3. Blind Canals in the Vagina 324
4. Faulty Communications of the Vagina 324

PAGE

CHAPTER II.

Vaginal Enterocele 325

CHAPTER III.

Prolapse of the Anterior Wall of the Vagina; Cystocele 326

CHAPTER IV.

Prolapse of the Posterior Wall of the Vagina; Rectocele 331

General Prolapse and Inversion 331

CHAPTER V.

Injuries; Thrombus, or Hematoma 331

CHAPTER VI.

Foreign Bodies 333

CHAPTER VII.

Vaginitis 334

A. Catarrhal Vaginitis 335

Exfoliative Vaginitis 339

Emphysematous Vaginitis 339

Mycotic Vaginitis 340

B. Exudative Vaginitis 341

C. Phlegmonous Vaginitis 341

CHAPTER VIII.

Gangrene 343

CHAPTER IX.

Erysipelas 344

CHAPTER X.

Cicatrices 344

CHAPTER XI.

Vaginismus 345

CHAPTER XII.

Neoplasms 348

1. Cysts 348

2. Fibroids 348

3. Mucous Polypi 351

4. Sarcoma 351

5. Carcinoma 351

6. Tuberculosis 353

CHAPTER XIII.

Fistulæ 353

A. Urinary Fistulæ 354

1. Vesicovaginal Fistula 354

2. Urethrovaginal Fistula 363

3. Ureterovaginal Fistula 363

4. Vesico-uterine Fistula 365

PAGE
5. Vesico-uterovaginal Fistula 366
6. Uretero-uterine Fistula 366
7. Ureterovesicovaginal Fistula 366
Genital Cleisis 367
Urinals 367
Pawlik's Operation for Incontinence 368
B. Fecal Fistulæ 369

PART IV.

DISEASES OF THE UTERUS 375

CHAPTER I.

MALFORMATIONS 375
A. Excessive Development and Precocity 375
B. Arrest of Development during the First Half of Intra-uterine Life . . . 375
1. Absence of the Uterus 375
2. Rudimentary Uterus 376
3. Uterus Duplex Separatus, or Uterus Didelphys 376
4. Uterus Unicornis 376
5. Uterus Bicornis 377
6. Uterus Septus 377
7. Atresia Uteri 378
C. Arrest of Development during the Second Half of Intra-uterine Life . . 379
1. Fetal and Infantile Uterus 379
2. Pubescent, or Congenitally Atrophic, Uterus 380
3. Uterus Parvicollis and Acollis 380
4. Congenital Anteflexion 381
D. Irregular Development 381
1. Obliquity 381
Lateroflexion 381
Lateroversion 381
2. Malposition 381
Lateroposition 381
Anteposition 381
Retroposition 381
3. Hernia Uteri 381
4. Elongated Cervix and Stenosis of the Cervical Canal 381

CHAPTER II.

INJURIES 381
A. Injuries of the Body 381
B. Laceration of the Cervix 383

CHAPTER III.

FOREIGN BODIES 390

CHAPTER IV.

METRITIS 390
A. Acute Metritis 390
Diphtheritic Metritis 393
Dissecting Metritis 394

PAGE
B. Chronic Metritis 394
1. Chronic Endometritis 394
2. Chronic Parenchymatous Metritis 403

CHAPTER V.

CLOSURE OF THE UTERUS (ACQUIRED ATRESIA) 407

CHAPTER VI.

STENOSIS OF THE CERVIX 408

CHAPTER VII.

ULCERS OF THE CERVIX 410

CHAPTER VIII.

HYPERTROPHY OF THE UTERUS 411
A. Infravaginal Hypertrophy of the Cervix 412
B. Supravaginal Hypertrophy of the Cervix 413

CHAPTER IX.

ACQUIRED ATROPHY OF THE UTERUS (SUPERINVOLUTION) 417

CHAPTER X.

GANGRENE OF THE UTERUS 418

CHAPTER XI.

HYSTERALGIA 418

CHAPTER XII.

DISPLACEMENTS 419
A. Anteversion 420
B. Anteflexion 424
C. Retroversion 429
D. Retroflexion 429
E. Lateroversion and Lateroflexion 440
F. Prolapse 440
G. Elevation 446
H. Inversion 446
I. Hernia 452

CHAPTER XIII.

NEOPLASMS 453
A. Cysts of the Cervix; Adenoma Uteri; Mucous Polypi; Myxoma 453
B. Uterine Fibroids, Fibroid Polypi, and Fibrocysts of the Uterus 454
C. Sarcoma 483
D. Carcinoma 486
E. Papilloma 500
F. Enchondroma 500
G. Tuberculosis 500

PART V.

DISEASES OF THE FALLOPIAN TUBES 502

PAGE

CHAPTER I.

MALFORMATIONS 502

CHAPTER II.

SALPINGITIS 503
Cystic Salpingitis 517
Pyosalpinx 519
Hydrosalpinx 520
Hematosalpinx 521

CHAPTER III.

DISPLACEMENTS 522

CHAPTER IV.

NEOPLASMS 522
A. Cysts 523
B. Fibroma 523
C. Lipoma 523
D. Papilloma 523
E. Cancer (Carcinoma and Sarcoma) 523
F. Tuberculosis 523

PART VI.

DISEASES OF THE OVARIES 525

CHAPTER I.

MALFORMATIONS 525

CHAPTER II.

DISPLACEMENTS 526
Extrapelvic Displacements 526
Intrapelvic Displacements, or Prolapse 527

CHAPTER III.

HYPEREMIA AND HEMATOMA 530

CHAPTER IV.

OÖPHORITIS 533
A. Acute Oöphoritis 533
B. Chronic Oöphoritis 535
Gyroma and Endothelioma 539

CHAPTER V.

NEOPLASMS 543
A. Ovarian Cysts 543
I. Dropsical Graafian Follicles 544
Rokitanski's Tumor 546
II. Proliferating Cysts 547
a. Glandular 548
b. Papillary 556
c. Mixed 557
III. Dermoid Cysts 557

PAGE
IV. Tubo-ovarian Cysts, or Hydrocele of the Ovary 559
Origin of Ovarian Cysts 563
Etiology 564
Symptoms 564
Accidents 569
Hemorrhage 569
Inflammation and Suppuration 569
Torsion of the Pedicle 569
Rupture of the Cyst 569
Ascites 570
Peritonitis 570
Intestinal Obstruction 570
Explorative Puncture 571
Diagnostic Value of the Fluid 571
Explorative Incision 572
Differential Diagnosis 572
A. Pelvic Tumor 572
B. Abdominal Tumor 573
Complications 578
Prognosis 579
Treatment 579
Tapping 580
Ovariotomy 582
Vaginal Ovariotomy 583
Abdominal Ovariotomy 585
Difficulties met with during Operation 591
Incomplete Operations 597
Complications of Ovarian Cysts 603
Complications during the After-treatment 605
Prognosis of Ovariotomy 609
B. Solid Ovarian Tumors 609
I. Fibroma 610
II. Papilloma 611
III. Sarcoma 611
IV. Endothelioma 612
V. Carcinoma 612
VI. Tuberculosis 613

CHAPTER VI.

OÖPHORALGIA 614

PART VII.

DISEASES OF THE PELVIS 616
(The Peritoneum, the Connective Tissue, the Vessels of the Pelvis, and the Ligaments of the Uterus.)

CHAPTER I.

MALFORMATIONS 616

CHAPTER II.

ANEURYSM OF THE UTERINE ARTERY 616

PAGE

CHAPTER III.

DISEASES OF THE BROAD LIGAMENT 617
A. Variocele 617
B. Cysts of the Broad Ligament 618
C. Solid Tumors of the Broad Ligament 621

CHAPTER IV.

DISEASES OF THE ROUND LIGAMENT 621

CHAPTER V.

DISEASES OF THE SACRO-UTERINE LIGAMENTS 621

CHAPTER VI.

PELVIC HEMORRHAGE 622
A. Intraperitoneal Hemorrhage 622
B. Hematocele 623
C. Hematoma 628

CHAPTER VII.

PERIMETRIC INFLAMMATION 630
A. Pelvic Peritonitis 630
B. Pelvic Cellulitis 641
C. Pelvic Phlebitis 648
D. Pelvic Lymphangitis and Lymphadenitis 648

CHAPTER VIII.

SARCOMA AND CARCINOMA OF THE PELVIC PERITONEUM AND CONNECTIVE TISSUE 651

CHAPTER IX.

HYDATIDS OF THE PELVIS 651

APPENDIX.

STERILITY 654
Lack of Orgasm 659

DISEASES OF WOMEN

OR

GYNECOLOGY.

GENERAL DIVISION.

DISEASES OF WOMEN.

GENERAL DIVISION.

PART I.

DEVELOPMENT OF THE FEMALE GENITALS.

THE history of the development of the female genitals being an indispensable key to the understanding of their malformations, which are of frequent occurrence and often of great importance in regard to life and happiness, we give here a résumé of the same.*

THE WOLFFIAN DUCTS.

The first organs belonging to the genital sphere which appear in the male as well as the female embryo are the Wolffian ducts. There is one on either side of the body, situated between the proto-

FIG. 1.

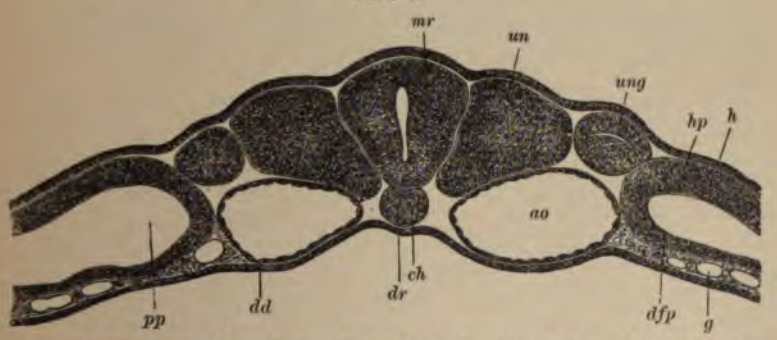

Transverse Section through the Median Part of the Body of the Embryo of a Rabbit of nine days and two hours (enlarged 158 times): *dd*, hypoblast; *dr*, intestinal groove; *ch*, notochord; *ao*, descending aortæ; *un*, protovertebra; *mr*, medullary tube; *ung*, Wolffian duct; *dfp*, visceral division of the mesoblast; *g*, vessels in the deeper parts of the visceral mesoblast; *hp*, parietal mesoblast; *h*, epiblast; *pp*, pleuro-peritoneal cavity (Kölliker).

vertebral column and the lateral plates (Fig. 1). Originally it is a

* This is an abstract of the author's more elaborate article on the subject in *A System of Gynecology by American Authors*, edited by M. D. Mann, Philadelphia, 1887.

solid string, but it is later tunnelled, so as to form a tube. The upper end lies on a level with the fourth or fifth vertebra, and connects soon with the Wolffian body, forming its outlet. The lower end opens into that part of the allantois which is situated in the body of the embryo and communicates with the cloaca. After the separation between the urogenital canal and the intestine the Wolffian duct ends in the urogenital sinus (Fig. 2).

FIG. 2.

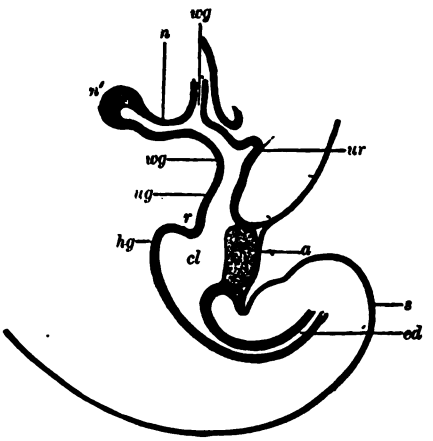

Sagittal Section through the Posterior Part of the Body of the Embryo of a Rabbit of eleven days and ten hours (enlarged 45 times): *wg*, Wolffian duct; ureter; *n*, beginning formation of the kidney; *ug*, urogenital sinus; *cl*, cloaca; *hg*, region in which, in the mesial plane, the hind-gut, opens into the cloaca; *ed*, post-anal gut; *a*, anus, or fissure of the cloaca; *s*, tail; *r*, perineal fold (Kölliker).

In the male the Wolffian duct becomes, in the course of time, the tail of the epididymis and the vas deferens. In the female it disappears more or less completely. Still, in the cow and the sow it persists as *Gartner's canal.* In woman remnants of it are found in the broad ligaments.

THE WOLFFIAN BODIES.

Shortly after the Wolffian ducts appear the Wolffian bodies. These are two long prismatic bodies, one on either side of the median line (Fig. 3). The upper end is fastened to the diaphragm, the lower to the inguinal region by a ligament which in course of time becomes the round ligament of the uterus, or the gubernaculum testis in the male (Fig. 4). They fill the hollow of the posterior wall of the abdominal cavity, leaving a narrow fissure on either side. In the inner one of these is later developed the genital gland; in the outer lies the Wolffian duct, and later also the Müllerian duct.

These bodies originate from the endothelium of the peritoneum, and form at first a long row of pear-shaped solid bodies. Later,

FIG. 3.

Human Embryo of thirty-five days (front view): 3, left external nasal process; 4, superior maxillary process; *z*, tongue; *b*, aortic bulb; *b'*, first permanent aortic arch; *b''*, second aortic arch; *b'''*, third aortic arch, or ductus Botalli; *y*, the two filaments to the right and the left of this letter are the pulmonary arteries, which just begin to be developed; *c*, the trunk of the superior vena cava and right azygos vein; *c'*, the common venous sinus of the heart; *c''*, the common trunk of the left vena cava and left azygos vein; *o*, left auricle of the heart; *v*, right ventricle; *v'*, left ventricle; *ae*, lungs; *e*, stomach; *j*, left omphalo-mesenteric vein; *s*, continuation of the same behind the pylorus, which afterward becomes the vena porta; *x*, vitello-intestinal duct; *a*, right omphalo-mesenteric artery; *m*, Wolffian body; *i*, gut; *n*, umbilical artery; *u*, umbilical vein; *S*, tail; *9*, anterior limb; *9'*, posterior limb. The liver has been removed. The white band at the inner side of the Wolffian body is the genital gland, and the two white bands at its outer side are the Müllerian and the Wolffian ducts (Coste).

these are separated from the peritoneum and become hollow, forming a row of vesicles called the *segmental vesicles*, each of which soon connects with the Wolffian duct by the absorption of the tissue intervening between their cavities and the bore of the duct. The former

vesicles appear now as branches of the Wolffian duct (Fig. 5), which grow rapidly and connect at the other end with arterial tufts in the same way as the uriniferous ducts and the Malpighian tufts in the kidneys.

In the male the Wolffian body later is transformed into the *epidididymis* and the *organ of Giraldez* (Fig. 6); in the female into *Rosen-*

FIG. 4.

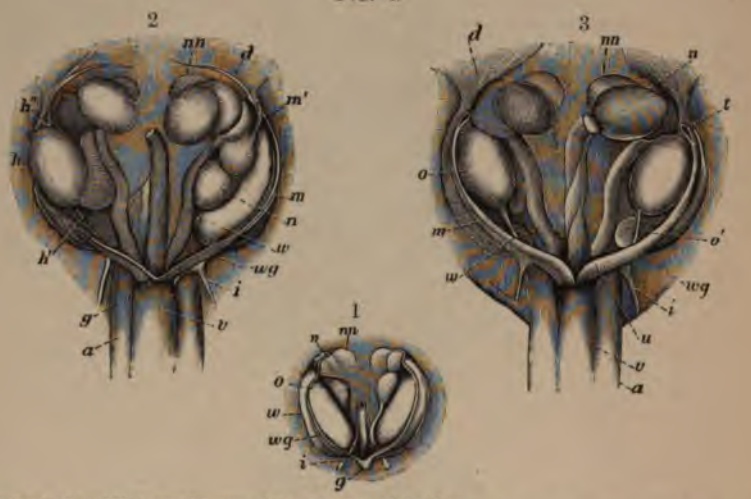

The Genital and Urinary Organs of the Embryo of Cattle:
1, from a female embryo 1½ inches long (double size); *w*, Wolffian body; *wg*, Wolffian and Müllerian ducts; *i*, inguinal ligament of Wolffian body; *o*, ovary with an upper and lower peritoneal fold; *n*, kidney; *m*, suprarenal body; *g*, genital cord, composed of the united Wolffian and Müllerian ducts.
2, from a male embryo 2½ inches long (nearly three times natural size): one of the testicles has been removed. Letters as in Fig. 1, and, besides, *m*, Müllerian duct; *m'*, upper end of the same; *h*, testicle; *h'*, lower ligament of testicle; *h''*, upper ligament of testicle; *d*, diaphragmatic ligament of Wolffian body; *a*, umbilical artery; *v*, bladder.
3, from a female embryo (enlarged nearly three times). Letters as in Figs. 1 and 2, and, besides, *t*, opening of the upper end of Müller's duct; *o'*, lower ovarian ligament; *u*, thickened part of Müllerian duct, which later becomes the uterine horn (Kölliker).

müller's organ, or the *parovarium*, and stray tubes found between the parovarium and the uterus (Fig. 7).

THE OVARIES.

In the beginning the sexual glands are identical in both sexes. At the end of the second month the ovary and the testicle begin to differ from one another, the testicle becoming broader and shorter, while the ovary stays long and narrow. The ovary has a much more developed columnar epithelium than the testicle.

The sexual glands are situated on the inner side of the Wolffian body (Fig. 4), to which they are fastened by a fold of the peritoneum

called the *mesorchium* in the male and the *mesoarium* in the female. At the upper end is a ligament which unites with the diaphragmatic ligament of the Wolffian body; at the lower end is another ligament, which is fastened to the Wolffian duct, opposite the starting-point of the inguinal ligament of the Wolffian body, and which later becomes the permanent *ligament of the ovary.*

The shape of the ovary undergoes great changes. At first it is a long flat body. Later it grows, especially at the edges, so that a transverse section has the shape of a bean or a mushroom (Fig. 8), and finally the transverse section becomes pear-shaped.

The ovary is subject to a *descent* just as the testicle. At the birth of the child the ovaries are yet situated above the ileo-pectineal line, and descend into the true pelvis during the first two or three months

FIG. 5.

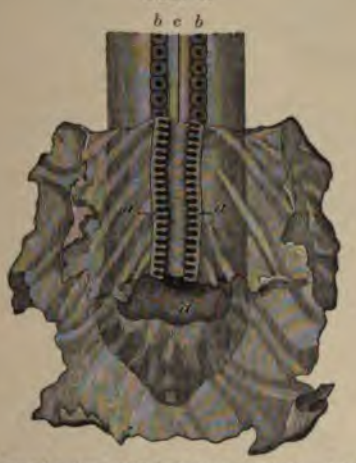

Posterior End of the Embryo of a Dog, with budding alantoid. The mesoblast and the hypoblast, or the beginning of the intestine and the neighboring parts of the blastodermic vesicle, are thrown back in order to show the Wolffian bodies (enlarged 10 times). *a*, Wolffian bodies, with the duct and the single blind canals; *b*, protovertebræ; *c*, spinal marrow; *d*, entrance to the pelvic intestinal cavity (Bischoff).

of the child's life. This descent is partly apparent and partly real: it is chiefly due to the greater growth of the parts above the ovaries; but, besides that, a shrinking of the round ligament of the uterus takes place, by which the ovaries indirectly are pulled down. At the same time there is a change in position by which the upper end sinks considerably downward and outward, and the whole organ turns around its long axis until the inner edge becomes the lower, where the hilum is; the outer becomes the upper, free edge; the anterior surface becomes the inner, the posterior becomes the outer. The relations to the Fallopian tube are changed in such a way that the

ovary, instead of lying inside of the Müllerian duct, as it does at first, finally lies behind and below the tube.

FIG. 6.

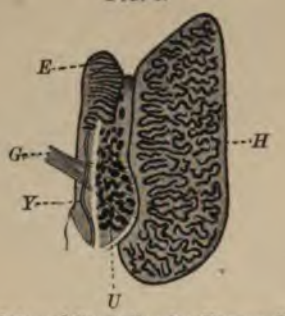

FIG. 7.

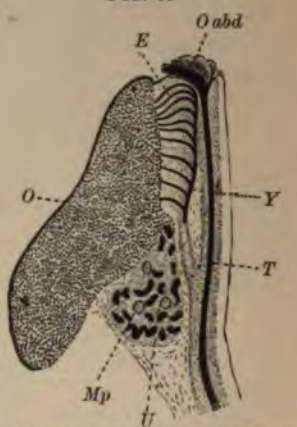

FIG. 6.—Internal Genitalia of a Human Fetus, 9 cm. long (enlarged 8 times): *H*, testicle; *E*, epididymis (epididymal part of Wolffian body); *U*, organ of Giraldez (uropoetic part of Wolffian body); *G*, bundle of connective tissue containing vessels; *Y*, vas deferens (Wolffian duct) (Waldeyer).

FIG. 7.—Internal Genitalia of a Human Female Fetus, 9 cm. long (enlarged 10 times); *O*, ovary; *T*, tube; *O abd.*, abdominal ostium of tube; *E*, parovarium; *U*, uropoetic part of the Wolffian body remaining as tubes between parovarium and uterus; *Y*, Wolffian duct disappearing lower down; *Mp.*, Malpighian bodies (Waldeyer).

The ovarian vessels enter originally at the upper end of the

FIG. 8.

Transverse Section of Ovary of Human Embryo of three months (enlarged 43 times): *a*, mesoarium; *a'*, stroma of the hilum (medullary substance); *b*, glandular tissue (cortical substance) (Kölliker).

mesoarium from the posterior wall of the abdomen, and are enclosed in a fold of the peritoneum, which in the course of time becomes the *infundibulo-pelvic ligament*, extending from the fimbriæ of the tube to

FIG. 9.

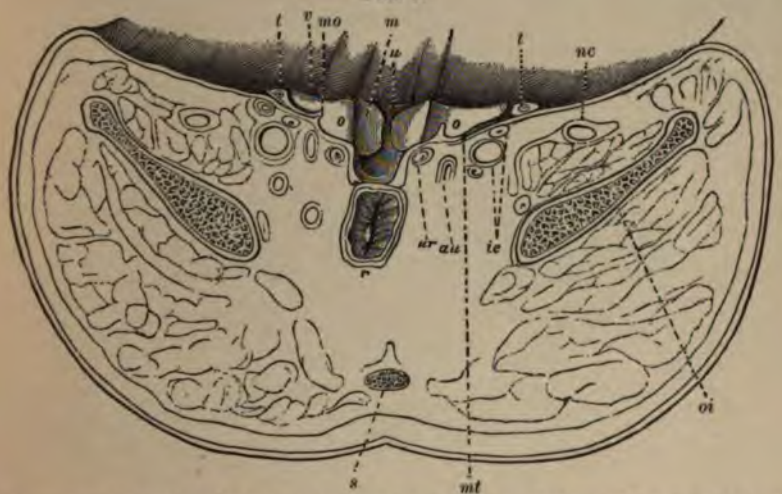

Transverse Section through the Ovarian Region of a Human Embryo of five months; lower surface seen from above (enlarged 3 times): *oi*, os ilium; *s*, sacrum; *mo*, mesoarium and hilum of ovary, bounded by two lips; *o*, cut surface of the ovary; *v*, free ventral surface or lateral part of the ventral surface of the ovary; *t*, tube; *mt*, mesentery of tube (later ala vespertilionis); *r*, rectum; *u*, uterus; *ur*, ureter; *au*, umbilical artery; *ie*, external iliac vessels; *nc*, anterior crural nerve (Kölliker).

the wall of the pelvis. To the outer side of the mesoarium is attached the *mesosalpinx* (Fig. 9) or mesentery of the tube, which later is called

FIG. 10.

Ovary of a Human Fetus of ten or eleven weeks: *a*, superficial stratum of cells; *b*, layer of connective tissue; *c*, trabeculæ of connective tissue, the cells having been removed; *d*, mesoarium (H. Meyer).

ala vespertilionis (the bat's wing), and contains the remnants of the Wolffian body, especially the parovarium, but at this period has no connection with the uterus.

The Formation of Ova and Graafian Follicles.—At the earliest stage the ovary is represented by a mass of cells developed from the peritoneal cover of the Wolffian body, and soon a protuberance of connective tissue enters from behind into this cell-mass. These elements build up the whole ovary, the cells forming the parenchyma or glandular element, and the connective tissue the stroma.

FIG. 11.

Part of Ovary near Surface, from Human Fetus of sixteen weeks, showing formation separation of ova (H. Meyer).

FIG. 12.

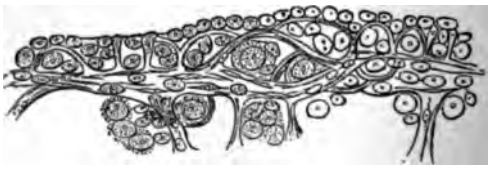

Part of Ovary near Surface, from Human Fetus of twenty-eight weeks. In some appears the permanent epithelium, composed of a single layer (H. Meyer

FIG. 13.

Part of Ovary near Surface, from a Human Fetus of thirty-six weeks. The single epithelium is interrupted by a belated primordial ovum with its follicular epithelium (H. Meyer).

longations from the connective tissue grow in between the ova, separate them, forming groups, and grow together over them; from this cover new prolongations start, and new cells are formed on the surface (Fig. 10). In this way irregular

with cells are formed which connect with one another, much like the canals found in a sponge (Figs. 11, 12, 13); but finally the whole surface is only covered by a single layer of cells, the columnar epithelium, under which is found a layer of connective tissue, the *albuginea*, and under that we find clusters of cells surrounded by connective tissue (Fig. 14), or sometimes a long row of large cells, each

FIG. 14.

Part of Section from Surface to Hilum of Ovary of Girl three days old: *s*, single layer of epithelium yet in connection with cluster of primordial ova. All ova have disappeared from the surface. A broad layer of stroma separates in most places the epithelium from the follicular zone. The farther we go from the surface toward the hilum, the fewer ova are there in one nest, until, finally, there is only one in its primary follicle; *n*, natural size of the whole ovary (H. Meyer).

surrounded by smaller cells, until finally all these clusters and columns are broken up into small compartments, each containing one

large cell and one or more smaller ones (Fig. 15). The large cells have each a large nucleus and nucleolus, and are the future ova, and

FIG. 15.

Perpendicular Section through the Ovary of a Bitch of six months (Hartnack, $\frac{1}{8}$): *a*, the epithelium; *b*, epithelial pouch opening on the surface; *c*, larger group of follicles; *d*, ovarian tube filled with ova; *e*, oblique and transverse sections of ovarian tubes (Waldeyer).

are called *primordial ova;* and the small cells multiply and form the epithelium of the *primary follicles,* which are the beginning of the Graafian follicles (Fig. 16).

FIG. 16.

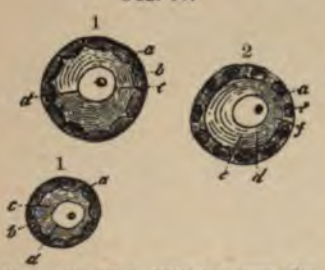

Three Graafian Follicles from the Ovary of a New-born Girl (enlarged 350 times): 1, natural condition; 2, treated with acetic acid; *a*, structureless membrane; *b*, epithelium (membrana granulosa); *c*, yolk; *d*, germinal vesicle, with germinal spot; *e*, nuclei of the epithelial cells; *f*, vitelline membrane (Kölliker).

The small cells increase in number and form several layers. A fissure is formed between them, and a fluid accumulates in this space, the beginning of the future *liquor folliculi.* The outer layers form the epithelium of the Graafian follicle, the so-called *membrana granulosa;* the inner continue to surround the ovum, forming the *discus proligerus* (Fig. 17). The fibrous membrane of the follicles is formed by a differentiation of the surrounding stroma.

It will be seen from the above description that the ova, the surface epithelium of the ovary, and the epithelium of the Graafian follicles have all one common origin, the cellular mass formed on the inner edge of the Wolffian body. As mother to so many epithelial formations, this is called the *germ-epithelium.* The formation of ova on the surface of the ovary ceases from the time the single layer of epithelium is formed, about the end of the seventh month, but it seems that the ova themselves multiply by division

lucts
the



the urachus,
the change

pass in front of it, and finally lie behind it. The lower part is at first formed by a solid column of cells which later is tunnelled so as to form a tube.

The Müllerian duct has a *mesentery*, by which it is fastened to the Wolffian body. After the disappearance of that body it springs from the posterior abdominal wall; still later from the mesoarium (Fig. 9), until, finally, in the fully-developed body we find it as part of the broad ligament of the uterus.

In the male the Müllerian ducts soon disappear, leaving as remnants the hydatid of *Morgagni* on the epididymis and the *vesicula*

FIG. 19.

Transverse Section through the upper end of the Wolffian Body of the Embryo of a Rabbit of fourteen days (enlarged 114 times): *wg*, Wolffian duct; *m*, connection between a tubule of the Wolffian body with a Malpighian body; *t*, entrance to the Müllerian duct (later the abdominal ostium of the Fallopian tube); *gg'*, mesentery of the Wolffian body, containing a glandular tubule; *W*, surface of the liver; *hb*, posterior abdominal wall; *mg*, lateral part of the Müllerian duct (Kölliker).

prostatica (*sinus copularis*, or *male uterus*). In the female they form the Fallopian tubes, the uterus, and the vagina.

The Fallopian Tubes.—The Fallopian tubes are formed of that part of the Müllerian ducts which lies above the round ligament of the uterus (the inguinal ligament of the Wolffian body, Fig. 4). The cells of the wall form the fibrous, muscular, and mucous coat of the fully-developed tube, and fringes grow out around the abdominal opening, forming the *fimbriæ*. The duct follows the ovary in its descent, and comes to lie above and in front of that organ, running from the upper corner of the uterus to the wall of the pelvis.

The Uterus and the Vagina.—The part of the Müllerian ducts below the round ligament forms, together with the lower ends of the

FIG. 20.

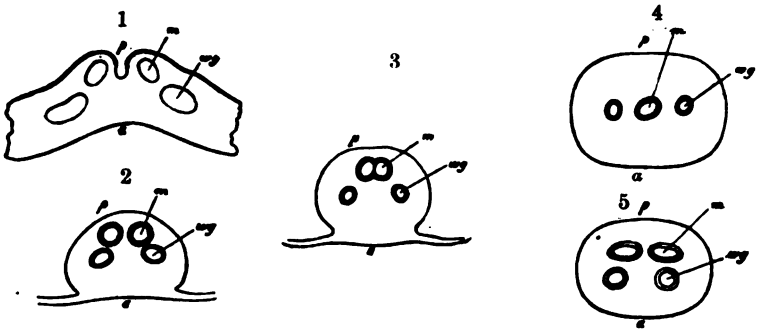

Transverse Section of the Genital Cord of the Embryo of a Cow, 2½ inches long (enlarged 14 times): 1, from the upper end of the cord (the ducts have been cut somewhat obliquely): 2, somewhat lower down; 3 and 4, from the middle of the cord, showing incomplete and complete fusion of Müller's ducts; 5, from the lower end, showing the two Müllerian ducts separated; *a*, anterior side of genital cord; *p*, posterior side; *m*, Müller's ducts; *wg*, Wolffian duct (Kölliker).

Wolffian ducts, a quadrangular cord with rounded edges, the *genital cord* (Fig. 20). The tissue that separates the two Müllerian ducts is gradually absorbed until there is one canal instead of two at the end of the second month. The genital cord is developed so as to form the uterus above and the vagina below. While the fusion of the Müllerian ducts is incomplete, they are yet separated above, forming the two *horns* of the uterus (Fig. 21). About the middle of pregnancy the uterus forms one sac without horns (Fig. 22).

FIG. 21.

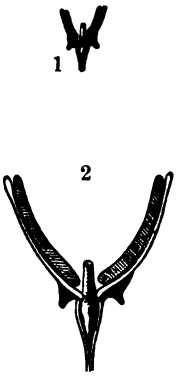

Ovaries, Tubes, and Uterus of Human Embryo from the tenth week, 26 mm. long: 1, natural size; 2, enlarged 4 times; *a*, round ligament; *b*, rectum (H. Meyer).

The Müllerian ducts open into the lower part of the urachus, that part of the allantois which is included in the body, and later forms the bladder (Fig. 23). This lower part, situate below the openings of the Müllerian and Wolffian ducts, is called the *urogenital sinus* (Fig. 2). Originally this sinus opens into the cloaca (Fig. 24). Later a septum is formed, dividing the cloaca and thereby separating the sinus urogenitalis from the rectum, and the urogenital opening from the anus, and forming the *perineum* (Fig. 25). The urogenital sinus grows much less than the other parts. The urethra is differentiated as a special organ from the bladder, with which it heretofore formed one sac called the urachus, and the vagina is undergoing a great development. Thus the change

is brought about that the urogenital sinus, which seemed to be a continuation of the bladder, now appears as the continuation of the vagina, and forms the *vestibule* (Fig. 26).

FIG. 22.

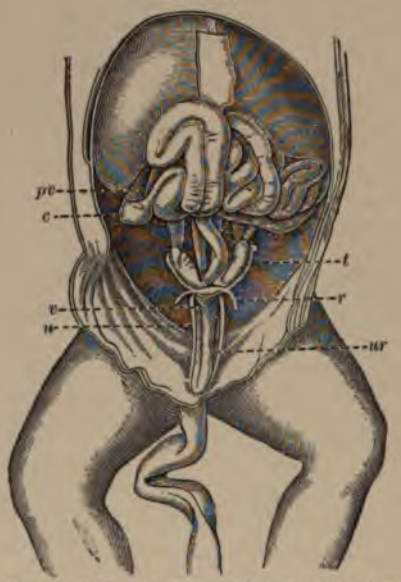

Abdominal and Pelvic Viscera of Female Fetus of five months (length from vertex to sole, 19 cm.): *t*, tube; *r*, round ligament; *v*, bladder; *u*, umbilical artery; *ur*, urachus; *c*, cæcum; *pv*, vermiform appendix (Kölliker).

In the fifth and sixth months the vagina is separated from the uterus by the formation of a ring (Fig. 26, 3), which finally becomes the *vaginal portion*.

FIG. 23.

FIG. 24.

FIG. 25.

FIG. 23.—*all*, allantois, which becomes the bladder; *r*, rectum; *m*, Müller's duct, which later is transformed into the vagina; *a*, indentation of the skin, which forms the anus (Schroeder).

FIG. 24.—*cl*, cloaca; *all*, allantois; *m*, Müller's duct; *r*, rectum (Schroeder).

FIG. 25.—*su*, urogenital sinus; *r*, rectum, separated from the former by the perineum; *v*, vagina (lower part of Müller's duct); *b*, bladder; *u*, urethra (Schroeder).

About the same time the cervix is being distinguished from the

body of the uterus by the formation of transverse folds on its mucous membrane.

In the new-born child the cervix is nearly twice as long as the body of the uterus, and its walls are much thicker. The anterior and posterior surfaces of the body have longitudinal folds, and in either edge is found another longitudinal ridge from which start to both sides fine transverse folds, ending at the longitudinal folds of the surfaces. They are a continuation of the transverse folds of the cervix. Later in life all these folds disappear from the cavity of the body of the uterus, while those in the cervix remain.

During the first ten or twelve years of the child's life the uterus changes very little, even in size, but at the approach of menstruation the organ undergoes a great development; and this increase in size

FIG. 26.

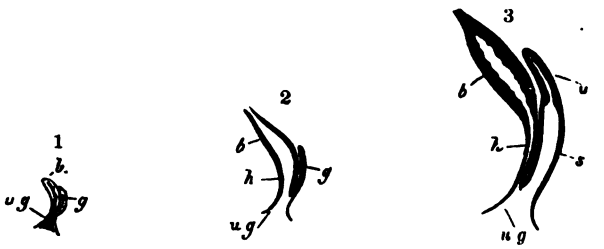

Urogenital Sinus and its Appendages, from Human Embryos (life-size): 1, from a three-months' fetus: 2, from a four-months'; 3, from a six-months'; *b*, bladder; *h*, urethra; *ug*, urogenital sinus; *g*, genital canal (common rudiment of vagina and uterus); *s*, vagina; *u*, uterus (Kölliker).

continues until the rest of the body has attained the limit of its growth.

After the differentiation between the uterus and the vagina, about the middle of pregnancy, the vagina becomes much wider, and its columns and rugæ make their appearance.

The Hymen.—The hymen is formed in the fifth month by a development of the posterior wall of the vagina.

THE VULVA.

We have seen that originally the urogenital and the digestive tract open into one common cavity called the cloaca. Toward the end of the first month the cloaca opens on the surface of the body by a slit called the *cloacal opening*. In front of this opening there appears in the sixth week a protuberance called the *genital tubercle*, which soon thereafter is surrounded by two lateral folds called the *genital folds*. The genital tubercle grows, and toward the end of the second month

there is formed a groove on its lower surface which extends to the cloacal opening, and is called the *genital furrow* (Fig. 27).

So far, the organs are identical in both sexes, and they cannot be distinguished before the tenth week. The genital tubercle becomes the clitoris, the genital folds form the labia majora, the edges of the genital furrow are developed into the labia minora, a fold of which later surrounds the clitoris, forming its prepuce.

FIG. 27.

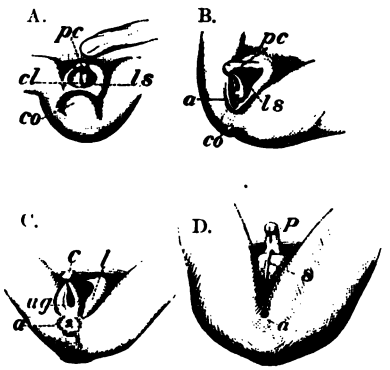

Development of the External Sexual Organs in the Male and the Female from the indifferent type: A, the external sexual organs in an embryo of about nine weeks, in which external sexual distinction is not yet established, and the cloaca still exists; B, the same in an embryo somewhat more advanced, and in which, without marked sexual distinction, the anus is now separated from the urogenital aperture; C, the same in an embryo of about ten weeks, showing the female type; D, the same in a male embryo somewhat more advanced; *pc*, common blastema of penis and clitoris or genital tubercle (to the right of these letters in Fig. A is seen the umbilical cord); *p*, penis; *c*, clitoris; *cl*, cloacal opening; *ug*, urogenital opening; *a*, anus; *ls*, cutaneous elevation which becomes the labia or the scrotum, genital folds; *l*, labium; *s*, scrotum; *co*, caudal or coccygeal elevation (Ecker).

In the tenth week the separation between the rectum and the urogenital sinus is consummated. The genital folds grow together at their posterior end, forming a perineum, which unites with the partition between the urogenital sinus and the rectum. While at first the two canals are in close contact, in the fourth month there is a well-formed perineal body between them.

In the male the genital tubercle forms the penis; the edges of the genital furrow grow together, forming the urethra; and the genital folds form the scrotum and perineum. The line of coalescence is elevated above the surroundings, forming the *raphé*, which extends from the anus to the meatus urinarius.

In the open condition, which continues until the eleventh or twelfth week, the external genital parts are alike in both sexes, and resemble very much the advanced female organs.

PART II.

ANATOMY.[1]

Division.—The genitals are divided into two groups: the external genitals, which are organs of copulation; and the internal, which are organs of reproduction. To the external genitals belong the *mons Veneris*, the *vulva*, and the *vagina;* to the internal, the *uterus*, the *Fallopian tubes*, and the *ovaries*.

THE MONS VENERIS.

The mons Veneris (Venus' mount) is the lowest part of the anterior abdominal wall, and the only part of the genitals that is visible when the woman stands on her feet. It has somewhat the shape of a trapezoid, and is limited above by a transverse sulcus that separates it from the hypogastric region, on the sides by the inguinal folds, and below it is continuous with the labia majora. It lies in front of the pubic bones and the lower end of the abdominal muscles. It has a convex surface, and falls gently off toward the surrounding parts. It consists of skin, adipose tissue, with many interwoven fibrous and elastic bands, and part of the common superficial fascia. It is rich in nervous fibrils. The skin is coarse, has many sebaceous glands, and is covered by a growth of coarse hair, which is limited by a straight or convex upper line (Fig. 28), and does not extend up to the umbilicus, as in man. It is in most women curly, and darker than the hair of the head. This growth appears about puberty.

Function.—During copulation these hairs come in contact with the corresponding growth of the other sex, and by the irritation thus

[1] Those who wish further information than that warranted by the limits of this work are referred to the excellent articles by Henry C. Coe in the *System of Gynecology*, and Ambrose L. Ranney, *Am. Jour. Obstetrics*, March, April, May, June, 1883.

My own special investigations on anatomical questions are found incorporated in the following papers: "Gastro-elytrotomy," *N. Y. Med. Jour.*, Oct. and Nov., 1878; "The Obstetric Treatment of the Perineum," *Am. Jour. Obst.*, April, 1880; "Rest after Delivery," *ibid.*, Oct., 1880; "Laceration of the Cervix Uteri," *Archives of Medicine*, Oct., 1881; "Additional Remarks on Gastro-elytrotomy, *Am. Jour. Obst.*, Jan., 1883; "Gartner's Canals," *N. Y. Med. Jour.*, March 31, 1883; and "The Improved Cæsarean Section," *Am. Jour. Med. Sciences*, May, 1888.

caused in the nerves at their root give a pleasurable sensation. The *vessels* and *nerves* come from the same sources as those of the vulva (see below).

The Vulva.

The vulva (Fig. 28) forms and surrounds the entrance to the genital canal.

The following organs compose it: The labia majora, with the fourchette; the labia minora, with the clitoris; the vestibule, with the bulbs; the fossa navicularis; and the vulvo-vaginal glands.

Fig. 28.

Virginal Vulva: 1, labia majora; 2, fourchette; 3, labia minora; 4, glans clitoridis; 5, meatus urinarius; 6, vestibule; 7, entrance to the vagina; 8, hymen; 9, orifice of Bartholin's gland; 10, anterior commissure of labia majora; 11, anus; 12, blind recess; 13, fossa navicularis; 14, body of clitoris (modified from Tarnier).

The labia majora (larger lips, Fig. 28, 1) are two prominent ridges, one on either side of the median line. A transverse incision shows a triangular cut surface. They are situated in front of the descending ramus of the pubes and the ascending ramus of the ischium. The outer surface is convex, of darker color than the rest of the skin, covered with a continuation of the hair on the mons Veneris, and has numerous and large sebaceous and sudoriferous glands. The inner surface is rose-colored, and forms a transition from skin to mucous membrane, having the same glands as the outer surface, and even a few downy hairs. The place where they unite anteriorly is called the *anterior commissure*, and the place where they unite behind is called the *posterior commissure*. Here the tissue becomes very thin by the disappearance of the fat which forms a great part of the labia majora. Thus a thin fold is formed called the *fourchette*. Exceptionally, the fourchette is a continuation of the labia minora. Its lower surface consists of skin which has a dark color, similar to that of the external surface of the labia, while its upper surface is pink, and looks like mucous membrane. In the adult nulliparous woman the lower edges of the labia majora are in contact, cover all the other parts of the vulva, and form a line running in an antero-posterior direction and called *rima pudendi*. In the new-born child, in whom the labia majora are incompletely developed, the labia

Fig. 29.

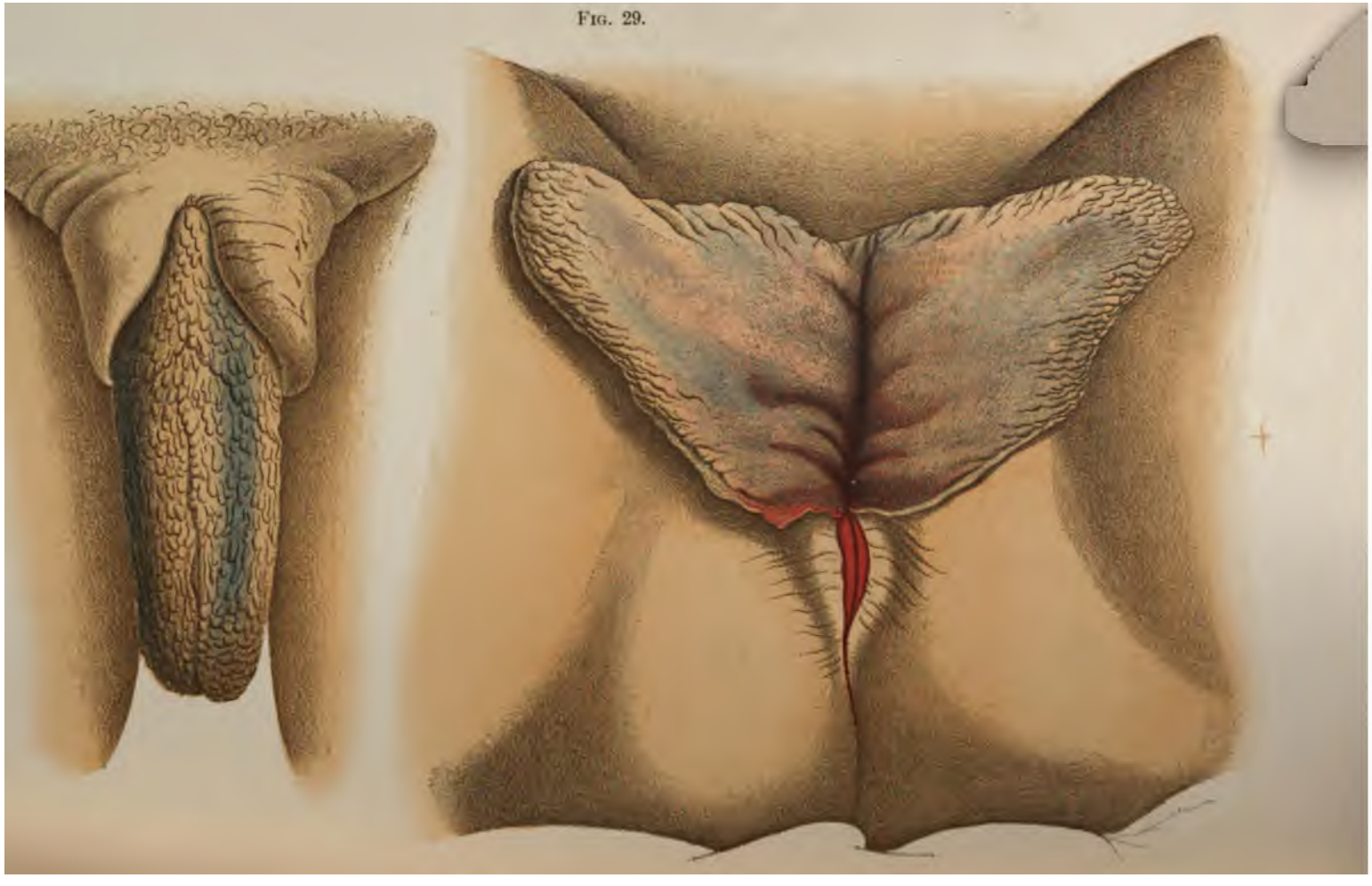

minora protrude between them; and when by childbirth or age the labia majora become flaccid and gape, the labia minora, the entrance to the vagina, and even part of that canal itself, become visible.

The structure of the labia majora is similar to that of the mons Veneris, but presents some peculiar features. Immediately under the skin forming the outer surface is found a layer of unstriped muscular fibres, which has been called *woman's dartos*. Under the dartos is found a layer of adipose and connective tissue, and under that, again, a pear-shaped sac called *Broca's pouch*, or the pudendal sac, attached with its mouth to the external inguinal ring, and extending with its broad part to the perineum, with the superficial fascia of which it coalesces. This pouch is composed of elastic fibres, and contains connective tissue and fat. Occasionally the prolongation of the peritoneum called the *canal of Nuck*, which accompanies the round ligament of the uterus, is found in it.

Function.—The labia majora protect the deeper parts, lead the male organ to them, and serve as buffers during coition.

The Labia Minora (small lips) or *Nymphæ.*—These are two small folds of skin (Fig. 28, 3) of the same dark color as the outside of the labia majora and the fourchette. They present a triangular surface when cut at right angles, having an outer and an inner free surface and a lower edge. At the anterior end they separate into two layers, the lower layer fastening itself to the lower surface of the glans clitoridis, forming its *frenulum*, and the upper passing above the clitoris, forming its *prepuce*. The extension backward of the labia minora varies very much. In some women they go back to the middle line, so as to form a complete ring inside of that formed by the labia majora. In others they do not even reach the level of the meatus urinarius. In most women they extend back about halfway between the clitoris and the posterior commissure. At the base of the inside is a more or less well-marked whitish line, which forms the limit between the skin and the mucous membrane. Their length from the base to the free edge varies likewise very much. In all the women of the Bushmen in South Africa and in some of the Hottentot women they hang halfway down to the knees, forming the so-called *Hottentot apron* (Fig. 29).

The labia minora are covered with several layers of epidermic cells. Beneath the epidermis they are composed of connective tissue, elastic fibres, and smooth muscular fibres, and contain large venous plexuses. They have no hairs nor fat, but numerous sebaceous glands and papillæ containing bulb-shaped terminal organs of nerves.

Function.—Their physiological significance seems to be to ensure more perfect adaptation and to act as an irritant for the nerves of the male member at the same time that their own nerves are acted on.

The Clitoris.—This corresponds to the penis in the male, but the urethra and the corpus spongiosum are separated from it. It is a

small cylindrical body about an inch long, placed in the median line, below the anterior commissure, and running in an antero-posterior direction. It is divided into the glans, the body, and the crura. The glans (Fig. 28, 4) is a roundish or pointed tubercle which forms the end of the clitoris. It is the only part of it that is visible, and even that in many women only on pulling the prepuce back. It is covered with mucous membrane, and has a prepuce and frenulum formed by the labia minora. The body (Fig. 28, 14) is surrounded by a fibrous sheath, and consists of two *corpora cavernosa* separated by an incomplete *pectiniform septum*. These corpora cavernosa consist of fibrous trabeculæ, elastic fibres, unstriped muscular fibres, and venous plexuses, with numerous anastomoses. The body is attached to the anterior surface of the symphysis pubis by the *suspensory ligament*. Arrived at the pubic arch, the body separates into two *crura* (Fig. 30), small fibrous cylinders attached to the rami of the pubes

FIG. 30.

Front View of the Perineal Septum, showing entire clitoris: 1, glans; 2, suspensory ligament; 3, crura of clitoris; 4, subpubic ligament; 5, dorsal vein of clitoris; 6, perineal septum (Savage's name for the deep perineal fascia or triangular ligament); 7, superficial transverse muscle; *u*, meatus urinarius; *v*, vagina; *P*, site of perineal body (Savage).

and the ischium. They are covered by the erector clitoridis muscle, which has its origin on the tuberosity of the ischium and is inserted on the crura, where they unite.

Blood-vessels.—The clitoris is an erectile organ, with helicine (spiral) arteries and numerous anastomosing veins. It receives the two end branches of the internal pudic artery, the *dorsal artery*, running on the upper surface, and *the artery of the corpus cavernosum* in the depth of that body. The veins go to the dorsal vein, running in the middle line between the two arteries, and ending in the pudic plexus,

which surrounds the upper part of the urethra. Those of the glans communicate with the bulbus vaginæ.

The *lymphatics* go to the superficial inguinal glands.

Nerves.—The clitoris has a rich nerve-supply (Fig. 31) from the *dorsal nerve* of the clitoris, a branch of the pudic nerve, and from the sympathetic, which form a kind of nervous sheath round the glans, with a peculiar kind of end-bulbs called *genital corpuscles.*

Function.—The clitoris is the chief seat of sexual excitement in women, and therefore often the object of masturbation. During coition it is enlarged, arched, and the glans is pressed against the dorsum penis.

The vestibule (Fig. 28, 6) is the triangular space between the clitoris, the labia minora, and the entrance to the vagina. It corresponds to the urogenital sinus of the embryo. In the middle line we have the *meatus urinarius*, which in most women forms a small isosceles triangle, with the base turned back toward the vaginal entrance, from which it is about a quarter of an inch distant, while the distance from the clitoris is about three times as long. On either side of this opening, just inside of the labia minora, is a deep blind recess (Fig. 28, 12). As these recesses are always plainly visible, and the urethral opening sometimes does not appear, the former become valuable landmarks in catheterization by eyesight. By placing the catheter just midway between the two blind sacs we cannot miss the urethra. In catheterization under cover the tip of the forefinger is introduced into the vagina, the bulb toward the urethra; the catheter is slid along the median line of the finger until it reaches the vestibule, and then raised a quarter of an inch.

There are many other smaller depressions, both in the recesses and in other parts of the vestibule, which are the openings of compound racemose glands (*glandulæ vestibulares minores*) that secrete a mucous fluid. Sebaceous glands are absent.

The *vestibulo-vaginal bulbs* (Fig. 32) are two leech-shaped organs, one on either side of the vestibule and the entrance to the vagina. Together they are equivalent to the bulb of the urethra in the male. The posterior end is round, and reaches back toward the posterior part of the vaginal orifice, where it is in contact with the vulvo-vaginal gland, and partly covers it. The anterior end is thinner, and nearly reaches the clitoris. It lies under the mucous membrane and the superficial fascia of the perineum, and inside of the sphincter vaginæ muscle. It consists of a fibrous sheath, and inside of that numerous veins from the internal pudic, complicated venous plexuses, some nerves, mostly belonging to the sympathetic system, unstriped muscular fibres, and connective tissue. The veins have numerous communications with those of the surrounding parts. Near the anterior end of the bulbs they go from one side to another, uniting the two

both behind and in front of the meatus urinarius, forming the *pars intermedia*, and from here they communicate with the corpora cavernosa of the clitoris.

The fossa navicularis is that part of the vulva situated between the vaginal entrance in front and the fourchette behind, and limited on the sides by the labia majora and above by the perineal body. It

FIG. 32.

Front View of the External Erectile Organs: *a*, vestibulo-vaginal bulb; *b*, sphincter vaginæ muscle; *ce*, pars intermedia; *f*, glans clitoridis; *g*, connecting veins; *h*, dorsal vein of the clitoris; *k*, veins passing behind the pubes; *l*, obturator vein (Kobelt).
The bulbs are over-distended with injection-fluid and reach too far back.

does not exist as a hollow when the labia majora are in contact. It is first formed, and gets its boat-shape when they are separated from each other. On stretching them from side to side we see the posterior commissure advance until it reaches the level of the posterior border of the entrance to the vagina. Thus a fold and a hollow are formed. The fold is the fourchette; the hollow is the fossa navicularis.

In virgins the fourchette projects a little forward, even without stretching, but in women who have had frequent intercourse it becomes so lax that the projection is lost or much diminished. During childbirth it is often torn. The lining membrane of this fossa seems to make a transition from skin to mucous membrane.

Function.—The vestibule and fossa navicularis form together one cavity, which, lying deeper (*i. e.* higher up in the erect posture) than the surroundings, and being coniform, in connection with the larger space formed by the labia majora, lead the entering member of copulation to the entrance of the vagina.

The vulvo-vaginal glands, or Bartholin's glands (Fig. 33, *b*), are two small oval bodies, of the size of a bean to that of an almond, situated one on either side of the entrance to the vagina close up to the posterior end of the vestibulo-vaginal bulb, in front of the superficial

Fig. 31.

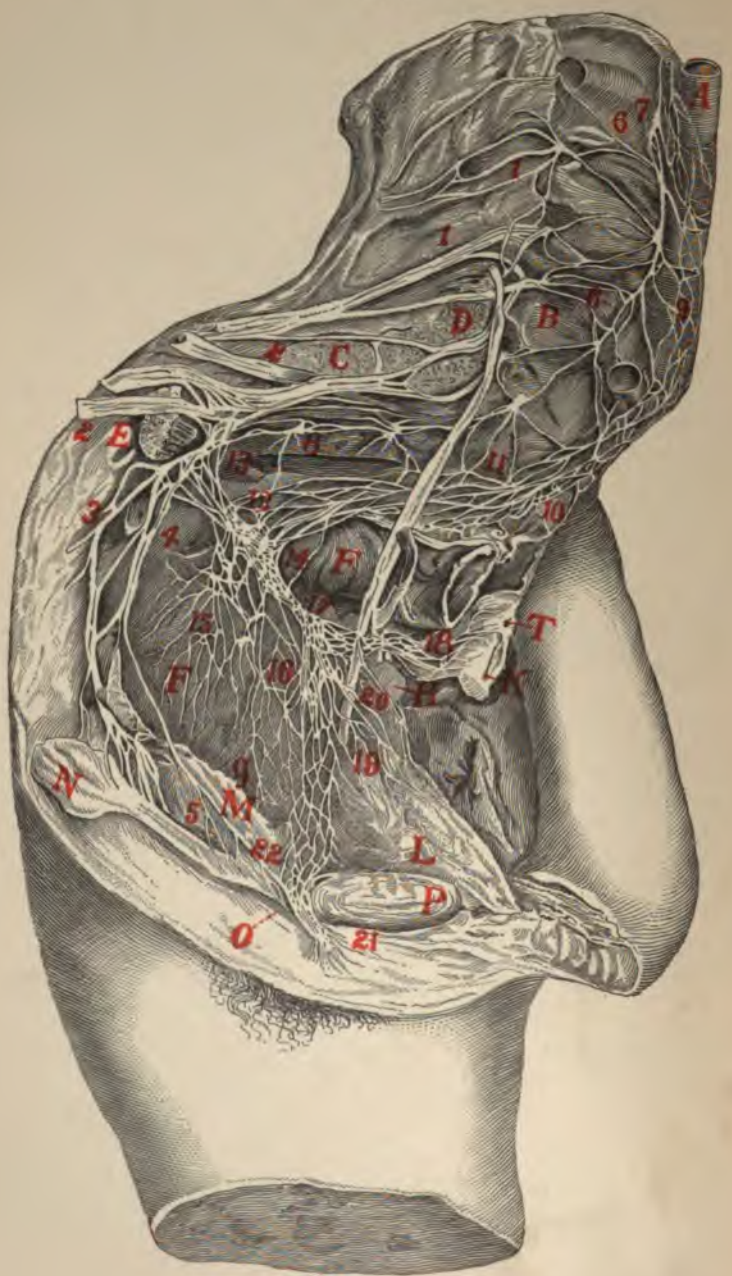
A
6
7
1
1
D
B
6
9
2
C
2
E
13
8
11
12
3
10
4
14
F
17
15
18
T
F
16
20
H
K
19
N
9
M
5
22
L
P
O
21

The Nerves of the Pelvis: A, abdominal aorta; B, lumbar vertebræ with intervertebral disks; C, the right portion of the sacrum sawn after removal of os innominatum; D, ureter; E, pyriformis muscle cut at its exit from the pelvic cavity; F, the curve of the rectum, corresponding to the anterior surface of the sacrum; H, virginal uterus feebly developed; K, right ovary displaced somewhat upward: L, bladder; M, levator ani muscle, cut in part: N, ischio-cavernosus muscle; O, corpus cavernosum clitoridis, joining on the other side the clitoris, covered with nerve-filaments; P, symphysis pubis (the whole body being inclined forward, it has become horizontal); T, fimbriated end of Fallopian tube; 1, *Lumbar nerves*, passing out of the intervertebral foramina to form the *lumbar plexus;* the lower lumbar and the upper sacral nerves joining to form the *sacral plexus* in front of the pyriformis muscle; 3, gluteal nerves cut; the *pudic nerve* springing by several roots from the plexus formed by the lower sacral nerves; 5, fine twigs passing from the pudic nerve to the ischio-cavernosus muscle; the main trunk goes under the symphysis, and ends as the *dorsal nerve of the clitoris* (21); 6, branches of communication which carry sympathetic twigs to the spinal nerves and spinal twigs to the hypogastric plexus of the sympathetic; 7, principal trunk of the *sympathetic* in front of the lumbar vertebræ; 8, continuation of the sympathetic in front of the sacrum; 9, *aortic plexus;* 10, *hemorrhoidal plexus*, following the arteries of the same name; 11, *superior hypogastric plexus, or ilio-hypogastric plexus*, which receives many spinal and sympathetic branches; 12, *inferior hypogastric plexus*, communicating with 13, *anterior sacral plexus*, made up of spinal and sympathetic branches; 14, from the many ganglia placed in this plexus it has a network appearance; 15, inferior rectal twigs which pass down even to the sphincter, where they form a network covered by the levator ani; 16, *vaginal plexus;* 17, that part of the inferior hypogastric plexus in the shape of a fine network at the upper end of the vagina gives branches to the bladder, the Fallopian tube, and the clitoris: 18, nerve-twigs which run on the side wall of the uterus (giving branches to it) upward to the Fallopian tube and ovary, where they join the nerves following the ovarian artery, which correspond to the spermatic plexus in man; 19, vesical nerves; 20, *uterine plexus;* 21, *dorsal nerve of clitoris*, which joins with the *cavernous plexus of the clitoris* from the sympathetic to the glans clitoridis (Rydinger).

transversus perinei muscle, and between the posterior third of the side of the vaginal entrance and the erector clitoridis muscle. They lie between the two layers of the deep perineal fascia, or sometimes under (*i. e.*, above in the erect posture) the deep layer.[1] They are compound racemose glands, secreting a mucous fluid, just like the smaller glands of the vestibule, and are sometimes called *glandulæ vestibulares majores*. Their excretory duct opens with a minute aperture just in front and outside of the hymen, on the inside of the labia majora, or labia minora if these extend so far back. They contribute to the lubrication of the vulva, especially when pressed upon by the surrounding muscles during sexual excitement.

FIG. 33.

Vulvo-vaginal Gland. The labium majus and minus, the sphincter vaginæ muscle, and the bulb have been partly removed on the right side in order to expose the gland: *AA'*, section of labium majus and minus; *B*, gland; *C*, excretory duct; *C'*, stylet introduced into the duct; *D*, glandular end of duct; *E*, free end of duct; *F*, section of bulb; *G*, ascending ramus of ischium (Huguier).

In the erect posture the vulva is hidden between the thighs. When not artificially spread out, the two lateral halves are in contact in the normal adult woman.

The vulva receives its *arteries* from the superficial perineal branch of the internal pudic and the external pudic arteries coming from the femoral. The *veins* accompany the arteries. On account of the free communications between themselves and with those of the pelvis even a small wound of the vulva, especially when during pregnancy they swell, may cause dangerous or even fatal venous hemorrhage. The *lymphatics* open into the superficial inguinal glands, which are in communication with the deep inguinal glands and external iliac glands. The *nerves* come from the superficial perineal nerve, which is a branch of the pudic, the inferior pudendal nerve, which is a branch of the small sciatic nerve, and from the pelvic, or inferior hypogastric, plexus of the sympathetic nerve.

Special features of the vessels and nerves of the clitoris and the bulbs of the vestibule have been treated under the descriptions of those organs.

THE VAGINA.

Until within a few years all descriptions and drawings of the vagina gave a very erroneous idea of this organ. It is a slit in the pelvic floor (Fig. 34, *h*), having a slanting direction from above and

[1] Ambrose L. Ranney found in every case Bartholin's glands lying posterior to triangular ligament ("The Female Perineum," *N. Y. Med. Jour.*, July–August, 1882, vol. xxxvi. p. 45).

behind downward and forward, at an angle of 60° with the horizon, situated between the bladder and the urethra in front and the rectum

FIG. 34.

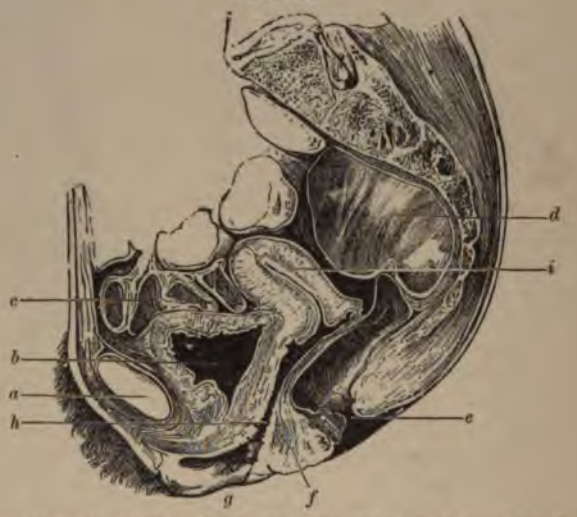

Sagittal Section of Pelvis (Waldeyer): *a*, symphysis pubis; *b*, bladder; *c*, small intestine; *d*, large intestine; *e*, anus; *f*, perineal body; *g*, vulva; *h*, vagina; *i*, uterus.

behind, and extending from the vulva below to the uterus above. It has a slight curve with the concavity forward, corresponding to the shape of the male member when in erection—a curve which is much increased during parturition, when the child rounds the symphysis pubis. When distended it has the shape of a truncated cone with the apex at the vulva and the base at the uterus; but when not distended it is folded together in such a way that the slit on a cross-section has somewhat the shape of the letter H, the anterior and posterior wall being in contact in the middle, and each side wall being folded against itself at the ends (Fig. 35, *va*). At the lower end it dips into the vulva, forming the hymen, in the same way as at the upper end the uterus dips into the vagina, forming the vaginal portion. At the upper end it forms a cup, adapting itself closely to the vaginal portion of the uterus, as does the cup to the ball of the toy called "bilboquet" or "cup and ball." The upper, broader end is called the *roof* or *fornix*, and in its adaptation to the vaginal portion it forms a shallow pouch in front and a much deeper behind, united by side pouches, forming an even transition from one to the other. The lower end, when we remove the hymen (which will be considered later), forms a circular opening, surrounded by the constrictor vaginæ muscle.

In olden times authors, just as the laity often do yet, comprised the whole parturient canal under the term "womb" or uterus. Now the profession has learned to distinguish the womb from the vagina, but the latter is yet in obstetrical and gynecological language frequently confounded with the vulva. We must, therefore, expressly call attention to the limits between these two parts of the parturient canal, and the difference between the two openings at its beginning. The entrance to the vulva is formed by the rima pudendi, a slit in the skin running in a straight line, in an antero-posterior direction; the entrance to the vagina lies an inch or two deeper, is circular, surrounded by mucous membrane and muscles, and is marked by the hymen or its remnants.

FIG. 35.

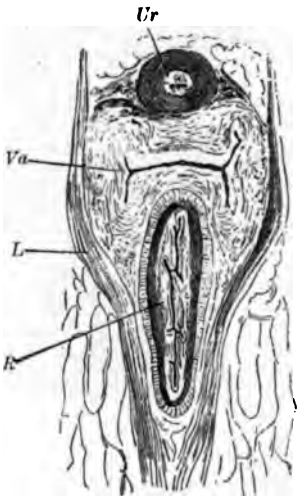

Horizontal Section of the Soft Parts in the Inferior Strait of the Pelvis (Henle): *Va*, vagina; *Ur*, urethra; *R*, rectum; *L*, levator ani.

The size of the vagina varies enormously in different individuals and different conditions. In the adult virgin the anterior wall is about 2 inches, the posterior about 2½ inches long, and the width near the upper end about 1½ inches. By coition, and especially childbirth, these dimensions are much increased. During copulation it has the size of the body that extends it. During pregnancy great proliferation of tissue, swelling of veins, and serous infiltration take place, so that at the time of delivery the canal not only is wide enough to let the child pass, but becomes so elongated that it can accompany the child far beyond the limits of the outlet of the bony pelvis.

The vagina is composed (Figs. 36, 37) of an outer sheath of connective tissue, containing fat, a muscular layer with longitudinal and transverse fibres, and a mucous membrane with flat epithelium. The muscular fibres can be followed to the posterior surface of the pubic bone and the anterior surface of the sacro-iliac articulation (Rouget). In the perineal region the muscle-fibres reach the bone between the two layers of the triangular ligament. The mucous membrane forms on the anterior wall a longitudinal ridge in or near the median line, from which folds, so-called *rugæ*, go out to the sides, like the teeth of a comb; a similar but less distinct formation is found on the posterior wall. They are called the *anterior* and *posterior columns*. The anterior often ends below in a round protuberance, called the *tubercle of the vagina*, which is situated immediately behind the meatus urinarius. Often the anterior column is divided by a lon-

gitudinal furrow into two halves. The rugæ are covered with microscopical papillæ. The columns and the rugæ disappear in the upper part of the vagina. They are organs of sexual excitement, and con-

FIG. 36. FIG. 37.

FIG. 36.—Longitudinal Section of the Posterior Wall of the Vagina of a girl twenty-four years old.

FIG. 37.—Transverse Section of the Same (Breisky): *a*, mucous membrane; *b*, muscular layer, with *α*, circular, and *B*, longitudinal fibres; *c*, fibrous layer containing adipose tissue.

tribute probably to the enlargement of the vagina during pregnancy and childbirth. After the latter they are much less prominent or disappear entirely. The presence of *glands* in the mucous membrane is disputed.[1]

The vagina has a rich vascular supply. The *arteries* (Fig. 38) come from the vaginal, the uterine, the vesical, and the internal pudic, which all are branches of the anterior division of the internal iliac.

[1] In a woman in the fifth month of pregnancy I have seen the whole vagina red and full of openings like a tonsil, out of which a solid yellowish discharge could be pressed. I do not see what these openings could have been except entrances to glandular follicles.

FIG. 38.

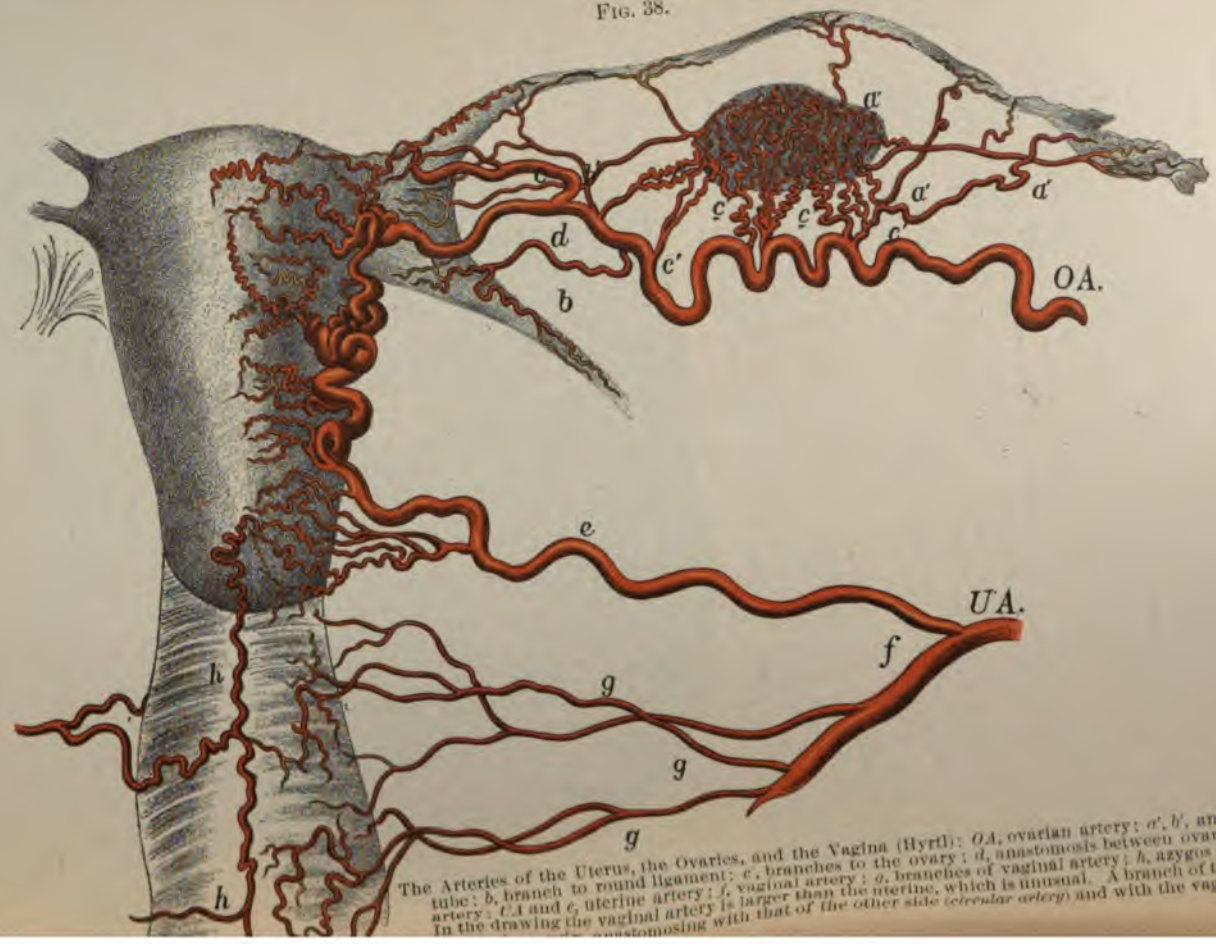

The Arteries of the Uterus, the Ovaries, and the Vagina (Hyrtl): *OA*, ovarian artery; *a'*, *b'*, and *c*, branches to tube; *b*, branch to round ligament; *c*, branches to the ovary; *d*, anastomosis between ovarian and uterine artery; *UA* and *e*, uterine artery; *f*, vaginal artery; *g*, branches of vaginal artery; *h*, azygos artery of vagina. In the drawing the vaginal artery is larger than the uterine, which is unusual. A branch of the uterine artery anastomosing with that of the other side (*circular artery*) and with the vaginal arteries.

The *veins* form a dense network (Fig. 39), and communicate with those of the vulva, the bladder, the rectum, the uterus, and the broad ligament. Finally, the blood is carried to the internal iliac veins.

The *lymphatics* from the lower fourth go to the superficial inguinal

FIG. 39.

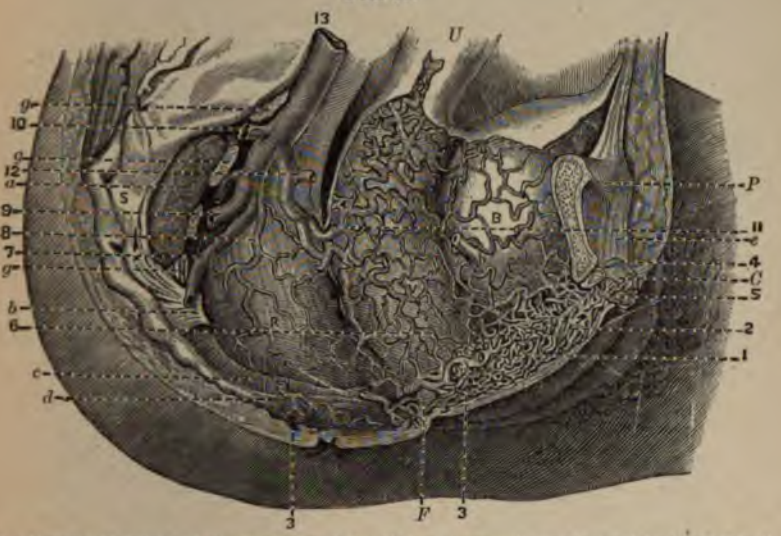

The Venous Plexuses of the Vagina and the Vulva, as seen in mesial section (Savage): *B*, bladder partially inflated; *b*, ureter; *V*, vagina; *P*, section of pubes; *R*, rectum; *C*, clitoris; 1, bulb; 2, its urethral process; 3, lower efferent veins; 4, dorsal vein of the clitoris; 5, urethral venous plexus; 6, commencement of vaginal venous plexus; 7, 8, 9, 10, sciatic and gluteal veins; 11, uterine veins; 12, obturator vein; 13, internal iliac vein; *a*, pyriformis muscle; *b*, greater sacro-sciatic ligament; *c*, levator ani and coccygeus muscles; *d*, os coccygis; *e*, suspensory ligament of clitoris; *F*, vulvo-vaginal gland; *ggg* roots of sacral plexus of nerves.

glands, like those from the vulva; those from the upper three-fourths go to the internal iliac glands, and perhaps the obturator glands, which again communicate with the inguinal glands.

The *nerves* (Fig. 31) come from the sympathetic, and form a *vaginal plexus* on either side of the vagina, communicating with the inferior hypogastric. Their final fibrillæ terminate in end-bulbs.

Function.—The vagina has a double physiological function. During copulation it receives the penis, and during parturition it helps move the child forward along the curve of Carus. The vagina can become distended independently of the introduction of any distending solid body or air-pressure, as exercised when the patient is examined in the knee-chest or Sims's position. This must be due to the contraction of the muscular fibres that are attached to the pelvic bones. I have often found this ballooning during examinations with a single

finger with the patient lying on her back, and in nulliparæ with a tight vaginal entrance. The same applies to the rectum.

The Hymen.

The hymen begins, as we have seen in the history of the development, as a protuberance from the posterior wall of the vagina. It is a fold of the mucous membrane containing elastic fibres, blood-vessels, lymph-vessels, nerves, and sometimes smooth muscular fibres. It closes the vagina more or less completely, and varies much in shape, but in most cases it is more developed behind than in front. The most common shape, especially in childhood, is that of a strip of tissue bent so as to form two lateral halves touching one another in a straight middle line (Fig. 40). In other cases it forms a ring with a

Fig. 40.

Hymen with Linear Opening (Tardieu).

Fig. 41.

Annular Hymen (Tardieu).

round opening (Fig. 41). In others, again, it has the shape of a crescent (Fig. 42). Often the border is indented (Fig. 43), a form that is easily distinguished from a lacerated hymen by the softness of the tissues, the absence of cicatrices, the round contour of the tongues, and, above all, by the decided resistance that is felt in trying to enter the finger. Sometimes the hymen is only represented by a low circular or crescentic ridge. The upper surface shows a continuation of the rugæ of the vaginæ, of which it only forms the lowest, thinned part, somewhat in the manner of the relation between the fourchette and the posterior end of the labia majora.

The hymen is, as a rule, torn by the first successful coition, into two or three, rarely a greater number of flaps, but there is no loss of substance. By putting the flaps in contact we can reproduce its original shape. In childbirth, on the contrary, it suffers so much

that only three or four roundish prominences are left of it, the so-called *carunculæ myrtiformes.*

In a strictly intact vulva considerable resistance is felt, and pain is caused by the examining finger, be it at the opening of the hymen or at its base, where it joins the rest of the vagina. An easy accessi-

FIG. 42.

Crescent-shaped Hymen (Tardieu).

FIG. 43.

Indented Hymen.

bility of the vagina without laceration of the hymen is due to a gradual dilatation by a comparatively small body. It must be borne in mind that this not always means masturbation. It may as well be the result of careful gynecological treatment, while a careless examination may rupture the membrane, producing a result similar to that of coition.

THE UTERUS.

The uterus (Fig. 44) is a hollow body with thick muscular walls situated between the vagina below and the small intestines above, the bladder in front, and the rectum behind. It has somewhat the shape of a flattened pear, and may be divided into two parts, called the *neck*, or *cervix* and the *body*, or *corpus*. A subdivision of the neck is the *vaginal portion* (Fig. 44, *A*, *a*), which dips down into the vagina; and a subdivision of the body is the *fundus* (Fig. 44, *C*, *f*), which lies above the entrance of the Fallopian tubes. The neck is cylindrical or rather barrel-shaped, being thicker in the middle than at the ends, and the line of demarkation between it and the body is marked outside, on its anterior surface, by the fold formed by the peritoneum when from the uterus it passes over on the bladder.

The *vaginal portion* or *infravaginal part of the cervix* forms a rounded cone nearly one-half inch high, on the top of which is found a transverse slit measuring about one-quarter of an inch from side to side, and called the *os externum*, *os tincæ* (*i. e.* the mouth of a tench), or simply the *os uteri*. If we imagine this opening prolonged so as to divide the cervical portion into two halves, the anterior is called the *anterior lip*, and the posterior the *posterior lip*—a condition that often is produced by childbirth, but then is pathological.

FIG. 44.

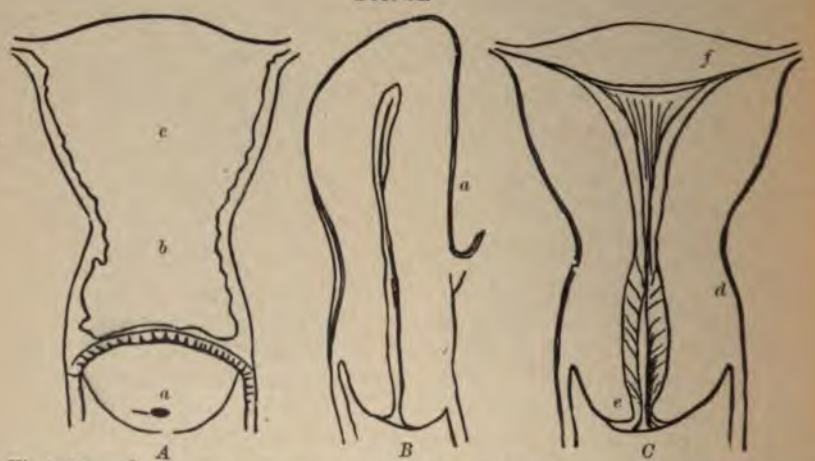

Virgin Uterus, natural size (Sappey): *A*, front view: the appendages and the vagina are cut away; *a*, vaginal portion of cervix; *b*, isthmus; *c*, body.
B, the same in vertical mesial section: *a*, anterior surface; the letter is placed a little above the bottom of the vesico-uterine pouch.
C, the same with cavity exposed by coronal section: *e*, os externum; *d*, os internum; *f*, fundus, the letter placed just above uterine opening of Fallopian tube.

The anterior lip dips lower down than the posterior, but the pouch formed by the vagina being much deeper behind than in front (Fig. 44) the posterior lip goes much higher up, so that it is longer than the anterior. The vaginal portion is covered with a smooth mucous membrane with flat epithelium, like that of the vagina.

The supravaginal part of the neck is about $\frac{3}{4}$ inch long, and is bound with rather loose connective tissue to the bladder in front, and on the sides to the mass forming the base of the broad ligaments of the uterus, and called the parametrium. Behind, it is free, being separated from the rectum by a part of the peritoneal cavity called Douglas's pouch.

The body of the uterus, in the more restricted sense of the word, is triangular. It forms a flattened truncated cone, with the end turned down to the cervix and the base up to the fundus. The sides

are a little convex (Fig. 44, *A*). The anterior surface is convex from side to side, and straight or slightly concave from above downward. The posterior surface is strongly convex in all directions. The fundus is moderately convex from side to side, and much more so from the anterior to the posterior surface (Fig. 44, B and C).

The interior of the womb contains a cavity (Fig. 44, B and C), the anterior and posterior walls of which are in contact. It is 2 inches long in the nulliparous woman, and is divided into three parts, the *cervical canal*, the *isthmus*, and the *cavity of the body*. The *cervical canal* is about 1 inch long, is spindle-shaped, and on the anterior and posterior wall there is found a longitudinal ridge from which branches go outward and upward, separated by deep pouches. The whole formation is called *arbor vitæ*, *palmæ plicatæ*, or *plicæ palmatæ*. The *isthmus*, or *os internum*, is the narrowest part of the cavity, nearly cylindrical, about $\frac{1}{4}$ inch long and $\frac{1}{8}$ inch in diameter. The median ridge of the *arbor vitæ* extends to its upper end. The cavity of the body is triangular, with curved sides bulging into the cavity and smooth surfaces. At the two upper angles are found the uterine apertures of the Fallopian tubes.

The wall is about $\frac{3}{8}$ of an inch thick in the thickest parts, which are the middle of the edges of the body, the middle of the fundus, and the middle of the cervix. It is thinnest at the entrances to the Fallopian tubes and at the external os.

The size of the womb increases somewhat by sexual intercourse, and still more by childbirth. The length measures in virgins 2 to $2\frac{1}{2}$ inches, in nulliparæ 2 to $2\frac{3}{4}$ inches, in multiparæ $2\frac{1}{4}$ to 3 inches. The width on the level of the Fallopian tubes, the broadest part, is in virgins $1\frac{1}{4}$ to $1\frac{3}{4}$, in nulliparæ the same, in multiparæ $1\frac{1}{2}$ to 2 inches. The thickness is about the same in all three classes, varying from $\frac{7}{8}$ of an inch to $1\frac{1}{4}$ inches.

The cervix is about $1\frac{1}{4}$ inches from side to side in the middle, and a little less at the ends.

The body is only a little longer than the neck in nulliparæ; in those who have borne children it becomes three-fifths or two-thirds of the length of the whole organ.

The wall is composed of three layers—a serous, a muscular, and a mucous. The serous coat is formed by the peritoneum, and does not cover the anterior surface and the sides of the cervix.

The muscular part of the wall may be divided into three layers, which become distinct during pregnancy: an outer longitudinal layer, which sends prolongations into the round and the ovarian ligaments, the tubes, and the sacro-uterine ligaments; a middle layer of interlacing longitudinal and transverse fibres, which is in connection with the muscular coat of the vagina; and an internal transverse layer, which is especially developed in what was formerly the two horns, and near

the internal os, in which latter place it forms a sphincter. It enters also the folds of the plicæ palmatæ. The middle layer is the thickest and contains the vessels.

FIG. 45.

Vertical Section through the Mucous Membrane of the Human Uterus (Turner): *e*, columnar epithelium; the cilia are not represented; *g,g*, utricular glands; *ct*, interglandular connective tissue; *v,v*, blood-vessels; *mm*, muscular layer.

The mucous membrane (Fig. 45) lines the whole cavity. In the body it is thin and intimately connected with the muscular layer, bundles of the muscles and connective tissue extending from one to the other. When fresh it is pink. It consists of fine threads of connective tissue and round or oblong cells (Figs. 46 and 47), and is perforated by numerous tubes, composed of a basement membrane and a layer of ciliated columnar epithelium, and called the *utricular glands*. They have a general direction parallel to one another, but are tortuous, and have often two or three branches in the deeper parts of the mucous membrane.[1]

In the cervix the mucous membrane is thicker, is composed of

[1] According to Dr. Arthur W. Johnstone of Danville, Ky., the mucous membrane is an adenoid tissue, like that of the tonsils, the thyroid body, the spleen, the thymus, the lymphatic glands, and the lymph-tissues in the wall of the alimentary canal. The cells originate as granules in the fibres. They are only found between the age of puberty and the climacteric (*Trans. Brit. Med. Soc.*, June 23, 1886).

fibrous connective tissue without adenoid structure, has racemose glands, and is separated from the muscular layer by a distinct submucous layer of looser connective tissue. The epithelium is columnar and ciliated on the free surface of the body,[1] in the utricular glands, and on the edges of the branches of the arbor vitæ. In the depressions between them it is goblet-shaped, without cilia. In the glands of the cervix it is cuboidal, without cilia.

FIG. 46.

Section of the Mucous Membrane of the Uterus parallel to the surface, enlarged 150 times (Henle): 1, 2, 3, glands (the epithelium has fallen out from 2); 4, blood-vessel.

Shape and Position.—Opinions as to the normal shape and position of the womb differ so much that it has almost become a confession of faith to say anything about it; but, since I have made gynecological examinations for the last twenty years, and have paid special attention for the last ten years to what can be seen and felt in regard to the anatomy of the genitals, I think I may be able to express an opinion that is not altogether without foundation in facts, as are so many descriptions and drawings given of these parts. We have five sources of information—viz. dissections of dead bodies, sections of frozen bodies, bimanual palpation of living women, laparotomies, and the development of the fetus, all of which methods have some advantages and some drawbacks; but by combining them all I think we get a pretty accurate idea of the true relations. After death, the body lying on its back, the whole pelvic floor, especially in multiparæ, is apt to sink, so that the fundus of the uterus comes to lie considerably deeper than in the living woman,[2] and at the same time it falls back toward the sacrum. Thus all descriptions based on autopsies and sections of frozen bodies become unreliable. On the

[1] Having stated elsewhere that the epithelium of the body was columnar without cilia—a view shared by such an authority on the microscopical anatomy of the female genitals as De Sinéty (*Manuel pratique de Gynécologie*, Paris, 1879, p. 239)—and having been told that I was wrong, I addressed Dr. Johnstone on the subject, who recently has made a special study of the mucous membrane of the uterus. He answered: "The cause of the difference of opinion is that the epithelium on the free surface of the corporeal endometrium is shed every twenty-eight days, and the different observers have each described a different stage of its regeneration. I have seen it in all conditions, from a simple round cell up to a fully-developed columnar epithelium, and in a few instances have seen what looked like cilia. But before they become perfect the menstrual flow strips off the epithelial coat, and the cycle repeats itself."

[2] According to Sappey, it should lie ¾ inch to 1 inch below the superior strait.

other hand, examinations of the living do not admit of the same degree of accuracy as those of dead bodies.

FIG. 47.

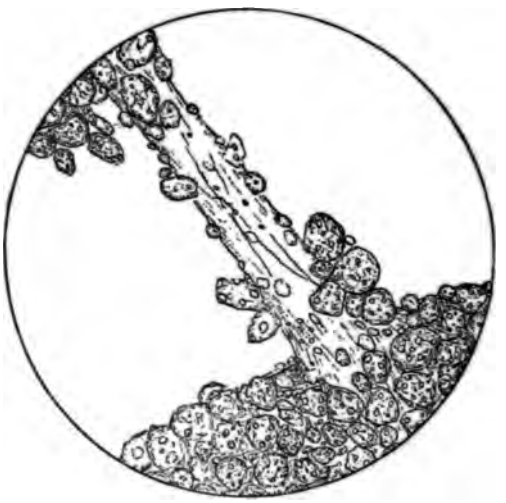

Fibre of Endometrium, showing different degrees of corpuscular development. Enlarged 3000 times (Johnstone).

The canal of the normal uterus is straight or slightly curved, with the concavity turned forward (Fig. 49), or S-shaped. The presence

FIG. 48.

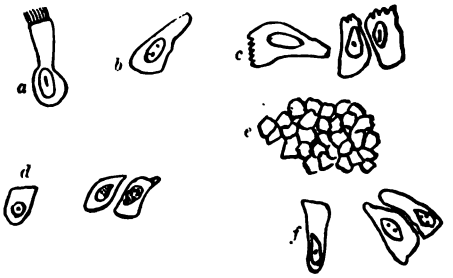

Epithelial Cells from the Uterus of a Woman sixty years old. From edge of a plica palmata: *a*, ciliated columnar cell (rare); *b*, plain columnar cell (the majority); *c*, large goblet cells. From the deepest part of the valley between two plicæ palmatæ: *d*, small goblet cells. From inner surface of body: *e*, front view; *f*, side view, columnar, non-ciliated; nucleus situated nearer lower or upper end, and containing one or two nucleoli.

of an angle opening anteriorly, or of a considerable curvature forward, is an abnormal condition called anteflexion, and constitutes, even if it does not give rise to other symptoms, a considerable hindrance to conception. Any kind of backward curvature constitutes the abnormal condition called retroflexion. The fundus reaches a little above

the brim of the pelvis (Fig. 50), and lies a little nearer to the right side than to the left. When the rectum and bladder are empty, the longitudinal axis of the womb forms a right or obtuse angle with that of the vagina. A full bladder will tilt the womb back and press it up against the sacrum, and a full rectum presses it forward toward the symphysis. The small intestines are regularly found in the

FIG. 49.

Mesial Section of the Pelvis of a Girl seventeen years old, half natural size (Kölliker): *ur*, ureter opening into bladder; *u*, vesical opening of urethra; *cl*, clitoris; *h*, hymen.

upper part of the recto-uterine excavation, not in the lowest, narrow part of it, Douglas's pouch. They are also found in the vesico-uterine excavation if the bladder contracts in such a way as to form a Y (Fig. 34), but not if it contracts by apposition of its anterior and posterior wall, in which case the womb and the bladder lie close up to each other (Fig. 49).

During pregnancy the uterus increases enormously in size, which is especially due to the formation of new muscular cells and enormous increase in size of the old ones.

After the menopause the organ shrinks, the cervical portion forms a small protuberance or disappears altogether, and the mucous membrane of the body loses nearly all its cells and consists of common connective tissue (Fig. 51).

FIG. 50.

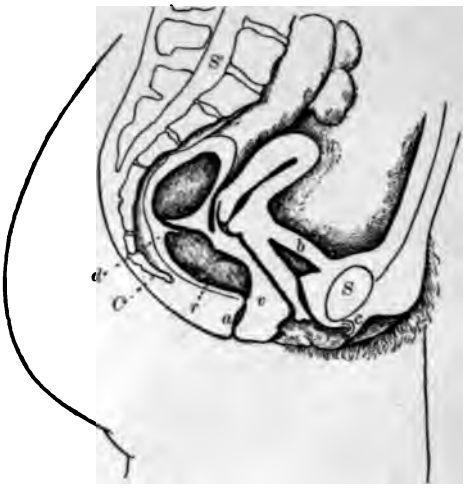

Diagram of a Supposed Mesial Section of the Pelvis of a living woman (Foster-Ranney): *a*, anal canal; *r*, rectum; *v*, vagina; *c*, clitoris; *b*, bladder when collapsed; *u*, uterus; *d*, valve of rectum (Houston); *S*, symphysis pubis; *S'*, sacrum; *C*, coccyx.

FIG. 51.

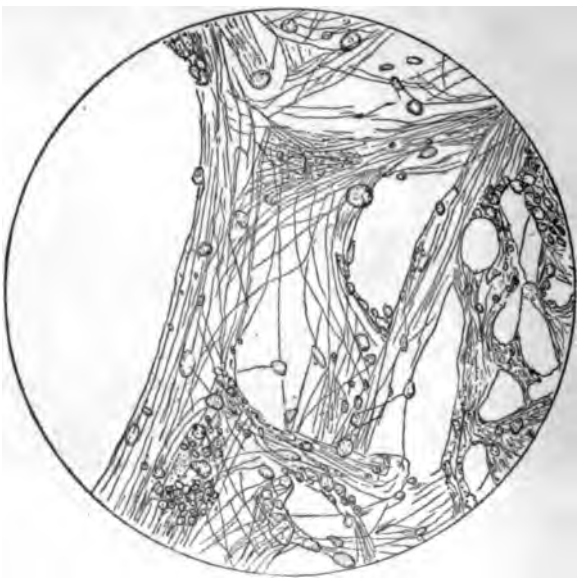

Endometrium of Woman sixty years old (Johnstone).

The Ligaments of the Uterus.—There are eight ligaments (Fig.

52) which contribute more or less to determine the position and shape of the uterus: the vesico-uterine in front, the sacro-uterine behind, the broad and the round at the sides.

FIG. 52.

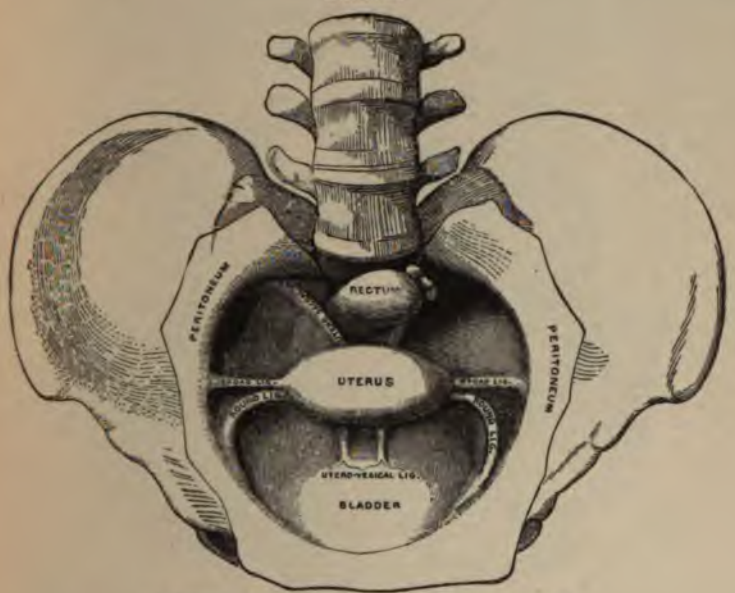

Diagram of the Ligaments of the Uterus (Hodge).

The *vesico-uterine ligaments* are two small semilunar folds, one on either side of the median line formed by the peritoneum, when from the bladder it passes over to the uterus, on the level of the internal os.

The *sacro-uterine ligaments* are much larger peritoneal folds, extending from the anterior surface of the second sacral vertebra to the uterus on a level with the os internum. Together they form an oval opening, with the narrow part turned toward the uterus. Their concave inner edge is turned inward toward the rectum (Fig. 53), and forms the upper border of Douglas's pouch. They contain unstriped muscle-fibres, a direct continuation of those of the womb, and have been called the *retractor muscles* of the uterus (Luschka). Besides, they contain loose and fibrous connective tissue. They form, together with the anterior vaginal wall, an elastic beam on which the uterus is suspended.[1] They prevent the uterus from being pulled down in the normal condition beyond the entrance to the vagina.

[1] Frank P. Foster, *Trans. Am. Gyn. Soc.*, 1881, vol. vi. p. 434.

Working together with the round ligaments, their shortening produces anteflexion.

The *broad ligaments* are two quadrangular folds of the peritoneum, one on either side, situated between the uterus and the pelvic wall, and forming a partition in the true pelvis between an anterior and a posterior pouch. The inner edge is attached to the edge of the uterus, the outer edge to the wall of the pelvis in a line extending

FIG. 53.

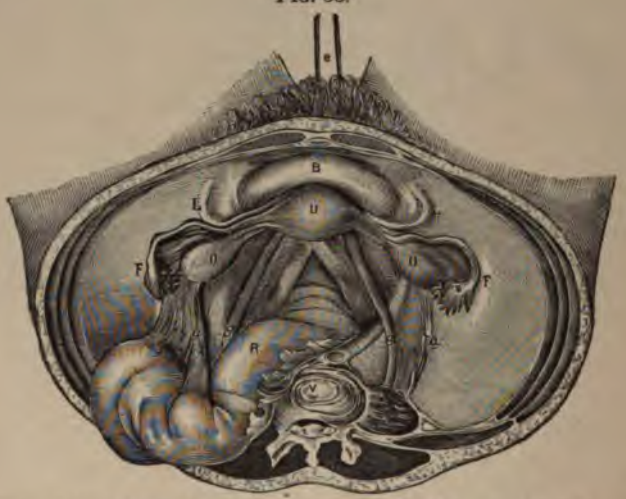

Superior View of the Pelvis and its Organs (Savage): *B*, bladder; *U*, uterus (drawn down by loop *c*); *F*, Fallopian tubes; *O*, ovaries; *L*, round ligaments; *g*, ureter; *a*, ovarian vessels, often prominent under their peritoneal covering.

from a point midway between the sacro-iliac articulation and the ilio-pectineal eminence, downward and backward, between the great sacro-sciatic notch and the obturator foramen, to the level of the spine of the ischium (Fig. 54). The upper edge is formed by the Fallopian tube inward and the infundibulo-pelvic ligament outward. The lower edge is attached to the mass of connective tissue lying to the side of the cervix, and called *parametrium* or *parametric connective tissue.* The upper edge is free; the three other edges are continuous with the peritoneal covering of the uterus, the sides and the floor of the pelvis. It is composed of an anterior and a posterior layer. The anterior layer covers the round ligament; the posterior layer contains an opening, in which the base of the ovary is inserted. Between these two layers lie loose connective tissue, unstriped muscular fibres, blood-vessels, lymphatics, and nerves. The muscular fibres are a continuation of the outer layer of the uterine muscular coat, and form

a kind of flat muscle (*platysma*—Savage) between the uterus, the ovaries, and the tubes, from which a bundle goes along the ovarian artery, up to the vertebral column, called the *superior round ligament* (Fig. 55, *LS*). This whole muscular expansion is capable of producing

FIG. 54.

The Right Wall of the Pelvis (Polk): *A*, internal iliac artery; *B*, uterine artery; *C*, ovarian artery; *D*, course of the ureter, projected on pelvic wall; *E*, line of pelvic attachment of the broad ligament of the uterus in a nullipara; *F*, line of attachment of the levator ani, marking the level of the base of the broad ligament.

a kind of erection of the internal genitals, and it is probably also instrumental in adapting the fimbriæ of the tube to the ovary during ovulation (Fig. 56).

During pregnancy the broad ligaments are dragged upward and backward by the uterus, so that at full term their base lies on a level with the ilio-pectineal line, and extends from the ilio-pectineal eminence to the sacro-iliac articulation.[1] The broad ligaments allow the uterus to be pushed or bent forward or backward to any extent; they allow also an excursion upward and downward of two inches in either direction, but they check the movement from side to side somewhat; and when the utero-sacral ligaments are cut or have lost their

[1] W. M. Polk, "Landmarks in the Operation of Gastro-elytrotomy," *N. Y. Med. Jour.*, May, 1882, vol. xxxv. pp. 449–454; as well as his "Observations upon the Anatomy of the Female Pelvis," *ibid.*, Dec., 1882, vol. xxxvi. pp. 561–569. These papers, based upon original investigation on the bodies of pregnant women, contain most valuable information not to be found anywhere else, to my knowledge.

elasticity, the broad ligaments, as well as the pelvic connective tissue, are put on the stretch by pulling the uterus down.

The *round ligaments* (Fig. 55, *LI*) are two strings, one on either side, springing from the anterior surface of the uterus immediately below and in front of the Fallopian tube, and going in a curve first upward

FIG. 55.

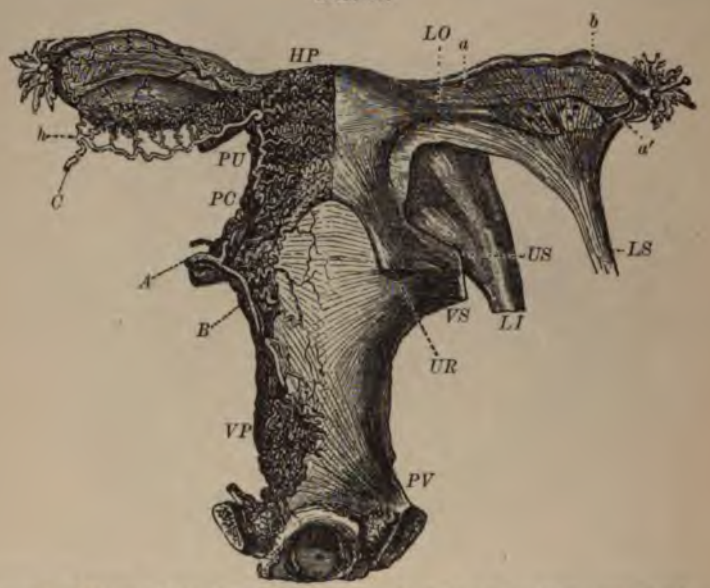

The vessels of the vagina and the internal genitals in their relation to the superficial muscular structures (Rouget). The specimen is seen from behind. Vascular system: *VP*, vaginal plexus; *PC*, cervical plexus; *PU*, uterine plexus; *HP*, helicine arteries of uterine body; *h*, helicine arteries of hilum of ovary. Muscular system: *VP*, insertion of the muscle-bundles of the vagina on the pubes; *VS*, bundles of the same muscular coat coming from the region of the sacro-iliac articulation; *US*, uterine muscle-bundles which accompany the preceding, and constitute to a great extent the posterior layer of the broad ligament; *UR*, recto-uterine or sacro-uterine ligaments; *LI*, inguinal or pubic round ligament, spreading over the whole anterior surface of the uterus; *LO*, ovarian ligament; *LS*, superior or lumbar round ligament, which accompanies and envelops the internal spermatic, or ovarian vessels; *a*, muscular bundles coming from the ovarian ligament (*LO*), spreading and interlacing with the bundles, *b*, coming from the superior or lumbar ligament (*LS*), in the interior of the ovary, and beyond in the ala vespertilionis, before they insert themselves on the tube and the fimbriæ; *a'*, bundles starting from the ovary, which, together with others coming directly from the superior ligament, form the *fimbria ovarica*.

and outward, then inward and forward, outside of the bladder, to the internal inguinal ring, then through the inguinal canal, following its lowest and outermost angle, and out through the external ring. Here it breaks up into different strands, ending in the mons Veneris, the symphysis pubis, and the upper end of the labium majus. Some strands are given off to the surrounding parts during the passage through the inguinal canal.

The ligament consists of fibrous connective tissue, unstriped muscular fibres from the uterus, and striated fibres coming from the transversalis muscle and the pubic spine. An artery from the deep epigastric runs through its centre and anastomoses with one from the uterus. The artery is accompanied by a vein. The genital branch of the genito-crural nerve lies in front of the ligament at the external ring. Other veins and nerves join it from below. At first it lies under the anterior layer of the broad ligament. When it leaves the broad ligament it has a peritoneal covering of its own, which, as a rule, stops at the internal ring in the adult. During fetal life the peritoneum forms a pouch which accompanies it through the inguinal canal,

FIG. 56.

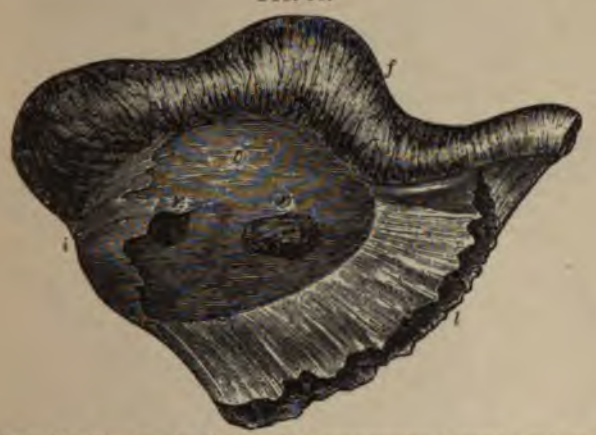

Tube and Ovary of a Woman who died during menstruation, natural size (Farre): *l*, broad ligament; *o*, ovary; *rr*, old corpora lutea; *f*, isthmus of tube; *i*, fimbriated end spread over ovary.

and is called the *canal of Nuck*, and corresponds to the processus vaginalis in the male. This pouch normally grows together, forming a fibrous string, but abnormally it may persist and give rise to female hydrocele, or be found as a sheath of the ligament in Alexander's operation. (See Retroflexion of Uterus.)

During pregnancy the round ligament becomes finger-thick. It is only found in women and the higher apes, who occasionally take the erect position. It contracts when stimulated by electricity like other muscles. Both ligaments being contracted at the same time they tilt the fundus uteri forward, and as they contract simultaneously with the abdominal muscles, they prevent retroversion from being produced by coughing, lifting, straining at stool, etc.[1]

[1] J. H. Kellogg of Battle Creek, Mich., *Trans. Am. Ass. Obstet. and Gyn.*, 1889, vol. ii. p. 266.

During copulation they produce probably a kind of suction, and by their intimate connection with the muscular platysma of the broad ligament, and working together with the superior round ligament, they cause erection of the inner genital organs. During labor they pull the fundus forward and downward, and thus give it the most favorable direction in relation to the superior strait.

The *arteries* of the uterus come from three sources: the uterine artery from the internal iliac; the ovarian from the aorta; and the insignificant artery of the round ligament from the epigastric. The uterine goes behind the peritoneum on the posterior wall of the pelvis, down into the parametrium, and forms a loop in front of the ureter, a short distance from the anterior lateral fornix of the vagina (Fig. 57). (Compare Fig. 54.) Hence it goes up between the two

FIG. 57.

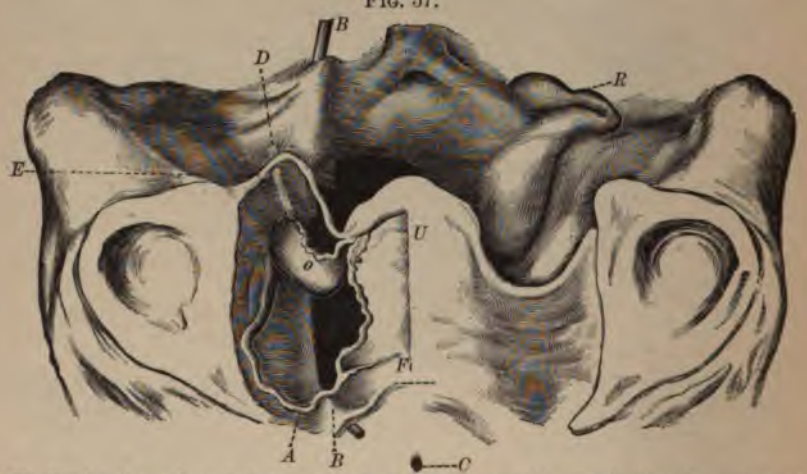

The Uterine Artery in its Relation to the Ureter: a photographic reproduction of a section of the pelvis, extending from the pectineal eminence above to the lesser sacro-sciatic foramen below (Polk). On the right side the broad ligament has been removed: *U*, uterus, right side freed of peritoneum: *O*, ovary; *C*, base of bladder showing urethral orifice, the organ having been cut away on a level with the utero-vesical peritoneal fold; the dotted line running across its upper edge corresponds to the utero-vaginal junction; above this, at *F*, we have the circular artery of the cervix; *A*, uterine artery; *BB*, ureter, with a probe passing through it; *D*, ovarian artery; *E*, round ligament, held up to show the ovary and vessels behind it; *R*, rectum.

layers of the broad ligament, following the edge of the uterus to the corner of the same, where it anastomoses with the ovarian artery. It sends numerous branches off at right angles to the uterus, where they anastomose with those from the other side (Fig. 38). At the level of the internal os such anastomosing branches in front and behind form the *circular artery*. The trunk has a very tortuous course, and the branches are wound like corkscrews, *helicine arteries* (Fig. 55, H. P.).

During pregnancy the uterine artery stays comparatively small, its calibre equalling that of the ureter, while the ovarian is much thicker.

The *uterine veins* form a network in the muscular coat, and open into a conglomeration of veins lying at the edges of the uterus. From the middle of this plexus the two uterine veins follow the uterine artery, and carry the blood to the internal iliac vein. At its upper end this plexus anastomoses with the branches of the ovarian

FIG. 58.

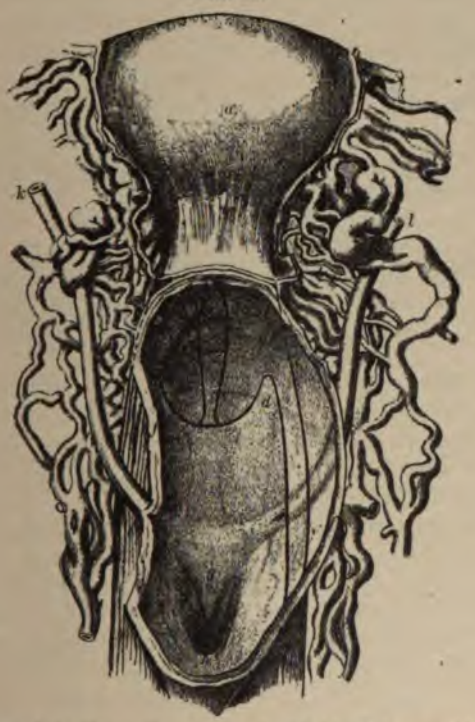

The Uterine Veins and the Ureter (Luschka). The bladder being considerably extended, it was cut off sufficiently to show the inner surface of its posterior wall where it is in contact with the uterus and the vagina. On the right side also part of the posterior wall of the bladder was removed in order to show the course of the ureter on the anterior wall of the vagina. Where the uterus and the vagina are concealed by the bladder their contours are marked with heavy black lines: *a*, anterior surface of uterus, showing how far it is covered with peritoneum when the bladder is full; *b*, portion of supravaginal part of cervix covered by the bladder; *c*, vaginal portion of uterus; *d*, vault of vagina; *e*, anterior wall of vagina; *ff*, cut surface of bladder-wall; *g*, trigone; *h*, vesical opening of urethra; *i*, venous plexus at the side of the uterus and the vagina; *k*, right ureter; *l*, left ureter.

vein, and below with the vaginal and vesical plexuses. The ureter passes right through it (Fig. 58). During pregnancy the uterine veins are enormously enlarged and form the so-called *sinuses*, large

spaces the walls of which only consist of the internal coat of the veins, and are intimately bound to the surrounding muscular tissue.

The Lymphatics.—The uterus is exceedingly rich in lymphatic spaces and vessels. They begin in the mucous membrane as open spaces lined with endothelium, and separating the bundles of connective tissue. In the muscular layer are found similar spaces and vessels, and they all communicate with a superficial network of vessels in the serous membrane. From the uterus the lymphatics go through the broad ligament. Those from the cervix go to the obturator glands, situated at the inner entrance of the obturator canal and communicating with the inguinal glands. Those from the body go to the internal iliac glands, situated between the external and internal iliac artery, and which, again, send vessels to the sacral glands on the anterior surface of the sacrum and to the lumbar glands in front of the lumbar vertebræ. The gland of the isthmus is situated in the lower inner angle of the broad ligament.

The Nerves.—Branches from the second, third, and fourth sacral (spinal) nerves meet with others from the hypogastric plexus (sympathetic) in a large ganglion on either side of the cervix, from which *cervical ganglion* branches go to the uterus, the vagina, and the bladder. Those of the uterus end in the nucleus of the muscular cells, and in ganglia in the mucous membrane.

Function.—The rôle the uterus plays as a copulative organ is not quite settled, but much evidence has been adduced in favor of the theory that it exerts a suction by which the semen is drawn into its cavity.[1] But it is a well-demonstrated fact that conception may take place independently of such action.

The most important physiological destination of the womb is to furnish a place of attachment for the ovum, to shelter the fetus during its development, and to expel the child during parturition.[2]

The uterus is the seat of the chief portion of the menstrual flow. At the menstrual period its epithelium is thrown off, and a new one is formed in the interval between two menstruations.

The Fallopian Tubes.

The Fallopian tubes, or oviducts (Fig. 59), are two long, slender, round tubes connected with the upper angles of the uterus. Their length varies between 3 and 5 inches. The tube starts from the highest point of the corner of the womb, above the round ligament in front and the ovarian ligament behind. From thence it goes first outward, and turns then backward, lying near the wall of the pelvis,

[1] Joseph R. Beck, *Am. Jour. Obst.*, 1874, vol. vii. pp. 353-391.

[2] Several cases are on record of women with a fracture of the spine, causing complete paralysis of the abdominal muscles, in whom the child was expelled by the mere contractions of the womb.

above and in front of the ovary, and finally it curves round the free end of the ovary, the abdominal end being turned against the ovary and the bottom of the pelvis. Sometimes it has even been found surrounding the ovary entirely, with the abdominal end resting on the ovarian ligament.

It may be divided into three parts—the isthmus, the ampulla, and the fimbriæ. The *isthmus* comprises about the inner third. It begins

FIG. 59.

Posterior View of Left Uterine Appendages (Henle): 1, uterus; 2, Fallopian tubes; 3, fimbriated extremity and opening of the Fallopian tube; 4, parovarium; 5, ovary; 6, broad ligament; 7, ovarian ligament; 8, infundibulo-pelvic ligament.

in the outermost and uppermost corner of the uterine cavity with an opening called the *ostium uterinum*, which is so fine that it barely admits a bristle. It goes through the wall of the uterus, and extends as a cord about $\frac{1}{8}$ inch thick outward. The *ampulla* is the middle part, which is twice as thick or more, curved, and follows a serpentine course. It has also been called the *receptaculum seminis*, because it seems to be particularly destined to hold and preserve the spermatozoids until they come in contact with the ovum. Its calibre admits a uterine sound. The *fimbriæ* are the outermost part. They surround the outer end of the ampulla like a collar with long flaps. One of these, the *fimbria ovarica*, is attached to the free end of the ovary, and forms a gutter. In the middle of the fimbriæ is the *ostium abdominale*, which again is a very fine opening, leading into the peritoneal cavity. Often a pedunculated hydatid is found at the abdominal end. This was originally the end of the Müllerian duct, of which the tube is a development.

As we have seen in the chapter on Development, the tubes have a common origin with the uterus. The point that forms the limit

between the two is the insertion of the round ligament. The tube, like the uterus, is composed of three layers—a serous, a muscular, and a mucous—and each of these is continuous with the corresponding layer of the uterus. The serous coat is formed by the uppermost part of the broad ligament. That part of this ligament which is situated immediately below the tube, between it and the ovary, is called the *mesosalpinx*, or the *ala vespertilionis* (bat's wing). The *mesosalpinx* is continued beyond the end of the tube as the so-called *infundibulo-pelvic ligament*, which goes from the fimbriæ outward and backward to the iliac fossa, whence it carries the utero-ovarian vessels (internal spermatic) to the tube and ovary.

The muscular coat consists of an outer longitudinal, an inner circular layer, and near the uterus another longitudinal layer.[1] It contains most of the blood-vessels.

The mucous membrane forms large and small longitudinal folds (Fig. 60). It covers the inner side of the fimbriæ, while the outer

FIG. 60.

Fallopian Tube laid open (from Playfair, source unknown): *ab*, uterine portion of tube; *cd*, folds of mucous membrane; *e*, tubo-ovarian ligament, or fimbria ovarica; *f*, ovary; *g*, round ligament.

side is covered with peritoneum. It has a single layer of ciliated columnar epithelium, the cilia of which move in such a way as to push the ovum in the direction of the uterus. With increasing age the ciliated epithelium is, however, partially replaced by non-ciliated columnar and flat epithelium. The mucous membrane has no glands.[2] The muscular expansion from the outer layer of the uterus extends to the tube, and seems to be able to cause an erection of it.

The uterine end moves with the uterus; the remainder is still more freely movable, since the tube is much longer than the straight line between its two ends, and its movements are only checked by the

[1] J. Whitridge Williams, *Am. Jour. Med. Sci.*, Oct., 1891, vol. cii. p. 378.
[2] Otto Cohen, *Med. Monatsschr*, New York, Sept., 1890, vol. ii. p. 413.

thin, loose, elastic mesosalpinx, the fimbria ovarica, by which it is connected with a movable ovary, and the infundibulo-pelvic ligament.

The *arteries* of the Fallopian tubes come from the ovarian artery (Fig. 38).

The *veins* go to the pampiniform plexus in the broad ligament.

The *lymphatics* unite with those of the ovary and go to the lumbar glands.

The *nerves* come from the inferior hypogastric plexus of the sympathetic.

Function.—The Fallopian tubes are the canals through which the ova pass from the ovaries to the uterus, and in which probably, in most cases, impregnation takes place by the union of an ovum and one or more spermatozoids. It seems that during menstruation the fimbriæ are spread out and applied with their mucous side to the ovary, so as to catch the ovum when it leaves the Graafian follicle (Fig. 56). The surface of the ovary being four or five times larger than that of the fimbriæ, it seems, however, impossible that these should always cover a bursting follicle. Many ova doubtless fall into the peritoneal cavity. The accompanying blood, if in small quantity, is absorbed. If copious, it forms periuterine hematocele. The ova perish or give rise to abdominal pregnancy. Some may also be secondarily attracted to the Fallopian tubes by the current produced by the movement of their cilia.

The Ovaries.

The ovaries (Fig. 61) are two oval bodies situated in the true pelvis, to the sides of the uterus, below, behind, and to the inner side of the Fallopian tubes. They are about 1½ inches long, 1 inch wide, and ½ inch thick. They are, as it were, inserted in a hole in the posterior layer of the broad ligament, as a diamond is fastened to a ring. They are covered with a single layer of hexagonal columnar epithelial cells,[1] such as we find on mucous membranes, and entirely different from the large, flat endothelial cells covering the peritoneum. Their long axis is placed diagonally in the pelvis. They have an inner anterior end, an outer posterior end, an anterior outer edge, a posterior inner edge, an upper anterior outer surface, and a lower posterior inner surface.[2] The inner end is fastened to the corner of the uterus, behind and below the tube, by means of the *ligament of*

[1] As some authors deny the fact, first pointed out by Waldeyer, that the ovary is not covered with peritoneum, I wish to state that I have satisfied myself by numerous examinations of ovaries of women of the correctness of the above.

[2] The reader will understand this much more readily if he takes an oblong box and gives the surfaces, ends, and edges the above indicated directions.

the ovary, a round string, about an inch long, running at the upper edge of the broad ligament, between its two layers, and composed of connective tissue and unstriped muscle-fibres, which are a continuation of the outer layer of the uterine muscular tissue. This inner

FIG. 61.

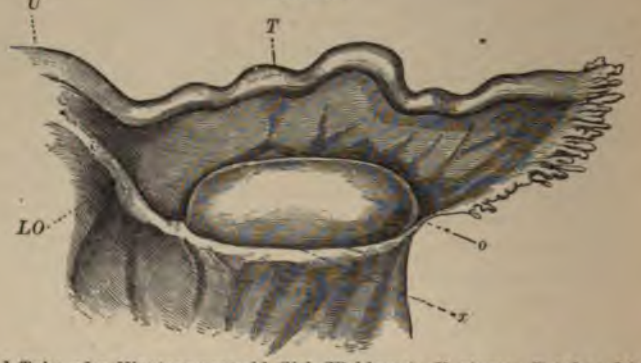

Ovary and Tube of a Nineteen-year-old Girl (Waldeyer): *U*, uterus; *T*, tube; *LO*, ovarian ligament (of unusual length); *o*, ovary; *x*, limit of peritoneum. (The inner end of the ovary is too high.)

end of the ovary is tapering and thinner than the outer. The outer end is broader, fastened above to the fimbria ovarica and below to the infundibulo-pelvic ligament (Fig. 61). The anterior edge is nearly flat, and bound to the posterior layer of the broad ligament. The place where the vessels and nerves enter is called the *hilum*. A white line marks the abrupt transition from the peritoneum to the ovarian epithelium, and this is situated on a higher level on the anterior surface than on the posterior. The anterior surface is less convex than the posterior. The posterior edge is strongly convex and free.[1] The ovaries lie above the retro-ovarian shelves (which will be described later in speaking of the pelvic peritoneum), are surrounded with coils of the small intestines, and lie near the rectum. By introducing one or two fingers into the vagina as high up as possible to the sides of and behind the uterus, and depressing the abdominal wall in the region of the iliac fossa, the ovaries can sometimes be felt.

In a young girl the surface of the ovary (Fig. 61) is even, smooth, velvety, of pearl-gray color.

Later, each ovulation leaving a little puckered cicatrix, the surface

[1] By the data given above it is easy to distinguish the left from the right ovary, but the only way of obtaining a correct idea of the ovary is by remembering that it has a uterine end and a tubal end, an attached border and a free border, a smaller and a larger surface, for the organ is so movable that it is found in the most different positions, so that expressions like upper and lower, inner and outer, are taken in the opposite sense by different authors.

becomes harder and shows irregular depressions (Fig. 62), and in old age it becomes nearly cartilaginous and loses partly its epithelium.

As to its composition, the ovary may even macroscopically be divided into an outer part, called the *parenchymatous zone*, or *corti-*

FIG. 62.

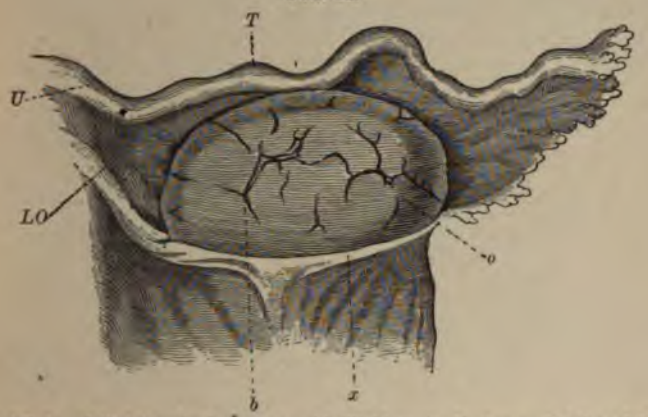

Ovary and Tube of Girl twenty-four years old (Waldeyer); *U*, uterus; *T*, tube; *LO*, ovarian ligament; *o*, ovary; *x*, limit of peritoneum; *b*, cicatrice after ruptured Graafian follicle.

cal substance, and an inner, called the *vascular zone*, or *medullary substance*.

The microscopical examination shows a greater number of layers. Under the columnar epithelium is found a narrow, somewhat harder layer called the *albuginea* (Figs. 63 and 64). It is intimately connected with the subjacent parenchyma, from which it cannot be dissected off. Under the microscope three layers may be distinguished in it. It is composed of fibrous connective tissue with interspersed unstriped muscle-fibres. Under the albuginea is found a zone distinguished by the presence of small follicles containing an ovum, the so-called *ovisacs*, or young *Graafian follicles*. Inside of this zone is found another with much larger Graafian follicles. The tissue in which these follicles are imbedded consists chiefly of unstriped muscle-fibres and connective tissue, which are arranged in circles around each follicle. The centre is formed by the so-called *medullary substance*, or *vascular zone*. Here the connective tissue is much looser than in the parenchymatous zone, but it is full of unstriped muscle-fibres, as well as the parenchymatous zone. The largest vessels are found most centrally and nearest the hilum. Nearer the surface and the free end they are smaller. A diagram (Fig. 65) may help to realize how these zones are distributed on a transverse section of a human ovary. The whole section appears pear-shaped, the zones

being narrower near the hilum and increasing in width toward the free border.[1]

The small follicles, measuring from 0.02 to 0.08 millimeter in diameter, are the same we have described in the history of the development (p. 26), but of the enormous number comparatively few are left. The large follicles constitute more properly what is called Graafian follicles, and can be seen with the naked eye as vesicles of the size of French peas.

FIG. 63.

Section of the Ovary of a Cat, enlarged six times (Schrön): 1, outer covering and free border of the ovary (epithelium and albuginea); 1', attached border; 2, vascular zone, or medullary substance; 3, parenchymatous zone, or cortical substance; 4, blood-vessels; 5, Graafian follicles in their earliest stages, lying near the surface; 6, 7, 8, more advanced follicles, imbedded more deeply in the stroma; 9, an almost mature follicle, containing the ovum in its deepest part; 9', a follicle from which the ovum has accidentally escaped; 10, corpus luteum.

There are from six to twenty of these large follicles in an ovary. The ovisacs do not migrate. It is simply by their increased size that the larger follicles seem to form a zone inside of the small ones. In growing they push the surrounding tissue aside and extend deep into the interior of the ovary, and at the same time closer to its surface, until finally all tissue between the follicle and the surface is absorbed and the follicle can burst there.

The wall of the Graafian follicle (Fig. 66) consists of two layers, an outer, denser, called *tunica fibrosa*, composed of fibres of connective tissue, and an inner, more delicate, softer, called *tunica propria*, and containing many cells and a fine network of capillary vessels. Although there is, microscopically, no line of demarkation between the follicles and the surrounding tissue, they are easily pulled out. Inside of the tunica propria are found several layers of epithelial cells, together

[1] When I state above that the ovary is pervaded by unstriped muscle-fibres, it is because I have good authority for it (Sappey and others), and because I have myself occasionally seen them form bundles exactly like those in other organs where their identity is recognized by everybody. But some authors do not admit that the cells we see forming the bulk of the tissue between the follicles are of muscular nature.

called the *membrana granulosa*, and between the epithelial cells and the tunica propria there is a *structureless membrane*. On one side

FIG. 64.

Part of the Same Section as represented in Fig. 63, more highly enlarged (Schrön): 1, the epithelium and albuginea; 2, fibrous stroma; 3, 3', less fibrous, more superficial stroma; 4, blood-vessels; 5, small Graafian follicles near the surface; 6, one or two more deeply placed; 7, one further developed, enclosed by a prolongation of the fibrous stroma; 8, a follicle still further advanced; 8', another, which is irregularly compressed; 9, part of the largest follicle; *a*, membrana granulosa; *b*, discus proligerus; *c*, ovum; *d*, germinal vesicle; *e*, germinal spot.

these epithelial cells form a mass protruding into the cavity of the

FIG. 65.

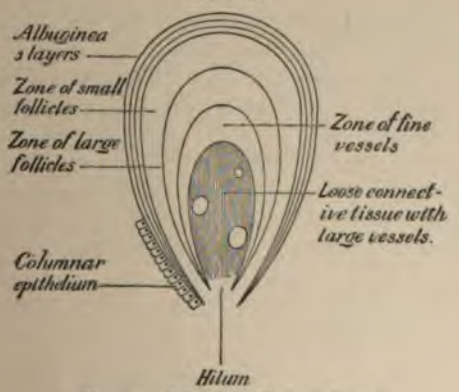

Diagram of Zones in Human Ovary.

follicle, and called *discus proligerus* (Fig. 64, *b*). The outermost

layer of epithelial cells of the Graafian follicle has a regular columnar shape; the inner ones are more irregular and breaking down, except those immediately surrounding the ovum, which again form a regular single layer of columnar cells. The space between this epithelium and the discus proligerus is filled with a clear serous fluid called *liquor folliculi*, which contains a few cells, albumin, and paralbumin. It is formed by liquefaction of the cells of the membrana granulosa.

FIG. 66.

Graafian Follicle of Adult Woman, 40 : 1 (De Sinéty): *a*, external layer, or tunica fibrosa; *b*, internal layer, or tunica propria; *c*, blood-vessels; *d*, membrana granulosa; *e*, discus proligerus; *l*, liquor folliculi (coagulated); *o*, ovum.

In the discus proligerus is imbedded the *ovum* (Fig. 67). The human ovum is 0.2–0.3 millimeters in diameter, or just about visible with the naked eye. The surrounding cells form a regular epithelial layer of short columnar cells all around it. Inside of that is found a fine membrane with radiating striæ, the *zona pellucida*, or *vitelline membrane*.[1] The interior is filled with a semifluid mass called the *vitellus*. This is composed of larger clear bodies and minute dark ones, and one much larger vesicle called the *germinal vesicle*. The latter contains a little round body called the *germinal spot*. In the interior of the latter are found a few small dark granules, and sometimes similar bodies are found in the germinal vesicle outside of the germinal spot.

After the climacteric age the follicles and ova disappear, the whole organ shrinks, and its surface is very uneven.

Corpus Luteum of Menstruation.—The Graafian follicle undergoes certain changes. As a rule, one attains during the intermenstrual

[1] The vitelline membrane is something entirely different from the yolk-sac, although one name might seem to be a translation of the other.

period the size of a hazelnut ($\frac{1}{2}$ inch or more in diameter), the tissue between it and the surface becomes thinner and thinner, until, finally, it bursts and lets the ovum escape. The follicle is then filled with blood, which coagulates, forming a cherry-colored clot (Fig. 68). A few days later the wall begins to be enlarged and thickened, and this enlargement within a confined space causes it to become folded upon itself in short zigzag reduplications, mainly at the deeper part of the

FIG. 67.

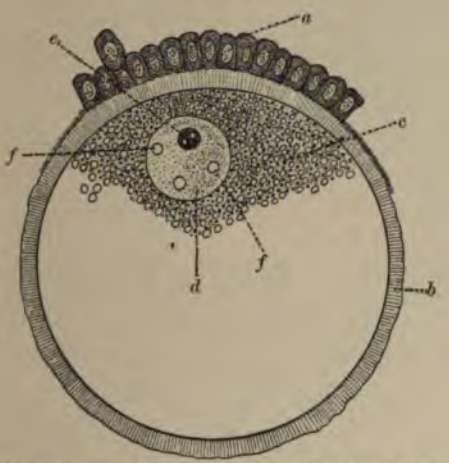

Mature Ovum of Rabbit, Hartnack $\frac{2}{3}$ (Waldeyer): *a*, cells from the discus proligerus (epithelium of ovum); *b*, zona pellucida; *c*, vitellus; *d*, germinal vesicle; *e*, germinal spot; *f*, large globules with dull lustre in the germinal vesicle.

follicle (Fig. 69). These folds grow into the clot, and finally replace it. In this way is formed, during the intermenstrual period, a *corpus luteum*, occupying the substance of the ovary immediately beneath the superficial cicatrix which marks the site of the ruptured follicle (Fig. 70). Subsequently the whole structure diminishes in size, and becomes more and more intimately connected with the surrounding tissue, so that it can no longer be peeled out *in toto*. In a regularly menstruating woman it seldom happens that we do not find three or more corpora lutea in different stages of growth or retrogression. The volume of the menstrual corpora lutea varies between about one-half and one cubic centimeter. By the eleventh week after menstruation it is less than one-twentieth of a cubic centimeter.

Corpus Luteum of Pregnancy.—If pregnancy takes place, no new corpora lutea are formed, but the one corresponding to the last menstruation becomes larger and stays longer. After the first month it continues to increase in size, or, at least, does not diminish, and its convoluted wall assumes the strong yellow hue which has given rise

to its name. At the same time the central clot becomes fully decolorized, growing denser and firmer in proportion as it diminishes in bulk, until a firm white fibrinous clot is found in the centre of the yellow ring (Fig. 71). Sometimes this clot has itself a central cavity filled with a serous fluid. Beyond a certain period of pregnancy, the date of which is not precisely known, the corpus luteum diminishes in size, and loses the freshness of its yellow hue. At the end of pregnancy it is reduced to about one-half of a cubic centimeter.[1]

[1] According to Dr. Mary A. Dixon Jones, working under the auspices of Dr. Charles Heitzmann, the process taking place in the ovary, in connection with menstruation, is a different one. They claim that the wall of the follicle bursts, not only on the surface of the ovary, but in many places, and that an extravasation of blood follows into the surrounding tissue, where it sets up a mild degree of inflammation. The fibrous connective tissue, as well as the unstriped muscle-fibres, in the vicinity of the follicle are reduced to a protoplasmic condition, and immediately outside of the follicle the tissue is infiltrated with granular inflammatory corpuscles (or medullary elements) which enter the follicular cavity (Fig. 72), and gradually are

FIG. 72.

Menstrual Follicle ten to twelve days after rupture ×600 (M. Dixon-Jones): *E*, extravasated blood; *S*, structureless membrane; *C*, capillary blood-vessels; *F*, fibrous connective tissue.

transformed there to a myxomatous tissue, destitute, as a rule, of blood-vessels, but showing now and then cavities, probably caused by a liquefaction of the myxomatous substance (Fig. 73). With advancing age the myxomatous tissue becomes less and less, until nothing is left of the original follicular wall but the so-called structureless membrane distinctly convoluted and imbedded in ovarian tissue (*New York Med Jour.*, May 10 and 17, 1890).

According to Dr. Jones, the so-called corpus luteum of pregnancy is a pathological

68

70

69

FIG. 71.

FIG. 74.

. 68.—Ovary of Woman two days after Menstruation (Dalton), showing earliest stage of transformation of a ruptured and bloody Graafian follicle into a corpus luteum.

. 69.—Ovary of Woman twenty days after Menstruation (Dalton). Besides large fresh corpus luteum are seen two smaller old ones, and Graafian follicles of different size.

. 70.—Ovary of Woman nine days after Menstruation (Dalton). The dark spot is the cicatrice; the surrounding yellow circle is the corpus luteum shining through the transparent tissue.

. 71.—Ovary of Woman at Term of Pregnancy (Dalton), showing corpus luteum with firm white central clot.

. 74.—False Corpus Luteum (Dalton)

False Corpora Lutea.—Sometimes Graafian follicles degenerate. The wall becomes thick, opaque, whitish, and assumes a slightly car-

FIG. 73.

Normal Menstrual Body × 100 (M. Dixon-Jones): *CC*, cortex of ovary: *S*, so-called structureless membrane, broken; *M*, myxomatous tissue filling the previous follicle; *O*, old menstrual body, remnants of structureless membrane; *VV*, veins.

tilaginous consistency. The fluid in the interior disappears, and the opposite surfaces come in contact with each other. The ovum dis-

formation which she calls *gyroma*, and which we shall describe in speaking of oöphoritis. It may be found in women who have never been pregnant, and be absent in those who have borne children (*New York Med. Jour.*, May 10 and 17, 1890; *Times and Register*, Philad., Apr. 30, 1892). In my opinion, the gyromas, the existence of which I am familiar with myself, are what Patenko has described under the name *corpora fibrosa* (*Virchow's Archiv*, 1881, vol. lxxxiv. pp. 193–207) —an abnormal formation which differs from the normal corpus luteum of pregnancy.

appears also. These follicles lie in the deeper parts of the ovary, and do not communicate with the surface (Fig. 74, colored plate, p. 71). They may be called false corpora lutea.[1] When the corpus luteum has lost its yellow color and most of its vessels, and is chiefly composed of connective tissue, it is called *corpus albicans*. If such a body contains dark pigment, it is not white, but dark brown or black, and is called *corpus nigrum* or *corpus nigricans*.[2]

Quite frequently large or small *extravasations* of blood are found in the tissue of the ovary.[3]

The ovary has a rich supply of blood- and lymph-vessels, which enter at the hilum. The *arteries* (Fig. 38, colored plate, p. 45) come from the ovarian artery, follow a spiral course, and end in a fine capillary network in the tunica propria of the follicles. They have very thick walls and a small calibre. The *veins* follow the arteries, and go to the pampiniform plexus in the broad ligament. From that the blood is carried through the ovarian veins. The right opens into the inferior vena cava, and has a valve; the left opens into the renal vein at right angles, and has no valve. The latter circumstance is perhaps the explanation of the much greater frequency of pain in the left side of the pelvis than the right in gynecological patients. The ovarian veins anastomose with the uterine (Fig. 58, p. 61). They are imbedded in the tissue in the same manner as those of the uterus. The *lymphatics* begin around the follicles, follow the veins, and go to the lumbar glands. The *nerves* come from the inferior hypogastric plexus (Fig. 31, colored plate, p. 39).

Function.—The ovary produces and expels the ova by which the species is propagated. The expulsion is probably brought about by contraction of the unstriped muscle-fibres which form so large a portion of the organ, combined with congestion.

The Parovarium.

The parovarium (Fig. 78) is a remnant of the Wolffian body (see p. 22). It is situated in the connective tissue between the two layers

[1] The term "false corpus luteum" is often, but less properly, used in the sense of corpus luteum of menstruation.

[2] John C. Dalton, "Report on the Corpus Luteum," *Am. Gyn. Trans.*, 1877, vol. ii. pp. 111–160.

[3] In 1879–80, while investigating abdominal fluids, I made numerous sections of apparently normal human ovaries. In so doing I got the impression that there are many processes going on in the ovaries which are not yet described. Other work has prevented me from following this track, but it may be permissible here to point out the large number of yellow masses we find in seemingly normal ovaries of women. Fig. 75 is drawn in natural size from the ovary of a woman thirty-six years old, cut open lengthwise. Under the albuginea was found a red zone with three Graafian follicles, and the whole interior was taken up by yellow tissue indistinctly divided into several parts.

Fig. 76 is likewise drawn from nature, in the exact size. It represents the ovary

of the broad ligaments, between the outer end of the ovary and the ampulla of the Fallopian tube. It can be seen by holding the broad ligament up against the light. It is a small, flat, triangular organ, the apex of which touches the attached edge of the ovary. It is composed of from six to thirty spiral tubules. At the base these tubules open into one transverse tube, which may be followed as a solid cord in the direction of the uterus. This tube and cord corresponds to Gartner's canal in certain animals (see p. 20), and are a remnant of the Wolffian duct. The tubules have a wall composed of connective tissue, unstriped muscle-fibres, and a ciliated columnar epithelium. At the outer side there are some tubules which do not reach the ovary, and one of them, the end of the transverse tube, terminates often in a small cyst similar to the *hydatid of Morgagni* (p. 30). At the inner side there are some tubules which have lost their lumen and become fine cords.

FIG. 75.

Ovary of Woman thirty-six years old (natural size): *a*, albuginea; *b*, red zone; *c*, *d*, *e*, Graafian follicles situated in the red zone, which here broadens; *f*, all the remainder is taken up by yellow tissue indistinctly divided into several parts, probably corpora lutea of menstruation in retrograde metamorphosis.

The parovarium has no function, but is liable to become the seat of cystic degeneration.

THE URINARY ORGANS AND THE RECTUM.

The urethra, the bladder, the ureters, and the rectum are so closely connected with the genitals, and the gynecologist is so often called upon to treat diseases in these parts, that a brief résumé of their anatomy would seem indispensable.

THE URETHRA.

The urethra is a canal leading from the bladder to the vulva. It is from 1 to 1½ inches long and ¼ inch in diameter, but very distensible. It is usually said to be straight or slightly S-shaped, but these descriptions are based upon post-mortem examinations. The fact that a catheter is best introduced by performing a curve round the lower end of the symphysis pubis, leads me to believe that

of a woman forty-seven years old. It shows a corpus luteum, a large yellow mass, and thirteen distinct small yellow masses. Examined under the microscope, these masses prove to be follicles with irregular lumps of yellow pigment interspersed in the thin tissue between the follicles, and sometimes in the follicles themselves. I wonder if all this yellow pigment is not a remnant of old corpora lutea?

Fig. 77 is also drawn from nature, in actual size, and shows a corpus luteum transformed into a cyst, numerous yellow masses with remnant of a central cavity, and two corpora nigra.

it follows a curved course, with the concavity forward. It is imbedded in the vaginal wall.

It is suspended to the pubic arch by the pubo-vesical ligament, and passes through the triangular ligament, between the layers of which it is surrounded by the compressor urethræ muscle, or Guthrie's muscle. Another sphincter muscle surrounds the urethra and the vagina together as a narrow belt just behind the vestibulo-vaginal bulbs.

FIG. 76.

Ovary of Woman forty-seven years old (natural size): *a*, corpus luteum with central cavity; *b*, another corpus luteum; *c*, a third small one; besides this thirteen yellow bodies could be counted on the cut surface, and there were perhaps more in the invisible parts of the ovary.

The urethra has an outer layer of circular unstriped muscle-fibres, an inner longitudinal layer, and a mucous membrane.

The *meatus urinarius* has already been described in speaking of the vulva (see p. 39).

The mucous membrane, when not distended, forms longitudinal folds. It has many depressions and blind canals, so-called *Morgagni's lacunæ*, and racemose glands (*Littre's*[1] *glands*). Near the floor, just inside of the meatus, are found two canals, *Skene's glands*,[2] or *urethral ducts* (Fig. 79), one on either side. They admit a No. 1 probe of the French scale, and extend upward, parallel to the long axis of the urethra, from $\frac{3}{8}$ to $\frac{3}{4}$ of an inch, in the muscular tissue, below the mucous membrane. The mouths of these tubules are found upon the latter $\frac{1}{8}$ of an inch from the meatus. If the mucous membrane is everted —which it often is in those who have borne children—the openings are exposed to view on either side of the entrance to the urethra. The upper end of these tubes terminates in a number of divisions which branch off into the muscular wall of the urethra.

FIG. 77.

Ovary of Woman twenty-nine years old: *a*, corpus luteum transformed into cyst; *b*, numerous yellow masses with remnant of central cavity; *cc*, corpora nigra; *d*, albuginea.

The mucous membrane of the urethra is of pink color, surrounded by a rich network of veins, and has a stratified flat epithelium.

Vessels and *nerves* are derived from those of the vagina.

[1] This name is often erroneously spelt Littré, which is that of the author of a dictionary, just as Gartner almost invariably is called Gärtner, and Bartholin often Bartholini. Both were Danes.

[2] Skene, "The Anatomy and Pathology of Two Important Glands of the Female Urethra," *Am. Jour. Obstet.*, 1880, vol. xiii. p. 265. Their glandular nature has been contested.

Functions.—The function of the urethra is to serve as an outlet from the bladder. Its muscular tissue works probably as a sphincter for the same.

FIG. 78.

Adult Ovary, Parovarium, and Fallopian Tube (Kobelt): *aa*, parovarium (or epophoron); *b*, remains of the uppermost tubes of the Wolffian body; *c*, middle set of tubes forming parovarium; *d*, lower, atrophied tubes; *e*, atrophied remains of Wolffian duct (Gartner's canal); *f*, the terminal bulb or hydatid of the Wolffian duct; *h*, the Fallopian tube; *i*, hydatid of Morgagni; *l*, ovary.

THE BLADDER.

The bladder is a hollow muscular organ situated in the median line, between the pubic bones in front and the vagina and uterus behind. When empty, it is in the true pelvis; when distended, it reaches more or less high up in the abdominal cavity, lying close up against the abdominal wall. When empty, it has been found in two different shapes—either so that the upper part falls against the lower, the cavity combined with the canal of the urethra having the shape of a Y, of which the two upper branches represent the bladder, and the lower trunk the urethra, or so that the anterior wall comes in contact with the posterior. In the latter case the combined lumen of the bladder and the urethra form a C or an L.[1]

The female bladder is shorter than the male in the antero-posterior direction, but more than makes up for this by being broader. I have myself drawn three quarts of urine from a woman who had no retention of urine, and I have read that four litres have been evacuated from a female bladder. When distended it has an ovoid shape.

We distinguish the base, the summit, the anterior and the posterior

[1] Hart and Barbour (*Manual of Gynecology*, 4th ed., p. 35) suggest ingeniously that the Y-shape is that of relaxation, and the oval shape represents systole—*i. e.* contraction; but if the oval shape were due to muscular contraction, it could hardly be maintained after death.

surface, and two sides. The *base* or *fundus*[1] is the lowest part of the organ. It is bound by rather dense connective tissue to the anterior wall of the vagina and the neck of the womb. Three openings are found on it. In front is the internal opening of the urethra, which is flat, crescent-shaped. There is no funnel-shaped part here, so that the term "neck" is a misnomer. The urethra opens abruptly on the wall of the bladder. Behind there are two fine, lengthy slits where the ureters open into the bladder. The triangle between these three openings is called the *trigone* (Fig. 80). Each of its sides measures about an inch. The base is formed by the intra-ureteric ligament. The distance from this to the cervix uteri varies. I have found it immediately under the os and half an inch below it. When the bladder is distended the distance increases to 1 inch.

FIG. 79.

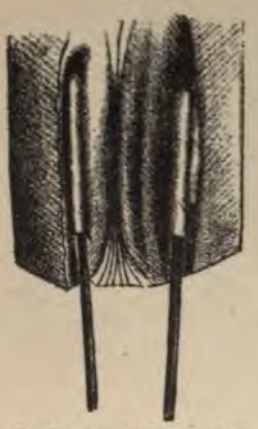

The Urethra laid open from behind; probes introduced into the urethral ducts (Skene).

The surface on which the bladder is in tact with the vagina is heart-shaped. The boundary-line runs in the lower part parallel to and a little outside of the trigone. In the upper part it follows the outline of the vagina. The bladder extends $\frac{5}{8}$ inch up on the cervix. From the *summit* the urachus, one of the false ligaments of the bladder, goes to the umbilicus. The anterior surface lies up against the body of the pubic bones and the anterior abdominal wall. It has no peritoneal covering. The posterior wall is covered with peritoneum down to the level of the internal os, where it passes over on the uterus. Under this fold lies some loose connective tissue. The sides are likewise covered with peritoneum. The posterior wall is alternately in contact with the uterus or the small intestine, which latter likewise at times touches the sides. The wall varies in thickness, according to the degree of distension, between $\frac{1}{8}$ and $\frac{1}{2}$ inch. It is composed of a serous, a muscular, and a mucous coat. The serous coat is formed by the peritoneum. During pregnancy the connective tissue that binds it to the underlying tissue becomes so loose that during labor the bladder becomes entirely stripped of its peritoneal coat. The muscular coat has an outer longitudinal and an inner circular layer of unstriped fibres. When the bladder is much distended, the bundles can be seen to separate so as to present a kind of lattice-work. The muscular tissue is thicker around the opening to the urethra, which disposition probably serves to press out the last drops of urine during micturition.

[1] The reader will notice that in speaking of the bladder the word "fundus" is taken in an entirely different sense from that applied to the uterus.

The mucous membrane, examined with the galvanic cystoscope, has a lively pink color. In general it is loosely attached to the muscular layer, and forms folds when the bladder is empty. But at

FIG. 80.

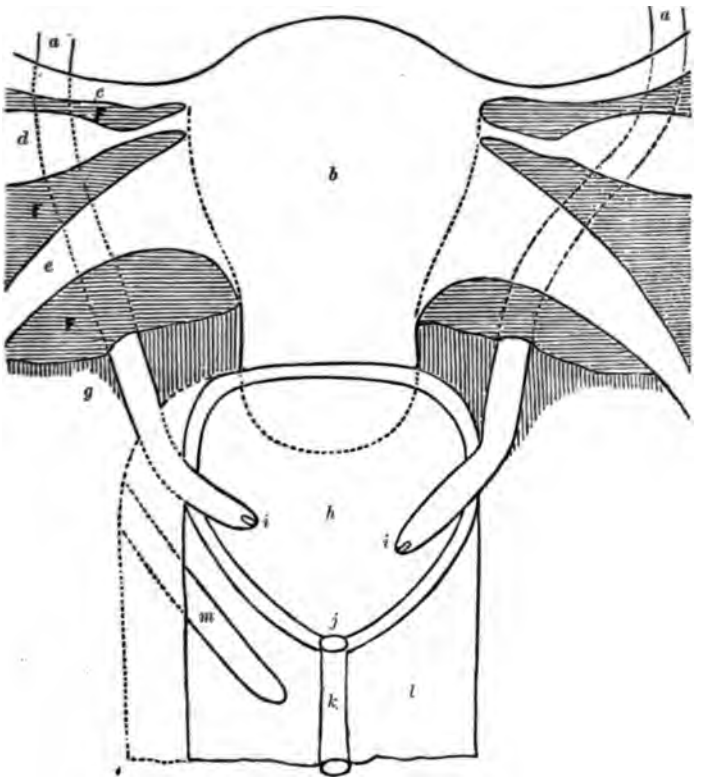

Uterus, Ureters, and Upper Part of Vagina of Woman forty years old, ⅓ natural size. All measurements were made *in situ* with compasses, and then marked on the paper without regard to foreshortening: *a*, ureters; *b*, uterus; *c*, Fallopian tube; *d*, ovary; *e*, round ligament; *F*, broad ligament; *g*, connective tissue; *h*, bladder (the antero-superior part removed to show attachment to cervix and vagina); *i*, vesical opening of ureters; *j*, inner aperture of urethra; *k*, urethra; *l*, vagina; *m*, incision and rent in the operation called gastro-elytrotomy.

the trigone it is attached more solidly. It contains numerous lacunæ and racemose glands. It is covered with a transition epithelium, in which several layers are discernible, an upper of flat and several deeper of large and small pear-shaped cells (Figs. 81, 82). The mucous membrane seems to be able to absorb substances injected into the bladder.

Between the mucous membrane and the muscular coat there

is, with the exception of the trigone, a well-developed *submucous layer* composed of connective tissue, elastic fibres, vessels, and nerves.

Ligaments.—The bladder has four true and five false ligaments. The *true* are thickened parts of the pelvic fascia. The *anterior true ligaments* are two in number, a narrow but strong band on each side, consisting to a great extent of involuntary muscle-fibres, and passing from the lower part of the pubis to the anterior surface of the bladder, above the urethral opening. On the outer side of the anterior ligament the part of the fascia which descends to the side of the bladder is known as the *lateral true ligament.*

FIG. 81.

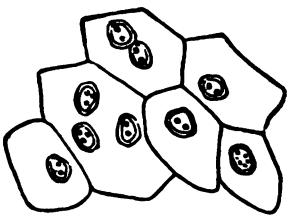

FIG. 82.

FIG. 81.—Superficial Layer of the Epithelium of the Bladder, front view, composed of polyhedral cells of various sizes, with one, two, or three nuclei (Klein and Noble Smith).

FIG. 82.—Deep Layers of Epithelium of Bladder, side view, showing large club-shaped cells above and smaller, more spindle-shaped, cells below, each with an oval nucleus (Klein and Noble Smith).

The *false* vesical ligaments are folds of the peritoneum. There are two posterior, two lateral, and one superior. The *posterior* are the *vesico-uterine ligaments* (see p. 55); the *lateral* false ligaments extend from the iliac fossæ to the sides of the bladder, each separated from the posterior ligament by the obliterated hypogastric artery. The *superior* false ligament (*ligamentum suspensorium*) is the portion of peritoneum between the ascending parts of the hypogastric arteries, and reaches from the summit of the bladder to the umbilicus. It covers the *urachus*, a fibrous cord which lies between the linea alba and the ligamentum suspensorium.

The *urachus* is a remnant of the atlantoid of fetal life, and has preserved a long cavity, subdivided by partitions and lined with epithelium similar to that of the bladder. Sometimes this cavity communicates with the bladder.

Vessels and Nerves.—The *arteries* come directly from the internal iliac (the *superior*, *middle*, and *inferior vesical arteries*) or from its branches, the sciatic, internal pudic, middle hemorrhoidal, and uterine arteries. The *veins* form large plexuses communicating with those of the uterus, vagina, vulva, and rectum, and sending their blood to the internal iliac vein. The *lymphatics* follow the veins and open into the hypo-

gastric glands. The *nerves* come from the hypogastric plexus of the sympathetic and the sacral nerves (cerebro-spinal).

Function.—The bladder serves as a reservoir for the urine, which is constantly being thrown into it from the ureters. It is emptied by the contraction of its own muscle-fibres, while the sphincters are placed in the urethra.

The Ureters.[1]

There are two ureters, long, slender cylindrical tubes, leading from the kidneys to the bladder. They are 16 to 18 inches long, and thick as a goose-quill. They are the continuation of the renal pelvis. They lie behind the peritoneum, imbedded in very loose connective tissue, and are much longer than the direct line between their two ends. At their upper ends the distance between them is 2½ inches. From this point they go, excepting slight windings, parallel with one another, down to the spot where they cross the iliac vessels at the brim of the pelvis. In this part of their course they lie in front of the psoas muscle. They are crossed by the ovarian vessels; the right lies close to the outer side of the inferior vena cava, behind the ileum. The left lies behind the sigmoid flexure of the colon. They cross the lower end of the common iliac artery or the upper end of one of its two branches, the external and the internal iliac (Fig. 83), and enter the pelvis. Here they describe a large curve. First they diverge, running downward, backward, and a little outward on the wall of the pelvis to a point near the spine of the ischium; then they bend downward, forward, and considerably inward, so as to converge toward the bladder. They lie outside of the internal iliac artery, behind the broad ligaments, running down to their base, and then under them. They go right through the large plexus of veins found at the sides of the cervix uteri (Fig. 58, p. 61), behind the loop formed by the uterine artery (Fig. 57, p. 60). They cross the cervix at the distance of about ½ inch, from behind, at an acute angle, so as to come in front of and below it. On reaching the wall of the bladder they turn rather sharply inward, run for ½ inch in the wall, perforating it gradually, and open with a small longitudinal slit in the interior of the bladder. But their substance is continued from side to side as the *interureteric ligament*, a ridge that forms the base of the trigone.

In crossing the cervix the ureters lie outside and above the anterior part of the side wall of the vagina on a spot as large as the tip of the finger.

[1] The knowledge of the topography of the ureter has acquired special importance in regard to the extirpation of the uterus. The questions involved have been investigated by Polk and myself, separately and conjointly (Polk, *N. Y. Med. Jour.*, May, 1892, vol. xxxv. pp. 451–53; Garrigues, on "Gastro-elytrotomy," New York, Appleton, 1878, pp. 67–74, also *N. Y. Med. Jour.*, Nov., 1878); Garrigues, "Additional Remarks on Gastro-elytrotomy," *Amer. Jour. Obstet.*, 1883, vol. xvi. pp. 45–49).

During pregnancy the course of the ureters undergoes a great change. Its middle part, that which in the unimpregnated condition sinks down to the spine of the ischium, is lifted up, together with the broad ligaments. From the point where the ureter crosses the iliac arteries it goes forward, downward, and outward, lying immediately under the peritoneum, on the wall of the false pelvis. A little behind

FIG. 83.

The Course of the Ureters, from a woman fifty-seven years of age, with atrophic uterus, ½ natural size. Specimen drawn *in situ*. Ureters laid bare from the place where they cross the iliac vessels to the place where they pass under the broad ligaments. Bladder dissected from uterine neck and upper part of the vagina and drawn down in order to show the curve of the ureters and the trigone. The broad ligaments have been removed and the bladder cut in the median line, so as to show the inside of it: *a*, ureter; *b*, common iliac artery; *c*, external iliac artery; *d*, internal iliac artery; *e*, uterus (appendages cut off); *f*, bladder; *g*, site of vesical aperture of ureter on the inner surface of bladder (not visible); *h*, vesical aperture of urethra; *i*, base of trigone (interureteric ligament); *j*, incision in bladder; *k*, vagina.

the end of the transverse diameter of the pelvis the ureter dips down into the true pelvis, and goes in a curved line inward, forward, and downward till it reaches the bladder. In this way it passes under the broad ligaments, and in front of these it lies again immediately under the peritoneum. From the point where it opens into the bladder to the posterior surface of the pubis behind the spine is a distance of 3 inches. It will thus be seen that while the posterior part of the course of the ureter through the pelvis is lifted up to so high a level, the anterior end retains its position.

Structure.—The ureters have a fibrous coat, a muscular coat, with an outer circular and an inner longitudinal layer, and a mucous membrane, with a transition epithelium composed of an inner short layer, a middle columnar with long processes, and a deep layer of more round smaller cells (Fig. 84). The cells of the deeper layers resemble those in the deeper layers of the bladder epithelium very much. When not distended the mucous membrane forms longitudinal folds. It has no glands.

FIG. 84.

Epithelium of Pelvis of Kidney of man × 350 (Kölliker): *A*, single cells; *B*, the same, in situ; *a*, small flat cells; *b*, large flat cells; *c*, similar ones with bodies like nuclei in the interior; *d*, cylindrical and cone-shaped cells from the deeper layers; *e*, transitional forms.

Vessels and Nerves.—The ureters receive *arteries* from the renal, ovarian, internal iliac, and vesical arteries. The *veins* correspond to the arteries. The *lymphatics* lead to the lumbar glands. The *nerves* come from the sympathetic.

Function.—The ureters lead the urine from the kidneys to the bladder. In cases of extroversion of the bladder or of large vesico-vaginal fistulæ, it can be seen how the urine is spurted out with pretty regular intermissions. That the ureters may become much distended by accumulated urine may be concluded from the fact that if the bladder has been overfilled and is emptied, fresh desire for emptying it recurs soon, and gives issue to a disproportionately large amount of urine. The ureters are kept closed by the elastic tension in the muscle-fibres which surround them, while they perforate the bladder, which tension is overcome when the pressure reaches a certain point.

THE RECTUM.

The rectum is the lowest division of the intestine, extending from the colon to the anus. Although the word "rectum" means straight, the intestine curves and bends so as to form three distinct parts. It enters the pelvis in front of the left ilio-sacral articulation (Fig. 53, p. 56), goes first downward, backward, and inward, in front of the third or fourth sacral vertebra, to the median line; here it turns forward and lies in contact with the cervix and the vagina (Fig. 50, p. 54); finally, an inch from its end it turns rather sharply downward and backward at a right angle to the axis of the vagina. This latter part is called the *anal canal* (Figs. 50, p. 54, and 34, p. 42), and is the narrowest por-

FIG. 85.

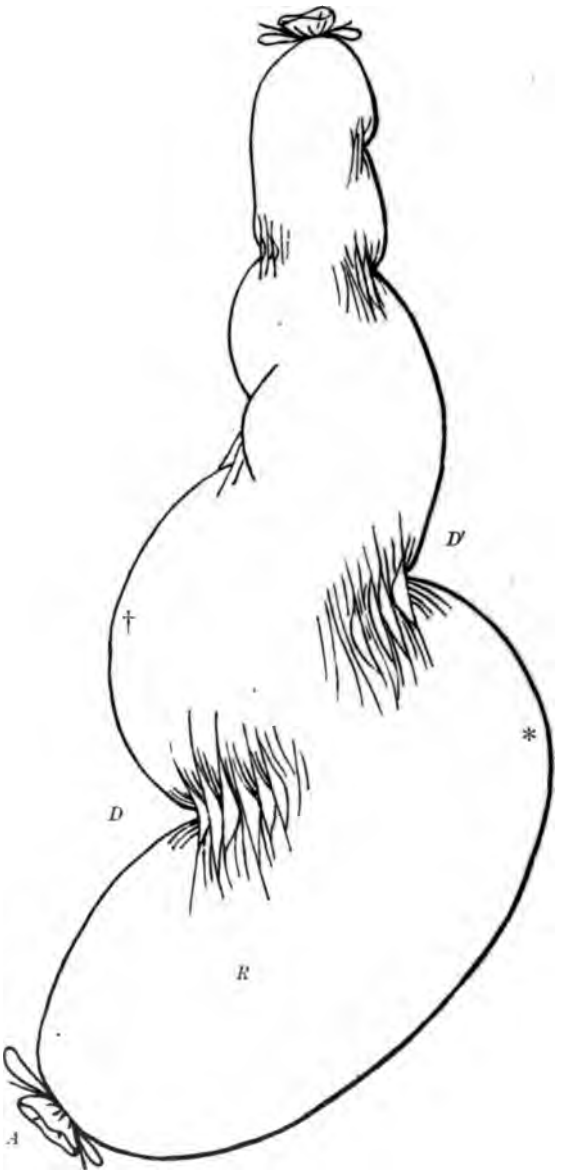

Rectum inflated with Air (Chadwick): *DD'*, anterior and posterior segments of the superior detrusor ficium (so-called third sphincter); *R*, rectal ampulla; † and * the same points so marked in Fig. 88.

tion, while the part situated immediately above it is the widest, and is called the *rectal ampulla*. From here the gut tapers gradually to the upper end (Fig. 85). It is about 8 inches long, and when empty

FIG. 86.

The Lower End of the Rectum in Vertical Section (Ruedinger): 1, rectal mucous membrane; 2, line of separation between mucous membrane and skin of buttock; 3, fat; 4, levator ani muscle; 5, 6, external sphincter; 7, internal sphincter; 8, 9, longitudinal muscular fibres interlacing with those of sphincter: 10, filiform terminations of longitudinal fibres; 11, circular fibres; 12, 13, longitudinal fibres of muscularis mucosæ.

about 1½ inches from edge to edge, but capable of such a distention that it sometimes nearly fills the pelvic cavity. The way in which it collapses when empty depends probably on the condition of the vagina and the bladder. If these are empty, the rectum collapses from side to side (Fig. 35, p. 43), but if the other cavities are distended, it becomes compressed in an antero-posterior direction.

Structure.—The rectum is composed of a peritoneal coat, a muscular coat, and a mucous membrane. In regard to its relation to the peritoneum, it may be divided into three parts: the upper is completely covered, and has even sometimes a *mesorectum;* the middle is cov-

FIG. 87.

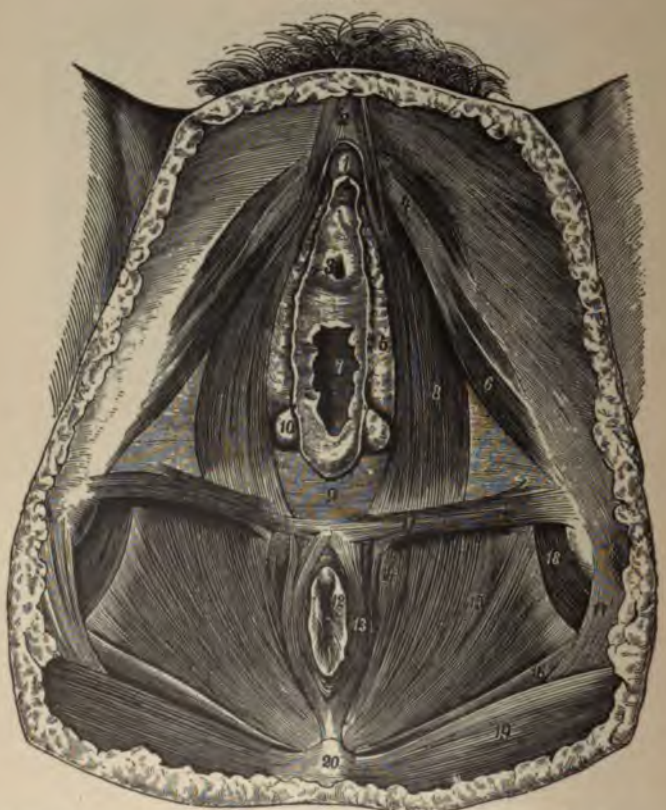

Muscles of the Perineum (Breisky): 1, glans clitoridis; 2, corpus clitoridis; 3, meatus urinarius; 4, tendon of ischio-cavernosus muscle; 5, bulb; 6, ischio-cavernosus muscle; 7, vaginal entrance; 8, sphincter vaginæ or bulbo-cavernosus muscle; 9, fossa navicularis; 10, Bartholin's gland; 11, superficial transversus perinæi muscle; 12, anus; 13, sphincter ani externus; 14, 15, levator ani muscle; 16, coccygeus muscle; 17, great sacro-sciatic ligament; 18, obturator internus muscle; 19, glutæus maximus; 20, os coccygis.

ered with peritoneum in front only (Douglas's pouch); and the third has no peritoneal covering at all. The last part measures $1\frac{1}{2}$ to 2 inches from the anal opening.

The muscular coat has an outer longitudinal and an inner circular layer. The longitudinal layer is spread all over, and does not form such bands as on the colon. Besides this, the mucous membrane con-

tains a layer of longitudinal fibres. At the lower end all the longitudinal fibres are intimately interlaced with certain other muscles that are attached to the rectum—the *levator ani muscle*, the *external sphincter ani muscle*, and the *internal sphincter ani muscle*—and can be followed down through them to the skin (Fig. 86).

The *external sphincter ani muscle* (Figs. 87, 13) is an elliptic layer of striped muscular fibres which surround the anal opening and lie directly under the skin. Behind it is fastened with a tendon to the tip of the coccyx; in front it blends with the transversus perinei and sphincter vaginæ muscles. It is the true voluntary sphincter by which fæces and gases are kept back.

The *internal sphincter ani muscle* is only a thicker part of the circular layer of the rectum situated inside of the external sphincter, and consists of unstriped muscle-fibres, with a considerable admixture of striped fibres. It gets fibres from the deep layer of the deep perineal fascia, from the superficial transversus perinei, and from the bulbocavernosus muscles. It surrounds the anal canal, and is an inch high. It contracts and relaxes by reflex action, and is not subject to the will.

The *levator ani muscle* (Figs, 87, 14, 15) forms an important part of the pelvic floor, and will be considered under that heading.

The mucous membrane shows numerous folds. In the lower part of the rectum these have a longitudinal direction, and are called *the columns of Morgagni*, and the depressions between them are called *the sinuses of Morgagni*. In the upper part transverse folds preponderate. Three of these (more rarely only two or one), situated within reach of the examining finger, are particularly developed, and called *Houston's valves*. Commonly one of them is placed on the anterior wall, about 2 inches above the anus; the others an inch higher up, on the posterior wall. They are semicircular, and, the transverse muscles extending from one to the other (Fig. 88), they form together a kind of circular valve, which ordinarily lies below the accumulated feces. This apparatus has been described as a *third sphincter*, but is, according to Chadwick, a detrusor; that is, it serves to expel the feces.[1]

The mucous membrane is covered with columnar epithelium and has many glandular pouches. The transition from the skin to the mucous membrane is distinctly marked by a so-called *white line*.

Relations.—The rectum lies in contact outside with the left ureter and left internal iliac artery. It has the left ovary in front, and rests on the pyriformis muscle and the sacral plexus. It is bound to the sacrum by the mesorectum in the upper part, and by fibrous connective tissue and fat lower down. It lies in the gap left between the

[1] J. R. Chadwick, "The Functions of the Anal Sphincters, so-called, and the Act of Defecation," *Trans. Am. Gyn. Soc.*, ii. pp. 43–56. I have, however, frequently palpated these folds on patients, and do not find that it causes any expulsive effort.

sacro-uterine ligaments. Loops of the small intestine lie between its upper part and the uterus, unless the latter be pushed far back by an overfilled bladder. In the narrow lower part of Douglas's pouch there are, as a rule, no intestines; the rectum hugs the cervix and lies close up to the vagina. The anal canal forms the posterior wall

FIG. 88.

Rectum cut open longitudinally, and the mucous membrane dissected off, so as to show the circular muscular fibres (Chadwick): *DD'*, anterior and posterior segment of the superior detrusor fæcium (or third sphincter); *S*, inferior detrusor fæcium (or internal sphincter); *A*, anus; † and * correspond to the same points in Fig. 85. This drawing shows the muscular fibres passing from the anterior to the posterior segment of the superior detrusor, by the action of which they may be approximated to each other.

of the perineal body, which separates it from the entrance to the vagina and the vulva.

Vessels and Nerves.—The rectum has an abundant blood-supply. The *arteries* are the *superior hemorrhoidal* from the inferior mesenteric, the *middle hemorrhoidal* from the internal iliac or one of its branches, a branch of the *middle sacral*, and the *inferior hemorrhoidal*

from the internal pudic. The *veins* form a rich plexus, and lead the blood through the inferior and middle hemorrhoidal to the *internal iliac*, and through the superior hemorrhoidal to the superior mesenteric, a branch of the *vena porta*. The *lymphatics* go to the sacral

FIG. 89.

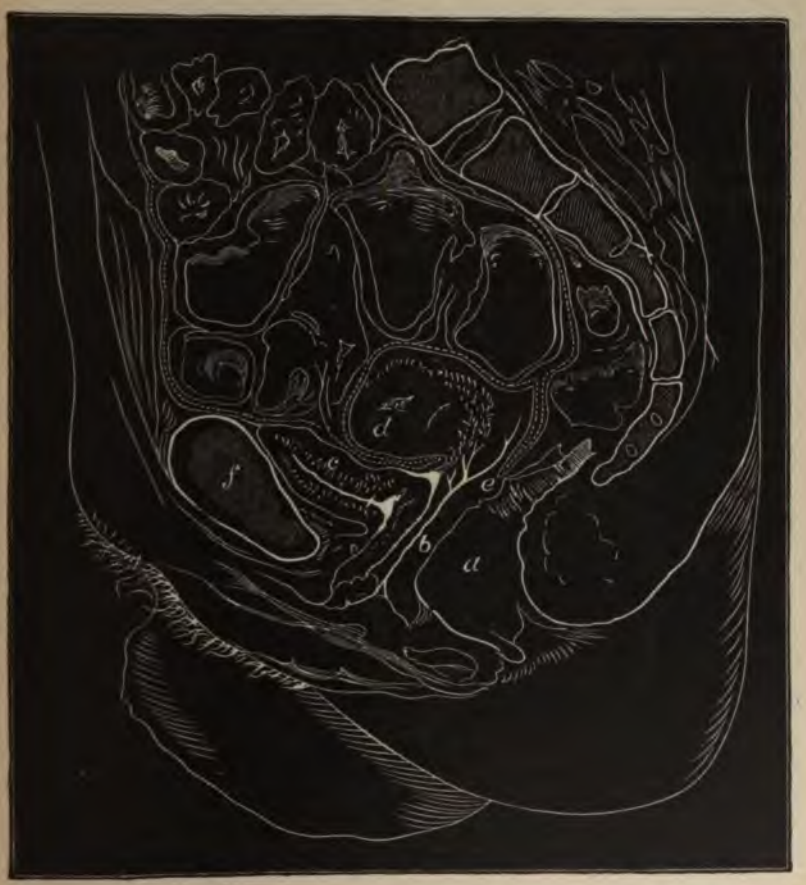

Pelvic Peritoneum with Empty Bladder; mesial section of frozen body, ½ (Fürst). The dotted line indicates the peritoneum; *a*, rectum; *b*, vagina; *c*, bladder; *d*, uterus; *e*, below pouch of Douglas; *f*, symphysis pubis.

glands. The *nerves* come partly from the sympathetic nerve (the hypogastric plexus), partly from the cerebro-spinal system (sacral plexus).

Function.—The rectum is a receptacle for the feces, and expels

them by the combined action of its circular and longitudinal fibres, the first contracting above and relaxing below the mass to be removed, and the latter preventing sacculation, straightening the canal, and pulling the relaxed part of the intestine up over the fecal mass. The internal sphincter can, by its contraction, push the mucous membrane out through the anus, and thus becomes an expulsive muscle, as is very apparent in the horse. The mucous membrane is capable of absorption, which explains many bad effects of constipation, and is utilized for the administration of drugs and artificial alimentation.

The Pelvic Peritoneum.

The pelvic peritoneum is a continuation of the abdominal peritoneum, and covers the organs in the pelvis more or less completely.

Fig. 90.

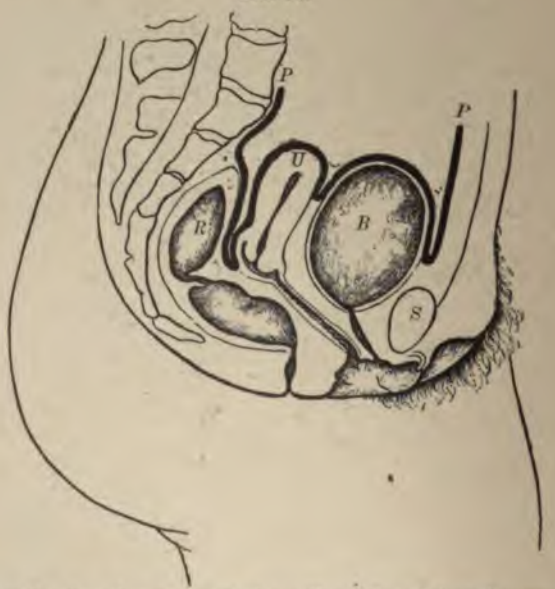

Diagram designed to show the antero-posterior outline of the pelvic peritoneum in the mesial pelvic plane, with distended bladder (Ranney): *PP*, peritoneum; *R*, rectum; *U*, uterus; *B*, bladder; *S*, symphysis pubis. The vesico-abdominal, the vesico-uterine, and Douglas's pouch are made very apparent.

It has been likened to a cloth which is being lifted up by pushing the organs from below up under it, by which they themselves acquire a covering and certain folds and pouches are formed. Thus the reader may imagine that the peritoneum is represented by a sheet of thin muslin, and that an apple representing the bladder, a pear representing the uterus, and a banana representing the rectum are placed under

it. Beginning in front, the peritoneum passes from the anterior abdominal wall at the upper end of the symphysis pubis over on the top of the bladder (Fig. 89), covers its posterior wall down to the level of the internal os of the uterus, and its sides behind the obliterated hypogastric artery. When the bladder is much distended it rises up into the abdominal cavity, and the peritoneum forms a pouch between the abdominal wall and the bladder (the *vesico-abdominal pouch*), the deepest point of which lies an inch above the symphysis (Fig. 90).

From the posterior surface of the bladder the peritoneum passes over on the anterior wall of the uterus, covering it entirely above the cervix, and leaving a pouch between the two called the *vesico-uterine pouch*. When the bladder is over-distended, the bottom of this pouch is raised a little, as represented in the figure. Next, the peritoneum covers the whole posterior surface of the uterus, and goes even generally an inch down behind the posterior wall of the vagina, and passes then over on the rectum, leaving a pouch between the two called *Douglas's pouch* or the *recto-uterine pouch*. This pouch varies very much in depth, sometimes ending at the posterior utero-vaginal junction, and in other cases extending down as far as the entrance of the vagina. Next, the peritoneum covers the anterior surface of the middle portion of the rectum, surrounds the whole upper portion of the same, and passes over on the sacrum as the meso-rectum.

From the sides of the uterus the peritoneum passes out to the wall of the pelvis, forming the broad ligaments, which cover the Fallopian tubes, the round ligaments, the ovarian ligaments, and the attached border of the ovaries.

The uterus and the broad ligaments together form a partition which divides the pelvic cavity into an anterior inferior and a posterior superior part (Fig. 52, p. 55). The anterior compartment as a whole is called the *utero-abdominal pouch*. In it we notice the utero-vesical and the round ligaments of the uterus. It is filled by the bladder, and, when this is empty, by loops of the small intestine. Its lateral parts, where the entrance is to the obturator canal, have been designated as the *obturator pouches*, or *paravesical pouches* (Fig. 91, II). When the bladder is moderately filled, the loops of the small intestine are found in the upper part of the utero-vesical pouch.

The posterior compartment may be subdivided into a central deep part—*i. e.* Douglas's pouch—and two shallower lateral parts called *para-uterine pouches* (Fig. 91, I). The bottom of the latter has been designated particularly as the *retro-ovarian shelves* (Polk). The boundary-line between these three parts is the sacro-uterine ligaments. On the side wall of the para-uterine pouch is seen the ureter running under the peritoneum (Fig. 53, p. 56). The ovaries project into

them, and they contain loops of the small intestine. These are likewise found in the upper part of Douglas's pouch.

About the elevation of the peritoneum during pregnancy, see the description of the broad ligaments and the ureters, pp. 57 and 82.) The para-uterine pouch is lifted up to the pelvic brim; the para-

FIG. 91.

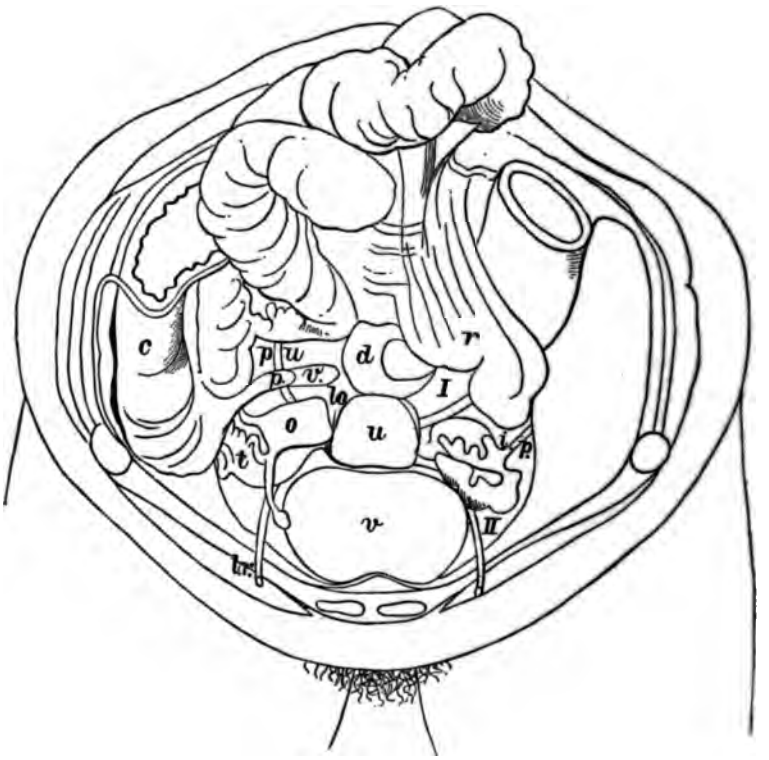

Position of Viscera at the Pelvic Brim (Hasse): *v*, bladder; *u*, uterus; *t*, tube; *o*, ovary; *c*, cæcum; *r*, rectum; *lr*, round ligament; *pv*, appendix vermiformis; *d*, Douglas's pouch; *pu*, fold covering ureter; I, para-uterine pouch; II, para-vesical, or obturator pouch; *ip*, infundibulo-pelvic ligament.

vesical pouch is only lifted in its posterior part; and Douglas's pouch is not interfered with.

The parts that have no peritoneal covering are the anterior wall of the bladder, the anterior surface and the sides of the cervix uteri, the whole lower part of the rectum, and the posterior portion of the middle part of the same.

Function.—The function of the peritoneum is to allow free, smooth movement between the viscera. It presents a large surface, with great power of absorption.

The Pelvic Connective Tissue.

The dense connective tissue forming true ligaments or fasciæ has already been considered, or will be considered in describing the pelvic floor. Here we have only in view the loose connective tissue, which is found everywhere underlying the peritoneum in larger or smaller quantity, and forming one continuous layer, which is a continuation of the corresponding layer of the adjacent parts. In some places it contains fat. Just above the symphysis pubis, behind the linea alba, is found a considerable layer of adipose tissue, the *preperitoneal fat*, which constitutes an important landmark in the performance of lapa-

Fig. 92.

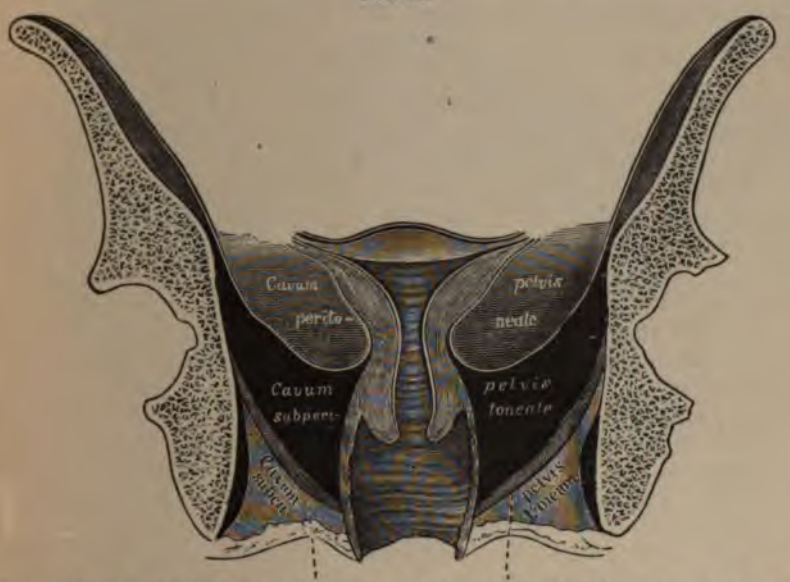

Coronal Section of Pelvis, showing the three cavities of the pelvis: the peritoneal, the subperitoneal, and the subcutaneous (Luschka).

rotomy. It is continued behind the symphysis as *retro-pubic fat* (Fig. 89), and lies here in front of the bladder. Between the base of the bladder and the vagina the connective tissue is rather tight. On the posterior surface of the vagina there is a very loose layer. A large mass is found on both sides of the cervix uteri (Fig. 92), forming under the broad ligaments the parametria, which are united by a thinner portion in front and behind. On the body of the uterus there is only very short connective tissue without fat, but during pregnancy it becomes much looser and increases in bulk. The rectum and the vagina are again imbedded in considerable masses of fatty connective

tissue. At the posterior fornix the distance between the vagina and the peritoneal cavity does not exceed one-third of an inch. From the uterus and the parametrium a thin layer extends between the two layers of the peritoneum which form the broad ligaments, and is here mixed with many elastic fibers and unstriped muscle-fibers. From here it is again continued up into the iliac fossæ and the lumbar region, and forward and backward along the pelvic wall.

The chief bulk of the subperitoneal connective tissue forms a funnel-shaped mass around the cervix and downward around the vagina to the insertion of the levator ani muscle (see Figs. 92 and 97).

Function.—The function of the connective tissue is to fill out all free spaces between the organs, to furnish a soft padding around organs of very changeable size, and to be the carrier of vessels and nerves.

The Pelvic Floor.

The pelvic cavity may be divided into three well-marked subdivisions: *the pelvi-peritoneal cavity, the subperitoneal space, and the subcutaneous space* (Fig. 92).[1]

Of these we have already described the first and the second. The boundary-line between the second and the third is a muscular diaphragm—the levator ani muscle—which is covered above and below with a fascia, and has openings for the passage of the urethra, the vagina, and the rectum.

We will now consider what remains to be studied under the three headings—the *pelvic fascia*, the *pelvic diaphragm*, and the *perineal region*.

I. *The pelvic fascia* (Fig. 93) is a continuation of the iliac fascia. It is attached to the iliac part of the ilio-pectineal line and to an oblique line on the posterior surface of the body of the pubic bone, extending from the upper and inner part of the obturator foramen to a point a little below the symphysis. At the upper end of the said foramen it leaves an opening free for the obturator canal. It descends on the inside of the bodies of the ilium and ischium, about halfway down the pelvic wall, where a strong sinewy cord, the so-called *tendinous arch*, extends from the spine of the ischium to the pubic bone just inside of the obturator canal (Fig. 94). This part of the pelvic fascia covers the obturator internus muscle, and is also called the *obturator fascia*. It sends a thinner prolongation backward, covering the pyriformis muscle, and called the *pyriformis fascia*. At the tendinous arch the pelvic fascia is split into two layers, an upper layer called the *vesico-rectal fascia*, which bends inward over the levator ani muscle, and a lower layer, which continues to follow

[1] The distinction was made by Luschka, but his names, cavum peritoneale, cavum subperitoneale, and cavum subcutaneum are bewildering, the two latter "cavities" being filled with solid tissue.

the obturator internus muscle down to the inner edge of the ischio-pubic branches, and keeps the name of obturator fascia. Just below the insertion of the levator ani muscle this fascia gives off another investment of this muscle, called the *anal fascia.* Together with that part of the obturator fascia situated below the tendinous arch it forms the lining of the ischio-rectal fossa.

FIG. 93.

Fascia of Pelvic Floor (Savage): *B*, bladder: *V*, vagina; *R*, rectum; *P*, symphysis pubis; *S*, sacrum; *a*, fascia covering psoas muscle; *b*, obturator fascia; *c*, tendinous arch; *d*, reflection of fascia on to the rectum, vagina, and bladder; *e*, posterior portion of fascia covering sacral vessels and nerves; *f*, iliac fascia covering iliac vessels; *g*, gluteal vessels; *h*, sciatic vessels; *i*, internal pudic vessels; *k*, obturator vessels.

From its insertion on the pelvic wall the vesico-rectal fascia goes inward and downward, covering the upper surface of the levator ani muscle, to the base of the bladder, the vagina, and the rectum. In front, near the middle line, a thicker, narrow part of this fascia forms the *anterior true ligaments of the bladder*, or the *pubo-vesical ligaments* (see p. 80).

Between the two ligaments the fascia is thin and depressed. Outside of this ligament lies another, thicker band, the *lateral true ligament of the bladder*, which is attached to the side of the bladder.

From the outlet surface of the vesico-rectal fascia a prolongation follows down with the vagina, surrounding it with a sheath that lies outside of the venous plexus and forms a strong ring around the vaginal entrance, where it coalesces with the deep perineal fascia.

From the ischial spine goes a band to the side of the rectum, which is called the ligament of the rectum, and prevents too great lateral movement of the intestine. The fascia follows the rectum down as a sheath, which gradually disappears near the anus. From the place

FIG. 58.

The levator ani: appearance when the pelvic outlet is looked at squarely. The cut ends projecting inward are those fibres which run into the recto-vaginal septum (Dickenson).

where it strikes the rectum it is continued over on the pyriformis muscle as the pyriformis fascia.

In some parts a double layer of fascia, with intervening loose connective tissue, serves to allow a sliding movement of one part on the other. Thus the fascia forms a pouch between the base of the bladder and the neck of the womb, extending an inch lower down than the corresponding vesico-uterine pouch of the peritoneum. Between the vagina and the rectum a similar pouch is found which descends nearly to the vaginal entrance.

In its totality the pelvic fascia forms a very irregular fibrous layer under the peritoneal cavity and the underlying loose connective tissue, the function of which is to strengthen the pelvic floor and give support to the organs found in it, especially the bladder, the vagina, and the rectum.

II. *The Pelvic Diaphragm* (Fig. 94).—Under the pelvic fascia, which forms a fibrous layer of the pelvic floor, is found a horseshoe-shaped muscular expansion, which is open in front, is attached all around to the wall of the pelvis, and forms a double loop behind the vagina and the rectum. It is generally described as *two* muscles, the *levator ani* and the *coccygeus*, but they touch each other with their edges, so that one is a continuation of the other, and sometimes they are even grown together. This diaphragm has also been described as composed of *three* muscles: the *pubo-coccygeus*, the *obturato-coccygeus*, and the *ischio-coccygeus* (Savage), but not one of the fibers that start from the pubes are inserted on the coccyx.

The *levator ani muscle* takes its origin from an oblique line on the posterior surface of the body of the pubic bone, running from the upper end of the obturator foramen to the lower end of the symphysis pubis, just above and inside of the insertion of the obturator internus muscle (*M. pubo-coccygeus*). It starts half an inch from the middle line of the symphysis. Its other bony origin is a small circle just in front of the base of the ischial spine. Between these two points it springs from the tendinous arch of the pelvic fascia (*M. obturato-coccygeus*).

The pubic portion (*M. pubo-coccygeus*) goes backward and inward, is in connection with the deep layer of the triangular ligament, and is attached to the urethra. It crosses the vagina, and is united to it by strong connective-tissue attachments, besides that the longitudinal fibers of the vagina on its lateral aspects are interwoven with those of the levator. Some loops go from side to side between the vagina and the rectum, but the greater part go behind the rectum, forming loops without intermediate tendon. They hug the concavity of the end-curve of the rectum and support it from below (Fig. 95). The muscle goes in between the external and internal sphincter, and intermingles with both of them, as well as with the longitudinal fibers of the rectum. Some of the fibers are inserted on the thin mesial aponeurosis, extending from the coccyx to the anus (*raphe ano-coccygea*).

The fascial portion of the levator ani muscle (*M. obturato-coccygeus*) goes with convergent fibers to the rectum and the coccyx. It takes part with the pubic portion in the formation of a loop behind the rectum, and another part of it is inserted on the fourth coccygeal vertebra.

The *ischio-coccygeal muscle* (= *the coccygeus*) forms likewise a triangle, but the base of this triangle is turned inward. It takes its origin on the spine of the ischium and the lesser sacro-sciatic ligament, and is inserted on the side of the upper part of the coccyx and the last two vertebræ of the sacrum.

Function.—The pelvic diaphragm strengthens the pelvic floor; in

connection with the two fasciæ that cover its upper and lower surface (the vesico-rectal and the anal fasciæ) it forms a strong sheet on which rest the uterus and the bladder. It is the antagonist of the thoracic diaphragm, being relaxed under inspiration and contracting under expiration. By inserting a Sims speculum it is easy to see

FIG. 95.

Side View of the Levator Ani (L) after Removal of the Ischium. The lower bundles are the strong and heavy ones. The sphincter ani is shown surrounding the anus, and the coccygeus (C) is faintly indicated (Luschka-Dickenson).

the rhythmical movement synchronous with the respiration. The anterior wall of the vagina goes downward and backward under inspiration, and then upward and forward during exspiration.

The pelvic diaphragm lifts the rectum up during the act of defeca-

tion, and draws the anus forward in the direction of the symphysis. It exercises a similar function toward the vagina during childbirth by pulling it upward and pushing the child forward, so as to make it turn round the pubic arch. By means of the loops that go between the vagina and the rectum it becomes a sphincter vaginæ, which can produce coarctation of the vaginal entrance. It draws the coccyx forward.

III. *The Perineal Region.*—The perineal region is a somewhat rhomboid space bounded by the symphysis and the descending ramus of the pubic bone, the ascending ramus and the tuberosity of the ischium, the lower edge of the gluteus maximus muscle, and the tip of the coccyx. In depth it comprises all the tissue lying within these boundary-lines between the surface and the pelvic diaphragm. It is shorter and broader than in man, and contains more fat. It may be subdivided by a line drawn just in front of the tuberosity of the

FIG. 96.

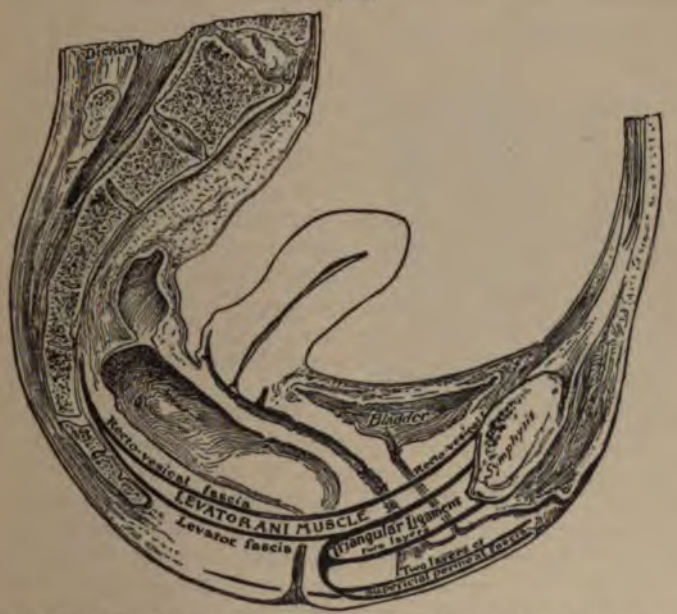

Diagram of the Fascia of the Pelvic Floor in mesial section, to show how the levator ani muscle is backed by strong and dense sheets of fibrous tissue (Dickenson): 1, superficial perineal fascia, outer layer (this we call simply subcutaneous adipose tissue); 2, superficial perineal fascia, inner layer (our superficial perineal fascia); 3, triangular ligament, or deep perineal fascia, outer layer; 4, triangular ligament, or deep perineal fascia, inner layer; 5, vesico-rectal (part of pelvic) fascia.

ischium on either side into two triangles, an anterior, or *uro-genital region*, and a posterior, or *anal region*.

In the anterior triangle we distinguish the following layers:
Skin;
Adipose tissue;
Superficial perineal fascia;
Deep perineal fascia divided into two layers;
Anterior continuation of ischio-rectal fossa;
Levator ani muscle;
Vesico-rectal fascia (*i. e.* part of pelvic fascia).

In the posterior triangle are found the following layers:
Skin;
Adipose tissue entering and filling ischio-rectal fossa;
Anal fascia inside, lower part of obturator fascia outside;
Levator ani muscle inside, obturator muscle outside;
Vesico-rectal fascia.

A. *The Perineal Fascia and Ligaments.*—The uro-genital region has under the skin a layer of adipose tissue (Fig. 96), which is a continuation of the similar layer on the surrounding parts (Fig. 97). Under that layer is found a sheet of dense connective tissue called the *superficial perineal fascia.* It is fastened in front and on the sides to the edge of the rami of the pubis and ischium, and behind it turns over the superficial transversus perinæi muscle, and is here grown together with the deep perineal fascia. In its anterior part it is grown together with Broca's pouch (p. 37), and at the ramus of the ischium with the obturator fascia.

FIG. 97.

Transverse Section of Pelvis through Axis of Vagina (Savage): V, vagina, showing posterior wall; O, ischio-rectal fossa filled with fat; I, ischial tuberosity; B, peritoneal cavity; D, recto-vesical fascia covering upper surface of levator ani muscle; C, anal fascia covering lower surface of levator ani; N, obturator fascia; P, posterior aponeurosis of perineal septum, or the deep layer of the triangular ligament; M, anterior aponeurosis of the same, or superficial layer of the triangular ligament; S, superficial perineal fascia; 1, cross-section of right crus clitoridis and erector clitoridis muscle; 2, superficial transversus perinæi muscle; 3, bulb; 4, deep perineal muscles.

The *deep perineal fascia,* also called the *triangular ligament of the urethra,* has two layers—an anterior, or superficial layer, and a posterior, or deep layer. The superficial layer is at the sides attached to the rami of the pubes and ischium, in front to a strong transverse ligament called the *transverse ligament of the pelvis* (Henle), which lies immediately under and behind the *subpubic ligament,* an opening for the dorsal vein of the clitoris separating the two. Behind it is grown together

with the superficial perineal fascia and with the deep layer of the deep fascia. The deep layer of the deep fascia is likewise fastened to the rami of the pubes and the ischium, where it joins the obturator fascia (p. 94), and covers the anterior part of the lower surface of the levator ani muscle. At its anterior attachment it is contiguous with the vesico-rectal fascia. Behind it is continued as a dense fascial sheet covering the lower surface of the levator ani muscle (the anal fascia).

The deep perineal fascia is perforated by the urethra and the vagina.

Where the superficial perineal fascia and the two layers of the deep perineal fascia come together, at the posterior margin of the superficial transversus perinæi muscle, they are fortified by a strong transverse fibrous band, the *ischio-perineal ligament*, which is inserted on the ramus of the ischium, just in front of the tuberosity, and forms the boundary-line between the uro-genital and the anal regions. It is a strong cross-beam, which by its connection with all the adjacent parts forms the chief support of the pelvic floor. Together with the posterior end of the superficial and deep perineal fasciæ it forms a partition between the anterior and posterior part of the perineal region, called the *transverse perineal septum*.

In the anal region the skin is darker and has large sebaceous glands. The anus forms an opening at the deepest point of the sulcus between the nates. It is closed from side to side so as to show a line of closure in the antero-posterior direction (Fig. 87, 12). It is surrounded by radiating folds of the skin, and often hair. In women the raphe between the anus and the vulva (*perineal raphe*) is often effaced, and has sometimes a whitish color, much like a cicatrix, which has to be borne in mind in answering the question whether a subject for examination has given birth to a child or not. Under the skin is found a thick layer of adipose tissue. There is no special superficial fascia, and the deep perineal fascia does not extend so far back.

Between the rectum and the ischium is found a space on either side which is called the *ischio-rectal fossa*, and has the shape of an irregular triangular pyramid. Its top is at the spine of the ischium; the inner wall is formed by the levator ani muscle, covered by the anal fascia, the outer by the obturator internus muscle, covered by the obturator fascia, below the line of demarkation between that fascia and the vesico-rectal fascia covering the upper surface of the levator ani muscle (p. 94). Its entrance from below is bounded by the lower edge of the gluteus maximus and the greater sacro-sciatic ligament behind, the transversus perinæi superficialis muscle in front, and the external sphincter ani on the inner side. Posteriorly these two spaces communicate by means of the loose adipose tissue behind the rectum and pelvic fascia. In front the fossa is limited by the line of junction of the superficial and deep perineal fasciæ. Here it be-

comes narrow, but may be followed above the deep fascia of the perineum along the origin of the levator ani muscle. It appears triangular both on perpendicular and horizontal section (Figs. 92 and 97).

The above-mentioned fasciæ constitute a frame-work in which lie imbedded muscles, blood-vessels, nerves, and other organs.

B. Perineal Muscles.—In the uro-genital triangle we find a superficial layer of three pairs of muscles (Fig. 87, p. 86) situated between the

FIG. 98.

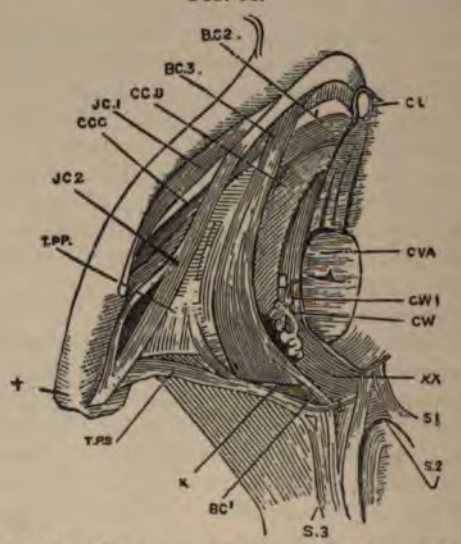

Perineal Muscles (Henle): *CL*, clitoris turned over to the left side; *CCC*, corpus cavernosum clitoridis; *CCU*, corpus cavernosum urethræ, or vestibulo-vaginal bulb; *CVA*, anterior column of vagina; *CW*, vulvo-vaginal gland; *BC*, 1, 2, 3, bulbo-cavernosus muscle; *JC*, 1, 2, ischio-cavernosus muscle; *TPS*, transversus perinæi superficialis; *TPP*, transversus perinæi profundus muscle; *S*, 1, 2, 3, sphincter ani externus; ××, layer of smooth muscle-fibers between vagina and rectum; +, limit of pubes and ischium.

superficial perineal fascia and the anterior layer of the deep perineal fascia—namely, the *ischio-cavernosus*, or *erector clitoridis muscle;* the *bulbo-cavernosus*, or *sphincter vaginæ muscle;* and the *superficial transversus perinæi muscle.*

The *ischio-cavernosus muscle* is a long, slender muscle which arises by two slips on the inside of the tuberosity of the ischium and the ascending ramus of the same (Fig. 98). It covers the corpus cavernosum of the clitoris, and is inserted with a tendinous expansion on the free part of the clitoris. Its function in the female is insignificant compared with that in the other sex.

The *bulbo-cavernosus muscle* receives some fibers from the external sphincter ani and levator ani and the superficial transversus perinæi

muscles, and others originate on the ischio-perineal ligament and neighboring tendinous tissue. The posterior ends are united by organic muscular fibers. It goes forward, outside of the vulvo-vaginal bulb, and splits up into three tendons, inserted one on the posterior aspect of the bulb, another on the mucous membrane between the clitoris and the urethra, and the third on the lower surface of the clitoris. It compresses the bulb, and thus aids in the erection of the clitoris. It may squeeze out the secretion accumulated in Bartholin's gland. The rôle of sphincter it divides with the constrictor vaginæ, and, above all, the levator ani muscle.

The *superficial transversus perinæi muscle* originates from the inside of the tuberosity of the ischium, behind the ischio-cavernosus muscle, goes across the perineal region, and is inserted in the transverse septum of the perineum in the angle between the bulbo-cavernosus and the sphincter ani externus, intermingling with both. In many women its course is more forward, so that it does not reach the perineal body, but is fastened to the outer edge of the bulbo-cavernosus muscle. When it has its normal insertion it helps to steady the perineal body and push the presenting part of the child forward toward the pubic arch during parturition. With its abnormal insertion it can only help to open the vaginal entrance.

In the anal region we find immediately under the skin surrounding the anus the *external sphincter ani muscle* (p. 87).

Under the tendon of the sphincter ani muscle, between it and the levator ani muscle, in front of the tip of the coccyx, lies the so-called *coccygeal gland*, a small body of the size of a pea, which seems to be a remnant of a more developed middle sacral artery, such as it is in animals with a tail.[1] It consists of round or tubuliform vesicles formed by a structureless membrane, inside of which are found cells. The whole is surrounded by a capsule of connective tissue, and receives numerous branches from the middle sacral artery and the sympathetic nerve, especially the coccygeal ganglion.

The deep muscles in the uro-genital region are not well developed or clearly separated from one another. They are, therefore, enumerated and described differently by different anatomists. Most commonly the following three are recognized: the *constrictor urethræ*, the *deep transversus perinæi*, and the *constrictor vaginæ muscles*.[2] They are all situated between the two layers of the deep perineal fascia.

The *constrictor urethræ*, or *compressor urethræ*, or *Guthrie's muscle*,

[1] An interesting article on this subject, illustrated with figures, was published by Augustus C. Bernay of St. Louis in the *Medical Brief*, Nov., 1887, vol. xv. p. 419.

[2] Some describe a *depressor urethræ* (or *Jarjavay's muscle*), a transverse muscle joining the constrictor from below and going from side to side over the urethra, and a *transversus urethræ muscle*, coming from above and inserted on the upper surface of the same. They are probably only parts of the *constrictor urethræ*.

consists of transverse fibers arising from the ischio-pubic rami and both layers of the deep perineal fascia, and crossing from side to side above and below the urethra, for which they form an upper sphincter (p. 76).

The *deep transversus perinæi muscle* arises from the ramus of the ischium just behind the constrictor urethræ, and goes horizontally to the side of the vagina. By some it is merely regarded as the posterior fibers of the constrictor. It helps to steady the vagina.

The *constrictor vaginæ muscle* consists of a few fibers which arise from the transverse septum of the perineum, and encircle the vaginal entrance as a sphincter. Thus the deep transversus and the constrictor vaginæ correspond to the superficial transversus and the bulbo-cavernosus of the superficial layer.

In the anal region we have the *internal sphincter ani* (p. 87) and the *levator ani*, inclusive of the *ischio-coccygeus* (p. 97). The anterior part of the levator ani lies immediately on the deep layer of the deep perineal fascia.

C. *The Perineal Body.*—The name of perineal body has been given to the tissue comprised between the rectum and the genital canal, below the point where the former turns backward (p. 83). Much diversity obtains among authors about its shape—a divergence of opinion easily accounted for when we notice how different its shape appears on sagittal section (Figs. 34, 48, 89). Sometimes the whole space between the rectum and the vagina up to the cervix uteri forms one triangular surface. In other cases this space is easily distinguishable into an upper narrow and a lower broad part, the latter alone deserving the name of perineal body; but this body, again, appears with very different forms, and differs in extension upward. Sometimes the whole body lies below the hymen; in other cases it extends more or less up behind the vagina. The shape is sometimes nearly quadrangular, with one surface to the skin, one to the rectum, one to the vulva, and one to the vagina. In others it has the shape of the quadrant of a circle; in others, again, that of the receiver of a retort, the neck of which is formed by the narrow part between the vagina and the rectum. When we take into consideration that all the parts concerned consist of more or less soft tissue, this great diversity of form is easily understood.

The perineal body is composed of the posterior ends of the bulbo-cavernosi muscles, the organic muscular fibers uniting them behind, fibers belonging to the superficial transversus perinæi, the external and internal sphincter ani, and the levator ani muscles, the ischio-perineal ligament, the posterior part of the superficial and deep perineal fasciæ, the anal fascia, and adipose tissue. It is covered below by the skin lying between the anus and the rima pudendi; behind by the rectal mucous membrane; above and in front by the

mucous membrane of the vulva and sometimes of the vagina. It has no definite lateral limits, unless we arbitrarily will suppose it continued to the tuberosity of the ischium. The cutaneous surface is shorter than in man. It measures ½ to 1 inch in length, while the distance from the anus to the entrance of the vagina (p. 43), the true length of the perineal body, is about 1¾ inches. According to what has just been said about its upper limit, no definite height can be ascribed to it.

Small as this body is, it is of great importance by forming the centre of the whole perineal region, where muscles, fasciæ, and ligaments come together. They being fastened to the surrounding bones, the perineal body becomes the chief support of the whole pelvic floor. Especially it keeps the vagina and the rectum in their proper relative position. During childbirth it forms a strong barrier against which the child is being pressed from above and pushed by passive and active counter-pressure forward around the pubic arch.

D. *The Projection of the Pelvic Floor.*—The perineal region forms a curve in the antero-posterior direction. The most projecting portion is that immediately surrounding the anus. The average distance from this point to a straight line drawn from the tip of the coccyx to the top of the pubic arch (*i. e.* the diagonal diameter of the outlet of the pelvis) is 1 inch.[1]

E. *The Arteries of the Perineal Region* are the *internal pudic* and branches thereof, and the *superficial* and *deep external pudic.* The *internal pudic artery,* a branch of the internal iliac, is much smaller than in the male. It passes downward and outward, emerges from the pelvis through the greater ischiadic foramen, between the pyriformis and ischio-coccygeus muscles, goes behind the spine of the ischium, re-enters the pelvis through the lesser ischiadic foramen, goes inside of the ischium, 1½ inches above the lower end of the tuberosity, where it lies on the obturator internus muscle in a sheath formed by the obturator fascia and the falciform ligament, a prolongation of the greater sacro-sciatic ligament. It reaches the margin of the ascending branch of the ischium, perforates the deep layer of the deep perineal fascia, continues its course along the margin of the descending branch of the pubis, perforates the superficial layer of the same fascia, and finally divides into its two end-branches, the *dorsal artery of the clitoris* and the *artery of the corpus cavernosum.* Before that it gives off four branches to the perineum—the *inferior hemorrhoidal,* the *superficial perineal,* the *transverse perineal,* and the *artery of the bulb.*

The *inferior hemorrhoidal* consists of two or three branches which start on the inside of the tuberosity, cross the ischio-rectal fossa, and

[1] Foster, *Amer. Jour. Obstet.,* 1880, vol. xiii. pp. 35–36.

end between the skin and external sphincter ani, giving branches to them and the levator ani.

The *superficial perineal artery* is a longer branch. It originates a little in front of the former, runs parallel to the ischio-pubic branches, either above or below the transversus perinæi muscle, between the superficial and the deep perineal fascia, and between the ischio-cavernosus and bulbo-cavernosus muscles. It then passes through the superficial perineal fascia, in which respect it differs from the corresponding artery in the male. It sends branches to the named muscles and ends in the vulva.

The *transverse perineal artery* perforates the deep layer of the deep perineal fascia, follows the superficial transverse perineal muscle, and supplies this muscle, the vestibulo-vaginal bulb, and Bartholin's gland.

The *artery of the bulb* is smaller than in the opposite sex. It comes from the internal pudic between the two layers of the deep perineal fascia, and pierces the superficial layer of the same. It supplies the vestibulo-vaginal bulb and the meatus urinarius.

The *artery of the corpus cavernosum* and the *dorsal artery of the clitoris* are much smaller than in the male, and that of the corpus cavernosum is again the smaller of the two, while in the other sex the opposite is the case. The artery of the corpus cavernosum is distributed in the crus. The dorsal artery of the clitoris follows the upper surface of the clitoris, and ends in the glans and prepuce.

The *superficial external pudic artery* is a branch of the femoral, passes through the saphenous opening, and spreads on the labia majora.

The *deep external pudic artery* comes likewise from the femoral. It crosses the pectineus muscle, pierces the fascia lata at the inner side of the thigh, and goes to the labia majora, where it anastomoses with the superficial perineal artery.

Hemorrhage.—In the median line of the perineal region there is no artery of any importance. The nearer an incision is made to the tuberosity of the ischium and the ischio-pubic branches, the greater is the danger of hemorrhage. The internal pudic artery is the only one that requires ligature on both ends (Ranney).

F. *The Veins of the Perineal Region* lead to the internal pudic and the internal saphenous veins. From the hemorrhoidal plexus (p. 89) the *inferior hemorrhoidal vein* follows the homonymous artery to the internal pudic vein. In the uro-genital region the veins do not correspond with the arteries. There is a single *dorsal vein* of the clitoris, beginning with small twigs from the glans and prepuce, running backward in the median line between the two dorsal arteries. It goes through an opening between the infrapubic ligament and the transverse ligament of the pelvis (p. 100), and divides into two branches that open into the *pudic plexus*, which surrounds the upper

part of the urethra. To this plexus go likewise the *veins of the corpus cavernosum—i. e.* several short, thick trunks which originate in the interior of the corpus cavernosum and form one branch on either side—and several *veins of the bulb.* The pudic plexus anastomoses with the vesical and vaginal plexuses (pp. 80 and 45) and the obturator vein. From this plexus two internal *pudic veins* on either side follow the corresponding artery through the sheath of the obturator fascia and open into the internal iliac vein.

The *external pudic veins* follow the corresponding arteries, and open into the internal saphenous vein.

G. The *lymphatics* of the perineal region lead to the inguinal glands.

H. *The Nerves of the Perineal Region.*—The perineal region receives its nerve-supply from the *pudic nerve* and from the *inferior pudendal branch* of the small sciatic nerve.

The *pudic nerve* comes from the sacral plexus, follows the internal pudic artery out through the great sacro-sciatic foramen, behind the spine of the ischium, and in through the lesser sacro-sciatic foramen. Its branches are the *inferior hemorrhoidal*, the *perineal*, and the *dorsal nerve of the clitoris.*

The *inferior hemorrhoidal nerve* crosses the ischio-rectal fossa, lies between the skin and the superficial perineal fascia, and gives branches to the external sphincter ani and the skin around the anus. Its anterior branches combine with those of the superficial perineal and inferior pudendal nerves.

The *perineal nerve* is the chief branch. It lies inside of the ischium, below the internal pudic vessels, in the same sheath of the obturator fascia. It breaks up into superficial and deep branches.

The *superficial perineal nerves* are two in number—an *external* or *posterior* and an *internal* or *anterior.* They run forward between the superficial and the deep perineal fascia, perforate the superficial fascia so as to come to lie between it and the skin, one on either side of the superficial perineal artery, and end in the labia majora. They give branches to the skin, and connect with branches from the inferior hemorrhoidal and the inferior pudendal nerves.

The *deep perineal nerves* generally arise by a single trunk, and are distributed to nearly all the muscles of the perineal region—the sphincter ani externus, levator ani, transversus, bulbo-cavernosus, and ischio-cavernosus—and to the vestibulo-vaginal bulb.

The *dorsal nerve of the clitoris* is the deepest branch. It lies above the pudic vessels in the sheath of the obturator fascia, then between the two layers of the deep perineal fascia, perforates the suspensory ligament of the clitoris, and is distributed on the clitoris, where it combines with twigs from the sympathetic and forms a nervous sheath (p. 39). It supplies the constrictor urethræ muscle and the corpus cavernosum.

The *inferior pudendal nerve* is a branch of the small sciatic. It passes under the tuberosity of the ischium, pierces the fascia lata, runs between the skin and the superficial perineal fascia to the labia majora, communicating with the inferior hemorrhoidal and superficial perineal nerves.

I. *Distribution of Organs between the Fasciæ.*—The following table may help to memorize the distribution of the muscles, vessels, nerves, etc. of the perineal region:

Immediately under the skin.	External sphincter ani muscle; Inferior hemorrhoidal vessels and nerves; Superficial perineal artery, veins, and nerves; External pudic artery; Superficial perineal nerves.
Between the superficial perineal and the deep perineal fascia.	Ischio-cavernosus Bulbo-cavernosus Superficial transversus perinæi } muscles; Pudendal sac; Vestibulo-vaginal bulb (in a particular sheath); Artery of bulb; Dorsal artery of clitoris; Artery of corpus cavernosum; Venous plexuses; Superficial perineal nerves and vessels.
Between the two layers of the deep perineal fascia.	Constrictor urethræ Deep transversus perinæi Constrictor vaginæ } muscles; Internal pudic artery with its branches, transverse perineal artery and artery of the bulb; Venous plexuses; Internal pudic veins; Deep perineal nerves; Dorsal nerve of clitoris; Vulvo-vaginal glands (sometimes above the deep layer).
Between the deep perineal and the pelvic fascia.	Levator ani muscle (anterior part); Vulvo-vaginal glands (sometimes).

J. *The Structural Anatomy of the Pelvic Floor.*—The vagina perforates the pelvic floor at an angle of 60° with the horizon.[1] What lies in front of the vaginal slit has been called the *pubic segment*, and what lies behind it the *sacral segment*. The pubic segment is composed of loose tissue, and is loosely attached to the symphysis pubis. (Compare pp. 87 and 93.) The sacral segment is made up of dense tissue,

[1] Hart is the first who has explained the structure of the pelvic floor in his remarkable thesis, *The Structural Anatomy of the Pelvic Floor* (Edinburgh, 1880).

and is firmly bound to the sacrum and coccyx. During labor the pubic segment is drawn up so that the empty bladder lies above the symphysis, while the sacral segment is being driven down by the pressure of the child.

Another division of the pelvic floor is into the *entire displaceable portion* and the *entire fixed portion*. The boundary between these two is a continuous layer of loose connective tissue, beginning as the retro-pubic fat (p. 93), then forming the loose tissue on the inside of the obturator internus and upper portion of the levator ani, and finally between the vagina and the rectum (Figs. 99 and 100).

FIG. 99.

Horizontal Section of Pelvis at Plane of Hip-joint (Ruedinger): *a*, coccyx; *b*, ischio-rectal fossa; *c*, rectum; *d*, vagina; *e*, bladder; *f*, retro-pubic fat; *g*, hip-joint.

The entire displaceable portion lies inside of the entire fixed portion, and consists of the bladder, the urethra, and the vagina. It has resting upon it the uterus, the broad ligaments, the tubes, and the ovaries.

The entire fixed portion has the shape of a funnel, wide above and narrow below. These two different divisions may be contrasted in the following way:

Seen in Sagittal Mesial Sections.		Seen in Horizontal Sections.
Pubic segment.	Bladder with urethra. Anterior vaginal wall.	Entire displaceable portion.
Sacral segment.	Posterior vaginal wall. Tissue attached to sacrum. Rectum. All outside of inner aspect of levator ani.	Entire fixed portion.

K. *The Function of the Pelvic Floor.*—The pelvic floor counteracts the abdominal pressure from above. The loose tissue surrounding the bladder and the rectum allows these organs to be distended and emptied. Its rôle during the act of copulation has been referred to in describing the vulva and the vagina, and the effect of the contraction of the perineal muscles and the levator ani in narrowing the genital canal is easily understood.

During parturition the entire displaceable portion is being pulled upward by the contractions of the muscular fibers of the uterus, which are continued on the vagina (p. 49). The child is pushed through the vagina, exerting a strong pressure on its posterior wall, on account of the angle between the uterus and the vagina. The active and passive counter-pressure exercised by muscles and fasciæ (pp. 99, 101, 102, 103) turn the child forward around the pubic arch.

The result of parturition is, first, to dilate the vagina and the vulva; second, to tear the perineal body more or less deeply; and third, to elongate and slacken the layer of loose connective tissue between the entire displaceable and the entire fixed portion of the pelvic floor, thus predisposing to prolapsus of the vagina and the uterus.

The Abdominal Regions.

By means of certain imaginary lines the abdomen is divided into regions, the familiarity with which is a great help in gynecological examinations and the recording of cases. One line is supposed to be drawn across from the highest point of the iliac crest on one side to the corresponding point on the other. Another transverse line goes from the lowest point of the wall of the thorax on one side (the cartilage of the tenth rib) to the corresponding point on the other side. Finally, a line is supposed drawn perpendicularly up from the iliopectineal eminence.[1]

Thus nine regions are formed, the names and relations of which are seen in this table:

Right hypochondriac.	Epigastric.	Left hypochondriac.
Right lumbar.	Umbilical.	Left lumbar.
Right iliac.	Hypogastric.	Left iliac.

The chief contents of each region are best learned by a study of the accompanying figure (Fig. 100).

[1] Different anatomists draw these lines somewhat differently.

FIG. 100.

Coronal Section of Frozen Body (Ruedinger): 1, right lung; 2, right atrium with fovea ovalis; 3, left atrium; 4, right branch of pulmonary artery; 5, arch of aorta; 6, left lung; 7, liver; 8, stomach; 9, ascending colon; 10, bridge of tissue between stomach and duodenum left by removing pylorus; 11, pancreas; 12, duodenum; 13, 13, small intestines; 14, fundus uteri; 15, bladder; 16, obturator internus muscle; 17, descending colon; 18, sigmoid flexure; 19, mesentery; 20, obturator externus muscle; 21, corpus cavernosum clitoridis; 22, meatus urinarius; 23, labia minora; 24, labia majora; 25, femur.

If we take into consideration the weight of all the organs pressing on the bladder, it is evident that that of a slightly enlarged or simply anteflexed uterus is hardly of any account. The discomfort often complained of in the bladder under such circumstances is either due to an affection of that organ itself or to a nerve reflex. The figure illustrates well the large amount of loose connective tissue found in the pelvis (p. 109).

PART III.

PHYSIOLOGY.

CHAPTER I.

PUBERTY.

PUBERTY and the climacteric are two important epochs in woman's life, one marking the beginning, the other the end, of the fruitful period. Puberty is the change from childhood to womanhood. It is a gradual development, which generally takes place in the fourteenth or fifteenth year of the girl's life. At that time the breasts become larger, the uterus increases in size (p. 33), the hips become broader, and the contour of the whole body is rounded off. The external genitals get their growth of hair, menstruation begins, and one sex feels attracted to the other.

Normal Development of Mammary Gland simulating Tumor.—When at puberty the mammary glands become the seat of greater development, it happens often that one lobule grows faster than other parts, gives rise to some pain, and becomes a little tender. Thus a more or less distinct round or oval swelling is formed, which often inspires fear and brings the young girl to the physician, who might himself be deceived and make a prognosis or even institute a treatment that might hurt his reputation, and, perhaps, harm the patient. It is enough to know of the frequent occurrence of such a condition in order to avoid mistakes. A wet compress covered with gutta-percha tissue, or rubbing with an anodyne liniment—*e. g.* chloroform mixed with twice the quantity of olive oil—relieves the pain, and a good prognosis disperses the anxiety.

Difference between Puberty and Nubility.—Puberty is the period when the possibility of reproduction begins, but by no means the time when it is desirable that the girl should marry and become a mother. Statistics show a very great mortality among married women under twenty years of age. It is evidently against nature's laws that women should become mothers before they are full-grown. Their uteri should have attained their maximum development, the breasts should be fit for nursing, the pelves should have reached a size that

allows the passage of a full-grown child, the muscles should have acquired strength enough to propel it, and the whole system should have been endowed with full power of resistance and endurance. It may, therefore, be stated that most women should not marry before they are twenty years old.

CHAPTER II.

Menstruation and Ovulation.

Menstruation is the discharge of a bloody fluid from the cavity of the uterus at regular intervals. It is also called the *menses*, the *catamenia*, the *menstrual period*, the *monthly sickness*, the *monthly flow*, *courses*, or *turns*.

This phenomenon is peculiar to woman and some monkeys.[1] It is probably due to the erect position, which necessitates a harder tissue of the womb, and excludes the presence of the enormously developed lymphatic system which is found in the horizontal animals, together with a flabby uterus.[2]

The menstrual flow commences in most women in the temperate zone between the fifteenth and seventeenth years of their life. It begins earlier in warm climates than in cold, earlier in cities than in the country, and earlier in the higher walks of society than in the lower.[3] It returns in periods of twenty-eight days,[4] and lasts on an average four days. The amount varies very much. Four or five ounces are said to be the average.[5] It is increased by exercise, corporeal work, chalybeates, and stimulants. The blood differs from that from other sources by a more or less considerable admixture of mucus and epithelial cells. It has also the peculiar "heavy" odor characteristic of the genitals. It comes from the mucous membrane of the body of the uterus and the tubes, while the cervix has no part in the process of menstruation. Before its appearance the woman feels a certain heaviness in the lumbar region, while pain is always a sign of an abnormal condition. Often the breath has an unpleasant odor during

[1] Bland Sutton, *Brit. Gyn. Jour.*, Nov., 1886, Part vii. p. 285.

[2] A. W. Johnstone, *Amer. Gyn. Trans.*, 1889, vol. xiv. p. 284.

[3] Special statistics are found in Hannover's *Om Menstruationens Betydning*, Copenhagen, 1851, p. 18; and T. A. Emmet, *The Principles and Practice of Gynecology*, 2d ed., 1880, p. 153 *et seq.* In a total of 2330 cases, Dr. E. found the average age at the first menstruation to be 14.23 years, but, his patients being from the "better classes," this average is too low.

[4] Most women are entirely unreliable in regard to their statement of the occurrence of menstruation. Very commonly they state that they have it on a certain date of each month. It is, therefore, advisable for the gynecologist to keep book himself of the beginning and the end of the periods of those under his treatment. Thus many an error is proved, many a complaint settled.

[5] Funcke, *Lehrbuch der Physiologie*, 4th ed., 1866, vol. ii. p. 991.

the period. If menstruation has been evolved from the rut in animals, it has changed very materially. While female animals only admit the male during this period of heat, woman not only has an aversion for sexual intercourse during her menstruation, but the act performed during the catamenial period exposes both sexes to disease—the woman to retro-uterine hematocele, the man to urethritis and orchitis. As a rule, menstruation ceases during pregnancy and lactation, but exceptions, especially from the latter rule, are by no means infrequent.

The anatomical basis of menstruation is a regularly recurrent development of the endometrium.[1] About a week before menstruation

FIG. 101.

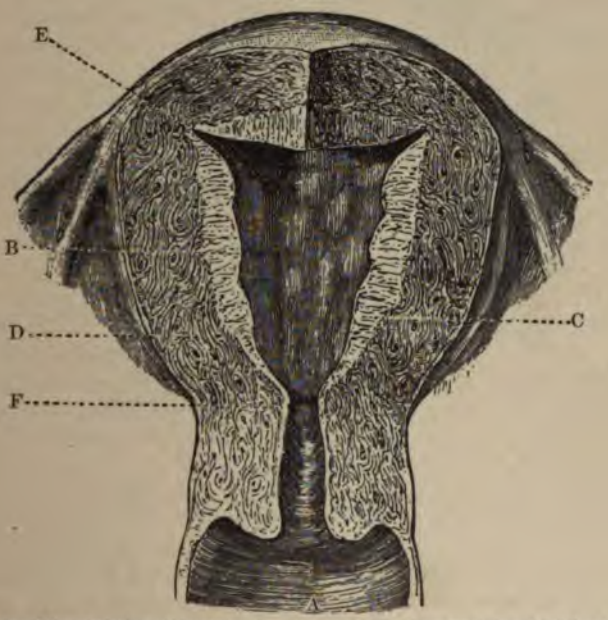

Uterus during Menstruation (Courty). Cut open to show the swelling of the whole organ, and particularly the mucous membrane: A, mucous membrane of cervix; B, C, mucous membrane of corpus, much thickened; D, muscular layer; E, uterine opening of tube; F, os internum (the mucous membrane tapers down to these openings).

sets in the mucous membrane of the uterus begins to swell, so that from 2 or 3 millimeters ($\frac{1}{8}$ inch) in thickness it becomes 6 or 7 millimeters ($\frac{1}{4}$ inch) thick. It acquires the greatest thickness on the middle of the surfaces and fundus, and falls gradually off toward the edges (Fig. 101). Its surface becomes wavy in consequence of the

[1] Leopold, *Archiv für Gynäk.*, 1877, vol. xi. p. 110 *et seq.*

disproportion between it and the underlying muscular tissue. Its arteries become much enlarged and form spirals. There is likewise so great a development of capillaries immediately under the epithelium that they form a plexus discernible with the naked eye. On the other hand, there are only few and small veins. The utricular glands become much wider and elongated, forming spiral- and zigzag-shaped tubes. The tissue itself is composed of connective-tissue cells interspersed with an enormous amount of round cells, like lymph-corpus-

FIG. 102.

Microscopical Section of Endometrium of a Menstruating Woman, aged twenty, showing utricular follicles denuded of epithelium, and one still containing the epithelial cast (Johnstone).

cles, and giant-cells with many nuclei. According to Leopold, these cells are found in a condition of active proliferation, while, according to Johnstone, who has worked with much more powerful lenses, the corpuscular elements are formed from granules in the threads of connective tissue forming the bulk of the mucous membrane (Fig. 47, p. 52). Before menstruation begins the blood-pressure is increased (Stephenson). Some of the capillaries near the surface burst and the blood escapes, partly into the tissue, forming small extravasations, partly on the surface, lifting up and tearing off the epithelium. The epithelium is also shed in that part of the utricular glands that lies nearest to the cavity of the uterus (Fig. 102). Five or six days after the beginning of menstruation the regeneration of the epithelium

begins from the utricular glands. Eight or nine days after the beginning of menstruation the regeneration is already completed. The glands are no longer twisted into spirals, the arteries have become smaller, the capillary net shrinks, the scars in the capillaries heal, and the whole surface is covered with epithelium. Most of the corpuscular elements have disappeared.

The tubes take part in the process of menstruation. Their mucous membrane is swollen, the epithelium is shed in some places, and they are filled with a thin bloody fluid containing blood-corpuscles and cast-off epithelial cells.

From this brief description of the condition of the endometrium during menstruation it is easy to draw several practical conclusions. We can understand how easily we can do harm by the introduction of the sound during the catamenia; how a normal menstruation may become a pathological hemorrhage, if the woman works hard or takes much exercise; and how the menstrual discharge may be intermittent—a thing that appears so surprising to many women.

Ovulation.—In mammalia the connection between the processes that take place in the ovaries and in the womb are perfectly known. One or more Graafian follicles become mature and burst before each recurrence of rut. The ovum escapes into the tube and passes into the uterus, the mucous membrane of which is in a similar condition in regard to the presence of medullary elements (the bodies that look like lymph-corpuscles) as that of a menstruating woman.[1] If copulation takes place, the ovum meets the spermatozoids somewhere on this passage from the ovary through the tube to the uterus, and, as a rule, impregnation takes place. In the ovaries are found as many corpora lutea as there are fetuses in the uterus. We do not know if a similar thing takes place in women; that is to say, we do not know if ovulation is a periodical process, and, if so, we do not know if the cyclus is the same as for menstruation. That there is some connection between the two seems to be proven by the correspondence, generally admitted, between the time elapsed since the beginning of menstruation and the degree of development of the corpus luteum (p. 71). But this correspondence is denied by others, who have large experience in the removal of the uterine appendages.[2]

We know for sure that a single coition at any time may result in the impregnation of a woman, but the likelihood of impregnation is much greater shortly after and shortly before menstruation than midway between the end of one menstrual period and the beginning of the next. Of the two terms, that preceding a menstruation seems, again, to give the best chances for impregnation. This is, among others, proved by embryology. In the young embryo the develop-

[1] A. W. Johnstone, *Brit. Med. Jour.*, Nov., 1887, Part xi. p. 384.
[2] Lawson Tait, *Diseases of Women*, Philadelphia, 1889, pp. 312-317.

ment is so rapid that an interval of three weeks makes an enormous difference in the condition of the organs. In this way it was found that three-fourths of young embryos corresponded to the first skipped menstruation, and only one-fourth to the end of the preceding.[1]

The fact that a woman may be impregnated at any time does, however, not prove that an ovum is detached at that time, for we know that both ovum and spermatozoids may be preserved for some time in the genital canal. The first has been found on the fourth day of menstruation in the uterine part of the tube (Hyrtl[2]) and in another case 1¼ inches above the internal os (Benham[2]). How long it stays in the uterus and keeps its faculty of becoming fertilized is unknown. We know as little, or still less, about the time the spermatozoids retain their fructifying power in the genitals of woman, but analogy from animals teaches that this is probably a longer one. They have been found alive in the os on the ninth day after coition.[3] We can, therefore, easily imagine that in the case of impregnation taking place in consequence of a single connection in the middle of the intermenstrual period, the spermatozoids are preserved and meet an ovum detached at the following menstruation.

On the other hand, it is a fact that copulation may be performed on any day of the intermenstrual period without resulting in pregnancy.

Influence of Operations on Menstruation.—It is very common that during the first days after the removal of the ovaries a bleeding takes place from the uterus, even if the patient had menstruated just before the operation.[4] In some cases the hemorrhage occurs from other organs: I have seen it come from the bladder, the rectum, and the nose. This determination of normal or vicarious menstruation is probably due to the irritation exercised on the nerves in the pedicle by the tightening of the ligature.

On the other hand, menstruation ceases in most cases after double ovariotomy or oöphorectomy, but exceptions from this rule are by no means rare. There are cases in which menstruation is repeated with more or less regularity for several months or even years. In other cases menstruation does not occur during the first three or six months following the operation, but then it reappears for a year or two, occasionally in the shape of a severe flooding.[5]

[1] His, *Anatomie menschlicher Embryonen*, Leipzig, 1882, ii. p. 73. The whole number, however, being only sixteen, this argument loses some of its weight.

[2] Leopold, *l. c.*, p. 121.

[3] R. Percy, of New York, *Amer. Jour. Med. Sci.*, July, 1876, p. 158.

[4] In order to avoid this extra loss of blood, which in anemic patients may turn the scales, Mr. Tait advises to operate immediately before or during menstruation (*l. c.*, p. 312).

[5] George Engelmann of St. Louis, "Menstruation and the Removal of Both Ovaries," *Trans. Southern Surgical and Gynecol. Assoc.*, Sept., 1889; reprint, p. 1. This is not in itself a proof against the ovulation theory, for if the presence of a

At the time the extra-peritoneal treatment of the pedicle was yet in vogue I saw menstruation after ovariotomy accompanied by bleeding from the tube in the stump. With the present intraperitoneal method there may, therefore, occasionally occur a retro-uterine hematocele under such circumstances.

According to Tait, the removal of the Fallopian tubes is of much greater importance in bringing on the menopause than that of the ovaries; but it is not unlikely that the influence of the removal of the tubes is again due to a large nerve-trunk which is seen running to the uterus in the broad ligament, in the angle between the round ligament and the tube.[1] When the object of the operation is to bring on the menopause, special care should, therefore, be taken to go close up to the uterus and include this nerve in the ligature; and in cases in which the removal of the uterus or its appendages proves impossible, it is advisable to ligate the tubes, including the nerve.

Theory of Menstruation.—The cause of menstruation is unknown. Most likely it has a yet unknown centre in the central organs of the nervous system. According to Johnstone, menstruation is a necessity in women and erect animals, because there are not sufficient lymphatics to carry off the lymph-corpuscles. The uterus is, according to him, a hollow lymphatic gland without a lymph-stream, and his definition of menstruation is, "a periodical washing away of those corpuscles which are too old to make a placenta." (Compare p. 50, foot-note.) If there is any connection between ovulation and menstruation, both are controlled by a common impulse from the central nervous system.

In some patients I have observed that alternately one and the other ovary undergoes a regular swelling at the time of every menstruation, but whether the same is the case in healthy women I do not know.

third ovary of the size of the normal ones is so rare as not to count in this connection, small supernumerary ovaries have been found twenty-three times in 500 bodies (Beigel). Another explanation is that a part of the two large ovaries has been left behind—a thing that sometimes is unavoidable. But perhaps the presence of ovarian tissue is not needed at all for the recurrence of menstruation. Tait has seen menstruation recur regularly for many years in a case of Porro's operation in which ovaries, tubes, and most of the uterus were removed (*l. c.*, p. 320). But can also occur in animals after complete removal of the ovaries (Barthelémy, *Jour. de Médecine vétérinaire; Med. Record*, Sept. 27, 1890, p. 368).

[1] Johnstone, *Brit. Med. Jour.*, Nov., 1887, p. 387.

CHAPTER III.

COPULATION.

COPULATION is the act by which the male and female bodies are sexually united. Under normal circumstances it is preceded by sexual appetite or desire. All its phases, perhaps with the exception of the desire, seem to be much less pronounced in woman than in man. The clitoris, the vestibulo-vaginal bulbs, and perhaps the inner genital organs enter into a state of *erection*. Friction between the male and female copulative organs causes a peculiar pleasurable sensation, which ends in *orgasm*, the acme of nervous excitement, which seems to be weaker in the female than in the male, and is altogether absent in some women, who nevertheless are capable of being impregnated. The orgasm is accompanied by an ejaculation of a mucous fluid from the glands of the vulva. If orgasm is less pronounced than in the other sex, it leaves far less feeling of exhaustion than in man. It is followed by relaxation which at any time may again give place to new excitement and erection. This difference is easy to understand when we take into consideration the difference between the fluids ejaculated and the profound shock sustained during orgasm by the central nervous system in the male.

The disturbance of these normal conditions which makes copulation painful or impossible is called *dyspareunia*,[1] and may be caused by many different affections or malformations of the genitals or other organs.

CHAPTER IV.

FECUNDATION.

FECUNDATION, or FERTILIZATION, is the union of the male and the female generative elements, the spermatozoid and the ovum, by which in the latter commences the formation of a new individual. It is likely that the two elements, as a rule, meet in the tubes, although the well-authenticated phenomenon of ovarian pregnancy proves that the combination may take place in the ovary, and in mammalia the spermatozoids are found on it within twenty-four hours after coition.

[1] Robert Barnes, *A Clinical History of the Medical and Surgical Diseases of Women*, London, 1873, p. 61.

In animals the ovum is no longer capable of fertilization when it has left the upper part of the tubes. It seems, therefore, highly improbable that in woman the ovum should retain the possibility of being fecundated for weeks after it has left the ovary, whilst no fact is known that would conflict with the supposition that the spermatozoids keep their vitality for weeks in the folds of the ampulla, and, on the contrary, such possibility is absolutely proved in animals.[1] If union of the two elements took place in the cervix, the ovum would be lost, as this part of the uterus is not fit for the formation of a placenta.

The analogy from animals makes it also highly probable that a part of the spermatozoid enters through the zona pellucida and combines with the germinal vesicle (p. 70), so that the formation of the new individual begins by the physical union of material derived from the father as well as from the mother. This leads us at least one step farther in the comprehension of the wonderful transmission through heredity of physical and mental peculiarities, aptitudes, and acquired talents, as well as diseases, from the father to his offspring.

CHAPTER V.

The Climacteric.

The climacteric—also called the *menopause*, or *change of life*—is the end of the fruitful part of woman's existence. Like puberty, it is not a momentary nor a single event. It comes on gradually, extending over a period of two or three years, and if the cessation of menstruation is the most characteristic symptom of it, it reverberates through the whole system, causing considerable physical and mental changes. It comprises the time when menstruation begins to be irregular, gradually diminishes, and finally ceases altogether. In most women the menopause supervenes when they are from forty-five to fifty years old, and the length of the fruitful period is in most women thirty-four years. Those who begin to menstruate early (under sixteen years) continue, as a rule, longer than those who have their first menstruation late (after sixteen). From this rule there is only one exception, and that is due to the influence of climate: in cold climates menstrual life begins and ceases late, while in hot climates it begins and ceases early. The fruitful period is longer in those women who have borne children and nursed them themselves than in nulliparæ and those who have not nursed their children. On the other hand, early sexual intercourse and a rapid sequence of childbirths or miscarriages shorten the period of fertility. It is shorter in the labor-

[1] His, *Anatomie menschlicher Embryonen*, Leipzig, 1880, i. p. 167.

ing classes than in women who lead an easy life. It is likewise shorter in fat women than in thin, and shorter in weak women than in strong. Those who suffer from chronic metritis or are weakened by uterine hemorrhages arrive sooner at the menopause than healthy women. Often it is brought on suddenly by severe diseases, such as cholera, typhoid fever, malaria, or a fall, a blow, a great fright, or deep mental depression. Such sudden entrance of the menopause is, as a rule, accompanied by especially violent disturbances in the whole organism, and it is therefore much better for a woman when it comes on gradually.

The most serious side of the climacteric is that it is the time when carcinoma most frequently appears in the uterus or the breasts.

The first symptom of the approaching menopause is irregularity in the menstrual flow in regard to time and quantity. As a rule, the interval between two menstrual periods becomes longer—say, six or eight weeks—but sometimes, on the contrary, menstruation becomes more frequent. The quantity of the discharge diminishes, but occasionally profuse hemorrhages occur. Menstruation lasts longer—say six or eight days. Most of the accompanying symptoms may be referred to active or passive hyperemia (congestion or stasis). Thus we find congestion in the head, causing a red face, headache, indistinct vision, a buzzing sound in the ears, vertigo, restless sleep disturbed by harassing dreams, and bleeding from the nose. The passive hyperemia of the intestinal tract produces catarrh of the stomach and of the intestines, hyperemia of the liver, with icterus, swelling and bleeding of the hemorrhoidal veins. The hyperemia of the lungs causes bronchial catarrh and attacks of dyspnea. That of the kidneys shows itself in sediment in the urine. Leucorrhea is very frequent. The skin is frequently the seat of flashing heat and profuse perspiration. Acne rosacea appears often in the face; there may be intolerable itching, burning, or smarting sensations all over the body, and the vulva may be the seat of a most distressing pruritus. The nervous system shows signs of a profound shock. Besides the symptoms already mentioned in reference to the head and skin, the patient often complains of backache and neuralgia; sometimes tremor occurs in her limbs; she suffers from palpitations; her temper is subject to great and sudden changes; the sexual appetite is often inconveniently increased; and she may become delirious or even insane.

A peculiar functional affection of the heart has been observed: it is characterized by palpitations, dyspnea on exertion, a feeling of distress in the region of the heart, faintness or syncope, a very rapid pulse without any rise in temperature, edema at the malleoli and the hypogastric region, and pallor of the face. The attacks usually last a week. The disease begins and disappears gradually.

The whole appearance of the person changes often at the meno-

pause. Most women become stout, but some lose flesh. Sometimes gout makes its appearance.

Considerable *anatomical changes* take place in the genitals. The uterus becomes atrophic. Sometimes the external or internal os or both close, and if at the same time there is catarrh of the mucous membrane, the mucus accumulates, forming *hydrometra*, or, if gases are developed in the fluid, *physometra*. If both the internal and external os close and a catarrhal discharge takes place both in the body and the cervix, a characteristic swelling is formed, composed of two globes separated by a transverse furrow (*uterus bicameratus vetularum*). The mucous membrane becomes thin and loses its corpuscular elements (Fig. 51). Sometimes a vessel ruptures in the fundus or posterior wall, causing an extravasation of blood (*apoplexy of the uterus*).

The ovaries become small and hard; the epithelium is lost on large areas; the follicles disappear, and are replaced by dense fibrous connective tissue.

The tubes become both thinner and shorter, and not seldom the walls grow together in different places.

In the breasts the glandular tissue disappears, and they become atrophic, or if they retain their size, or even become larger, it is due to the development of fat. Sometimes a serous fluid is found in them before the gland has all been absorbed—a circumstance which, together with abnormal sensations in the abdomen, tympanites, and the cessation of the menses, often lead the patient, and sometimes the physician, to the erroneous belief that she is pregnant.

Treatment.—Although the climacteric is a physiological process, normally occurring in every woman's life if it is sufficiently extended, the dangers with which it threatens are so serious, and the normal condition passes so easily and frequently over into the domain of disease, that the physician is often consulted about it. The treatment of the real diseases connected with it will be discussed in later chapters, under the diseases of the different organs affected, or must be looked for in works on the practice of medicine. Here we can only indicate a few points, especially in reference to hygiene.

A chief point is to keep the bowels open, preferably by means of aperient salts or waters. Sometimes enemas of plain water or mucilaginous and oily substances or glycerin may advantageously be combined with or substituted for the aperient medicine. Derivation to the skin by washing the whole body with cold water and rubbing the skin well with Turkish towels is both pleasant and useful. For the loaded urine it is good to drink a syphonful of Vichy, Rhens, or Seltser water in the course of the day, or to take bicarbonate of soda (ʒss) in a tumblerful of water. The congestion of the head and visual disturbance are often much benefited by the use of hot foot-

baths, with or without mustard, of the cold eye-douche five minutes three times a day, combined with scarification of the cervical portion. A glycerin pledget introduced morning and evening into the vagina may also relieve congested organs by causing a watery discharge. A lukewarm general bath taken two or three times a week keeps the skin in good order and tranquillizes the nerves. The diet should be bland, but must vary according to the constitution. In those women who have a tendency to stoutness it ought to be as much restricted as possible, and all fat-producing food (cereals and sugar) ought especially to be taken in very small quantities; milk and beer are prohibited. Fish, meat, green vegetables, lettuce salad, and juicy fruits ought to constitute the bill of fare. Tea and coffee ought only to be taken weak. Upon the whole, the less the woman drinks the better, for even water makes her fat. Alcoholic stimulants are best avoided altogether, but if there are special indications making their use desirable, or the patient has a craving for them, a light acid white wine (Moselle), mixed with plain water or a mild alkaline water, will do least harm. When the stoutness takes the proportions of pronounced obesity, a still stricter diet is necessary (Banting cure), and special treatment at certain mineral springs (Carlsbad, Marienbad, Tarasp) may be indicated.

Those more exceptional women who lose flesh, must be well fed and have chocolate and plenty of milk to drink, if they can digest them. Cereals ought to be a chief part of their diet-list, but all sorts of animal food ought to be given besides.

As a sudden suppression of the menses is particularly dangerous, the patient ought to take special precautions in that respect during the climacteric. She must beware of cold feet or a wet skin when she has her menses, not wash the genitals with cold water, and still less take a cold bath when the menses are present.

As congestion of the pelvic organs might cause hemorrhage, she should abstain from sexual intercourse. When first the menopause is well established marital relations may be resumed without danger.

The mental diet is of no less importance than the physical. The physician may relieve much unnecessary anxiety by giving a good prognosis. The patient should occupy her mind by useful work, and exercise as much self-control as her mental condition and acquired habits will allow.

When hemorrhage supervenes, it ought to be checked just as under other circumstances when a proper amount of blood corresponding to a menstrual period has been discharged. For this purpose we use hot douches, an ice-bag over the hypogastric region, tamponade, and drugs that have that effect (see Menorrhagia); and the patient ought to be kept in bed lightly covered in a cool room, and on cool, spare diet.

The above-mentioned menstrual cardiopathy is treated with digitalis and other heart tonics.

PART IV.

ETIOLOGY IN GENERAL.

THE causes of gynecological diseases may be divided into *predisposing* and *exciting*.

Predisposing Causes.—The first class, although more remote in their effect, are more important on account of their frequency. *Heredity* may play a double rôle, either that the same defect that is found in the mother is transmitted to her daughter, especially malformations and malignant diseases, or that the child inherits a generally weak constitution from one or both of her parents, which, in combination with her sex and the other predisposing factors, gives rise to diseases of the genitals and pelvic organs. In the latter respect it must be noted that children of parents advanced in life at the time of their procreation as a rule are less vigorous than those engendered in younger years.

Education has great influence in the development of gynecological diseases. Too great assiduity in study in early youth concentrates the nerve-energy on the brain, and deprives the uterus and ovaries of their share at a time when these organs are undergoing an enormous development, and preparing for the important functions of womanhood and motherhood. Too great interest in and practice of *music*, by its profound effect on the emotions and the constantly repeated physical thrill in the nerves, is particularly dangerous.

Everything that causes active or passive *hyperemia of the pelvic organs* is a source of disease. In this category belongs sexual excitement brought on by reading prurient novels; by looking at obscene pictures; by seeing representations on the stage that aim at the exposure of so much of the body as existing laws and public opinion will permit; by masturbation, sapphism (the same as tribadism), sodomy, and even normal coition if performed too violently.

The *neglect of the skin*, by which a chief emunctory is nearly blocked up, is hardly found in the better classes in this country, but is exceedingly common among the poorer women, especially immigrants, of certain nationalities.[1]

Insufficient exercise and *lack of open air* are a frequent cause of disease, and favor the stagnation of blood in the pelvis; but in this

[1] The Jewesses from Russian Poland in my dispensary experience exceed all others, and make, in fact, the impression of never bathing or washing their body.

respect, as also in regard to food, a great change has taken place in the higher classes during the last decade. The ideal of the American girl is no longer to be thin and pale. The young men having taken an ever-increasing interest in athletics and all sorts of sports, most of which are cultivated in the open air, the girls do not want to stay behind. The dull croquet has speedily been followed by the lively tennis; muscular strength is developed by swimming, riding, fencing, skating, and ballet-dancing; and now the girls begin even to have gymnasiums of their own, where every part of the body may be developed by properly adapted exercises.

In regard to *food* there is also great improvement, but it is too often necessary to inculcate the importance of taking a proper amount of good, wholesome nutriment. Many girls have a loathing for food in the morning, and will, if allowed to do so, go to school with an empty stomach, and let their brain work for hours before they take any substantial food. A very bad habit, that spoils the appetite, causes a sour stomach, and in consequence impoverishes the blood and gives rise to nervous troubles, is the immoderate use of candy, which among women and children corresponds to alcoholic beverages and tobacco in men.

A fruitful source of disease among women is the *lack of attention to the excretions*. The vast majority of gynecological patients suffer from constipation. They will go for days—nay, sometimes a whole week—without a movement of the bowels. This accumulation of feces gives rise to local trouble by pushing the uterus out of its place and interfering with the free circulation of the blood in the pelvis; but, besides, it causes absorption of the gaseous and liquid part of the fecal material, that shows its deleterious effect in bloodless lips, headache, neuralgia, and fatigue. The excretion of the urine is no less neglected. The requirements of polite society will often prevent women from emptying the bladder in time, which may lead to paralysis of that organ, not to speak of rupture, and not unfrequently is the cause of cystitis and neuralgic pain, besides predisposing to uterine disease by pushing the womb out of place.

The mode of *dressing*, although changing under the varying caprices of fashion, is always fundamentally wrong and conducive to disease. The "décolleté" evening dress and the bell-shaped nether garments drive the blood from the periphery to the pelvis. The lower part of the abdomen is generally insufficiently protected from cold air and blasts of wind, which become particularly dangerous to women who skate. High heels, when worn at an early age, while all articulations are yet subject to change, not only alter the shape of the foot, but are apt to cause neuralgia in the legs and a change in the inclination of the pelvis and the normal curvature of the back.[1]

[1] S. Busey, *Trans. Amer. Gyn. Soc.*, 1882, vol. vii. pp. 243–261.

Of much greater importance yet is the use of corsets. Even a loose corset exercises a pressure of 30 pounds, which has still greater effect on the abdominal cavity than on the thoracic. The abdominal wall is thinned and weakened. In the erect posture the liver and intestines are pushed forward, driving the weakened abdominal wall in front of them, and in sitting the normal pressure backward from the abdominal wall against the spinal column is changed into one going directly down into the pelvic cavity. By tight lacing the pelvic floor is bulged down to the extent of one-third of an inch.[1]

Late hours, social gatherings beginning at the time when the girl ought to go to bed, have a very bad effect on the nervous system, and predispose to much greater suffering from actual trouble than is felt by those leading a more natural life.

Neglect during menstruation seems to be a fruitful source of female complaints. Women not only move about, but dance and skate, at a time when a process is going on that is so easily turned in an abnormal direction.

We have seen in the chapter on Physiology how differently women are constructed from men in regard to sexual excitement. It is very unlikely that the mere frequency of normal sexual intercourse does a healthy woman any harm, but it is quite different when the natural relations are disturbed. The sin of Onan,[2] sodomy, and even the use of condoms, injections made in a hurry immediately after ejaculation at a moment when nature calls for rest, and often with a fluid of improper temperature, all cause a tension of the nervous system and a congestion of the genitals which in the course of time result in hemorrhage, leucorrhea, chronic metritis, fibroids, or other affections.

Marriage with existing disease of the pelvic organs often lays the foundation of much wretchedness for both husband and wife. If a flexion of the uterus may be cured by childbirth, provided conception takes place in spite of it, how different is it when the ovaries or tubes are the seat of chronic inflammation, which causes excruciating pain at the mere touch during a careful examination!

If married life has its dangers, *celibacy* does not offer entire protection. Especially is the liability to the formation of fibromas of the uterus greater in unmarried and nulliparous women than in those who have borne children, as if the uterus, deprived of the function of building up a new being, were more liable to use the material for the formation of a tumor.

[1] The question of the effect of the corset and other wearing apparel has been ably discussed by Dr. Robert L. Dickinson in the *New York Med. Jour.*, Nov. 5, 1887, Hare's *System of Therapeutics*, vol. iii. pp. 730–784, and *Trans. Amer. Gyn. Soc.*, 1893, vol. xviii. pp. 411–433.

[2] A careful perusal of Genesis xxxviii. 9 will convince the reader that thereby is not meant the vice which erroneously has been named after that man, and which properly is called masturbation, but the practice commonly known as "withdrawal."

In married as well as unmarried women the *climacteric* predisposes to disease—a point which has been considered in a previous chapter (p. 122).

Exciting Causes.—Sometimes a faulty development of the fetus constitutes directly a disease. Too great closure of the two halves forming the body gives rise to atresia; too little results in hypospadias, epispadias, or extroversion of the bladder. Arrest of development may also cause an infantile uterus. The genitals may be more or less completely absent. These conditions will be discussed under the diseases of the special organs.

Coition during menstruation has often been the cause of retro-uterine hematocele.

Childbirth is a fruitful source of disease to women, sometimes without, but oftener with, fault on the part of the obstetrician. Tears of the vaginal entrance often lay the foundation of prolapse of the vagina or the uterus. A torn cervix gives rise to ectropion of the mucous membrane, leucorrhea, hemorrhage, cystic degeneration of the cervix, secondary sterility, neuralgia, impaired nutrition, and carcinoma or sarcoma of the uterus. Too early rising after confinement, while the uterus is still large and soft, often causes subinvolution or displacement of that organ.[1] Through deficient antiseptic precautions inflammation is started in the uterus, the tubes, the connective tissue of the pelvis, or the peritoneum—conditions which, if they do not end the patient's life at once, often leave her sterile or a sufferer for life.

Abortions, spontaneous or legitimately induced to avert greater evil, may give rise to conditions calling for the gynecologist's interference; but of by far greater importance is the criminal abortion so frequently resorted to by women in all classes of society, in the country as well as in cities. Sometimes the ignorance and recklessness of the abortionist go so far that he makes a hole in the uterus through which one can put one's thumb, and through which the intestines may find their way into the vagina and down between the thighs;[2] and it is by no means rare to read in the reports of coroners' autopsies in suits for malpractice that wounds inflicted with some sharp or pointed instrument are found in the genitals of those who have succumbed in consequence of criminal abortion. But, even apart from these surgical injuries, there are two immediate dangers of abortion—namely, hemorrhage and septicemia, which are due to retention of the whole or part of the ovum. Hemorrhage occurs in two forms: either in the shape of sudden considerable flooding or as a constant or frequently-repeated loss of small amounts of blood, which is due

[1] This question has been considered at length in my article "Rest after Delivery," *Amer. Jour. Obstetrics*, vol. xiii. No. iv. Oct., 1880, pp. 851–863.

[2] Cases of this kind were reported by Thomas and Noeggerath in the Obstetrical Society of New York, *Amer. Jour. Obstet.*, 1882 (Supplement, pp. 4–6).

to fungosities of the endometrium, and undermines the most robust constitution.

The more remote effects of abortion are similar to those of too early rising after childbirth, especially subinvolutions and displacements.[1]

Gynecological Treatment.—Unfortunately, our list of the chief direct causes of gynecological diseases would be incomplete, if we left out the gynecological treatment itself. Even with the greatest care, our procedures are frequently not free from danger, and, if we neglect antiseptic precautions, the danger increases manifoldly. Especially is all intra-uterine treatment with sounds, curettes, tents, dilators, and pessaries[2] fraught with danger on account of the absorption of septic material, which so easily takes place through the lymphatics of the endometrium.

Gonorrhea.—Greater than any other danger is, however, sexual intercourse with a man who has gonorrhea, or who has, perhaps, had one many years ago which has not been thoroughly cured. While a gonorrhea in man in most cases is a trifling disorder, although exceptions, in which it leaves a serious condition, and even becomes fatal, are not so very rare, in women it is one of the most serious diseases. If it only affects the vagina and the urethra, it is of less consequence. It is already more serious if it extends into the vulvo-vaginal glands, but if it works its way up through the uterus to the tubes, ovaries, and pelvic peritoneum, it jeopardizes not only the woman's life, but, if she survives, she is most frequently left sterile, and is often an invalid for life, being subject to a chronic inflammation of the tubes and ovaries, with frequent acute attacks of peritonitis and an incurable uterine catarrh due to reinfection from the tubes. If sterility does not follow, such women often have an attack of puerperal endometritis in every confinement.

Under the name of *latent gonorrhea* has been described a condition in which a woman is infected by a man who had a gonorrhea months or years before. No acute gonorrhea is produced, but the women become ailing, remain sterile, and are affected with chronic, subacute, sometimes acute, very often relapsing, inflammation of the internal genitals.[3]

[1] An interesting paper on "Abortion and its Effects" was read by Dr. J. T. Johnson of Washington, D. C., before the Medical and Chirurgical State Faculty of Maryland, on April 23, 1890 (*Maryland Med. Jour.*).

[2] Garrigues, "Danger of Stem Pessaries," *Amer. Jour. Obstet.*, Oct., 1879, vol. xii. p. 756.

[3] Emil Noeggerath, "Latent Gonorrhea," *Trans. Amer. Gyn. Soc.*, 1876, vol. i. p. 268, *et seq.*

PART V.

EXAMINATION IN GENERAL.

THE examination of a gynecological case is *verbal* and *physical.*

Verbal Examination.—The aim of this work being to offer a practical guide for general practitioners, I shall not expatiate about all that we might be led to surmise by a number of symptoms elicited by a protracted conversation—conundrums that, anyhow, only find their solution by a physical examination; but I shall briefly state the questions I ask a patient before proceeding any further.

Age.—The age ought to be ascertained, because it often gives a measure of the weakness or robustness of the constitution of the patient, may throw some light on the nature of the affection for which she consults us, and may give us a hint in regard to special epochs in her life, such as puberty or the climacteric.

Social Position and Pursuits.—It is useful to know whether we have to do with a society lady, whose greatest fatigue is her social obligations; a shop-girl, who is kept standing or tripping about all day long; or a washerwoman, who stands bent over the tub rubbing linen day after day. It is of importance to know whether the patient spends her day in studying or in artistic pursuits—conditions which, as a rule, are combined with a highly-developed but over-sensitive nervous system. It is necessary to know something about the financial resources of the patient. In the poor recourse to more radical measures is often imperative, while those who possess adequate means may be benefited by a less vigorous but more protracted treatment.

Duration of Sickness.—The knowledge of the length of time during which the patient has been sick teaches us at once whether we have to deal with an acute or a chronic disease.

Condition.—It is of the very greatest importance to know whether our patient is single, married, or a widow, or has sexual connection without being married. If she is married, we want to know how long she has been so.

Childbirth and Miscarriages.—Next we want to know how many children she has borne, the age of the oldest and the youngest, and if she has had any miscarriages. A rapid succession of pregnancies is in many cases an important etiological point. Often the disease for which we are consulted may be referred to the last confinement. If

she is sterile, we must find out if it is a natural condition or due to the use of preventives. If we find sterility combined with dysmenorrhea, we nearly always find a flexion of the womb, and most frequently an anteflexion, often combined with a narrow os. If there have been many miscarriages, we must ask if they were spontaneous or induced. If criminal abortion has been performed, that gives often the clue to the origin of the disease, while, on the other hand, repeated spontaneous miscarriages generally are due to a misplacement of the uterus or to syphilis, either in the patient or her husband, or both.

Menstruation.—The normal period is twenty-eight days, of which menstruation lasts four (p. 114). Some women have periods of twenty-seven or twenty-nine days; some even of only three weeks. The duration varies likewise a good deal within normal limits. Some women menstruate only a day or two, others for a whole week; but, as a rule, such conditions are allied to symptoms which show that we have to do with something abnormal. The amount of blood lost at the menstrual period is of greater importance than its duration, since one will lose more in a day than another in a week. As a rule, women are able to tell whether they lose much or little, even if they do not use diapers, the numbers of which are often given as measure of the amount of the discharge. Normally, menstruation is only preceded and accompanied by a feeling of heaviness, especially in the loins. Menstrual pain is always a sign of disease. If it precedes the flow for many days, it is probably of ovarian origin, while a pain felt for a day and relieved by the flow is in most cases referable to a flexion of the uterus, and a pain continuing during menstruation points toward a diseased condition of the endometrium.

If menstruation is absent, we ask if it has ever been established. If it has not, we must take the patient's age into consideration (p. 114) and ascertain if she has *molimina*—*i. e.* if at regular intervals of four weeks she suffers from abdominal pain, congestion to the head, and general malaise. If the patient has reached the age of puberty, is otherwise well developed, and has monthly molimina, a physical examination is imperatively called for, in order to find out whether some malformation forms a barrier which prevents the blood from escaping from the genitals. We must inquire if the patient is subject to a regular bleeding from other parts which might have the character of a vicarious menstruation (Part VII., Chap. II.).

If menstruation has been established, we must ask if it is the first time it has failed to appear, or if similar periods of amenorrhea have preceded. We must ask if it has been suddenly suppressed, and if any cause for such suppression is known—*e. g.* exposure to cold.

Under all circumstances of disappearance of the menstrual flow the physician must think of the possibility of pregnancy, and inquire about nausea and vomiting, and if the patient is unmarried, under

some plausible pretext, obtain an examination of the breasts, which may give such corroborative information that a vaginal examination must be proposed. Even with married women he must remember that they may be pregnant without knowing it, or may be led by the secret desire that something may be done that will put an end to their pregnancy.

So-called menstruation recurring a year or more after the menopause is very suspicious, as it generally is a hemorrhage caused by cancer.

Discharge.—We ask the patient if she has any discharge from the genitals between her periods, and if so what color, consistency, and odor it has. A discharge is always an abnormality. A white, milky discharge is of least importance; a thick, glairy one comes from the cervix, and is often hard to cure; a bloody one comes probably from ulcers or granulations; a purulent one is a sign of a deeper inflammation, which often is of gonorrheic origin, or it may come from ulcers; an offensive one is particularly found in cancer.

Micturition and Defecation.—After these questions about the genitals proper we inquire about the condition of the neighboring organs. Very often we find frequent or painful micturition, even without disease of the urinary organs, and constipation.

Pain.—The symptom that most frequently brings the patient to seek help is pain. The pain has certain places of predilection, which, according to decreasing frequency, may be arranged in the following list: the left iliac fossa, the right iliac fossa, or both; backache, pain under the left breast, pain in the epigastric region, headache, neuralgia on the anterior surface of the thigh (anterior crural nerve), neuralgia on the external surface of the same (external cutaneous nerve), pain in the coccygeal region or in the interior of the pelvis when sitting. As a rule, the pain is increased by walking or other exertions. Frequently coition is painful (*dyspareunia*). When a pain is felt on one side of the body, it is, as a rule, on the affected side, but sometimes it is referred to the opposite side.

Worse than real pain are sometimes other abnormal sensations, such as itching or burning.

Sometimes patients suffer from a pricking pain in the eyeballs, with weak eyesight (*asthenopia*), palpitations, and the different nervous symptoms known as hysteria.

Nutrition and Strength.—Most frequently gynecological patients are thin and anemic, their appetite is poor, and they suffer from dyspepsia. They complain of feeling tired, and are unable to do the same amount of work as before they were taken sick.

Family History.—Sometimes the family history helps to a diagnosis, especially in regard to such hereditary diseases as tuberculosis and cancer.

Special Questions.—In special cases many other questions suggest themselves. For instance, if the patient has an enlarged abdomen, it is of great importance to know in what locality the enlargement was first noticed. If during the physical examination we find great tenderness in a married woman, it is a pertinent question to ask if coition is painful, and, if so, how often it takes place. When there is a deficient development of the genitals, it is proper to ascertain if the patient has a normal sexual appetite and feels any normal satisfaction in sexual intercourse. Venereal affections call for a close examination in regard to the time of their first appearance, preceding or concomitant symptoms (ulcers, rash, sore throat, alopecia), and the health of the husband. Sometimes it becomes necessary to ask the patient if she masturbates, which usually can be done by asking if she suffers from heat in the genitals, if she touches them, if she scratches herself, and so forth. But all such special questions will, as a rule, best be put during or after the physical examination.

Physical Examination.—For the physical examination we must make use of four of our senses—viz. sight, touch, smell, and hearing—and certain instruments or apparatus. Most examinations can be satisfactorily made with the patient lying in her bed or on a lounge, and in private practice, in the home of the patient, most examinations are made in this way. Certain things are, however, felt much better, or are first brought out, when the patient lies on an even, unyielding surface, and office practice is much expedited by having a couch especially made for the purpose. There are numerous *examining chairs and tables* in the market and in more or less common use. Tables are by far to be preferred to chairs, the latter not allowing so easily and so completely a change from the dorsal to the lateral posture. A common table with a hard mattress may be used, but it is a great improvement to have a table that can easily be made to slant backward, and to that side which is to the right of the physician when he stands at the foot of the table and turns his face to the patient. The most perfect table is, I believe, Daggett's, of Buffalo, N. Y. (Fig. 103). Whatever table is used should be placed near a window, with the foot end turned toward as good a light as can be obtained.

Fig. 103.

Daggett's Table.

The bladder and the rectum must be empty. If the bladder is more or less full, the urine may be drawn when the patient is on the table. If the rectum is loaded, it

is better to postpone the examination until the intestines have been emptied by means of an enema and an aperient. By neglecting these precautions the beginner may fall into serious errors, such as to diagnosticate pregnancy or tumors that are destined soon to disappear in the water-closet.

I. Positions.—The two chief positions used for examining a gynecological patient are the dorsal and Sims's. Of less importance are the genu-pectoral, the erect, Trendelenburg's, and the ventral positions.

The Dorsal Position.—The patient lies on her back, the head slightly raised on a cushion, the knees drawn up and widely sepa-

Fig. 104.

Dorsal Position.

rated, and the heels placed on the table or in front of it or above its foot-end in some kind of holes or stirrups (Fig. 104). The skirts are pushed up on the abdomen. For a complete examination of the abdomen the corset must be removed, and all bands round the waist opened, but for an exploration of the pelvic cavity we need only insist on the removal of closed drawers. In this way we save much time and cause the patient less trouble. When she is in position, she should be covered up to the breasts with a sheet, which thereafter is folded in between her legs, so as to leave only the vulva exposed.

If no inspection is intended, but only a digital examination, the patient remains entirely covered under the sheet.

The modification of the dorsal position called *breech-back position* will be described under "Preparation for Operations in General" and under "Urinary Fistulæ."

Sims's Position (Fig. 105) is a position on the left side, but by no means is every left-side position Sims's position. In the latter the patient lies on her left side half turned over on her front. The left side of the face rests on a cushion; the left breast touches the table;

Fig. 105.

Sims's Position.

the left arm is placed behind the body; and, if the table is narrow, both arms hang down beside it, but if it is too broad, the right forearm and hand may rest on the cushion in front of the face; the nates form an inclined plane, the right being a little nearer the head and in front of the left; the right leg lies on the left, but is drawn a little higher up toward the pelvis.

These two positions should be used in every case at the first examination. The dorsal position is the best for bimanual examination, for the use of the plurivalve speculum, and for the examination of the abdomen. Sims's position allows us to introduce one or two fingers much higher up behind the uterus than when the patient is in the dorsal position. Even things in the anterior part of the pelvis

are sometimes felt better; for instance, an anteflexion which cannot be made out while the patient is on her back, may become quite plain when the bent uterus falls forward over the tip of the examining finger in Sims's position. The chief advantage of this position is, however, that it admits of the use of Sims's speculum, and is preferable to others in certain operations.

The *genu-pectoral position* is rarely used for diagnostic purposes, but is sometimes useful in replacing a retroflexed gravid uterus, or a prolapsed ovary. The patient rests on her knees, the upper part of the chest, the right side of the face, and the right forearm (Fig. 106). The thighs are kept perpendicular and the back hollowed.

The *erect position* is useful in order to ascertain if there is any prolapse of the vagina or uterus. The patient stands with the feet about

Fig. 106.

Genu-pectoral Position (H. F. Campbell).

half a yard apart, slightly bent forward. The physician sits in front of her and introduces the index-finger into the vagina.

Trendelenburg's[1] *position* (Fig. 107) is sometimes useful in determining the connection between an abdominal tumor and the pelvic organs. The patient lies on her back on a strongly inclined plane, with much-elevated pelvis, and her legs hang over a flap that can be raised from the table. This position, which rarely is used for diagnostic purposes, is of the highest value in operations in the depth of the pelvis.

The *ventral position* is needed when we want to use percussion on the lumbar region; *e. g.* in a case of supposed floating kidney. The patient lies stretched out on her front surface and one side of her face, and the physician stands at her side.

When the patient is placed in the proper position we proceed to examine her, and, in order not to overlook anything, we will consider

[1] The accent is on the first syllable: Tren′del-en-burg.

separately the *examination of the pelvis*, the *examination of the abdomen*, and *other diagnostic means.*

II. THE EXAMINATION OF THE PELVIS.—The means employed are *inspection; digital examination* through the vagina, the rectum, and the bladder; *combined examination; artificial prolapse of the uterus; specula;* the *uterine sound;* the *probe;* and *dilatation of the cervical canal.*

A. *Inspection* is performed while the patient is in the dorsal position. Having in mind the normal anatomy of the external genitals (pp. 35 to 47), we pay attention to every deviation from the standard.

FIG. 107.

Trendelenburg's Position (Leopold's apparatus): *a*, adjustable flap; *b*, supporter; *c*, wooden frame fastened with clamps to table.

B. *Digital Examination.*—The fingers, especially the two index-fingers, are instruments of exploration of the very greatest value. The touch can to a great extent replace vision, and is sometimes superior to it—*e. g.* in judging of the extent of a cervical laceration—but a good deal of practice is needed before the limit of all the possibilities of this sense are reached. Great care should be taken to cultivate *both* index-fingers, as it is an immense advantage to feel equally well with both. By being able to do so, we can often avoid changing the position in which we find the patient, which in private practice often is preferable. Besides, the patient being in the dorsal position, we feel best with the homonymous finger—*i. e.* we feel what is in the right side of the pelvis best with the right index-finger, and what is in the left side with the left index-finger.

The fingers and the hand are used in several ways. The index-finger may be introduced into the vagina, the rectum, or the bladder; the fingers of the other hand are used on the abdomen; and diferent forms of these explorations may be combined.

Cleanliness.—It goes without saying that the physician shall have clean hands and short nails, kept clean with brush and steel, but strict asepsis, which is the absolute duty of the obstetrician, is not required for common gynecological examinations.

Lubricants.—Before the finger is introduced into the vagina it ought to be made slippery with some suitable lubricant, such as vaseline, olive oil, or a solution of soap. In rectal examinations it is a good plan first to fill the space under the nail by running it over a cake of soap. For vesical examination only the mildest lubricants, such as vaseline or olive oil, should be used.

Vaginal Examination.—The patient is in the dorsal position. The physician stands in front of her, observing her face, which will often give valuable information in regard to tenderness, pain, or sexual excitement. If the vulva does not gape, the labia majora are separated with the thumb and index-finger of one hand, while the index-finger of the other is introduced. As a rule, only the index-finger is used in the vagina. It is stretched, the last three fingers are bent flat in against the hand, so that one right angle is formed at the joints between the metacarpus and the first phalanges, and another between the first and second row of phalanges The index-finger, again, forms a right angle with the first phalanx of the middle finger, and the thumb is either extended so as to form a right angle with the metacarpal bone of the index-finger, or bent against the second phalanx of the middle finger (Fig. 108). In exceptional cases, and in women with large vaginal entrances, both the index and the middle finger may be used simultaneously in the vagina, which allows us to penetrate fully an inch deeper, but causes some pain. In entering it is well first to ascertain the condition of the vaginal entrance, especially the perineal body. In proceeding we notice the condition of the walls of the vagina in regard to smoothness, rugosities, hardness, adhesions, cysts, etc. Next, we place the tip of the finger on the os, and examine its size, shape, and direction. We notice the length, thickness, shape, and consistency of the cervical portion. The remainder of the vaginal examination is done much better by the *bimanual method* than by the unassisted finger. For this purpose the physician places the four fingers of the other hand on the hypogastric region—in the middle for the examination of the uterus, over the right and left iliac fossa for that of the appendages, the broad ligaments, the parametria, etc.—and presses well down, so as to bring the organs within easier reach of the finger in the vagina, and at the same time palpate them from above.

The index-finger is placed against the anterior part of the vaginal roof, while the fingers of the other hand rest on the fundus. Thus we easily sweep over the anterior surface of the uterus. Next we place the inside finger against the posterior part of the roof of the vagina, the so-called *cul-de-sac*, and push the fingers of the other hand with the tips turned downward and the pulp forward, far down behind the uterus, which in lean women allows us to examine the whole posterior surface of that organ. After that we place the inside finger on the left lateral part of the vaginal roof, and the outside fingers over the corresponding iliac fossa. By pushing the inside finger well

FIG. 108.

Combined Examination (Schroeder).

upward and backward, a little outside of the edge of the uterus, we are sometimes enabled to feel the ovaries, the tubes, the sacro-uterine ligaments, cysts of the broad ligaments, exudations, infiltrations, pelvic abscesses, etc. Finally, we examine the right side of the pelvis in the same way.

Rectal examination is best performed with the patient in Sims's position. We look for hemorrhoidal tumors, fissures, mucous patches, chancroids, etc. The physician stands behind the patient, and introduces his right index-finger as far as it goes, which is to the so-called third sphincter (p. 87), and in so doing pays attention to tumors, ulcers, or strictures of the intestine itself, and to the condition of the genitals in front and the sacro-uterine ligaments to the sides. Sometimes the uterine appendages are felt better from the rectum than

from the vagina. In cases of abdominal tumors this examination ought never to be neglected, as valuable information is often gained thereby which cannot be obtained in any other way. But in most cases the diagnosis can be made by the other modes of examination, and as this one is particularly disagreeable to physician and patient, and much more painful than a vaginal examination in a woman who has had sexual intercourse, it is by no means used in every case.

A peculiar evolution of the rectal touch is *Simon's intestinal examination*, by which the four fingers, the whole hand, and even a great part of the forearm, are introduced through the anus, the rectum, the sigmoid flexure, and all the way up to the upper end of the descending colon. The feasibility of this procedure shows how distensible the spincter ani is, but it is a dangerous manipulation, which has caused rupture of the intestine, and is one of the diagnostic means which formerly, when abdominal surgery was yet in its infancy, was of value, but which has fallen into disuse since laparotomy has become so harmless that we do not hesitate to perform it for diagnostic purposes.

Vesical Examination.—The urethra can easily be dilated by means of a set of seven coniform tubes with obturators (Fig. 109) varying from $1\frac{1}{4}$ to $2\frac{3}{4}$ inches in circumference, until the index-finger can be introduced into the interior of the bladder. This procedure permits the palpation of tumors in the bladder itself or between the uterus and the bladder facilitates the introduction of instruments into the ureters, and may decide about the presence or absence of the internal genitals in a case of atresia of the vagina. The patient is, of course, anesthetized, and occupies the dorsal position. The method is valuable, but, as sometimes it has led to incurable incontinence,[1] it ought only to be risked in cases in which the information sought is of great importance and cannot be obtained in any other way.[2] As a rule, we can reach our goal by means of a catheter in the bladder and a finger in the vagina or the rectum, or both.

Combined Examination.—Sometimes it is an advantage to combine several of the above-mentioned methods. Thus, a good mode of examining the perineal body is to introduce the index-finger into the rectum and the thumb into the vagina simultaneously. In other cases the middle finger is introduced into the intestine, the index-finger into the vagina, while the four fingers of the other hand palpate through the abdominal wall.

C. *Artificial Prolapse of the Uterus*, by which this organ is pulled down by means of a volsella to the entrance of the vagina, is much

[1] T. A. Emmet, *Principles and Practice of Gynecology*, 2d ed., 1880, p. 732.

[2] I have, for instance, done it successfully in an old lady with a large cancerous mass situated on the base of the bladder, so as to preclude incision from the vagina.

practiced abroad, and has some advocates in this country.[1] The method is not without danger, as it is liable to set up an acute peritonitis or cellulitis where there are remnants of old similar affections, and even endanger the integrity of the tubes or large veins in the broad ligaments if, perhaps, they are bound by old adhesions which escape our attention. It is better not to be too zealous a diagnostician

FIG. 109.

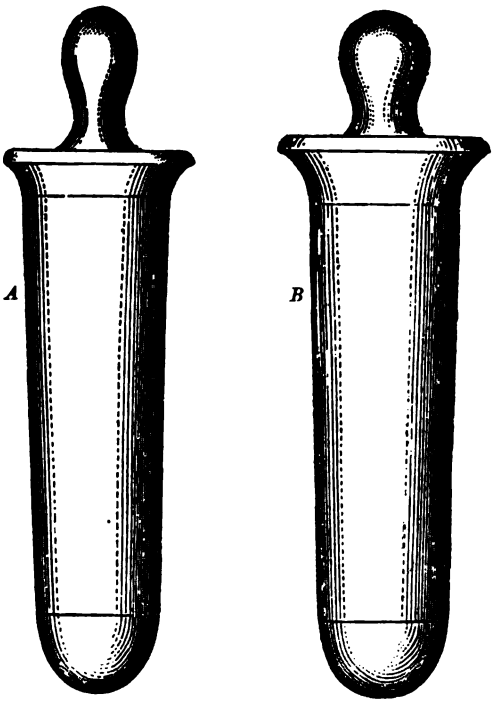

Gustav Simons's Urethral Specula, natural size: *B* represents the largest size; *A* is one number smaller.

than to risk making the condition of the patient worse in trying to determine its precise character.[2]

D. *Specula.*—In order to see the deeper parts of the canals leading to the pelvic organs we have instruments called "specula," which at the same time are of great importance for treatment, since they render it possible to make applications to, or perform operations on, the

[1] Howard Kelly has constructed a special kind of hook for the purpose (*Amer. Jour. Obstet.*, 1891, vol. xxiv. No. 2, p. 141).

[2] For details the reader is referred to a paper by H. C. Coe, *Med. Record*, Aug. 9, 1890, vol. xxxviii. p. No. 6, p. 141.

parts exposed. We have *vaginal, cervical, rectal, urethral specula,* and the *cystoscope.*

Vaginal Specula.—Of these there are a great variety, but virtually they may be reduced to three types: the *tubuliform,* the *plurivalve,* and the *univalve* specula.

Of the *tubuliform* specula, *Ferguson's* is the one most in use (Fig. 110). It is made of glass, covered with black varnish on the outside.

Fig. 110.

Ferguson's Vaginal Speculum.

A layer of tin-foil is inserted between the glass and the varnish. The proximal end has a flange which serves as handle and as check in introducing the instrument. It is mostly used with the patient on her back. The labia majora are separated, the most prominent end is introduced through the vagina, pressing on the perineal body. The anterior and posterior walls of the vagina shall be seen all the time touching one another in a transverse line until the vaginal portion with the os takes their place. It gives excellent light, but is inferior in all other respects: it pushes the uterus away; it spreads out a torn cervix, so that the tear may be overlooked;[1] it cannot be used for the inspection of the fornix of the vagina, which is often of as much interest to see as the os; it does not allow us to introduce the sound through it, unless we take a very wide and short one, which, again, can only be used where the vagina is exceptionally wide, and which causes pain; and it is hard to clean.

Of the *plurivalve* specula, some modification of *Cusco's* bivalve—*e. g. Brewer's* speculum (Fig. 111)—is most generally useful. A good instrument of this class should have few blades, for the more blades the more folds of the vagina will get in between them and obstruct the view. It should have a rounded end, so as to be introduced without causing pain. It should have a very wide opening, in order to admit much light, and at the same time be narrow at the vaginal entrance, so as not to cause too much distension and pain there. The blades should be of the same length: if the anterior be

[1] The almost exclusive use of this speculum in England accounts in a great measure for the tardiness with which Emmet's laceration and its cure by operation were recognized there.

half an inch shorter than the posterior, as in some instruments of this kind, the os cannot be seen if the uterus is anteverted.

Fig. 111.

Brewer's Speculum.

The *bivalve* speculum is used to greatest advantage in the dorsal position. Before introducing it the physician ascertains by touch the position of the os, and directs the instrument, closed, in that direction to its full length or till he reaches the vaginal portion. Then the branches are separated by turning the screw, and the instrument pushed a little farther in, so as to reach the fornix of the vagina.

The *univalve*, or *Sims's speculum* (Fig. 112) is the only one that

Fig. 112.



Sims's Speculum.

shows the uterus and the anterior wall of the vagina in their normal position and relation, since all it does is to pull back the perineal body and the posterior vaginal wall. It covers a smaller part of the vagina than the other two. It alone allows us to combine touch with sight,

and it is indispensable in the performance of operations for conditions which before its invention were incurable.

Sims's speculum is most frequently used with the patient in the genu-pectoral or in Sims's position, but it is often also used either on the posterior or on the anterior wall of the vagina, or on both at the same time, in the dorsal decubitus. Generally, two Sims's specula, of different sizes, are combined in one instrument, but for use on the posterior wall of the vagina in the dorsal decubitus a single one, with a suitable handle, is required.

Sims's own way of introducing his speculum was to hold the handle with the left hand and apply the thumb and index-finger of the right hand as a guide (Fig. 113); and where there are folds or other obstacles in the way, this is the best way of introducing it, the end of the finger being used to push the obstacles aside and place the end

FIG. 113.

Introduction of Sims's Speculum.

of the speculum behind the cervix. But in ordinary cases the physician seizes the handle with the right hand, placing the tip of the index at the base of the blade to be introduced. He stands behind the patient, separates the labia, holds the speculum so that its plane forms an angle of 45° with the top of the table, pushes it slowly in along the posterior wall to the posterior cul-de-sac, and brings it then over on the right side of the coccyx. After that he performs a movement in the direction of part of a circle, by which the perineal body and the posterior vaginal wall are pulled back. In so doing he gives the air free access to the vagina, and the viscera, falling by their own weight, up against the anterior abdominal wall and the diaphragm, the air distends the vagina so that it becomes more like a hollow globe than a cylinder—the so-called *ballooning*. This ballooning may, however, occur under circumstances in which air-pressure cannot be the moving principle. I have often felt it in examining

patients in the dorsal position, and I have felt an exactly similar distension of the rectum when the examining finger excluded all entrance of air. In such cases the ballooning is, in my opinion due to contraction of mucles extending from the wall of the cavity in question to fixed points in the surroundings (p. 43 and Fig. 55, p. 58).

If the os and posterior lip do not present themselves, they must be brought forward in some way, either by pulling on the anterior lip with a tenaculum, or, since this causes some pain, preferably by introducing the end of a sound into the os, if that can be reached, or by using a *depressor* on the anterior wall of the vagina, such as *Sims's*, consisting of a flexible metal rod with a loop at each end (Fig. 114),

FIG. 114.

Sims's Depressor.

or, better, *J. B. Hunter's*, a silver-plated copper rod ending in a spoon at each end (Fig. 115), or my own, which will presently be described.

FIG. 115.

Hunter's Depressor.

Modifications of Sims's Speculum.—Mundé's speculum (Fig. 116) is a Sims's speculum to which is added a flange that holds the upper nates out of the way. *Hubbard W. Mitchell's speculum* (Fig. 117) is a single Sims's speculum with Mundé's flange and wings, which give a good hold for the index and middle finger.

Self-holding Sims's Specula.—If a man holds one of these flanged specula in his left hand, or a common Sims's speculum, requesting the patient to lift the upper nates herself, and he holds the depressor in the right hand, he can see well enough, but no hand is left for treatment. The consequence is, that he must have an assistant. The presence of a third person, especially a female nurse, offers many advantages, but not everybody who wants to use Sims's speculum, has sufficient gynecological practice to make it pay to keep one for the purpose. A number of instruments have, therefore, been constructed with the aim of making the assistant superfluous by render-

ing Sims's speculum self-holding. The best instrument of this class is, in my opinion, that of the late Dr. Ehrich of Baltimore (Fig. 118), which I constantly use in operations on the cervix or anterior vaginal wall. It is true, no instrument can surpass the hand of an experienced nurse, but to hold Sims's speculum for any length of time is very trying, and Ehrich's speculum is infinitely more useful than the hand of an assistant who has not great practice in holding it. It is a single Sims's

Fig. 117.

Fig. 116.

Mundé's Speculum. H. W. Mitchell's Speculum.

speculum with flanges for both nates, fastened to a curved metal rod articulating with a plate which rests on the sacrum, and is kept in place by means of a band going over the patient's left shoulder. If sometimes a little help is needed, it may be rendered by any bystander, since all that is required is to pull the curved rod a little backward.

All these self-holding apparatus are, however, bulky, expensive, apt to scare the patient, and take much more time to apply than a common Sims's speculum. In order to have all the advantages of

the latter without being obliged to have an assistant for a mere application, curetting, and similar manipulations, I have had a vaginal depressor constructed which is held with the same hand as the speculum (Fig. 119).[2] The eye in which the name is, is held against the middle part of a double Sims speculum. The other end is placed in front of the cervical portion. The bow in the middle corresponds to the vulva and leaves the vagina unencumbered. It is on purpose that there is no connection between the depressor and speculum. A slight pressure with the thumb allows the physician to bring the depressor in whatever

FIG. 118.[1]



Ehrich's Speculum.

FIG. 119.

Garrigues's Vaginal Depressor.

[1] This figure represents the speculum so modified that the vaginal blade is divided into two lateral halves, which can be separated and approximated by means of a screw. It has also a depressor for the anterior wall which is fastened to the upper flange. It prevents one from pulling the uterus down and has not appeared practical to me.

[2] H. J. Garrigues, "A Vaginal Depressor," *Med. Record*, 1881, vol. xx. p. 698.

[illegible] for the inspection of any irregularly placed [illegible] is easy to cleanse.

[illegible] with a similar lubricant as the one used [illegible] (p. 138). When the cervix is exposed it is [illegible] to wipe away the mucus that covers it, which

FIG. 120.

Boerman's Dressing Forceps.

[illegible] a long pair of dressing forceps (Fig. 120) holding [illegible] cotton dipped in some antiseptic fluid.

[illegible] Fig. 121) are conical or cylindrical tubes on a [illegible] pushed into the cervical canal. They are less [illegible] for preventing any application destined for the

FIG. 121.



[illegible] a, tube; b, handle; c, movable clasp, preventing ends of wire [illegible] slipping out of d, small tube at right angles to main tube; e, [illegible] a; f, obturator fitting the two tubes.

[illegible] from being rubbed off on the cervical wall, and [illegible] cavity with gauze.

[illegible] much pain, and should therefore not be used [illegible] needed for diagnosis or treatment. Often a Sims [illegible] speculum may be used instead of a special rectal [illegible] rectal speculum is constructed on the same principle [illegible] vaginal, but with a closed round end and fenestra [illegible] Kelsey's bivalve rectal speculum is the best [illegible]

[illegible] are sometimes needed. *Jackson's* (Fig. 124) con- [illegible] tube, closed at one end and provided with a

FIG. 122.

Ashton's Rectal Speculum.

flange at the other, and having a fenestra on one side. It is convenient to have a set of three such tubes, but the one two and a half

FIG. 123.

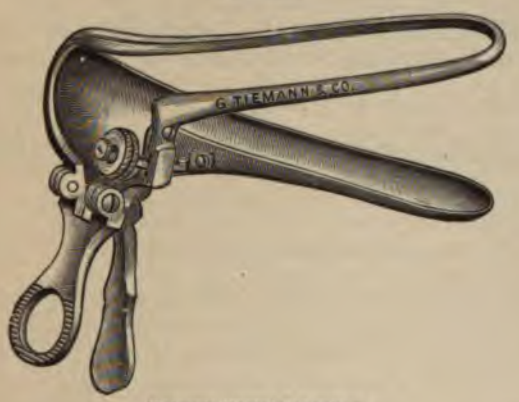

Kelsey's Rectal Speculum.

inches long and half an inch in outside diameter will be suitable for most cases.[1] *Skene* has adapted Folsom's nasal speculum to the

FIG. 124.

Jackson's Urethral Speculum.

urethra (Fig. 125). It consists essentially of two oblong eyes of

[1] A. Reeves Jackson, *Amer. Gyn. Trans.*, 1877, vol. ii. p. 575.

direction [illegible] and capable of being kept at the os, and the [illegible] screw. For the inspection of the

All spec[illegible] the urethra reflected light is for the [illegible]

in most [illegible]

[illegible].—By the introduction of a minute [illegible] into the bladder Nitze and Leiter [illegible] this hidden cavity as distinctly visi- [illegible] glottis illuminated by the laryngo-

[illegible] *Uterine Sound* (Fig. 126) consists of [illegible] flexible silver-plated copper rod [illegible] handle. At the end it has a little [illegible] 2½ inches a small protuberance with [illegible] marking the normal depth of the ute- [illegible] cavity, and other notches with figures by

is done by [illegible] the depth to which the sound enters is a pledget of [illegible] read off.

Cervic[illegible] useful, and, when properly used, harmless, long shaft w[illegible] it we must never forget that it is a metal used for seen[illegible]

Fig. 126.



Simpson's Uterine Sound.

[illegible]ate the wall of the womb, and that it is [illegible] from which absorption easily takes place. [illegible] manipulation and antiseptic precautions are [illegible] to the latter, it is hardly feasible to carry [illegible] case, but we ought at least to disinfect the

Burrage's Cer[illegible] composing [illegible] smaller cer[illegible]

[illegible] any bad discharge in the vagina, it ought to [illegible]ction and swabbing before the sound is intro-

cavity of the [illegible] the sound pathogenic germs may be brought for packing [illegible] they abound, or from the cervix, where they

Rectal spe[illegible] the cavity of the corpus, which never is their unless impera[illegible] in order that the reader may not form an exag- or bivalve va[illegible] danger of this mode of infection, I may state that speculum. [illegible] of the sound, and that for many years, before ciples as Pe[illegible] precautions, I have only four times seen inflam- on the side [illegible] acute metritis, and in the other cases exudative I know of [illegible]

Urethral sp[illegible] only used in the dorsal or in the lateral posi- sists of a tape[illegible]

[illegible] Cystoscopy," *New York Med. Jour.*, Apr. 21, 1888.

tion, with or without speculum. As a rule, I think the introduction in the left lateral position without speculum is the best. The sound should never be used before the position and the shape of the uterus have been ascertained by palpation, and if there is any marked deviation from the normal direction of the uterine canal, the sound should be curved so as to correspond to it, apart from the slight curve which always is given to the last 2½ inches in order to introduce it more easily into the canal, which forms an angle with the vagina (p. 53). The tip of the left index-finger is applied to the os; the lubricated sound, held between the thumb and index-finger of the right hand, is slid along the palmar surface of the finger till it reaches the os; then the finger is placed on the front or back of the uterus and used to tilt that organ in the proper direction in order to facilitate the introduction of the sound. A peculiar snap is felt when the sound passes the internal os. Often it is caught in the folds of the cervix (p. 49); then it must be pulled a little back, and turned in another direction. When once it has passed the internal os, the handle is pushed well back until the stem points in the direction of the umbilicus. As soon as the resistance of the fundus is felt we desist from further pushing.

In cases of anteflexion the introduction is often greatly facilitated by introducing the sound with the concavity turned backward as far as it goes, and then reversing it, or by giving it a sharp curve near the end like a prostate catheter.

In order to measure the depth of the uterus, the handle of the sound is held with the left thumb and index-finger, the tip of the right index-finger is applied to the sound just below the anterior lip, the sound is grasped with the right hand and withdrawn, and finally the distance from the tip of the finger to the end of the sound is read off.

Often the sound is used in connection with a finger in the vagina or in the rectum, or fingers pressed down behind the symphysis in order to locate tumors in the wall or in the neighborhood of the uterus; and sometimes it is used for moving the uterus in different directions, and thus ascertaining the relation of this organ to tumors in its vicinity.

F. *The Probe.*—The probe is a much thinner, very flexible rod with handle, used exclusively for exploring the inside of the uterine cavity. It is made of metal, hard rubber, or whalebone.

G. *The Curette.*—The curette is an instrument used for scraping something off the inside of the uterus. It is mostly used as a therapeutic agent, but sometimes it is employed in the service of diagnosis in order to obtain a specimen for microscopical examination. The chief curettes are Sims's (Fig. 127) and Simon's (Fig. 128) sharp and stiff, and Thomas's dull and flexible curettes (Fig. 129). In

the choice of a Thomas dull wire curette the purchaser should take good care not to buy one that is so flexible that it bends while being

FIG. 127.

Sims's Sharp Curette.

used. It should only be so flexible that it can be bent to adapt itself to the shape of the uterus in which it is going to be used. Simon's

FIG. 128.

Simon's Sharp Curette.

seems to me the best instrument for the cervix, and of late years I use it also more and more in the body of the uterus. In curetting

FIG. 129.

Thomas's Dull Wire Curette.

great care should be taken to disinfect the instrument, the vagina, and the interior of the womb both before and after operating.

H. *Dilatation.*—Sometimes it becomes necessary for diagnostic purposes to dilate the cervical canal sufficiently to introduce the curette or the finger. This may be done slowly by means of *tents*, or rapidly by means of cones or diverging rods working on the principle of a glove-stretcher.

Tents are cones made of substances that swell by absorption of fluid, especially sponges, sea-tangle (laminaria), tupelo root, and slippery-elm bark. It is next to impossible to get these tents disinfected, and they are therefore dangerous, and ought only to be used in very exceptional cases, especially for the dilation of fistulous tracts.

Laminaria tents are disinfected by placing them for one or two minutes in boiling antiseptic fluid. This makes them, at the same time, so soft that they can be curved to fit a bent cervical canal, and, on being placed in cold fluid, they become immediately hard again. Still, they should never be brought in contact with a fresh wound. If the sound is used and a drop of blood appears, the introduction of the tent should be postponed for twenty-four hours. The patient must keep absolutely quiet for a few hours until the tent is suffi-

ciently swollen to be retained. The labor-like pain produced by the swelling may be relieved by hot applications. If needed, four or more tents may be introduced, one after the other, changing them twice in twenty-four hours, and washing out the uterus at the same time.[1]

The tent is introduced with a pair of dressing forceps or Barnes's tent-carrier (Fig. 130).

For diagnostic purposes, and as part of treatment, dilatation is

FIG. 130.

Barnes's Tent-Introducer. A tent is seen fitted to the end ready for introduction. When it has been placed the stylet on which it is mounted is withdrawn through the larger tube, with which it is held steady till the stylet is quite free from the tent.

much safer when performed rapidly. For the lower degrees of dilatation a few of Hanks's coniform hard-rubber dilators (Fig. 131) are

FIG. 131.



Hanks's Uterine Dilator.

very serviceable. Where there is great narrowness of the os, it may, however, become necessary first to make a small incision in its edge. For the next degree of dilation, up to $1\frac{1}{4}$ inches, a strong instrument of the diverging kind is required. I have had one made which I

FIG. 132.

Garrigues's Uterine Dilator.

think unites the best features of the different instruments of this class (Fig. 132). It has Ellinger's parallellogram; only one handle, in

[1] This is the method of B. S. Schultze, *Centralblatt für Gynäkol.*, 1878, vol. ii. p. 150.

order not to lose light; fine ridges on the lower part of the branches, in order to prevent the instrument from slipping without bruising the uterus too much; curved branches, since these are more easily introduced than the straight, and the uteri upon which they are used, are commonly ante- or retroflexed. For the very highest degrees of dilatation—which, however, scarcely are needed for mere diagnosis—another set of instruments originated by Hanks for the treatment of abortion are excellent (Fig. 133). They consist of a set of oblong balls of hard rubber screwed on both ends of a curved shaft of the same material. One of the balls serves as handle while the other is being slowly pressed through the cervix, the lips of which are in

FIG. 133.

Hanks's Large Uterine Dilators.

the beginning pulled gently over the ball; but later on pressure alone is used to propel the same through the internal os.

Since dilatation cannot be resorted to without bruising and tearing the tissues to some extent, it goes without saying that the rules of antiseptic surgery must be scrupulously observed.

Dilatation has been carried to such an extent as to make the whole cavity of the uterus visible up to the fundus (Vulliet's method[1]). This is obtained by introducing small bulbs of absorbent cotton impregnated with iodoform ether (1 part iodoform to from 10 to 30 ether), dried, and tied to strings. These balls are carried with dressing forceps and sound right up to the fundus. Anesthesia is produced with pledgets dipped in cocaine solution. The patient is in the genu-pectoral posture. If the cervical canal is too narrow, it is first dilated by means of the above-mentioned dilators. The tampons are left in for forty-eight hours.

In order to get the cervix and lower uterine segment dilated, it is sometimes necessary to combine the use of these cotton balls with a bundle of laminaria tents, the cotton ball being pushed up in the centre of the bundle as far as the middle of the cervical canal, so as to form a cone which is left in from ten to fifteen hours. After the dilatation of the cervix has been obtained in this way, only cotton balls are used and the stuffing renewed. Occasionally this method

[1] Vulliet et Lutaud, *Leçons de Gynécologie opératoire*, Paris, 1890, p. 75.

might prove valuable both for diagnostic purposes and for the removal of tumors from the cavity of the body of the womb.

I. *Examination of Virgins.*—The vaginal examination ought to be avoided as much as possible in virgins. In cases where the symptoms are not grave, such as leucorrhea, menstrual disturbances, backache, etc., it is better to desist from an exact diagnosis, and first try the effect of medical treatment. Some information may be gained by the rectal exploration. If, however, the symptoms point toward more serious trouble, a vaginal examination becomes imperative, but ought only to be undertaken with great care and deliberation. Unfortunately, many girls are easy enough to examine, but in a really intact girl the introduction of the finger meets with considerable resistance, and the sharp edge of the hymen is felt like a fine steel cord on the pulp of the finger. With the exception of a few urgent cases, in which it is necessary for treatment's sake to make a speedy diagnosis, it is better first to prepare the hymen by the introduction twice daily of a small tampon of absorbent cotton soaked in glycerin. By gradually increasing the size of the tampon at every change the parts will in a few days be sufficiently softened and dilated to allow the index-finger to pass. It should be carefully lubricated all over and introduced very slowly, in order to avoid causing unnecessary pain and rupturing the hymen. When once the finger has passed, a small-sized speculum may be used if necessary.

III. *The Examination of the Abdomen.*—The patient occupies the dorsal position; the physician stands at her right side. The diagnostic resources at his command are *inspection*, *palpation*, *percussion*, *auscultation*, *mensuration*, *injection of water* into the intestine, and *production of carbonic acid* in the stomach.

A. *Inspection.*—The practiced eye can frequently, at the first glance, distinguish the more pointed prominence caused by a tumor or pregnancy from the flat enlargement due to an accumulation of free fluid in the abdominal cavity or to hyperplasia of adipose tissue. We look for changes in pigmentation (*linea fusca*), subepidermal tears in the skin (*striæ albicantes*), and the protrusion of the navel.

B. *Palpation* is superficial or deep. By folding the abdominal wall we judge of its thickness and mobility. By slight pressure we sometimes get a crackling sensation due to fresh adhesions. By deep pressure we try to gain as much information as possible about the contents of the abdomen. We examine if there is any abnormal tenderness anywhere. We feel for hard masses. If we find any, we try their mobility. If it is the uterus that is enlarged and has risen up into the abdomen, this is often done best by placing the index-finger on the os and moving the uterus from side to side, when the cervix will be felt to move in the opposite direction. If the mass contracts while being palpated, we know that is the gravid uterus.

If a patient makes a deep inspiration, a tumor of the liver will ascend under the following exspiration, while all other tumors may be kept down with the hands.[1]

In palpating tumors the bimanual examination (Fig. 108, p. 139) is likewise often used. The physician stands then between the legs of the patient. Often an assistant is needed to lift the tumor or move it from side to side. By placing the fingers of one hand lightly in one place and pressing on another with those of the other hand, we ascertain if there is any *fluctuation*—a sign which denotes the presence of a fluid. In a case of pregnancy we may be able to recognize certain parts of the fetus.

C. *Percussion.*—By means of percussion we find out whether we have the normal tympanitic sound of the intestines containing gas, or a dull or flat sound characteristic of a solid mass or a fluid. We note very carefully the limits of the dull area, by which we get valuable information in regard to the starting point of the tumor. If it is a fluid, we make the patient alternately lie on the back and on either side while we use percussion. If the fluid sinks down, leaving a tympanitic area above, we conclude that the fluid moves freely in the abdomen (ascites), whereas it cannot change position if enclosed in a cyst.

D. *Auscultation* often gives information of the very greatest importance. Whenever we have to examine an enlarged abdomen we ought always to bear pregnancy, normal or extra-uterine, in mind as the key to the whole condition or as a complication. We listen, therefore, for the double sound characteristic of the fetal heart, for the sound caused by fetal movements, and for the blowing sound (*uterine souffle*) formed in the large vessels running along the edges of the womb. The latter may, however, also be heard in fibro-cystic tumors of the uterus. The *bruit* produced in an aneurism of the abdominal aorta has a different character, and is accompanied by other characteristic signs.

E. *Mensuration.*—The measures are taken with a tape-measure in the dorsal position. This method is especially used in order to form an idea of the size of a tumor, and gives sometimes information in regard to its starting-point. The measures usually taken are the girth at the level of the umbilicus, the girth at the most prominent point of the swelling, the distance from the umbilicus to the symphysis, the ensiform process, and the anterior superior spine of the ilium.

F. *Development of gas* in the stomach and *injection of water* into the intestine have recently been recommended for diagnostic purposes. The stomach is expanded by giving bicarbonate of sodium and tartaric acid together. Later the stomach is evacuated by introducing a

[1] Naunyn, reported by Minkowski, *Centralblatt für Gynäkologie*, 1888, vol. xii. p. 790.

soft-rubber œsophageal sound, and tepid water is injected into the intestine by means of a fountain syringe. In this way a tumor is displaced in the direction from which it has started.[1]

G. *Charts.*—It saves much time and contributes to a precise diagnosis to use printed charts representing the outline of the abdomen and pelvis in front and side view, and mark on them the location of any swelling found by examination.[2]

IV. *Other Means of Investigation Common for Pelvic and Abdominal Diseases.*—Such are *exploratory aspiration, exploratory incision, urinary analysis, microscopic examination, chemical examination,* examination under *anesthesia,* and *examination of the ureters.*

A. *Exploratory aspiration* is used less now than it was some years ago. It is done in order to ascertain the presence of a fluid or to obtain a sample of such fluid for examination. If the fluid is thin, it may be drawn out by the common hypodermic syringe. For use in the vagina such a syringe has been made with a longer needle and an attachment by means of which the piston can be pulled out.[3] In most cases it is preferable to use a real aspirator, such as Dieulafoy's, Potain's (Fig. 134), or Emmet's. Even the finest hypodermic syringe ought to be carefully disinfected before being plunged into the interior of the body, and the same precaution ought to be taken in regard to the skin it is going to perforate. As a rule, a cavity once entered should be totally emptied in order to prevent the fluid from finding its way into the peritoneal cavity. As this may be very tedious, a syphon action may be substituted for the aspiration by attaching a rubber tube to the needle and placing the other end, armed with a plunger, in a vessel with water. Aspiration ought never to be performed in the office or dispensary, and the patient ought to be kept in bed for four days. In order to lessen the danger of wounding blood-vessels as much as possible, the finest instrument that will do the work is preferable, and it ought to be introduced slowly, so as to push arteries aside which it might meet in its way. If the puncture is made through the skin, the opening should be pressed together from side to side and covered with a piece of rubber adhesive plaster. (Compare "Tapping," under Treatment of Ovarian Cysts.)

B. *Exploratory Incision.*—With the increasing innocuousness of laparotomy the exploratory incision has to a great extent replaced exploratory aspiration. It is, of course, in many cases only the first act of a capital operation, and must therefore only be undertaken by a person qualified to perform the latter, and after all preparations for such an operation have been made. The incision in the abdominal

[1] Naunyn, *Centralblatt f. Gyn.*, 1888, vol. xii. p. 790.

[2] Rubber stamps for recording cases are manufactured by the Barton Manufacturing Co., No. 338 Broadway, New York.

[3] Campbell, southwest corner Lexington Avenue and Thirty-fourth Street, has made such a syringe for me.

wall is not made larger than is necessary to clear up the existing doubt, for which purpose the introduction of one or two fingers often suffices. As a rule, it is made in the median line and so that the

FIG. 134.

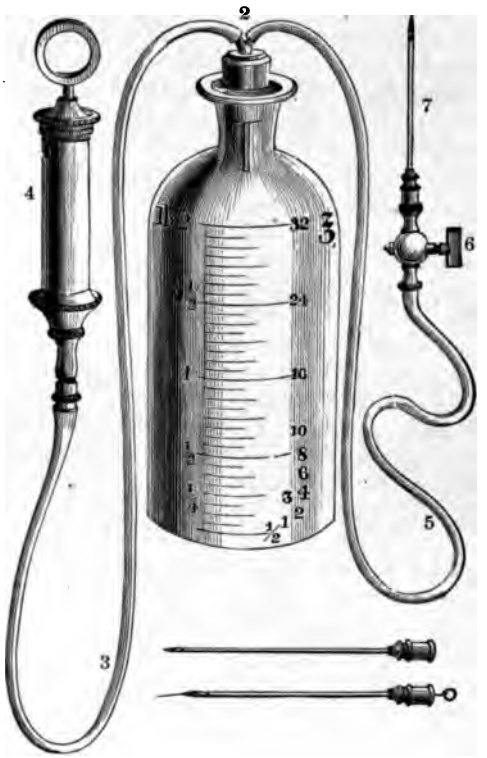

Aspirator. This instrument consists of a clear glass bottle, with a graduated scale showing the amount of fluid contained. It is closed by a rubber stopper, through the centre of which a double-current tube, 2, passes. It is attached to an elastic hose, 3, with an exhausting pump, 4, and another elastic hose, 5, with a stopcock, 6. On the top of the latter fit needles and trocars, 7, of different sizes.

lower end of the incision comes to lie two finger-breadths above the symphysis pubis.

C. *Urinary analysis* ought to be made in every case before an operation is undertaken, and even before the patient is subjected to the influence of anesthetics, as the result of the analysis may decide which anesthetic should be preferred (see Anesthesia). But even in minor gynecology the examination of the urine often gives valuable hints as to diagnosis or treatment. The urine should be examined chemically and microscopically.

D. *Catheterization of Bladder.*—In most cases the patient may pass her urine herself and send it for examination, but if there is any complaint referable to the bladder, the urine should be drawn with the catheter. To do this under the clothes is easy enough, but entirely antiquated. We know that by introducing mucus from the vagina or vulva into the bladder we may set up cystitis. The meatus urinarius should, therefore, be exposed, the patient being either in the dorsal or left-lateral position. The vulva is opened with the fingers of the left hand, and the vestibule wiped with a pledget of absorbent cotton wrung out of an antiseptic solution. Next the disinfected catheter, held with the thumb and index-finger of the right hand, is introduced. The metallic catheter is preferable, as it is easier to keep clean, and in many examinations a stiff rod is needed. It ought to be smeared with vaseline or olive oil, and introduced in a curve hugging the symphysis pubis.

E. *Microscopical examination* is of great diagnostic value for the gynecologist. It is applied to the urine, pathological fluids obtained by aspiration, and solid bodies removed with the curette or cutting instruments. In examining urine special attention is paid to the presence of epithelial cells from the different parts of the urinary tract and the external genitals (Fig. 135), to casts characteristic of nephritis, and to the different crystals abnormally seen in urine.[1]

As a sample of fluid let us take that from an ecchinococcus. A single hooklet or a particle of the structureless stratified cuticula, revealed by the microscope, settles the diagnosis. A piece of tissue scraped off with the curette or cut off with the scissors may tell us if it comes from a part affected with carcinoma.

F. *Chemical Examination.*—*Chemical reactions* are especially used to reveal the presence of sugar, albumin, or gall in urine or other fluids.

G. *Examination during anesthesia* is of course only used in more important cases, since the process always contains an element of danger; but this is so small, and the benefit to be derived for the diagnosis so great, that this means of investigation is perfectly legitimate. Some women contract their muscles so persistently that it is impossible to make a thorough examination without having recourse to this means, when often the existence of a condition calling for active interference will be brought to light.

H. *Examination of the Ureters.*—The ureters may be made accessible in three ways: by making a vesico-vaginal fistula, by catheterization, and by palpation.

1. *Artificial Vesico-vaginal Fistula* (T. A. Emmet's method).—An

[1] For details the reader is referred to the work of Charles Heitzmann, *Microscopic Morphology of the Animal Body in Health and Disease*, New York, 1883, with its excellent illustrations.

[illegible] through the vesico-vaginal septum. [illegible] the ureters may be seen and [illegible] the fistula should be closed again, the

No. 35.

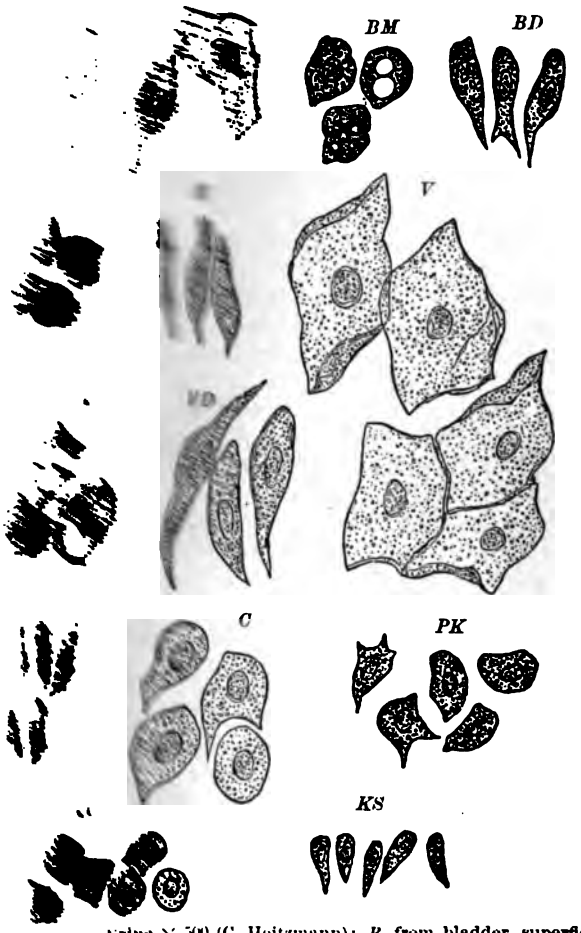

[illegible] Urine × 500 (C. Heitzmann): *B*, from bladder, superficial layer; [illegible] of bladder; *BD*, from deepest layer of bladder; *P*, from the [illegible] ejaculatory duct; *V*, from superficial layer of vagina; *VM*, from [illegible] *VD*, from deepest layer of vagina; *C*, from the outer surface of [illegible] from the cavity of the uterus; *PK*, from pelvis of kidney; *KC*, from [illegible] the kidney; *KS*, from the straight tubes of the kidney.

[illegible] together with silver sutures and a catheter left in [illegible] be described in detail in treating of vesico-vaginal

The catheter may also be introduced through the urethra and guided with a finger introduced through the artificial fistula into the ureter.[1]

2. *Catheterization.*—The ureters may be catheterized with or without previous dilatation of the urethra.

a. Catheterization of the Ureters after Dilatation of Urethra (Simon's method).—The urethra is dilated (p. 140) until the index-finger can be brought through. With it the interureteric ligament is grasped (Fig. 136) and the openings of the ureters felt. A slender catheter is

FIG. 136.

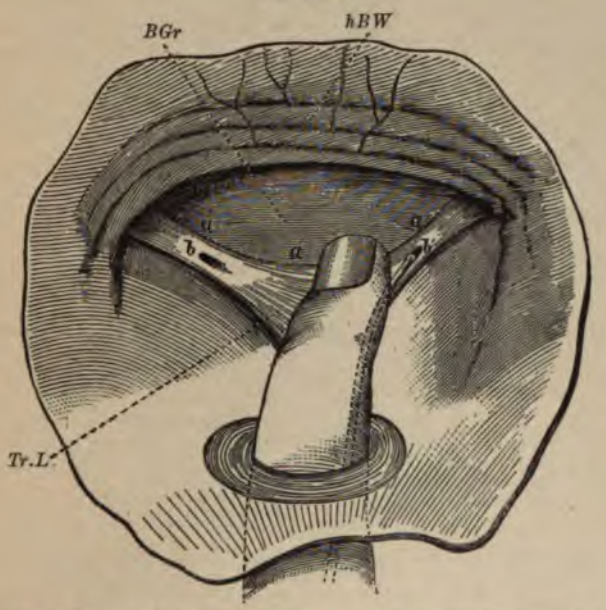

Simons's Method of Catheterization of the Ureters: *a*, interureteric ligament; *b*, *b'*, orifice of ureter; *Tr. L*, Lieutaud's trigone; *hBW*, posterior wall of bladder; *BGr*, base of bladder.

introduced along the finger into the bladder and made to enter the ureter; but since it is difficult to enter the ureters even when one holds the open bladder in one's hand, we can imagine what an unusually fine touch and dexterity of movement are needed for the introduction in the dark.

b. Catheterization of the Ureters without Dilatation of Urethra (Pawlik's method).—The anterior vaginal wall presents folds corresponding to the trigone (Figs. 83, 136, and 137), and permitting

[1] W. M. Polk, *N. Y. Med. Jour.*, April 13, 1884.

us to locate the openings of the ureters. The patient is placed in the dorsal position, with legs strongly flexed on the abdomen and

FIG. 137.

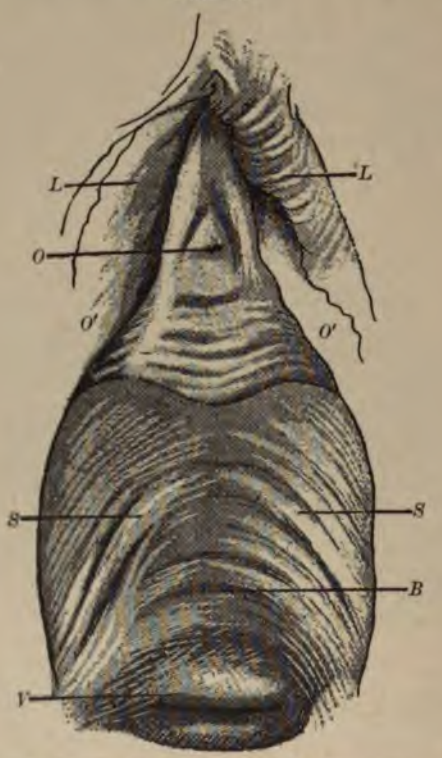

Pawlik's Vaginal Trigone, corresponding to Lieutaud's vesical trigone: *L*, labia minora; *O*, meatus urinarius; *O*,' *O*,' urethral ledge; *S*, *S*, lateral folds corresponding to the sides of the vesical trigone; *B*, fold corresponding to the basis of the vesical trigone; *V*, vaginal portion of uterus.

the posterior vaginal wall drawn down with a single Sims speculum. A delicate catheter (Fig. 138) is then carried into the bladder, and

FIG. 138.



Pawlik's Ureteral Catheter.

poised between thumb and index-finger. The position of the end of the catheter is plainly seen in the vagina as it sweeps gently over the floor of the bladder. The urethral orifice is to be sought for about an inch back of the internal opening of the urethra and

about one-half or three-quarters of an inch from the median line on either side. This position of the ureter, however, is not constant, and cannot be relied upon alone. Far more characteristic is the slight tripping sensation given to the point of the catheter as it glides over the ureteral prominence. As soon as this sensation is perceived the catheter must be at once brought back to the place where it was felt, and gentle attempts made to engage its point by repeatedly carrying the handle upward and outward to the other side, and directing the point toward the posterior lateral wall of the pelvis. With each of these sweeping motions the catheter is rotated until the point is directed fully outward or slightly upward. Once caught, the catheter sweeps readily in, and, if lightly held, directs its own course, the fingers simply following. The anterior vaginal wall is seen lifted up in advance and to one side of the cervix, forming a distinct pocket on the side on which the ureter is being catheterized.

Before trying to catheterize the ureters the bladder is injected with about six ounces of a blue anilin solution, which removes rugosities of the bladder, makes Pawlik's folds more distinct, and by the difference of the color of the fluid shows when the ureter has been reached.[1]

On withdrawing the stopper of the catheter a few drops of urine run out, and then cease, keeping up an intermittent discharge entirely characteristic. The catheter can be pushed beyond the brim of the pelvis, up to the pelvis of the kidney, by introducing an index-finger into the rectum, and lifting and guiding the catheter while it is being pushed up. Sometimes the ureters may even be catheterized without anesthetizing the patient.

3. *Palpation of the Ureters*—When there is no disease the ureters can usually be felt with facility as more or less flat cords about one-eighth of an inch in diameter, movable to an extent of one-half to three-quarters of an inch, in the loose pelvic connective tissue at the side and in front of the cervix. The patient may be in the dorsal position, and both hands used, the homonymous index-finger in the vagina (*i. e.* the left for the left ureter, the right for the right), or she may be in Sims's position. In both positions the vaginal roof is pushed well upward, when the ureter may be felt, hooked, brought down, and compressed.

A practical and safe method of obtaining urine from one ureter alone is very desirable in order to locate and treat disease there, and to ascertain the presence and healthy condition of the second kidney, when the removal of one is contemplated.

It goes without saying that the *pulse* should be counted and its character noted, the *temperature* measured with a clinical thermometer, and such other investigations made in regard to the condition of *other organs* and the *general health* of the patient as the case may call for.

[1] Howard Kelly, *Annals of Gynecology and Pædiatry*, August, 1893, p. 642.

PART VI.

TREATMENT IN GENERAL.

THE treatment of gynecological diseases is *preventive* and *curative*, the latter again is carried out by *external manipulations*, by the *internal use of drugs* or by *electricity*.

Preventive Treatment.—What can be done and is to be attempted in the way of preventing gynecological diseases, can easily be inferred from a study of the chapter on etiology, but the beginner must not be too sanguine in his expectations or too positive in his demands, if he will avoid disappointment or the loss of his patient. As soon as his advice clashes with that of the dressmaker or social habits, ninety-nine women will be decided by these last two factors for one who will follow the first. Where this antagonism does not come into play, much good may, however, be done by timely warning.

At puberty girls should not be exposed to mental overwork, and at no time should the practice of music be carried so far as to engender nervousness. All sexual excesses and unnatural practices should be avoided. The skin should be kept clean. The muscles should be strengthened by exercise and games. Some time, at least an hour every day, should be spent in the open air. Good, wholesome food should be taken at proper times, and in sufficient quantity to make up for the physiological tissue-consumption. The bladder should be emptied when a desire is felt to do so. An evacuation from the bowels should take place once or twice a day. The body should be sufficiently covered, especially in the cold season. In winter time women should wear woollen drawers, but they should not be "closed," as this tempts to neglect proper evacuation of the bladder. Corsets ought to be banished from the dress of children, girls, and young women. All of them ought to go early to bed—as a rule, not later than ten o'clock. During menstruation they should carefully avoid exposure, violent exercise, or sexual intercourse. If suffering from chronic pelvic inflammation they had better abstain from marriage. Good midwifery, both as to surgical help and conscientious use of antiseptics, not only in hospitals, but in private practice,[1] goes far to prevent later disease. Puerperæ should be kept in bed until the uterus has receded into the pelvis.

Lacerations of the cervix and the perineum, if not healed immediately after delivery, should be repaired by the proper operations before the bad effects consequent upon them make their appearance. Women should be told to what enormous dangers they expose themselves by availing themselves of abortionists, and miscarriages should

be treated with great care according to the tenets of modern midwifery, and especially all the products of conception should be removed. Antiseptic precautions should be taken as far as feasible, even in minor gynecological operations and examinations. A man who has had a gonorrhea should not marry before a careful examination by a competent judge has ascertained that he is perfectly cured.

External Treatment.

A. *Applications.*—Applications of medicinal substances are made to the vagina or to the uterus. The patient is in Sims's position, the parts are exposed with Sims's speculum and my depressor (p. 147). After having wiped the mucus off with absorbent cotton, the vaginal vault is painted with common tincture of iodine, by means of a large camel's-hair brush on a long handle. The throat-brushes with wooden handle that are found in the drug-stores, are quite serviceable for this purpose. As the iodine smarts when it reaches the vulva, care should be taken not to fill the brush too much, and to wipe the superfluous fluid off with absorbent cotton before the patient rises. In the vagina I prefer the common tincture of iodine to Churchill's, as I have seen the latter produce ulceration.

For applications to the interior of the uterus an applicator is needed.

[1] The writer has for the last ten years repeatedly called the attention of the profession to the importance of aseptic and antiseptic midwifery. He was the first to introduce strict antisepsis in this country. On the first day of October, 1883, the whole arrangement of the New York Maternity Hospital was changed, and the results were so striking that the example was soon followed by others, and that the treatment then inaugurated has been kept up ever since with insignificant modifications. His first report was given in a paper on "The Prevention of Puerperal Infection" read before the Medical Society of the County of New York, and published in the *Medical Record*, December 29, 1883, vol. xxiv., pp. 703–706. Soon followed an article under the same title, especially on the use of injections, published in the *New York Medical Journal*, March 1, 1884. Then came a paper on "Puerperal Diphtheria" published in *Transactions, Amer. Gynecol. Soc.*, vol. x. 1885, pp. 96–113. Next, he treated the whole subject of puerperal infection at greater length in book-form in his *Practical Guide in Antiseptic Midwifery*, Detroit, Mich., 1886, and in a long article on "Puerperal Infection" in the *American System of Obstetrics*, edited by Hirst, Philadelphia, 1889, vol. ii. pp. 290–378. The article on "Corrosive Sublimate and Creolin" in *Amer. Jour. Med. Sci.*, August, 1889, contained the only change he in the course of time found it advisable to make.

In hospital practice strict antisepsis is now used everywhere, but in private practice we lag yet in a deplorable way behind other countries, and the result is to be found in frequent disease and death among the well-to-do, which have nearly disappeared from the lying-in hospitals. It is to be hoped that the general practitioner soon will follow the lead of the expert obstetrician in this field. At my motion the following resolution was unanimously adopted on October 27, 1892; "In the opinion of the Section on Obstetrics and Gynecology of the New York Academy of Medicine, it is the duty of every physician practicing midwifery to surround such cases in private practice with the same safeguards that are being used in hospitals" (Garrigues, "Reprehensible, Debatable, and Necessary Antiseptic Midwifery, *Med. News*, Nov. 26, 1892).

Budd's (Fig. 139), which is a flexible flattened hard rubber stick, is as good as any, recommends itself by its simplicity, and is easy to keep

FIG. 139.



Budd's Uterine Applicator.

clean. It is sold straight, but it ought to be curved like a sound. This is easily done by warming it over an alcohol lamp and bending it.

A little absorbent cotton is fashioned so as to form a thin rectangular pledget, 3 inches long by 1 wide. The applicator is held at right angles a little inside of one of the ends and one of the sides, and the cotton is rolled round it with the fingers of the left hand, going down in a spiral line toward the handle. By a little practice it becomes easy to put it on smoothly and of variable thickness, according to the caliber of the cervical canal. The thick mucus that is often found in the cervical canal must first be wiped off with dry cotton, or, if this proves impossible, it is coagulated by applying a mixture of equal parts of tincture of iodine, tannin, and carbolic acid.

Some prefer to make applications to the inside of the uterus by means of a glass pipette, or through a cervical speculum (p. 148). If the canal is too narrow it must be dilated (p. 152). For the endometrium, I use mostly Churchill's tincture of iodine, liquor ferri chloridi undiluted, chloride of zinc (20 to 50 per cent.), and occasionally sol. argent. nitrat. 1 to 12, or pure carbolic acid.

As some patients are very sensitive to intra-uterine applications, it is best to restrict the first application to the cervix, and gradually penetrate into the cavity of the body up to the fundus.

Drugs may also be made up as ointments, and applied in the interior of the womb by means of *Barnes's ointment carrier*, a silver tube with large side openings and a piston. Or they may be incorporated in small rods, so-called *bacilli*, made with cacao-butter or althæa, which are pushed through a metallic tube with open end (*E. Martin's pistol*). Powders, especially boracic acid, iodoform, and aristol, may be applied in the interior of the uterus by means of a similar instrument. All these tubuliform instruments have, however, the grave drawback that it is next to impossible to keep them clean. I have, therefore, of late years, discarded them all in favor of the applicator wound with cotton.

Applications are, as a rule, repeated twice a week.

B. *Injections.*—Injections are made into the vagina, the uterus, the rectum, and the bladder, with plain or medicated water, by means of a syringe.

Vaginal injections are used to greatest advantage in the dorsal posi-

tion on a bed-pan (Fig. 140). A good bed-pan should be large, and have an opening near the bottom with an attached rubber tube to carry off the water into a larger vessel placed under the bed. If it does not have such a contrivance, and is not large enough, the water may

FIG. 140.

Bed-pan, holds nearly seven pints: *A*, tube closed with plug, *B*, unless used to make connection with rubber hose leading to vessels placed under the bed; *C*, tube for emptying pan; *D*, cover to be screwed on the same when not in use.

be gradually pumped out by means of a bulb-and-valve syringe (Davidson's syringe) while running into the bed-pan.

Patients who are obliged to help themselves may also take their vaginal douche standing over a chamber-pot placed on a chair, or sitting on a bidet.

It is best to use a *fountain syringe;* that is, a bag of soft rubber, or a metal pail, a so-called *douche-can*, with a long soft rubber tube and a nozzle of metal or preferably hard rubber. The nozzle should only have holes at or near the end, and it should be pushed in so far that the openings are behind and above the os uteri. If there are side openings lower down or the nozzle is not introduced to the proper depth, an opening may face the os and some fluid be injected into the uterus, which gives rise to a very painful and alarming uterine colic.

If the chief aim of the injection is to combat inflammation and cause absorption of inflammatory exudations, plain hot water is the best. The amount should not be less than two quarts. The temperature should be as high as the patient can stand it—*i. e.* so that she just can hold her hand in it (110° to 115° F.). In exceptional cases hot water increases instead of relieving pain, and is then advantageously replaced by lukewarm water. Cold injections are injurious.

For merely cleansing the vagina—for instance, when a pessary is worn—a pint of tepid water suffices, and its effect may be increased by adding a heaping teaspoonful of common salt or bicarbonate of sodium.

If an astringent is called for, alum, borax, or equal parts of sulphate of copper and alum are dissolved in the water. Of alum or borax, a teaspoonful is added; of the mixture of copper and alum, only half a teaspoonful.

If there is a spongy os uteri giving rise to hemorrhage, I use half a teaspoonful of the liquor ferri chloridi to a pint of water.

For antiseptic injections carbolic acid (1 to 2 per cent.) or creolin ($\frac{1}{2}$ to 1 per cent.) are used. The latter is also an excellent hemostatic, but in some patients it produces a smarting sensation. Bichloride of mercury should be avoided, except for gonorrhea, on account of its poisonous properties,[1] and the solution should not be stronger than 1 to 3000 or even 5000.

As an emollient injection a decoction of flaxseed tea or slippery-elm bark, a heaping teaspoonful to each quart of water, is good.

Vaginal douches are, in chronic cases, as a rule, used morning and evening, and in acute three times a day, or even every three hours.

Intra-uterine injections are much more dangerous than vaginal injections, and should always be administered by the physician himself. We distinguish between small and large intra-uterine injections. The former are really only applications of drugs made on a larger scale. The injection is made by means of a small glass syringe with a long nozzle, with one or more fine openings near the end (Fig. 141). Having seen several cases of alarming collapse follow the use

Fig. 141.



Braun's Uterine Syringe.

of this method, and knowing that it has been fatal in the hands of others, I have entirely discarded it.

Large uterine injections are used for cleaning and disinfecting the uterus and for checking hemorrhage. If the cervix has been thoroughly dilated before injecting, a single-current tube is preferable, as it leaves more room for evacuation of large débris. For this purpose I find the so-called soft-metal male catheters sold in the stores of the instrument-makers very convenient, as they are easily bent so as to adapt themselves to any shape of the uterine canal. By adding a flange at the open end, connection is easily established with a fountain syringe. If the cervical canal is not so wide, Bozeman's double-current uterine tube (Fig. 142), or its modification by Fritsch, which is easier to clean, should be used.

The patient is placed on a table, unless she is so weak that it is deemed better to leave her in her bed, and only move her sufficiently beyond one edge to have a free back-flow from the vagina. The outer

[1] Garrigues, "Corrosive Sublimate and Creolin in Obstetric Practice," *Amer. Jour. Med. Sci.*, Aug., 1889, vol. xcviii. pp. 109–128.

leg is placed on a chair. Whether she remains in bed or is placed on a table, a rubber sheet or oil cloth is pushed in under her buttocks, and pinned with two pins so as to form a funnel, the lower end of which opens into a slop-pail. Intra-uterine injections ought only to be given in the dorsal position in order to avoid the entrance of the fluid through a possibly dilated tube into the peritoneal cavity. The vagina is first disinfected by injecting some of the fluid and by swabbing the wall thoroughly with large pieces of absorbent cotton dipped in the same. Cusco's speculum is introduced. The intra-uterine tube is attached to the tubing of the fountain syringe, and, all air having been expelled, is pushed up to the fundus of the uterus while the fluid is turned on. The physician watches the flow all the time to make sure that there is no obstruction. I use about a quart for the vagina and from a pint to a quart for the uterus. When the uterus is deemed to be sufficiently washed out, it is squeezed in order to

FIG. 142.

Bozeman's Double-current Uterine Tube.

remove all fluid from its cavity. Finally, the vagina is again douched, and the perineum depressed so as to allow all fluid to flow off.

For these injections I prefer creolin (1 per cent.), as it is a non-poisonous reliable disinfectant and an excellent hemostatic. I have never seen any untoward symptoms follow this kind of injections.

Rectal injections, enemas, or *clysters* are used for emptying the lower part of the bowels, or as a vehicle for medicinal substances to be applied to the diseased mucous membrane, or in order to exercise an influence on the pelvic organs, or to overcome an obstruction in the intestine, or to mark the course of the intestine (p. 156). If the object is only to cause a movement of the bowels, plain lukewarm water may be used, or a teaspoonful of salt may be added, or soap-suds or an infusion of linseed-meal (a tablespoonful to a quart) may be injected. In cases of constipation with impaction of hard feces the following is an excellent enema: a teaspoonful of inspissated ox-gall, a tablespoonful of glycerin, a tablespoonful of castor-oil, and a heaping teaspoonful of salt, to a quart of linseed-meal infusion. The ox-gall is stirred with the warmed glycerin, the oil is added, then the flaxseed tea, and finally the salt.

For tympanitis an enema with a teaspoonful of oil of turpentine,

a tablespoonful of castor-oil, and a quart of soap-suds or flaxseed tea is good. All these enemas are given lukewarm.

In diseases of the rectum often astringents or sedatives are used in injections. As the fluid in these cases is meant to be retained for some time, the amount should be small (℥j to ℥iv).

Large injections (1 to 2 quarts) of hot water (110° F.) into the rectum have been recommended instead of vaginal injections in uterine and other pelvic disease.[1]

After operations rectal injections of a pint of tepid water may be used to relieve thirst. Similar injections of very hot water may be used to combat collapse caused by loss of blood.

All rectal injections are best given with the patient lying on her left side. Evacuant enemas are preferably administered by means of a bulb-and-valve-syringe (Davidson's), but where it is desirable that as much water as possible should enter the bowel, the fountain-syringe used with very little pressure is by far better.

Vesical injections are used very much in diseases of the bladder. The patient occupies the dorsal position. For large injections *Keyes's*

Fig. 143.



Keyes's Irrigator for Bladder.

irrigator (Fig. 143) may be used. It is essentially a fountain-syringe with a two-way stop-cock, which allows alternately to fill and empty

[1] J. R. Chadwick, *Trans. Amer. Gyn. Soc.*, 1880, vol. v. p. 282.

the bladder simply by turning the stopcock. It may be used with any hard or soft catheter. Where shreds are to be washed out, *Nott's double-current catheter* (Fig. 144) with its large eyes will be found to

FIG. 144.



Nott's Double-current Catheter.

answer a good purpose. For smaller injections, Thompson's rubber bag with stopcock (Fig. 145), inserted into a soft catheter with hard

FIG. 145.

Thompson's Rubber-bag with Stopcock.

rubber mouth-piece is handy. For the injections is used plain water, or solutions of chloride of sodium (1 per cent.), salicylic acid (1 per thousand), boracic acid (3 per cent.), tannin (½ to 1 per cent.), carbolic acid (½ per cent.), creolin (½ per cent.), permanganate of potassium (½ to 2 per thousand), nitrate of silver (2 to 5 per thousand), etc. The amount of fluid used varies from half a pint to a quart; for small injections one to four ounces are used. Generally the fluid should be pleasantly lukewarm (95° F.), but as hemostatic hot or ice-water is used. The irrigation of the bladder is repeated once, twice, or three times a day.

Intravenous, subcutaneous, or intraperitoneal injection of a hot solution of 6 parts of chloride of sodium in hot water (110 to 115° F.) is used with great benefit to counterbalance loss of blood in operations. (See Uterine Fibroids.)

C. *Curetting.*—The instruments used for scraping the inside of the uterus have been described in the preceding chapter (p. 151). The

patient is placed on a table arranged for intra-uterine injection (p. 168). As the procedure is often protracted and painful, she ought to be anesthetized.[1] The vagina and uterus are disinfected with creolin (p. 169). The cervix is dilated (p. 152). The condition of the inside of the uterus is ascertained by sound (p. 150) or finger. The index-finger is preferable if the cervix admits it. In introducing it counter-pressure is made on the fundus with the other hand. The nail of the finger is often used itself as curette. It is safer than, but not so efficient as, instruments. In gynecological cases I use the dorsal position, introduce the curette through Cusco's speculum (p. 142), and move it up and down along the surfaces and edges and from side to side along the fundus. In cases of incomplete abortion I turn the patient on her left side and work with the left index-finger and the large dull wire curette simultaneously. The scraping should be continued until everything is removed and the inside of the uterus is smooth. Then the patient is turned back into the dorsal position. Finally, the uterus and vagina are again disinfected, and a tampon is put in the latter until the following day. The hemorrhage is not very considerable. It is very rarely necessary to renew the tampon. On changing it a vaginal injection with creolin or carbolic acid is given, and after its final removal twice a day as long as there is any discharge. The patient is kept in bed for four days. If there is any pain, which is an exception, an ice-bag is applied over the symphysis and the patient is given an opiate.

Thomas's dull-wire curette being rather short to be used through Cusco's speculum (he uses himself Sims's position and speculum), I have had one made that is eleven inches long. The instrument should only be used for scraping in the direction from the fundus to the os and along the fundus. In moving the curette up toward the fundus great gentleness should be used, as otherwise the instrument may perforate the uterus. If this should happen, the beginner need not be particularly alarmed. It has happened twice to me, and no bad consequences were observed, but in such a case it is necessary to desist from washing out the uterus, an omission which, of course, in other respects is undesirable. The smaller the loop of the curette, the greater is the danger of perforation. We should, therefore, always use as large an instrument as will enter the cervix and is in reasonable proportion to the mass to be removed. In cases of incomplete abortion before the end of the second month, when the large dull-wire curette does not enter, *Récamier's curette* (Fig. 146) is sometimes useful.

D. *Tamponade.*—The word tampon is French, and means a small mass of cotton or other soft material which is carried into a wound or cavity for the purpose of filling it, so as to prevent hemorrhage, or

[1] This applies to strictly gynecological cases; in cases of hemorrhage due to recent abortion, anesthesia can be dispensed with except in very nervous women.

applying drugs to it, or exercising pressure on it. A tampon being used for so very different purposes, becomes a very different thing, and we will, therefore, consider separately the application of medi-

FIG. 146.

Récamier's Curette.

cated pledgets in the vagina, the packing of the vagina, the hemostatic vaginal plug, and the tamponade of the uterus.

Pledgets in the Vagina.—Small rolls of absorbent cotton, about 2½ inches long and 1 inch thick, with a string of strong crochet-yarn fastened round the middle and made long enough to hang an inch or two outside the vulva, are impregnated with some medicinal substance and pushed up to the posterior vault of the vagina. They are, as a rule, withdrawn morning and evening, when an injection is made and a new pledget put in. The cotton may be impregnated with different substances. The most generally useful and least objectionable is pure glycerin, which produces a watery discharge, relieves pain, and scatters swelling. I have used iodine-glycerin (5 per cent.) and an iodoform ointment,

℞. Iodoformi,
Balsami Peruviani, āā ʒj;
Vaselinæ, ℥j;

but have always come back to the plain glycerin. Of late years I use much ichthyol-glycerin (5 per cent.), which has a special resolving power and some anodyne effect. As an astringent, for instance, for a spongy cervix, tannin-glycerin (10 per cent.) is very efficient, but, as it stains the clothes, it is necessary to wear a napkin with it. Others prefer boroglyceride, or sulphate or acetate of alumina, in the proportion of ℥j to glycerin Oj.[1]

Packing of the vagina differs from the application of a pledget, as heretofore considered, by the combined action of drugs and pressure in the treatment of diseases of the uterus, ovaries, and periuterine structures. The patient is placed in the knee-chest position, Sims's speculum is introduced, and the upper third or fourth of the vagina is packed tightly with pledgets of cotton (Fig. 147). The uppermost, which covers the cervical portion and part of the vaginal roof, should be saturated with pure glycerin and spread with the above-mentioned iodoform ointment. The others are rolled into balls and

[1] Wiley, *Med. Record*, October 8, 1887, vol. xxxii. p. 483.

put in dry. For the first few weeks the tampon is renewed every

FIG. 147.

Packing the Vagina.

two days, and subsequently every three days, but may be left in a whole week without becoming foul.[1]

By this method adhesions may be lengthened, cicatrices stretched, exudations absorbed, congestion relieved, and the vagina lengthened; but if the parts are too tender to stand the pressure, other methods must first be used to overcome the sensitiveness.

The Hemostatic Vaginal Plug.—Plugging of the genital canal is one of the most potent remedies against hemorrhage. A vaginal plug must be put in in such a way as fully to distend the vagina, for which often two dozen good-sized pieces of cotton are necessary. Generally I prefer common cotton batting to any other material. The balls should be soaked in a 1 per cent. creolin emulsion and squeezed dry. Thus they acquire both styptic and antiseptic properties. The first may also be obtained by squeezing them out of an alum solution, the latter by using carbolized water (1 per cent.).[2]

[1] V. H. Tagliaferro, "The Application of Pressure in Diseases of the Uterus, Ovaries, and Periuterine Structures," *Atlanta Medical Register*, September, 1882.

[2] A stronger solution takes off the whole epithelium.

When there is much bleeding from an accessible surface—*e. g.* after curetting a cancerous cervix—the three or four upper pledgets which immediately touch the cervix should be wrung out of a mixture of one part of liq. ferri chloridi and ten parts of water. The liquor should never be used undiluted on a tampon. I have seen it cause deep ulcers which took weeks to heal, and the removal of the tampon is very painful. Bichloride of mercury is not good for tampons, as by imbibition with blood they lose their antiseptic properties.

Instead of cotton batting, a roller bandage, lampwick (Foster), or, if nothing else can be obtained, clean pocket-handkerchiefs, may be used, all of which ought to be treated with disinfectants. A strip of iodoform gauze four finger-breadths wide is good, and may be made more antiseptic and styptic by powdering it with equal parts of iodoform and tannin. The iodoform gauze acts at the same time as a drain, and is, therefore, particularly appropriate in the treatment of cancer, but on account of the very porosity of this material I would not rely on it in severe hemorrhage.

The vaginal tampon is best applied in Sims's position and with Sims's speculum. The rectum and bladder having been emptied, the first pledgets are placed around the cervix and then over it, and the same principle should be followed if a continuous long strip of some kind is used. Whatever we use should be evenly and tightly put in with a strong pair of dressing-forceps until the vagina is filled all the way down to the entrance (but not the vulva). If the patient cannot pass her urine spontaneously, it must be drawn four times a day, but that is an exception. The tampon should be removed and, if necessary, renewed within twenty-four hours, except if made of iodoform gauze, when it may stay in for five or six days if necessary.

If a strip of some substance has been used, all that is necessary for its removal is to pull on the lower end, which should be left hanging just outside the vulva. If cotton pledgets have been employed, the patient is again placed in Sims's position, Sims's speculum is introduced a short distance, some pledgets are pulled out with the dressing-forceps, and the speculum is gradually pushed farther in until the whole tampon has been removed. Then the patient is turned on her back and given a vaginal injection with creolin.[1]

Tamponade of Uterus.—For the uterine cavity only iodoform gauze should be used. This method is not only used to great advantage in post-partum hemorrhage, which does not concern us here, but likewise for many gynecological conditions, either as hemostatic or for applying medicinal powders or fluids to the mucous membrane of the womb, or for causing changes in the structure of the uterine muscular

[1] To attach a string to each pledget does not facilitate their removal. The so-called *kite-tail*, made by tying all the pledgets to one string, is indeed more easy to remove, but more troublesome to put in.

tissue, especially in chronic endometritis and metritis. It is used both in the cervix and in the body of the womb. Even a nulliparous uterus will admit a strip of gauze 8 inches long and ½ inch wide. On account of the antiseptic properties of the iodoform the intra-uterine tampon may be left undisturbed for five or six days.[1]

I have constructed a forceps for its application through an undilated cervix (Fig. 148).[2]

Abdominal Tampon.—The iodoform-gauze tampon is even used in the abdominal cavity. Sometimes there may be considerable oozing

FIG. 148.

Garrigues's Intra-uterine Packing Forceps.

of blood after a laparotomy, which does not yield to hot water poured into the peritoneal cavity. In such cases the hemorrhage is sometimes checked effectually by packing the pelvis with iodoform gauze through the abdominal wound. The end is left hanging from the lower end of the wound, and in closing the same one or two of the lowest sutures are left untied till the next day and the removal of the tampon. In the mean time sufficient adhesive matter has been formed to shut off the abdominal cavity from that part where the tampon was put in, but the adhesions are, of course, weak, and it would be too great a risk to use injections through the wound. It is a good plan first to introduce the centre of a large square piece of iodoform gauze and make a pouch of it, which is subsequently filled with long strips of gauze the ends of which remain outside (Mickulicz's method). This tampon acts not only as a plug, but at the same time, on account of the porosity of the gauze, as a drain. Sometimes it is necessary to combine the intra-abdominal tampon with one in the vagina. In order to remove the abdominal tampon, each strip is pulled out separately and finally the surrounding gauze by pulling on a strong silk thread inserted for that purpose in its center before introducing it.

E. *Hemostasis.*—Besides the hemostatic *tampon*, of which we have

[1] Fritsch, *Klinische Vorträge*, No. 288, Leipzig, 1886.
[2] *Amer. Jour. Obst.*, vol. xxv. No. 1, January, 1892.

just spoken, other means of preventing or checking hemorrhage are available: *hot water, styptics, cauterization, ligature, suture, and forci-pressure.*

Hot water is used in vaginal injection (p. 166 *et seq.*) before operations in order to diminish bleeding during them (T. A. Emmet). It is also used to check hemorrhage during operations. Thus a stream of some hot antiseptic solution may be kept continually flowing over the field of operation[1] or may occasionally be directed against the bleeding surface. At the end of laparotomy hot water is often poured by the pitcher or through a finger-thick glass tube right into the peritoneal cavity. Hot-water injections are also used as a hemostatic independently of operations both in the vagina and in the uterus (pp. 167 to 169).

Styptics, especially alum, tannin, and chloride, persulphate or subsulphate of iron (Monsel's solution), are used as applications (p. 165), on tampons (p. 172), or in injections (p. 167). The undiluted liq. ferri chloridi or subsulphatis may be applied with cotton to small bleeding surfaces. Diluted with 10 parts of water, it may be used in injections or left in on a tampon. A very convenient way of using styptics on small wounds is in the shape of dry *styptic cotton* as sold in the drug-stores.

Cauterization is an excellent hemostatic and, at the same time, an antiseptic, but as it leaves an eschar, it can, as little as styptics, be used where healing by first intention is aimed at. The dry heat of the actual cautery is so powerful a hemostatic that it may even be used to sever the pedicle of an ovarian tumor without using any ligature. A very convenient apparatus is *Paquelin's thermo-cautery* (Fig. 149), in which a tip of platinum may be kept at different degrees of heat by a more or less abundant supply of benzine vapor.

Independently of its hemostatic effect, cauterization is often used as an antiseptic to sear a wound surface, and thus make it impenetrable to bacilli. Thus, some use it on the stumps left after removal of the ovaries or the uterus.

Cauterization by means of the *galvano-cautery* will be described under Electric Treatment.

Ligature.—Spurting arteries, or more rarely bleeding veins, may be ligated with silk or catgut, according to the general rules of surgery, but in gynecological practice we are oftener than in other departments obliged to tie, not the isolated bleeding vessel, but a more or less considerable mass of the surrounding tissue with it (*mass ligature*). Arteries may be tied where they are severed or in continuity.

Ligature of the Uterine Artery.—The uterine artery may be tied from the vagina. The patient is placed in the dorsal posture with raised knees. A large Sims speculum is introduced. The operator

[1] Geo. Englemann of St. Louis, *Trans. Amer. Med. Assoc.*, 1885.

tries to locate the artery by its pulsation. The cervix is pulled well over to one side with a volsella. A middle-sized, strong, curved

FIG. 149.

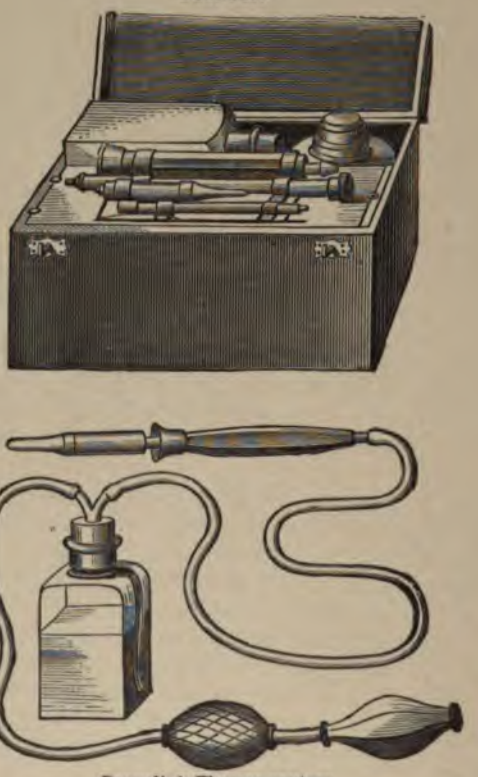

Paquelin's Thermo-cautery.

needle is introduced into the anterior part of the fornix of the vagina, a finger-breadth [?] from the cervix and on a line with its anterior circumference. The needle is carried deep in, and pushed out on a line with the posterior wall of the cervix. Next, the ligature is tied very tightly. If needed, the same may be done on the other side.[1] There is danger of comprising the ureter in the ligature.

After making several dissections, Cushing became convinced that the only point in which the artery could be reached without endangering the ureter is midway between the body of the uterus and the ureter. The artery is about the size of the radial, and can be felt with the finger through the roof of the vagina in thin subjects, its

[1] A. Martin, *Pathologie und Therapie der Frauenkrankheiten*, Leipzig, 1885, p. 22.

pulsations being clearly perceptible. He has invented an instrument for ligating it (Fig. 150). Each blade consists of a small canula, curved at its terminal end, so that when the blades are united and closed they form a half circle, and the two canulas when joined represent a single tube from handle to handle. The end of each canula is furnished with a trocar point.

FIG. 150.

Clinton Cushing's Instrument for Tying the Uterine Artery: *a*, trocar-pointed end of canula; *b*, lock; *c*, posterior end of canula, where the wire enters on one blade and comes out on the other.

The method of using this instrument is as follows: Place the patient on the left side and introduce a large Sims speculum; seize the cervix with a strong volsella, draw it down slightly and steady it; now pass one of the blades through the vaginal roof *a third of an inch*[1] to the side of the cervix, and a third of an inch behind the median line running from the cervix to the side of the pelvis; push the canula into the parametrium one inch deep, keeping the point within half an inch of the uterus. Now introduce the other blade in front and to the side of the cervix in a similar manner, lock the handles of the instrument, and the curved ends of the canulas will come together in the connective tissue of the broad ligament, above the uterine artery and between the ureter and the uterine body. Next take a piece of steel wire, No. 23 gauge, made quite sharp at one end and with a loop at the other for the attachment of ligatures, and pass it around through the canula and draw the ligature into its place. The sharp end of the wire pierces any portion of the connective tissue that may become engaged between the ends of the canulas. The blades are now unlocked and removed separately, and the ligature is left in their track and firmly tied.[2]

Fritsch[3] is opposed to methods by

[1] Italics mine. I consider this distance much safer than Martin's "finger-breadth."
[2] Clinton Cushing of San Francisco, *Med. Record*, May 12, 1883, vol. xxiii. p. 529.
[3] H. Fritsch, *Billroth und Luecke, Handb. der Frauenkrankheiten*, Stuttgart, 1885, vol. i. p. 949.

which the uterine artery is tied by means of a mass ligature applied through the vaginal roof. He says by so doing we do not know what we tie, and even if the uterine artery is included in the ligature, it is not sure that it is made impervious. He makes an incision an inch and a quarter long in the posterior roof of the vagina on the right and the left side. This incision divides, as a rule, first the two vaginal branches. Next he cuts deeper until he has severed the uterine artery, which is then seized and tied or surrounded by a mass ligature. Then the same is done on the other side. The wounds are filled with iodoform gauze in order to prevent rapid healing and the formation of a collateral circulation.

Ligature of the Internal Pudic Artery.—As a rule, this artery should be cut down upon where it bleeds and both ends tied, but it may also be tied in continuity by cutting through the skin and fascia in an oblique line running downward and outward a little above the spine of the ischium, separating the fibers of the gluteus maximus, holding them apart with retractors, and tearing the deep fascia.

Sometimes sutures are used for hemostatic purposes—*e. g.* a running catgut suture may be put over a bleeding tear in the broad ligament; or an artery imbedded in tissue may be made to stop bleeding by passing a needle with thread under its course and tying; or a bleeding surface of the abdominal wall may be excluded from the abdominal cavity by folding the wall, so as to press one-half of the bleeding surface against the other, and put sutures through from side to side as in a mattress (*mattress suture*). These sutures may be made more efficacious by using *quills*, a couple of lead-pencils or pen-holders serving as such.

Fig. 151.

Koeberlé's Artery-Clamp.

Forcipressure.—Much time is saved by substituting a temporary strong pressure with Koeberlé's clamp (Fig. 151), a kind of artery-forceps with catch that has been modified by many other operators, and therefore goes under different names (Péan's, Spencer Wells's, Tait's, etc.). When made of proper size and left for twenty-four hours, such forceps may be made to secure even the uterine and the ovarian arteries in the extirpation of the uterus; but in most operations small clamps, five or six inches long, are used temporarily, and removed toward the end of the operation when the bleeding is stopped. If, exceptionally, a vessel yet bleeds, it may, of course, be seized again with the forceps and secured with a ligature.

F. *Dilatation* and G. *drainage* are so intimately connected that we

will treat of them together. In regard to dilatation of the cervix the reader is referred to what has been said on the subject in the chapter on Examination (pp. 152–154).

Dr. Outerbridge of New York has constructed an ingenious *instrument for permanent dilatation* of the cervix and drainage of the uterus. It consists of a silver- or gold-plated steel wire (Fig. 152), made so as to form an anterior and posterior blade, with a slight eversion at one end and bent at right angles at the other. It is self-retaining, and varies in length and curvature. For its introduction the patient may be in Sims's or in the dorsal position. The univalve or bivalve speculum is introduced, the cervix steadied with a tenaculum, and the dilator put into the grasp of a carrier made for the purpose (Fig. 153). It consists of a fork with a movable ball and spiral spring sliding up and down a metal rod with handle. The dilator is introduced five or six days before expected menstruation, left in during, and at least from five to eight days after the same, unless conception takes place and menstruation does not come on. The instrument may be removed with a finger or by means of speculum and tenaculum or a blunt hook.[1]

Fig. 152.

Outerbridge's Permanent Dilator of Cervix.

Fig. 153.

Carrier for Outerbridge's Dilator.

Sometimes a *perforated glass or hard-rubber stem* is introduced into the uterus, and on the same principle I have had a *glass vaginal plug* made with an opening at the top.

Sometimes an opening is made with knife or trocar in the vaginal roof, behind the uterus, with or without laparotomy. This opening

[1] P. E. Outerbridge, *Med. Record*, April 20, 1889, vol. xxxv. p. 430.

is enlarged by means of a diverging uterine dilator and a *soft-rubber drainage-tube* inserted. The same may be carried through the abdominal wound. If it is only introduced through an opening in the vagina into a space shut off from the peritoneal cavity, the drain should have a T shape, the upper bar of the T serving as wings to retain the tube in situ.

In laparotomies often a *hard-rubber* or *glass tube* (Fig. 154) is left leading from the bottom of Douglas's pouch or of a cyst which cannot be entirely removed to the lower end of the wound, where it is held between the lips of the incision, by the sutures. The tube is closed with a stopper of iodoform gauze, and the accumulating fluid pumped out at short intervals—in the beginning every hour—by means of a small glass syringe and attached rubber tube. It is still better to utilize the capillarity of iodoform gauze and fill the tube loosely with a strip of this material, through which the fluid will trickle out.

FIG. 154.

Abdominal Glass Drainage-tube.

There are also *double-current drainage-tubes*, which allow the washing out of a cavity without disturbing the dressing (Thomas's and H. Sims's).

Great diversity of opinion obtains among leading gynecologists as to the frequency with which abdominal drainage should be used and the length of time the tube should be left in. The more strictly antisepsis is carried out during operations the less drainage becomes necessary, and the absorbent power of the peritoneum may to a great extent be relied upon to remove blood and serum from the abdominal cavity.

We have already spoken of the use of *iodoform gauze* for drainage of the uterus and the abdomen (pp. 175–176). For further particulars, see Ovariotomy.

H. *Bloodletting.—Leeches*, from two to four in number, may be applied through Fergusson's speculum to the vaginal portion. In order to prevent them from entering the uterus a small cotton plug should be placed in the cervical canal. This method is little used here.

The *artificial leech* may be substituted with advantage (Fig. 155).

Scarification.—In most cases no sucking apparatus is needed. A small spear (Fig. 156) is pushed to the depth of three-quarters of an inch into the vaginal portion in three or four places, and from half an ounce to two ounces of blood are withdrawn twice a week. The posterior lip is less sensitive than the anterior. If the flow does not stop of itself, the small openings are pressed together with a pledget of

cotton dipped into cold water, or if that does not suffice liquor ferri is applied or a hot douche is administered.

Fig. 155.

Reese's Uterine Leech. It consists of a glass cylinder with scale. By pressure on the plate, *A*, a lance-shaped knife is pushed into the tissue of the cervix to a depth regulated by screwing the disc, *l*, along the piston, *B*, and then withdrawn. By pulling the piston out a vacuum is created, into which the blood enters. The metal fitting, *C*, can be unscrewed, so as to allow the removal of the piston and the cleaning of the tube.

Bloodletting is a very valuable remedy in cases of chronic conges-

Fig. 156.



Buttle's Uterine Scarificator.

tion, not only of the uterus, but also of other pelvic organs. It has great power to relieve pain.

I. *Heat and Cold.*—We have spoken above of hot, lukewarm, and cold *injections* (pp. 166–171 and 177). Heat is applied to the abdomen in the shape of a flaxseed-meal *poultice* or a rubber bag filled with hot water or a double sheet of flannel wrung out of hot water. Sometimes the anodyne effect of such a *stupe* or *fomentation* is increased by sprinkling it with oil of turpentine or laudanum. Poultices or a small rubber bag with hot water may also be used in the vagina.

In acute inflammations an *ice-bag* or a *coil* with running ice-water is a more expeditious remedy, and checks in most cases the pain more efficaciously. Four layers of muslin should be inserted between the ice-bag and the skin in order to avoid local freezing.

When the acute stage is passed, *Priessnitz's compress*—*i. e.* a towel wrung out of cold water and covered with some waterproof material and held in place with a flannel binder—is preferable to both hot and cold applications. It is changed every six hours and becomes warm in a few minutes. This change from cold to heat is a powerful absorbent.

A great variety of *baths* may be used as valuable adjuvants in gynecological diseases. A tepid *general bath*, of a temperature slightly below blood-heat, taken for fifteen or twenty minutes twice a week, keeps not only the skin in good order, but has a marked soothing influence on irritated nerves. *Sitz-baths* of similar temperature may be taken for ten minutes once a day. The effect on the pelvic organs

may be enhanced by the use of a *bath-speculum* (Fig. 157), which is introduced into the vagina and allows the water to fill the same.

Fig. 157.

Bath-Speculum.

Turkish and *Russian baths* may sometimes be substituted for warm baths, but are often too irritating or too fatiguing. An *artificial steam-bath* may be improvised by placing an alcohol lamp under a chair and an open umbrella partly over the chair and partly over the patient lying in bed, and covering all well with blankets and waterproofs. If the patient is well enough, she may sit on the chair covered with a waterproof. Perspiration may also be induced by the *hot pack*. The patient is wrapped up tightly to the neck in a blanket wrung out of hot water, and covered with several layers of dry blankets. Perspiration should not be allowed longer than from half an hour to two hours.

Sea-baths are often very beneficial as a nerve tonic and to check a disposition to hemorrhage and leucorrhea. A complete *hydrotherapeutic* treatment may also do good. On a smaller scale cold water may be used to great advantage in the shape of *shower-baths*, *sponge-baths*, the *wet sheet*, or *towel-baths*. For a sponge-bath the patient stands in a tub and has a pailful of cold water standing at her side—the contents of which she presses all over her body with a large sponge.

For a sheet-bath a sheet is dipped into a pail of cold water and thrown from behind over the patient, who is rubbed with it for several minutes all over the body. Thereafter the wet sheet is exchanged for a dry warm one and the rubbing repeated until she is dry all over.

The towel-bath is less powerful, but by no means without effect, in keeping the skin in order, strengthening the nerves, and brightening the mind. It has the advantage that no help is needed for its administration. All that is required is three Turkish towels and a large basinful of cold water. The patient immerses one of the towels in the water, presses it a little, and washes the upper half of her body with it. Then she dries herself with the two other towels, and finally she repeats the procedure on the lower half of the body, except the feet, which in most people are treated to greater advantage with warm foot-baths.

Some European *springs* enjoy a particular reputation for their supposed effect on female complaints, such as Franzensbad and Marienbad in Austria, Ems and Kreuznach in Germany, and Plombières in France; but it would be a grave mistake to think that any watering-place can be more than an adjuvant in the proper treatment of diseases of women.

J. *Counter-irritation.*—*Tincture of iodine* is often painted once a

day on the skin over a swelling in the deeper parts. When the epidermis is hardened a little, it is well, in order to avoid cracking, to cover it with a compress soaked in the following wash:

℞. Acid. carbol,		♏xl;
Glycerini,		℥ss;
Aquæ,	q. s. ad	℥iv.

This allows one to continue the use of the iodine indefinitely. (Compare p. 165.)

Spanish fly blisters are sometimes used on the abdomen to combat inflammation in the deeper parts. A large blister is a painful remedy, and it has appeared doubtful to me if it is any better than other means; but half a dozen small blisters, 2–4 square inches, one of which is put on every evening, often relieve pain in chronic cases.

K. *Tapping and Aspiration.*—The difference between these two operations is only that in simple tapping a fluid is given outlet through the canula of a trocar by pressure from behind, and in aspiration by forming a vacuum in front; but on account of the greater efficacy of the latter method a smaller trocar, or even a needle, may be used instead of the large trocar used in simple tapping. The object is to remove a fluid collected in a normal cavity or a cyst. Tapping is used much less now-a-days as a separate and complete gynecological operation than a decade or two ago. Tumors are seldom tapped, the more radical operation of removal being preferred; but ascitic fluid has often to be evacuated by tapping. Tapping is used during ovariotomy to diminish the cyst, and aspiration is often used as part of a more comprehensive operation—*e. g.* in removing a pyosalpinx or opening a pelvic abscess. Aspiration through the vaginal roof is used to remove encysted peritonitic exudation or a collection of pus in the parametrium. Straight and curved, fine and large, trocars or needles may be needed. We have already spoken of the use of the aspirator for diagnostic purposes (p. 157).

A patient who is going to be tapped through the abdominal wall should sit on a chair or lie on her side with the abdomen turned toward the operator. The abdomen should be surrounded above and below the point selected for the operation with a sheet, the ends of which are crossed in front and pulled upon during evacuation. The object thereof is not only to produce the necessary pressure for the evacuation, but to avoid a sudden suction of blood to the abdominal viscera, which might cause syncope. A quarter of a grain of cocaine should be injected with a hypodermic syringe into the skin at the place selected, which, as a rule, should be in the mesial line, midway between the symphysis and the umbilicus. Full antiseptic precautions should be used. The bladder should be emptied with the catheter. The trocar is thrust in, the stylet withdrawn, and the fluid

directed into a pail placed on the floor. When all has been removed, the abdominal wall is lifted in a fold around the canula, the latter is withdrawn, the opening is compressed from side to side, and a piece of rubber adhesive plaster placed over it.

In the vagina only the aspirator should be used. So far as possible, the puncture should be made behind the uterus. In front is the bladder and to the sides are the uterine artery and the ureter. The latter organs may, however, sometimes be felt and avoided.

Tapping has occasionally proved fatal by lesion of a blood-vessel in the abdomen. Septicemia may be avoided by antiseptic precautions.

Sometimes the canula is left in as a drainage-tube, and has for that purpose two eyes for the insertion of cords or wire. The puncture may be followed by incision or dilatation; then the pointed stylet

Fig. 158.

Trocar, composed of canula with cap, pointed stylet, and blunt staff.

is withdrawn, and a blunt guide with a longitudinal furrow substituted, over which the canula is withdrawn (Fig. 158).

Fig. 159.

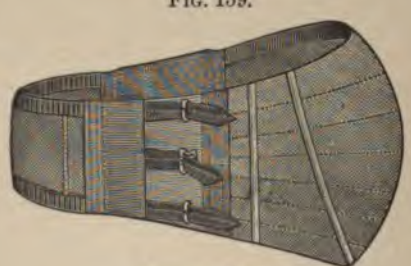

Abdominal Belt.

L. *Abdominal Belts.*—An elastic abdominal belt (Fig. 159) is often

useful, especially in fat women, to take off some of the pressure on the pelvic organs, and is used during the first year after laparotomy to take off the strain on the cicatrix.

When a special pressure above the symphysis is required, an abdominal supporter, with a solid hypogastric pad, is used (Fig. 160).

FIG. 160.

Fitch's Abdominal Supporter.

M. *Massage.*—Certain manipulations inside of the pelvis and through the abdominal walls constitute a valuable mode of treatment in many diseases of women, especially chronic metritis, cellulitis, peritonic exudations, adhesions, hematoma, and oöphoritis. Often a general massage of other parts of the body or the whole body is added. In this way exudations, infiltrations, hypertrophies, and adhesions are made to disappear, weak ligaments and muscles strengthened, and displaced organs brought back and kept in their normal position. The procedures being rather painful, there is no danger of causing sexual excitement. The manipulations are quite complicated, have to be adapted to the special abnormal conditions obtaining, and can hardly be learned except by seeing them carried out by an expert. Unfortunately, this treatment requires so long sittings[1] that a gynecologist or general practitioner will hardly find time to use it himself, and, on the other hand, such fine diagnosis is necessary that nobody who has not a large experience in abdominal examinations can be entrusted with it.[2]

[1] Up to three-quarters of an hour! The length of the sittings is, however, partially counterbalanced by the great efficacy of the treatment, which often leads to a cure in a short time.

[2] The limits of this work forbid me even to give an outline of the different manipulations used in massage. Those interested in it are referred to the paper by

N. *Gymnastics.*—Gymnastic movements, active and passive, are sometimes a direct cure for certain diseases, perhaps even the best of all—*e. g.* Thure Brandt's[1] wonderful cure for procidentia uteri.

In other cases the *Swedish movement cure* may be a valuable adjuvant, combined with other methods, and even common gymnastic exercises, if not too violent, are not only an excellent preventive of pelvic diseases, but may be used to advantage toward the end of a cure begun on other lines.[2]

O. *Operations in General.*—1. *Time for operating.* If we have a choice, operations should be avoided in this climate during the hot season. It is no small discomfort for the patient to lie in bed for weeks, when not even the nights bring coolness, and it is rather trying for the operator to work when the thermometer is in the nineties in the shade. But I have had hospital-service during the hottest time of the year, and performed both laparotomies and plastic operations without the slightest disturbing influence on perfect success.

In general, operations should not be performed on *pregnant women*, on account of the danger of producing miscarriage. It would seem that interference with the rectum is particularly liable to have this effect. As to the genitals, we may say that the farther the seat of operation is removed from the uterus the less is the danger of provoking abortion. Sometimes the very presence of pregnancy may call for operative interference. Vomiting in pregnancy, which may lead to the patient's death, may be treated successfully by applying nitrate of silver in substance or in solution to a granular os, or by stretching the os and lower part of the cervical canal (*Copeland's method*) with the index-finger. Large polypi hanging from the cervix may be the source of hemorrhage or become an obstruction during labor. It may, therefore, be wise to remove them with the galvano-caustic wire. Ovarian cysts should be removed if discovered early. If the patient is far gone or in labor, tapping may be preferable. If a cancer of the cervix can be removed, it is better to do so even with the risk of causing abortion, as the cancer, as a rule, grows rapidly during pregnancy, and may cause an obstruction during labor that may cost the life of both mother and child.[3]

A. Reeves Jackson of Chicago, on "Uterine Massage as a Means of Treating certain Forms of Enlargement of the Womb," *Trans. Amer. Gyn. Soc.*, 1880, vol. v. p. 80; to that by H. J. Boldt of New York, on the "Manual Treatment in Gynecology," *Amer. Jour. Obst.*, June, 1887, vol. xxii. p. 579; to that by H. N. Vineberg on "The Treatment of Retrodisplacements of the Uterus with Adhesions by Brandt's Method," *N. Y. Med. Record*, July 11, 1891; and to Profanter's pamphlet, *Die Massage in der Gynäkologie*, Vienna, 1887.

[1] This is the name of a Swedish layman who is the inventor and successful performer of most of the special massage and gymnastics applied in gynecology.

[2] The value of gymnastics as preventive of and cure for pelvic disorders has been inculcated by John H. Kellogg, *Med. News*, November 8, 1890, No. 930, p. 468.

[3] Further information may be found in a paper by M. D. Mann of Buffalo, N. Y.:

As a rule, we avoid operations during or near *menstruation*, on account of the great congestion of the pelvic organs. Most operators prefer to operate eight or ten days after menstruation has ceased, but since we have seen (p. 117) that the menstrual process is finished even in the uterus itself eight or nine days after the beginning of the flow, there is no occasion to wait more than four or five days after it has stopped. As the removal of the ovaries, or probably rather the tying of the pedicle, very commonly brings on a menstrual flow, even if the patient has just gone through her menstrual period (p. 118), it may be preferable in anemic patients, in order to avoid this extra loss of blood, to operate immediately before or during menstruation. H. P. C. Wilson[1] of Baltimore even prefers, in regard to laparotomies, to select the "uterine flood" rather than the "uterine ebb," during which he thinks patients are more liable to passive hemorrhages, the absorption of septic poison, and the deadly influence of shock, than when the system is under the stimulus of the uterine flood. Moreover, he believes that the local bloodletting from the uterine mucous membrane is a healthy derivation from many of the dangers of laparotomy. Tait,[2] Goodell,[3] and Thomas-Mundé[4] do not care whether the patient menstruates or not. Operators may, therefore, be warranted in not paying much attention to the time of menstruation in regard to the performance of laparotomies, and sometimes even in preferring the approach or the presence of the flow. If the patient menstruates, her vagina, after having been disinfected, should be filled with a tampon of iodoform gauze. Goodell recommends curetting during menstruation or metrorrhagia, but to avoid this time in myomectomy or hysterectomy.

Plastic operations ought always to be performed shortly after menstruation, as the occurrence of this flow might be mistaken for hemorrhage or interfere with proper after-treatment.

Lactation need not interfere with operations. It is only necessary to discontinue nursing for twenty-four hours, on account of the effect of the anesthetic on the child, and press or pump out the milk of the breasts.

The *time of the day* most suitable for serious operations is the morning, when the operator may be sure not to have come near any case from which pathogenic germs might be brought to the patient, and his own nerves are refreshed by rest and sleep. But other considerations often prevail, and many operate in the afternoon. Daytime should always be preferred, as no artificial light, but the elec-

"Surgical Operations on the Pelvic Organs of Pregnant Women," *Trans. Amer. Gyn. Soc.*, 1882, vol. vii. p. 340.

[1] *Amer. Gyn. Trans.*, 1889, vol. xiv. p. 45.

[2] Tait, *Diseases of Women*, p. 212.

[3] Wm. Goodell, *Med. News*, Nov. 29, 1890, p. 560.

[4] Thomas, *Diseases of Women*, 6th ed., p. 718.

tric can replace a good daylight. If it is necessary to operate at night, care should be taken to obtain as perfect an illumination as possible.

2. *Preparation for Operations.*—The more thought the operator and his assistants bestow beforehand on every detail of a contemplated operation, the more smoothly it will come off, and, other things being equal, the better the result will be.

Room.—If we have the choice, we should select a large room with a good light for operating, and, if possible, this should be another room than the one in which the patient shall lie after the operation, but contiguous with it. The best room should be reserved for the after-treatment. According to the season this should either be cool or have a southern exposure. For an important operation, especially a laparotomy, all superfluous furniture should be removed, the carpet should be taken up, the bedding aired, the floor and, if they are oil-painted, also the walls should be scrubbed, not only with soap and water, but thereafter with a solution of bichloride of mercury (1 : 1000). No curtains should be allowed round the bedstead. Every object should be carefully dusted. The room should be pleasantly warm, about 70° F., or, if the abdominal cavity is to be opened, even a little more than that.

The bed should have a horse-hair mattress and blankets. If possible, it is a great advantage to have two beds. With proper precautions even a very sick patient may be moved from one bed to another, and it contributes much to her comfort.

Table.—A strong narrow table should be placed with one end in front of a window. A common kitchen table four feet long and two wide is very convenient. It should be covered with a folded blanket or quilt, a muslin sheet, and a rubber sheet or oil-cloth. The latter should be pinned together, so as to form a funnel leading at the lower end of the table, down into a slop-pail. Instead of the latter arrangement inflatable rubber cushions (Fig. 161) may be used to advantage. A towel or sheet may be rolled so as to form a hard cylinder, which is bent so as to form part of a circle or the three sides of a square, and in the latter case tied with strings at the corners. This frame is covered with a rubber sheet. The first part of this arrangement may be improvised, and the latter is easily carried in a satchel. A pillow is placed at the head of the table, and this end is slightly raised so that fluids may gravitate down into the pail. For laparotomy it is better to have the table level with drainage to the side where the operator stands.

In hospitals tables are preferably used that can be thoroughly disinfected. Good tables for this purpose, and with facility for Trendelenburg's position (p. 136), have been constructed by Cleveland, Edebohls, Foerster, and Boldt.

Leopold uses for Trendelenburg's position an apparatus that has

the advantage of being inexpensive and so simple that any carpenter can make it. It consists of a frame 50 inches long and 20 inches

FIG. 161.

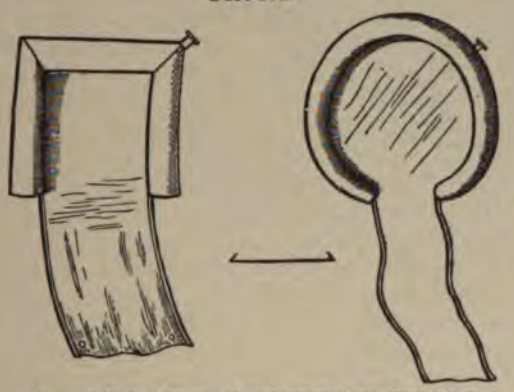

Howard Kelly's Perineal and Ovariotomy Cushions.[1]

wide, with a hinged flap that can be raised up. The shorter, lower part of the flap, upon which the legs rest, can be bent downward, so as to form a right angle with the upper part, upon which lie the thighs and the pelvis, and which is a yard long. By means of a support the flap can be raised as much as 20 inches above the frame, so that the support forms an angle of about 30° with the upper part of the flap. The frame is fastened with iron clamps to a table (see Fig. 107, p. 137).

Krug has had a portable attachment made of galvanized iron. Lapthorne Smith has constructed a whole transportable table of wood that is light and inexpensive.[2]

Most tables are of a convenient height for the operator to stand at, but not only are perineal and vaginal operations performed sitting, but some prefer also to perform laparotomies in the sitting posture. Then the table should be rather low, and the operator seated on a high chair between the legs of the patient.

Assistants.—For most operations three, four, or even five assistants are needed, and each of them should have his part distinctly allotted and explained to him beforehand. One should exclusively be charged with the anesthesia, and as the patient's life in most cases depends much more on him than on the operator, this function should be con-

[1] Howard Kelly, *Amer. Jour. Obst.*, 1887, vol. xx. p. 1030, but H. O. Marcy of Boston claims many years' priority (*Trans. Amer. Association of Obstetricians and Gynecologists*, 1893, reprint, p. 13.

[2] This table may be obtained from the Ford Surgical Instrument Co., 315 Fifth Avenue, New York, or from Lalonde & Son, 2092 St. Catherine street, Montreal.

[illegible]. In operations with the [illegible] should hold each knee [illegible] free for sponging, holding [illegible] assistance as may be needed. [illegible] operator and the other at his [illegible] to hand instruments, which [illegible] keep his eyes uninterruptedly [illegible] to limit the possible sources [illegible] operators prefer to place their [illegible] with this assistant. As a [illegible] to hand and clean sponges, [illegible] syringes, dressing-material, etc. [illegible] any doubt that the fewer persons [illegible] better, other things being equal, [illegible] Particularly in laparotomies the [illegible] case of erysipelas, scarlet fever, [illegible] zymotic diseases constitutes an [illegible] hand, nobody can learn to operate [illegible]. The accumulated experience [illegible] be acquired by seeing others at [illegible] the interest of humanity in general [illegible] and fellow-practitioners to witness [illegible] and with what restrictions this [illegible] many circumstances which cannot be [illegible] experience has shown that when those [illegible] field of operation follow all the rules [illegible] presence of other persons in the room [illegible] the result of the operation.

[illegible] should be examined with special ref- [illegible] in the same, as it may be deemed [illegible] or desist from it altogether if the [illegible], or at least to prefer chloroform to [illegible] having proved particularly dangerous [illegible] kidneys,[1] or to use opium or cocaine, or [illegible]. If there is albumin in the urine, it [illegible] microscopically for casts. If the urine is [illegible] prepare the patient for an important [illegible] or lithia water. If the urine contains [illegible] be a fit subject for any plastic operation [illegible] treated for glycosuria. The presence of [illegible] may likewise call for special preparatory [illegible] is undertaken.

[illegible] should also be examined. If the heart is [illegible] dangerous. Advanced phthisis is

[1] T. A. Emmet, *l. c.*, *p.* 745.

a counter-indication for nearly all operations; in lighter pulmonary affections ether should be avoided.

On the day preceding that of the operation the patient should have a warm *bath* and be scrubbed with soap all over, in order to have the skin in as good a condition as possible. In the morning her *bowels* should be moved with a heaping teaspoonful of compound liquorice powder or another suitable aperient, and she should receive no other food than milk or beef tea.

An hour before the operation she should be given an *enema* of a quart of soap-suds, and when that has been evacuated, it should be followed by a vaginal injection of at least two quarts of hot emulsion of creolin or another antiseptic fluid, not only for disinfecting the vagina, but in order to diminish hemorrhage.

Twenty minutes before anesthesia is begun I give a hypodermic injection of $\frac{1}{6}$ of a grain of morphine and $\frac{1}{72}$ of a grain of sulphate of atropine, the first of which has the effect that less of the anesthetic is needed, and the second, that of strengthening the heart.

Immediately before the operation begins the bladder should be emptied with the catheter, even if the patient says she can urinate herself.

The patient should be in night-dress, and the feet, legs, and thighs covered with leggings made of a woollen or other warm stuff. In private practice stockings are sufficient. Besides, she should be covered with a sheet and towels in such a way as never to expose more of her body than what is needed to give access to the field of operation.

The field of operation should be washed with soap and water, ether, if it is on the skin, and bichloride of mercury (1 : 2000), and all hair shaved off with a razor. For laparotomies the field is surrounded with four towels wrung out of carbolized water, and pinned together and to the clothes, and the vagina is carefully disinfected by swabbing with tinctura saponis, followed by corrosive-sublimate solution.

For perineal and vaginal operations the knees are lifted more or less up, and kept separate by means of *Clover's crutch* (Fig. 162), an expensive apparatus which, however, may easily be replaced at small cost by placing a two-feet-long broomstick in the popliteal spaces, tying it with some figure-of-eight turns to each knee with a roller-bandage, and leading part of the bandage up behind the neck of the patient.

A most excellent and inexpensive *leg-holder* is that of Robb (Fig. 163). It is easily rolled up, and takes up little room in the satchel. It surrounds the lower part of the thigh, passes under one shoulder and above the other, which is protected against pressure by a folded towel being placed between it and the leg-holder.

FIG. 162.

Clover's Crutch.

[illegible]—Two instrument-trays of hard rubber, enam-[illegible] should be kept ready, likewise 4 plates for ligatures,

FIG. 163.

Robb's Leg-holder.

[illegible] gauze, and gutta-percha tissue; 4 basins; 4 pitchers, [illegible] cold water, carbolized water, (5 per cent.), solution of

bichloride of mercury (1 : 1000); 2 fountain syringes or douche-cans, with a straight glass nozzle 6 inches long, and a hard-rubber nozzle with a stopcock easily opened and closed with the thumb (Fig. 164).

At least a dozen towels will be needed.

FIG. 164.

Nozzle with Stopcock.

Disinfection.—We have already referred to the disinfection of the room and the field of operation. The operator and his assistants take off their coats, turn up their sleeves to the elbows, scrub their hands and forearms with soap and water, using a rather stiff nail-brush, wipe their hands, remove all dirt from under the nails with a steel nail-scraper, and hold the hands immersed in a solution of bichloride of mercury (1 : 2000) for at least three minutes, after which they should *not* wipe the hands. To combine the use of soap and corrosive sublimate in disinfecting the hands is wrong, as the soap deprives the drug of some of its power. It is convenient to put on a rubber apron covering the whole front of the body from the neck down to a little above the feet, and to pin to this a towel wrung out of carbolized water.

For dressing, the antiseptic materials, such as iodoform gauze or corrosive-sublimate gauze, sold by druggists and instrument-makers, may be used, but so-called aseptic ligature and suture material and sponges found on the market are unreliable. The operator who wants to feel safe and give his patients the best chances, must take the trouble to prepare them himself or have it done by a reliable private assistant.[1]

Sponges.—The raw sponges are beaten in order to soften them and remove sand, and then immersed in acidulated water (acid. hydrochlor. ℥j to each quart of water) in order to dissolve the calcareous matter. Part of this trouble may be avoided by buying the sponges already prepared;[2] but even then they have to be treated with the acidulated water, and wrung many times out of water until all sand has been removed.

When sponges have been used in an operation, they are cleaned in the following way: They are first washed with soap and water until

[1] Aseptic material may be prepared in many ways; I describe only the one I follow myself.

[2] Mr. Angelo, druggist, southwest corner of Fourth Avenue and Thirty-first Street, New York, keeps a large collection of all kinds of sponges suitable for surgical purposes.

the water remains clean; then they are left for an hour in a solution of potassa (liquor. potassæ ℥j to each quart of water) which draws out all the blood. If the sponges have been unusually soaked in blood, it may become necessary to change this solution. Then they are again wrung out of plain water till it stays clear. After that they are left for an hour in a solution of bichloride of mercury (1 : 1000), wrung out, dried in the sun or in front of a fire, and kept in a muslin bag. By keeping them in this dry way they do not become rotten so soon as when kept in an antiseptic fluid. Before using them the next time they are left for five or ten minutes in a similar solution of bichloride, after having soaked them well by pressing all air out of them, wrung out, and kept in carbolized water (2 or 2½ per cent.) during the operation.

Three sizes of sponges are needed: small round, about 1½ inches in diameter; large round, about 3 inches in diameter; and large flat sponges, ¼ inch thick.

Some operators, in order to avoid infection from sponges or the trouble of disinfecting them, have discarded them altogether, and use, instead of round sponges, pieces of sterilized gauze or round balls of absorbent cotton wound with gauze, and instead of the flat sponges pads of several layers of gauze, about 8 by 6 inches. Such gauze sponges are sterilized with heat in a gas-stove or Arnold's milk-sterilizer.

Silk.—Twisted or braided silk is used: the latter is stronger. Four thicknesses are needed: Nos. 1, 2, 5, and 12 of the braided.

In order to render it aseptic it is boiled in a small china casserole over an alcohol lamp for half an hour, and soaked in a solution of bichloride of mercury (1 : 1000) for an hour, wound on glass spools, several of which may be suspended on one glass stand and kept in alcohol in a well-corked glass with a heavy bottom. Such glasses can be obtained from the instrument-makers. The different ends may be run through holes in the cork or rubber stopper covering the glass, and thus the silk is unwound without opening the bottle. If there is a hitch, great care should be taken only to use a perfectly aseptic pair of forceps to get hold of the silk or the spools. New alcohol must be constantly poured into the bottle to keep it full, and if not used often the silk should from time to time be boiled again, and the alcohol renewed altogether.

I have had a ligature-box made (Fig. 165) which is a modification of that described by Greig Smith.[1] It consists of a solid hard rubber-box, to which is screwed a cap. A leather washer is placed at the bottom of the screw. Into this case fits a leaden disk which is heavy enough to remain stationary while the silk is being drawn out, and on this disk, supported by upright rods of German silver, are placed

[1] Greig Smith, *Abdominal Surgery*, 2d ed., Philadelphia, 1888, p. 65.

four metal reels of the same material. A glass plate perforated in four places for the threads is screwed to the top of a central bar. This whole inner part, except the glass plate, may be boiled in water or any solution the operator may prefer, and the plate and box are immersed in a solution of corrosive sublimate; and when once all is aseptic, it is kept so by keeping the box filled with alcohol. By winding the reels with finest black iron-dyed silk, and braided No. 2, 4, or 5, and 12, the operator is prepared for everything that needs

FIG. 165.

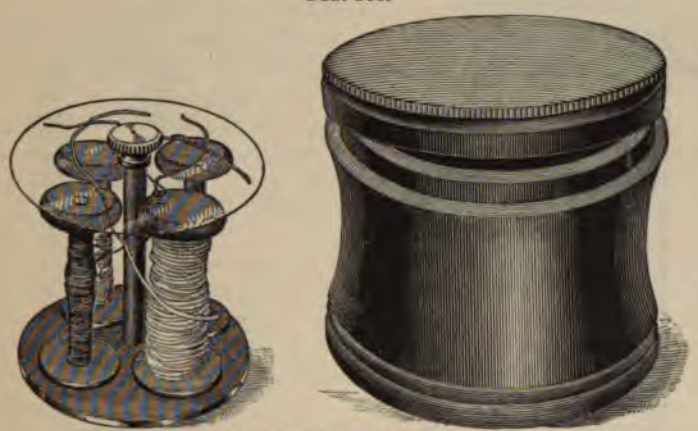

Greig Smith's Ligature-box (modified).

tying, from a wound in the intestine to the thickest pedicle of a tumor.

Catgut, so called, is in reality sheep's gut. It is so hard to render it aseptic, and keep it so, that some have given it up altogether. Heretofore the best way of preparing it has been to immerse it for twenty-four hours in ol. juniperi baccarum, and keep it in absolute alcohol (Kocher). Some keep it in alcohol (95 per cent.) and add bichloride of mercury (1 : 2000). Recently another method has been recommended which probably is best of all—viz. to boil it in alcohol (97 per cent.) for an hour and keep it in the same alcohol.[1]

This method has been made easy, inexpensive, and safe by means of Dowd's condenser, represented in Fig. 166.[2] The catgut is wound on glass reels enclosed in small glass jars, which are immersed in alcohol in a larger jar placed in a water-bath on a gas-stove. From the top of the large jar the vapor of the boiling alcohol rises into a coil of tin, in which it is condensed by having cold water flowing

[1] Geo. R. Fowler of Brooklyn, *N. Y. Med. Record*, 1890, vol. xxxviii. p. 178.
[2] Charles N. Dowd of New York, *Med. Record*, Dec. 3, 1892.

through the surrounding copper cylinder, and from which it drops back into the jar below.

For the intestines No. 0 is required; for closing the peritoneum in laparotomies I use No. 1; for the perineum a medium size is used;

FIG. 166.

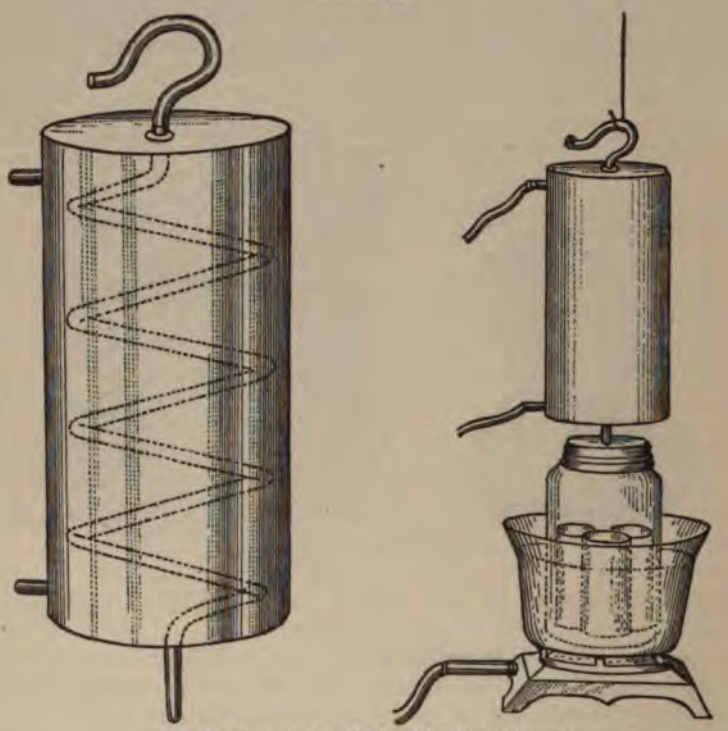

Dowd's Apparatus for the Sterilization of Catgut.

and for the pedicles of tumors a very thick one. Different manufacturers use different numbers, so that I cannot designate the thickness in that way.

Catgut has the advantage over silk that it is soon dissolved and absorbed, which recommends it for ligatures in wounds or cavities from which it cannot be removed, and for sutures in so far as its removal becomes unnecessary. The thick grades are so strong that they never break in being tightened. It has therefore been recommended as exclusive material for both ligatures and sutures, while others as exclusively use silk for all purposes. On the other hand, catgut is more difficult to tie, becomes easily untied, so that triple

knots are necessary where there is any strain on it, and, as before stated, it is more difficult to render and keep aseptic. Its great dissolvability proves even sometimes a fault instead of a virtue; which, however, can be remedied by preparing it with chromic acid in the following way: 1 part of chromic acid is dissolved in 4000 parts of distilled water; 200 parts of carbolic acid are added. Catgut equal in weight to the carbolic acid is left for forty-eight hours in the mixture. It must be dried on the stretch by tying the ends of each hank to two fixed points in the room. When dry it is placed in 1 : 5 carbolized oil. Erosion of this catgut does not begin till about a fortnight after its introduction into the tissues.[1]

Silkworm gut is sold "prepared" in a long bundle tied at both ends. It may be disinfected by boiling it in water. As many single threads as are likely to be used are cut off before the operation, washed in a solution of bichloride (1 : 1000), and kept in carbolized water (2 per cent.) during it, just like sponges. It is, of all materials, the best for operations on the perineum. It does not absorb fluid like silk, does not become corroded like catgut, and does not hurt in removal like silver wire.

Silver Wire.—Silver wire, or its much cheaper substitute silver-plated copper wire, is the best material for most plastic operations in the vagina or on the cervix. It is made aseptic by immersion in 5 per cent. carbolized water or by drawing it through the flame of an alcohol lamp, and is kept during the operation in carbolized water or alcohol.

The thicknesses commonly used are No. 26 for the perineum, No. 27 for the cervix, and No. 28 for the vagina.

Iodoform is not, in itself, an antiseptic, but it seems that it is decomposed by the very appearance of pus-cocci and the formation of ptomaïnes in such a way as to become a germicide. However this may be, experience has shown that it is a most valuable preventive of suppuration and sepsis. Its disagreeable odor may be covered by adding 1 part of thymol to 5 parts of iodoform.[2] A chemical combination of the two has of late been introduced under the name of *aristol.* Coumarin, the odoriferous principle in Tonka beans (1 part to 5), and ground coffee are also recommended for the purpose.

Antiseptic Fluids.—Bichloride of mercury is a powerful antiseptic, but so poisonous that it has to be used with great circumspection. Experiments have shown how fatal the effect of a solution of bichloride of mercury is when it is kept in contact with a wound leading into the subcutaneous connective tissue, and the same applies, of course, to the submucous. Even the intact mucous membrane of the

[1] Lister's procedure, described by W. Watson Cheyne, *Antiseptic Surgery*, London, 1882, p. 57.
[2] *Med. World*, 1886, p. 89.

vagina absorbs it.[1] I have, therefore, nearly entirely discarded it for intra-uterine and vaginal injection and irrigation of wounds or the peritoneal cavity. I use it almost exclusively for washing the skin, swabbing the vagina, and for the hands of the doctors and nurses. It is convenient to have a solution of 1 : 1000, which may be diluted by adding hot water.

Carbolic acid is used for instruments and sponges. It is best to have a 5 per cent. solution, and add hot water so as to get a 2½ or 2 per cent. solution.

Creolin forms no solution, but an emulsion, with water. This emulsion should be prepared by pouring the creolin into cold water, stirring it, and adding as much hot water. The strength that answers best in most cases is a 1 per cent. emulsion (2 tablespoonfuls to 3 quarts of water), but both ½ per cent. and 2 per cent. solutions are used. The emulsion looks like milk with a little coffee. It has the fault of being opaque and of producing a smarting sensation in the vagina of some patients. It is not so powerful an antiseptic as bichloride of mercury, but, compared with carbolic acid, it has the advantage of being an excellent hemostatic, of being almost innocuous, of making the tissues slippery, of having a rather pleasant odor, and of not affecting the operator's skin and nerves. I use it after curetting, especially for cancer, where its hemostatic powers prove of great value.

Hydro-naphthol is praised very much by the few who use it. "It is harmless and does not injure instruments or the operator's hands. The strength used is a saturated solution in hot water. The peritoneal cavity may be repeatedly filled with this solution with perfect impunity."[2]

Boro-salicylic solution, or *Thiersch's solution* (℞ : Acidi borici 12, Acidi salicylici 2, Aquæ 1000), is a bland fluid that likewise may be used in the peritoneum or for irrigation of wounds.[3]

Thymol (1 : 1000) is also a bland disinfectant.

3. *Anesthesia.*—The two chief anesthetics used are ether and chloroform. *Ether*, as the safer of the two, should be preferred, except when the kidneys, the lungs, the larynx, or trachea are affected or in patients suffering from congestion of the brain, for under these circumstances ether is the more dangerous of the two. It seems, also, that there are differences of susceptibility to the effect of the two drugs in different persons. I have had cases where one of them,

[1] Details may be found in my article on "Corrosive Sublimate and Creolin," *Amer. Jour. Med. Sci.*, 1889, vol. xcviii.

[2] Clinton Cushing, *Pacific Med. Jour.*, July, 1890, reprint, p. 7. First recommended by Geo. R. Fowler of Brooklyn, N. Y., *New York Med. Jour.*, 1885, vol. xiii. p. 374 *et seq.*, and endorsed by R. J. Levis of Philadelphia, *ibid.*, p. 593.

[3] A convenient way of making this solution is by dissolving Thiersch's tablets in water, 1 tablet to each quart.

ether as well as chloroform, failed to induce anesthesia, but caused alarming symptoms, such as convulsions or arrest of respiration, while the other worked satisfactorily.

In giving ether constant watch should be kept on the respiration. As soon as it stops etherization should be interrupted, and artificial respiration by Sylvester's method or Richardson's double-acting bellows be instituted. In giving chloroform special attention has to be directed to the pulse, for when breathing stops under the use of that drug there is great danger that the heart will be fatally affected. In case of collapse during chloroformization, the best treatment is the combination of artificial respiration with Nélaton's method, which consists in suspending the patient by holding her knees over the shoulders of an assistant and letting her head hang down. I have succeeded every time with this combination.

Another method that may answer a good purpose, even at a later stage, is Koenig's rapid compression of the heart. The ball of the thumb is pressed against the wall of the chest between the apex of the heart and the left edge of the sternum 120 times or oftener in the minute. When the pupils contract and the patient breathes, a pause is made until the former dilate again and the respiration stops.

If there has been considerable loss of blood and the heart threatens to become paralyzed, an intravenous injection of a 6-per-thousand solution of common salt (sodium chloride) at the temperature of the blood may yet save the patient's life.

Ether is given with *Allis's inhaler* (Fig. 167), a frame of metal with many parallel long side-openings, through which a roller bandage is drawn and surrounded by a soft rubber cover. The inventor describes its use in the following words: "Placing it over the face, I sprinkle on a few drops of ether: I mean, literally, but a few drops. In a few seconds I add a few more drops, and usually in from half a minute to a minute I find that I can drop it more constantly. As soon as I notice the deep inspiration I pour on a small stream, watching carefully lest I irritate the larynx; and as soon as I find the patient tolerant of its vapor, I add it in larger quantities, and as rapidly as it can be evaporated, and am usually gratified by seeing my patient pass *quietly* under its influence in from three to ten minutes. A slight *dripping* will suffice to prolong the effect." The chief virtue of Allis's inhaler is the free access of air.

FIG. 167.

Allis's Ether-inhaler.

Often a substitute is improvised by folding a newspaper and a towel together, so as to form a kind of cap, into the bottom of which is put a little absorbent cotton. About a fluidounce of ether is poured on the cotton, and more added when it has evaporated.

Other inhalers—*e. g.* Ormsby's—admit very little air, and make the patient all the time inspire the same air she expires, so that there really is a combination of etherization and poisoning with carbonic acid. This class of instruments use a much smaller amount of ether. Ormsby's has a metal cone with a small sponge at the top and an inflatable rubber ring at the brim, which can be placed air-tight over the face. The ether is poured on the sponge through a small funnel. Air may be admitted in small quantities through an opening on the side of the cone, which can be made larger or smaller. On the other side of the sponge is a rubber bag into which the patient expires, and from which she again inspires.

As often a considerable amount of ether is used, it is best to have a pound of it on hand, but divided into quarter-pound cans. Even in hospitals it is better to have these small cans, because ether undergoes some change as soon as the can has been opened, in consequence of which it loses part of its anesthetic power, and a larger quantity is needed to produce the same effect.

The use of a hypodermic injection of morphine before giving ether does not abridge the time required to induce anesthesia, but offers the advantage that very little or nothing is needed to keep up the effect.

The vapor of ether is inflammable. Great care must, therefore, be taken not to bring the ether-cone or bottle too near the flame or incandescent body when a cautery is used, or when the operation is performed with artificial light, or in a room with an open fire. It is safe to have gas-lights a yard above the operating table.[1] My own experiments have, indeed, proved that a compress saturated with ether does not catch fire from a burning candle before the flame is approached to the distance of one inch from below or from the side, and even half an inch from above. Ether vapor contained in the breath is not inflammable.

Of *chloroform* it is well to have four ounces. It is best administered on *Esmarch's mask* (Fig. 168), which consists of a wire skeleton covered with Canton flannel. It lies over nose and mouth, and the chloroform is dropped on it without removing it. Instead of the mask a pocket-handkerchief may be used, but then the face should be smeared with vaseline in order to protect the skin from irritation. Chloroform should be given in the dose of 5 to 10 drops poured on the mask at intervals of half a minute. Death from chloroform appears in four modes: (*a*) By syncopal apnea; (*b*) by epileptiform

[1] J. R. Comte, "Éther et Chloroforme," *Revue médicale de la Suisse Romande*, 20 Février, 1890, p. 87.

syncope; (*c*) by paralysis of the heart with paralysis of the muscular system generally; (*d*) by chloroform combined with surgical shock.[1]

FIG. 168.

Esmarch's Chloroform-Mask.

Since in chloroformization there is so much danger of paralysis of the heart, it is well to add $\frac{1}{72}$ grain of sulphate of atropine to the preliminary hypodermic injection.

Whatever anesthetic is used, false teeth should be removed before beginning; a gag to separate the jaws, a long dressing forceps, and some gauze or lint should be within reach for the removal of froth, which sometimes accumulates in the throat. The tongue should always be kept forward, which can be done by pressing both rami of the lower jaw forward. Special tongue-forceps are found in the instrument-stores. The tongue should not be pinched with artery-forceps, which causes bad-looking and painful ulcerations.

Particular care should be taken when Trendelenburg's position is used, as it tends to produce congestion of the brain. Some prefer for this reason to use chloroform.[2] At all events, the patient should be anesthetized in the horizontal position, not kept inclined longer than necessary, and brought back to the horizontal position, at least temporarily, if she becomes cyanosed.

Cocaine.—Although great operations, such as ovariotomy and amputation of the breast, have been successfully performed under the anesthesia brought on by hypodermic injection of hydrochlorate of cocaine, so many cases of alarming depression following the use of even very small doses are on record that I think the use of this drug should be very limited in gynecological practice. Perhaps it interferes also with healing by the first intention.[3]

It is, however, in many cases, a great advantage to dispense with general anesthesia, and it has been noticed that the dangerous collapse is less likely to occur the farther away from the head cocaine is used. I have been well satisfied with the application of a 10 per cent. solu-

[1] Benjamin Ward Richardson, "On Death by Chloroform," *The Asclepiad*, 1st quarter, 1890.

[2] Cleveland and Goodell, *Amer. Jour. Obst.*, Oct., 1891, vol. xxiv. p. 1240.

[3] H. T. Hanks, *Amer. Jour. Obst.*, 1888, vol. xxi. p. 316.

tion before cauterization with chloride of zinc in diphtheritic inflammation of the genitals. The cervix may be dilated without pain after pledgets soaked in a 5 to 20 per cent. solution are placed for five minutes around it, and in its cavity if it is sufficiently wide to allow it.

Whatever agent be used to produce anesthesia, the most powerful *stimulants* should be kept ready. A few drops of nitrate of amyl are good where there are signs of anemia of the brain (chloroform, cocaine). Hypodermic injections of several syringefuls of brandy often increase the volume of a sinking or indiscernible pulse. Still more powerful is the hypodermic injection when 5 to 10 minims of tincture of digitalis are added.[1] Strychnine has a powerful effect on respiration.[2] Injection of ♏xxx of a solution of 1 part of camphor in 4 parts of olive oil into the deltoid or vastus externus muscle is efficacious and harmless.[3] Faradization of the diaphragm may occasionally prove useful.

Against the collapse caused by cocaine have been recommended inhalation of nitrite of amyl, subcutaneous injections of ether or caffeine, or a warm or cold infusion of coffee by the mouth.

Both ether and chloroform are very apt to cause vomiting. The patient should, therefore, not have any solid food the day of the operation. When she vomits, she should be turned on her side, so as to give the rejected masses a free outlet and prevent their entrance into the larynx. After the operation she should only have hot water or ice-water in teaspoonful doses to relieve her thirst until all nausea has stopped. A little black coffee is grateful, and seems to have a good effect on the stomach. If vomiting continues, I give, with excellent effect, the following mixture:

℞. Acidi hydrocyanici dil., ʒss;
Acidi citrici,
Sodii bicarbon, āā. ʒij;
Syr. rubi Idæi, ℥ss;
Aquæ, ad ℥vj.—M.

Sig. A tablespoonful every one, two, or three hours.

Common Instruments, and their Use.—Some instruments are so

[1] The injection of camphor dissolved in acetic ether, used in several hospitals of this city as well as elsewhere, ought to be discarded, as it in several cases has produced paralysis.

[2] Horatio C. Wood of Philadelphia has made special experiments in regard to the effect of drugs during anesthesia, and laid the results before the International Medical Congress in 1890 (*Abstract in Practice*, Feb., 1891, p. 58–59). According to him, alcohol is ineffective in small doses and dangerous in large. Nitrite of amyl, caffeine, and atropine are of little or no use. Ammonia has some little influence on the heart. He recommends digitalis for the heart and strychnine for the respiration.

[3] H. C. Coe, *The New York Polyclinic*, vol. i. No. 1, p. 20.

generally useful that they are needed for nearly all gynecological operations, and should always be on hand. Such are a uterine sound (p. 150), bivalve, and univalve specula (pp. 142 and 143), a vaginal depressor (p. 145), tenacula, volsellæ, sponge-holders, knives, scissors, several pairs of artery-forceps (p. 180), needles, a needle-holder, counter-pressure-hook, suture-twister, and suture-shield. With some of these we are already acquainted from the chapter on Examination. In regard to the others I shall make a few remarks.

Vaginal Retractors.—Besides the specula and depressors described in speaking of how to make an examination, *Schroeder's lateral*

Fig. 169.

Schroeder's Lateral Vaginal Retractor.

retractors (Fig. 169) are often needed in operations in the dorsal position

Tenacula.—A tenaculum is a sharp-pointed steel hook with handle, which should be made of one piece of metal. Two shapes of hooks are most convenient: one is simply bent so as to form a little less than a right angle; in the other the point has a second flexure in the direction of the handle (Fig. 170).

Fig. 170.

Emmet's Tenaculum.

Tenacula are used to put tissue on the stretch, to lift up tissue to be cut with scissors, to manipulate silver sutures, etc.

Fig. 171.

Volsella.

A *volsella* (Fig. 171) is a pair of forceps, each blade of which ends in a double hook. It is used for seizing and pulling tissue.

A *tenaculum-forceps* is a modified volsella with single or double hooks, and, as a rule, of more slender build.

A *tissue-forceps* (Fig. 172) is a pair of forceps with side teeth, convenient for holding a strip of tissue while cutting it off.

FIG. 172.

Thomas's Tissue-Forceps.

A *sponge-holder* (Fig. 173) should be made of one piece of nickel-plated steel. It is a rod with a handle at one end, and divided at the

FIG. 173.

Sims's Sponge-holder. (At *a* a piece of the shaft is left out.)

other into two halves with teeth, which are brought together with a ring. Four sponge-holders are needed.

Knives are used much less than in general surgery. A medium-sized scalpel is about all that is needed.

Scissors are in most cases used to great advantage as cutting instruments. They cause less hemorrhage than knives, are more expeditious, and can do more delicate work. The chief shapes needed are straight, curved on the flat, and knee-bent on the edge. They must for most purposes have long shanks.

When a surface is to be pared a tenaculum is passed into the mucous membrane at the end nearest to the operator and at the lowest part of the field to be denuded, so as to avoid having blood running over the upper part that is to be denuded later. The mucous membrane is lifted a little, and the scissors are made to cut off a thin strip of tissue under the tenaculum in such a way that the tenaculum stays in the loosened strip. When once the strip is cut loose, it is often more convenient to exchange the tenaculum for a tissue-forceps. The strip should be cut of as uniform breadth and thickness as possible, and from one end of the surface to be denuded to the other. If this is wider than the strip, one or more similar strips are cut off parallel to the first, taking great care not to leave any part undenuded. While this is being done the denuded surface is kept free from blood by irrigation or sponging. Especial care is also taken to get a regular line

of incision all around the pared surface without any projecting tongues or receding bays.

Pressure-forceps, of lighter or heavier construction, are put on bleeding vessels. If it is a large vessel that spurts, the pressure-forceps takes simply the place of the old artery-forceps before the vessel is secured by means of a ligature, but on small vessels the pressure exercised by the pressure-forceps suffices within a few min-

FIG. 174.

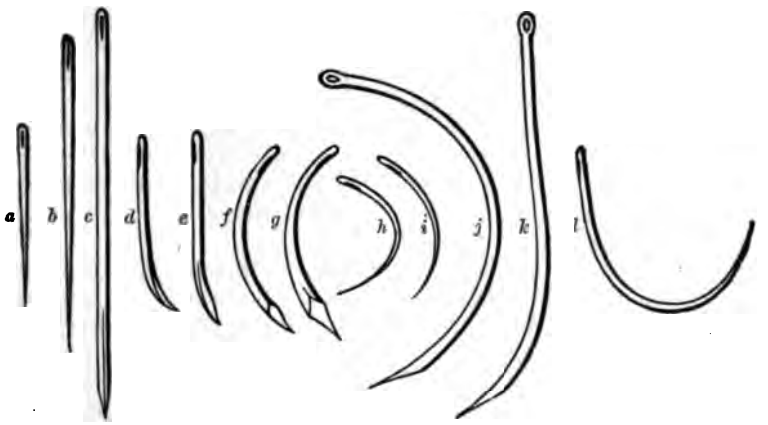

Needles: *a*, short straight round; *b*, long straight round; *c*, trocar-pointed straight; *d*, semi-curved, crescent-ground (Sims's fistula-needle); *e*, semi-curved, trocar-pointed (Emmet's cervix-needle); *f*, curved, crescent-ground; *g*, curved, trocar-pointed; *h*, *i*, old-fashioned strongly curved surgical needles with three edges; *j*, semicircular Hagedorn needle; *k*, half-curved Hagedorn needle; *l*, fishhook-shaped needle.

utes to arrest the hemorrhage permanently, so that no ligature is needed.

Needles.—A variety of needles (Figs. 174 and 175) are used, and

FIG. 175.

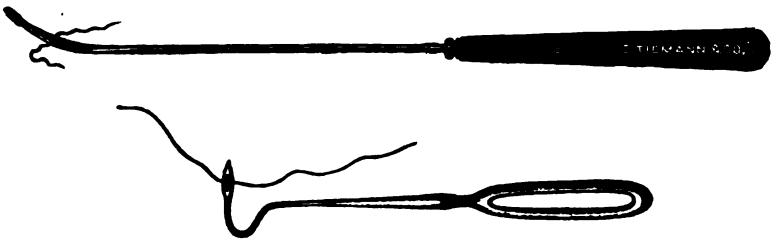

Needles with Handle; *a*, slightly curved, sharp-pointed or dull; *b*, strongly curved, dull.

special kinds made for gynecological work have in certain operations been found preferable to the old-fashioned needles used in general

surgery. We use straight, more or less curved, round, trocar-pointed, crescent-ground, Hagedorn, and handled (sharp-pointed or dull) needles. Common English sewing-needles, short and long, may be used in the vulva and the vagina. They are harder to push through the tissues, but make only a round hole, which, on account of the elasticity of the penetrated tissue, closes round the suture. The same kind of needles are also curved, which makes it easier to push them in a curved line. But where the tissues offer much resistance it is necessary to make the round needle cutting near the point by grinding it so as to form a crescent-shaped surface with two cutting edges, or three sharp edges like the point of a trocar or a spear. Hagedorn's needles are flat from side to side, with a straight cutting edge near the point. They have a very large eye, which makes them particularly useful when catgut is used. When the suture inserted with Hagedorn's needles is tightened, the edges of the wound made by the needle are drawn together from side to side, instead of being pulled apart, as when a needle is used that cuts at right angles to the direction of the suture.

In order to avoid turning or breaking of the curved needles when grasped by the needle-holder, the part nearest the eye should be straight and flat. For operations on the intestines the finest English cambric-needles are used.

Needle-holder.—For all these needles a needle-holder is needed. Sims's (Fig. 176), that has eyes like scissors, is indispensable for fine

Fig. 176.

Sims's Needle-holder.

work in the vagina, especially operations for fistula; Emmet's (Fig. 177), that allows a firm grasp with the whole hand, is particularly useful for cervix operations, and may be used for most other purposes; and Hagedorn's (Fig. 178), or a simplification thereof by Hanks, is indispensable when Hagedorn's needles are used.

As a rule, the needle-holder should be applied to the needle just in front of the eye, for if the latter is comprised in the grasp of the forceps, the needle is very liable to break.

Much time is saved and a good adaptation more easily obtained by

handled needles (Fig. 175), but in order to be strong enough to through resistant tissues they must be made so thick that they

Fig. 177.

Emmet's Needle-holder.

a large hole, which, however, immediately contracts, and, there- is without importance if the patient is anesthetized. When only

Fig. 178.

Hagedorn's Needle-holder.

slightly curved and ending in a sharp point, these needles are particularly useful for closing wounds in the perineum or the abdominal wall, and are often called *perineum-needles* (Fig. 175, *a*). They have the eye near the point, and are threaded after having been pushed through the tissue. A blunt needle of this kind is used in ovariotomy and similar operations, and will be described later.

Ligatures.—For ligatures is used silk or catgut (pp. 196, 197). They should be tied in the so-called *square knot*, and, as we have seen above, catgut requires sometimes an additional knot. In most operations the ends are cut short and the ligature left in the body.

Under particular circumstances (see Lupus Vulvæ, Fecal Fistulæ, Fibroids of the Uterus, etc.) the elastic ligature of rubber is used. It consists of solid round strings varying in diameter from less than $\frac{1}{16}$ up to $\frac{1}{4}$ inch, or in rubber tubing twice as thick. Rubber soon loses its elasticity, and in order to be reliable a ligature of this substance must be rather new. It is, however, said to preserve its elas-

ticity for a whole year or more by being kept in a 4-per-thousand solution of bichloride of mercury in alcohol.[1]

Sutures.—The chief materials used for sutures are silk, catgut, silver wire, and silkworm gut (pp. 196–199). Silk is generally tied in a *surgical knot*, for which catgut and silkworm gut are not pliable enough. Where it cannot be used an assistant may by pressure prevent the suture from opening while the second knot is being tied. Silk sutures may be left in the abdominal wall for a week.

Silk sutures placed near a drainage-tube or a tampon, from which septic material may come, are apt to become secondarily infected. In order to avoid this they should not be used in such places, but preference given to silver wire or silkworm gut, which does not absorb fluids.

Silk may be rendered more resistant to infection by immersing it during the operation in a mixture containing iodol:

℞. Glycerini,	
Alcohol,	*āā* 5 parts;
Iodol,	1 part.

In the vagina I have often left silk sutures for a month without causing suppuration or cutting through. When silk or silkworm gut is to be removed, the ends are seized with a pair of pressure-forceps and slightly lifted; the end of one blade of a pair of sharp-pointed scissors is inserted under the suture, and the latter is cut close up to the skin or mucous membrane on one side, in order to prevent that part of the suture that has been exposed, and is often dirty, from being drawn through the stitch-canal.

Silver wire may be fastened directly in the eye of a needle—*e. g.* in stitching a torn perineum—but for most plastic operations it is necessary to use a thread of silk, linen, or hemp as a *wire-carrier*. Both ends of a linen thread (No. 70) two feet long are passed from the same side, one after the other, through the eye of the needle, and then the two ends together are tied with the loop on the other side of the needle, so as to form a half knot just behind it. If the free ends are made about 4 inches long, we get a loop about 8 inches long. A piece of silver wire 10 or 12 inches long is bent at a distance of $\frac{3}{8}$ of an inch from one end under a *sharp* angle, which is done by seizing it in Emmet's needle-holder and bending it close up to the edge of the instrument. At the same time we straighten the wire and ascertain that there are no kinks in it by sliding the nails of the thumb and middle finger down its full length. The hook thus formed at one end of the silver wire is passed through the loop of the thread and given a little twist, so as to prevent it from coming off. When one pared surface is to be applied against the other, the needle is, as

[1] Fasola and Martinetty, *Centralblatt f. Gynäk.*, 1891, Nov. 24, p. 506.

a rule, inserted about a quarter to half an inch from the outer edge of one of the denuded surfaces, carried deep in under the same, and pushed out just on the inner line between pared and unpared tissue, reinserted at the corresponding point on the other side, and pushed out a quarter or half an inch beyond the pared surface (Fig. 179).

FIG. 179.

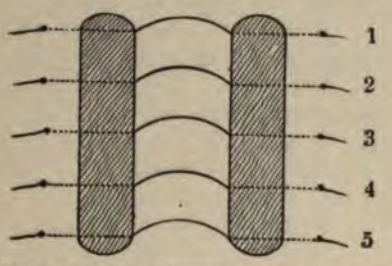

Two Denuded Surfaces, showing where the sutures lie.

When the point of the needle emerges from the tissue, a dull hook, much like a button-hook and called a *counter-pressure hook* (Fig. 180), is inserted under the point and pressed against the tissue, while

FIG. 180.

Emmet's Counter-pressure Hook.

the operator pushes the needle farther in. Next he takes the needle-holder off from the posterior part of the needle and seizes the point above the counter-pressure hook, and pulls the needle through. When the thread has been drawn through under both surfaces, it is suddenly pulled on, so as to jerk the silver wire through the tissue. When the wire is pulled halfway through, the hook is detached from the loop, and one end of the wire is made to form a slip-knot round the other, and this suture is temporarily put aside until all have been inserted.

Only if there is much hemorrhage, it may exceptionally be necessary to close a suture immediately after passing it.

When all the sutures are in place we proceed to close them, beginning with the uppermost. The slip-knot is pushed down and the free end pulled farther out, taking care not to cut the tissue with the wire, until the loop is reduced to a little over an inch in length. The two ends are now seized below the slip-knot with the *wire-twister* (Fig. 181), the long free end cut off, the suture drawn taught and *shouldered*

FIG. 181.

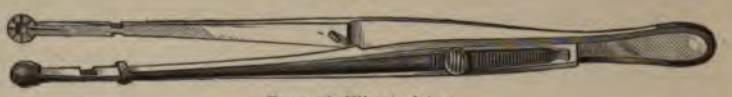

Emmet's Wire-twister.

—*i. e.* bent with a tenaculum at the point that will come to lie just at the line of union when the edges are brought together (Fig. 182). Next, the *suture-shield* (Fig. 183) is placed around both wires and pushed gently down to the tissue. The wires are now bent against the sharp inner edge of the shield, and turned round until the twisted part thus formed just reaches the shield.

Fig. 182.

Shouldering Wire Suture: *a*, twisted suture bent to a side and cut short; *b*, shouldered suture.

This is the nicest point in the whole procedure. If you do not twist enough, the suture will be loose and not bring the denuded edges in contact; and if you twist too much, you will strangle the tissue included in the loop, and the suture will cut through.

While the end is yet held with the twister the shield is withdrawn, a tenaculum pressed against the wire just where the twisted part ends, and the latter bent to a side at right angles to the line of union. At a distance of half an inch the tenaculum is pressed against the twisted wire, another right angle formed,

FIG. 183.

Sims's Suture-shield.

and the end cut off at this point. The wire should lie quite flat against the skin or mucous membrane. When there are many sutures, it is sometimes an advantage to turn them alternately to either side. The number of sutures should always be counted at the end of the operation and marked in the history of the case, as they sometimes become so imbedded that they are hard to find. I have seen a forgotten silver suture work its way into the bladder and form the nucleus of a stone, and have heard of overlooked silk sutures causing septicemia and death.

In most operations silver sutures are left in for nine days, but on the cervix some leave them for a month, in order to ensure reliable union or to save a perineum operated on at the same time. When the time comes for removing them, the end is seized with the twister;

the suture is pulled gently up until a minute triangular space appears between the wires and the tissue; one point of the wire-scissors, a strong pair of curved scissors with rather sharp points, is inserted under one of the wires, which should be cut close up to the point where it enters the tissue; and finally the twisted end is pulled in the direction of this same point, by which we press the newly-united edges against one another, instead of pulling them apart. Slight irregularities caused by the imbedding of the wires disappear soon after their removal.

The kind of suture most used in gynecological work is the *interrupted.* Rarely the *quilled* suture is required. The *continuous* suture is often used in laparotomy, in bringing together the edges of the peritoneum in closing the abdominal wall, or after the removal of

FIG. 184.

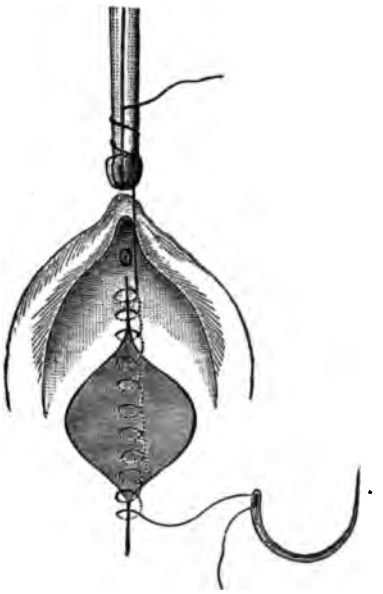

Beginning of a Catgut Tier-Suture.

tumors or organs. Some use it also much in plastic operations for lacerated cervix, cystocele, or prolapse of the uterus. A particular modification of this suture is the so-called continuous *tier-suture* (Fig. 184).

Suppose an oval denudation has been made on the anterior vaginal wall. The needle, armed with a catgut thread a yard long, is carried through both edges and under the whole pared surface from the

operator's right side to the left, near the upper end of the wound. The catgut is pulled through until within about three inches from the end, and tied in a knot as for an interrupted suture. The free end is seized and drawn up with a pressure-forceps. Then several turns are made in the same way below the first, but with a continuous suture, always drawing the thread taut. When the tension becomes too great, the needle is not carried under the whole wound-surface, but only under the part of it lying nearest the median line, thus placing a deep tier at the bottom of the wound. When the operator reaches the lower narrow part of the oval, he comprises again the edges in the suture. If necessary, a second tier of buried sutures may be placed over the first (Fig. 185), avoiding interference with

Fig. 185.

Second Deep Row of Tier-Sutures (A. Martin).

it, and finally the superficial tier is inserted. The best way of knotting the suture is by pulling the free end so far out that it can be tied together with the loop carrying the needle. This method of suturing is expeditious, and has the advantage of bringing broad surfaces in contact with each other.

Interrupted sutures may also be placed in tiers above one another —*e. g.* in closing the abdomen after laparotomy.

Chain-suture is used to secure thick pedicles, and will be described under Ovariotomy.

Sponging and Irrigation.—During most plastic operations very small sponges on sponge-holders are needed, and the assistant should press the sponge very gently against the bleeding place, without rubbing it, and he should always keep those points clean where the needle is to be inserted or pushed out. In operations performed in the dorsal decubitus irrigation with some hot antiseptic fluid may advantageously be substituted for sponging (pp. 177 and 195); and under all circumstances it is advisable to irrigate the wound before closing the sutures, and to remove all clots. The smoother and cleaner the cut surfaces are, the sooner they will grow together by first intention.

How to Clean and Keep Instruments.—New instruments should be boiled, and many do so even before every laparotomy. To boil them in water for twenty to thirty minutes is a simple and practical way of disinfection extensively used of late. After an operation instruments should be scrubbed with soap- or, better, sapolio-water, and nail-brush, rinsed with clear water, and wiped perfectly dry with at least two towels. During the operation they should be immersed in a 2½ per cent. solution of carbolic acid.

Selection of Instruments.—In preparing for an operation the operator or his assistant should carefully go through the different steps of the operation in their mind, and take out all instruments that are sure to be used; but, besides, they ought, within reasonable limits, to prepare themselves for the unexpected by having such instruments in readiness as may be required under certain eventualities, and by having more than one of the most indispensable instruments, such as knives, scissors, needles, pressure-forceps, etc.

5. *Combination of Operations.*—If several operations are needed on one patient, it is, as a rule, best to perform them at different sittings; but as this would sometimes take more time and cost more money than the patient can afford, it may become necessary to perform two or more in one sitting. This ought, however, only to be done when the single operation does not require much time nor cause much shock, for, other things being equal, the danger increases with the length of the operation. A torn cervix, a cystocele, and a lacerated perineum may all be operated on in one sitting; likewise shortening of the round ligaments and perineorrhaphy; but if laparotomy and a vaginal or perineal operation are required, it is better to do the laparotomy first and the other a week later. I prefer to follow the same principle in regard to the cervix, and postpone the other operations until the sutures are removed, for a secondary hemorrhage may occur or menstruation come on prematurely, as happens so often, and the necessary measures for diagnosis or treat-

ment may frustrate the operations performed on the walls of the vagina.[1]

After-treatment.—If there is no danger of shock, the best way is to let the patient sleep after the operation until she wakes of her own account; but if there is shock, it is better to rouse her by aspersion of cold water, shaking, talking, etc.

If she vomits, the measures recommended in treating of anesthesia (p. 204) should be taken.

For the thirst, frequently repeated teaspoonful doses of hot water are often good, but in other cases nothing is like small quantities of ice-water. Ice itself does not quench thirst. An injection of tepid water into the rectum has sometimes proved useful (p. 170).

No food is given as long as nausea continues. As a rule, a fluid diet of peptonized milk, buttermilk, kumyss, matzoon, beef-tea,[2] and oatmeal gruel may be begun the day after the operation. Nothing solid should be taken until the bowels have been moved, which in most cases is done on the fourth day, and in laparotomies even earlier, by giving compound licorice powder or sodium sulphate, a teaspoonful every three hours. (See Ovariotomy.)

Pulse, temperature, and respiration should be marked graphically on charts, so that the surgeon may judge of the condition at the first glance. The nurse should also keep a record of food taken, urine excreted, and movements of the bowels.

C. *Internal Treatment.*—Few gynecological diseases can be cured by internal treatment alone, but, combined with external treatment, the internal is a valuable and often indispensable adjuvant.

The reader is, of course, supposed to be conversant with general therapeutics. He will ever bear in mind that the body from the vertex to the sole forms one system, all parts of which are most intimately connected; he will watch for symptoms pointing to disorders in any division of the body; and in his treatment of gynecological cases he will make such modifications as are called for by the conditions of other organs or the constitution in general.

Food and Drink.—Most gynecological patients are suffering from anemia, and often from anorexia at the same time. Attention must therefore, first of all, be paid to their diet. They should be encouraged to eat as much albuminoid food as possible, and, by taking six small meals a day instead of the usual three more copious ones, much can be done to increase the amount of food taken every day. The physician should give as precise orders as possible in regard to time, quality, and quantity of meals, and look to a proper variety in order to avoid disgust. Mild alcoholic drinks, such as beer, Johann Hoff's

[1] How far some operators go in combination, and yet get good results, may be seen in a paper by Edebohls, *Amer. Jour. Med. Sci.*, Sept., 1892, p. 262.

[2] Mousquera's beef-jelly is excellent for the purpose.

malt extract, Rhine wine, Moselle wine, French or Hungarian claret, Burgundy, vin Mariani, port, or tokay,[1] should be taken with meals unless especially contraindicated.

Weir Mitchell's rest cure, in which the patient is removed from her friends, put to bed, fed by a nurse to the limit of her digestive powers, and treated with massage and electricity,[2] may be indicated in exceptional cases, but, as a rule, gynecological patients should be encouraged to take as much exercise in the open air as they can without increasing their sufferings.

If the patient cannot digest her food, she should take pepsin and hydrochloric acid after each meal:

℞. Pepsinæ,	ʒij;
Acid. hydrochlor. dilut.	ʒij;
Syr. aurant.,	℥ss;
Aquæ,	ad ℥viij.—M.

Sig. A tablespoonful after meals.

I have also found Park, Davis & Co.'s pepsin cordial very beneficial.

In severe cases of indigestion *rectal alimentation* may even become necessary.[3]

Very commonly gynecological patients suffer from constipation and need some *aperient*. A heaping teaspoonful of Carlsbad salts[4] or sulphate of sodium, dissolved in a tumblerful of hot water and taken on an empty stomach in the morning, often effects a cure in the course of six weeks. A heaping teaspoonful of compound licorice powder, taken in the evening, gives a passage the next morning, and many like it. As a rule, I combine the aperient with a tonic by giving Blaud's pills with aloes:

℞. Ferri sulph.,	
Potass. carb.,	āā ʒij;
Aloes Socotrinæ,	gr. v to xv;
Extr. gent. co.,	q. s.

Ft. pil., No. lx.

Sig. Three pills three times a day, after meals.

Tonics are nearly always needed, especially iron, quinine, strych-

[1] Where economy is an object the strong California wines, such as port, sherry, angelica, and tokay, are to be recommended. Good wines can be obtained for 50 cents a bottle, and superior kinds are sold for $1. These wines are certainly much to be preferred to the cheap mixtures often sold as imported wines.

[2] S. Weir Mitchell, *Fat and Blood, and how to Make them*, 2d ed., Philadelphia, 1878.

[3] An important paper on this subject, by Henry F. Campbell of Augusta, Ga., is found in *Trans. Amer. Gyn. Soc.*, 1878, vol. iii. p. 268, *et seq.*

[4] The artificial salt seems to be just as good, and costs only one-fourth of the imported.

nine, and phosphorus. I do not know of any better tonic than the solution of ferrous malate (American Pharmaceutical Manufacturing Company) and the compound tincture of cinchona, equal parts.—M. Sig. A teaspoonful three times a day.

Another valuable combination is the following:

℞.	Strychn. sulph.,	gr. j;
	Ferri et quininæ citrat.,	ʒij;
	Syr. aurant.,	℥ss;
	Aquæ,	ad ℥iij.—M.

Sig. A teaspoonful in a wine-glass full of water, three times a day, after meals.

Plain Blaud's pills are also excellent. If a malarial element is present, full doses of quinine and other antiperiodics are required.

In tympanitis, so often accompanying gynecological diseases, strychnine answers an excellent purpose.

Anodynes are sometimes indispensable, but they should only be used for a short time and in as small doses as will suffice. Magendie's solution of morphine, 4 to 8 drops three times a day; tincture of opium, 15 drops; or suppositories with 1 grain of opium every three hours, are the most common anodynes. Hydrobromate of hyoscine, gr. $\frac{1}{60}$, has been much praised of late. I find phenacetin, in doses of vii ss grains, repeated after one hour, and if needed a second time after three hours, has an excellent effect in relieving pelvic pain.

Extract of conium in the dose of 1 or 2 grains, *t. i. d.*, is also good. Iodoform or aristol, 5 grains, in suppositories, *t. i. d.*, often dulls pain.

Among *sedatives*, the bromides of potassium, sodium, and ammonium, single or combined, are often required. An embrocation with chloroform (1 part) and olive oil (3 parts) gives at least temporary relief in the troublesome backache so generally complained of.

If the patient is troubled with insomnia, it has to be met with one of the many *hypnotics* chemistry has offered us in late years. I have been particularly pleased with sulphonal (gr. x), chloralamid (gr. xlv), or trional (gr. xv).

Resolvents are often called for in chronic inflammations. The most important are iodine, gold, and mercury. We have spoken in another place (pp. 165 and 185) of the application of tincture of iodine to the vaginal roof and the abdominal wall. Internally, iodine is best given as iodide of potassium, gr. viij–x, *t. i. d.* The chloride of sodium and gold has seemed to me to have a decided effect, especially in chronic oöphoritis. It is given in the dose of gr. $\frac{1}{6}$ to $\frac{1}{3}$, *t. i. d.*, after meals. The bichloride of mercury (gr. $\frac{1}{10}$, *t. i. d.*) has been recommended in chronic metritis.

Hemostatics.—In acute hemorrhages from the womb, menstrual or

intermenstrual, *ergot* is the best drug (Extr. ergotæ fl. ʒj, *t. i. d.*, or so-called ergotin, gr. ij, *t. i. d.*). It works by causing contraction of the unstriped muscle-fibers composing the bulk of the womb and those found in the walls of the arteries. It is also useful in subinvolution, chronic metritis, active or passive hyperemia, in intramural and submucous fibroids, but not in polypi, in which it is apt to increase the hemorrhage.

In chronic cases cotton-root is in my experience superior to all other remedies, whatever the cause of the hemorrhage may be.[1] The fluid extract is not so efficacious as a decoction prepared fresh every morning by boiling three heaping teaspoonfuls of rasped cotton-root bark with one pint of water for a quarter of an hour, during which one-half of the fluid evaporates. It is then strained, and one-third taken cold three times a day (℞. Gossypii radicis corticis raspati, ℥iv). This decoction not only checks hemorrhage when present, but seems to have a tonic influence on the uterus and the general health. The patients may take it for months, only interrupting its use from two to four days in the beginning of menstruation. I have found that in fibroids it even takes the concomitant pain away, besides checking the hemorrhage and arresting the growth of the tumor. It works, like ergot, by causing contraction of the muscular tissue of the uterus, and is often used in the South to produce abortion.

Another uterine hemostatic that I sometimes have seen help when the two first named had failed is the *mistletoe* (℞. Extr. visci albi fl. ℥ij. Sig. A teaspoonful three times a day).

Bromides are good when the cause of the hemorrhage is nervous excitement. If malaria is at the bottom of it, *quinine*, followed by small doses of *arsenic* (Liq. potass. arsenitis, gtt. iij to v, *t. i. d.*), is indicated. Arsenic is also recommended in the menorrhagia of growing girls and young women, and that occurring at the climacteric. In syphilitic patients *mercury* is to be prescribed.

Digitalis is recommended for the passive hyperemia consequent on weakness of the heart or mitral insufficiency. *Opium* becomes a hemostatic by subduing excitement. *Cannabis Indica* operates probably in a similar way (℞. Tinct. cannabis Indicæ, ℥j.—Sig. 20–40 drops three times a day). It has been especially extolled in the hemorrhages of the climacteric. Witch-hazel has been accorded a high position on the scale of uterine hemostatics in passive engorgement[2] (℞. Extr. hamamelis fl.—Dose, from a few drops up to 2 drachms).

Among astringents are used *gallic acid* (gr. v to xv in pills or powder, *t. i. d.*), and *alum* (gr. x to xx, *t. i. d.*, especially in the form

[1] Garrigues, The *Post-Graduate*, Jan., 1887, vol. ii. No. 2, p. 117, and *New Yorker Medicinische Presse*, Nov., 1886, vol. ii. No. 6, p. 231.

[2] Chauncey D. Palmer of Cincinnati, O., *Trans. Amer. Gyn. Soc.*, 1887, vol. xii. p. 182.

of alum-whey, prepared by boiling 2 drachms of alum with a pint of milk, and straining.—Dose, a wineglassful, containing 15 grains of alum).

Other drugs that are recommended for uterine hemorrhage are Viburnum prunifolium (Extr. fl., ʒj, *t. i. d.*); hydrastis Canadensis (Extr. fl., gtt. xx, *t. i. d.*), or hydrastininæ hydrochloras (gr. ½, in a capsule, four times a day); terebinthina Chiensis (gr. vj, *t. i. d.*[1]); tinct. capsici (5 drops in a tablespoonful of water every hour); smut of Indian corn (Extr. ustilaginis maidis fl., ʒj, *t. i. d.*), and the root of Caulophyllum thalictroides (℥j–℥ij of the infusion or decoction made with an ounce of the root to a pint of water, or ʒj–ʒij of the tincture made with four ounces to the pint), which both cause uterine contraction; the nettle (Urtica urens and U. dioica, as decoction, ℥j to Oj of water.—Dose, a cupful several times a day). Chlorate of potassium, given together with ergot, is also much praised.

In cases of uterine hemorrhage the bowels should be kept open, so as to avoid congestion of the pelvic organs. Sulphate of sodium, the old "sal mirabile Glauberi," a heaping teaspoonful dissolved in a little hot water every three hours till effect, answers a good purpose.

When we see an exsanguinated person, we are tempted to give iron, but this drug should be carefully avoided during uterine hemorrhages, which I invariably have found increase when any chalybeate is used. Even in the interval between the hemorrhages it has to be used tentatively, as it sometimes increases the amount of blood lost at the next flow. The same applies to alcoholic drinks. I prefer under such circumstances first to use cotton-root, ergot, cinchona, and sulphuric acid, combined with local treatment and non-alcoholic malt preparations, until the tendency to bleeding has been overcome.

Antipyretics.—In acute cases there are often indications for reducing the temperature. If ice-bags and sponging with equal parts of cold water and alcohol do not suffice, recourse is had to antipyretic drugs, such as quinine (in 10-grain doses), salicylate of sodium (gr. xv), antipyrine (gr. x), phenacetin (gr. vii ss), or antifibrin (gr. v), repeated with two hours' interval.

D. *Electric Treatment.*—Electricity is of great value in gynecology. The different kinds of electricity and differently constructed machines and batteries have very different effects, and must therefore be considered separately. We distinguish between *franklinism*, *faradism*, and *galvanism*, and, as a subdivision of the last named, *galvano-cauterization*.

1. *Franklinism*, or *frictional electricity*, is produced by rubbing a glass plate against cushions covered with amalgam. The patient may be insulated by sitting on a stool with glass feet, her body more or less filled with electricity, and sparks drawn from her by approaching

[1] J. R. Chadwick, Boston, *Trans. Amer. Gyn. Soc.*, xii. p. 188.

a metal rod to different parts of her body. Another way of using frictional electricity is by means of sparks and shocks from a Leyden jar. This kind of electricity is little used, and can hardly have any other effect than as a nerve-stimulant and counter-irritant in hyperesthesia and neuralgic pain.

2. *Faradism*, or *inductional electricity*, is produced by leading the electricity generated in one or more voltaic cells, usually composed of zinc and carbon immersed in a fluid containing bichromate of potassium, sulphuric acid, and water, through a short coil of coarse insulated copper wire called the *primary coil*, in such a way that the current is broken and closed at short intervals. The effect is much enhanced by placing a bundle of varnished wires of soft iron inside of the coil. Outside of the primary coil is another called the *secondary coil*, which consists of a much longer and finer insulated copper wire. The current going through the first coil is called the *primary current*, and that induced in the second the *secondary current*.

The primary current produces muscular contraction, but the secondary, having the same effect in a higher degree, is in more general use for this purpose.

One electrode may be applied in the uterus or in the vagina, the other on the abdominal wall over the fundus of the uterus, or both poles may be combined in one uterine or vaginal electrode (Fig. 186). The advantages of the bipolar method are that it is less painful, the sensitive skin not being enclosed in the current, and that, consequently, a much stronger current can be borne.

FIG. 186.

Apostoli's Bi-polar Uterine and Vaginal Excitors: 1, small uterine; 2, medium uterine; 3, large uterine; 4, vaginal, used in the uterus after confinement.

If the primary current goes through a thick and short wire, it has a great *quantity* of electricity; and if the secondary current is induced in a very long and thin wire, it acquires a high degree of *tension*.[1] Such a current of tension has

[1] Lapthorn Smith recommends a primary coil of No. 14 or 16, 25 yards long, with a secondary coil No. 40, a mile long (*Med. News*, Jan. 25, 1890). Rockwell has constructed an apparatus which is made by the Jerome Kidder Manufacturing Company, 820 Broadway, New York (*New York Med. Jour.*, May 13, 1893). With the latest improvements this battery consists of a fixed coil of No. 21 wire, 62 to 65 feet long, for the primary current, and a movable secondary coil, operated by a rack-movement. The total length of this secondary coil is 7,962 feet, with the following sub-

great power in subduing pain (ovaralgia, abdominal pain in hysterical women, vaginismus, and pain arising from pelvic inflammations). It is also an emmenagogue.

The faradic current is, as a rule, applied three times a week, sometimes daily; each sitting lasts from ten to thirty minutes. The electrodes should be applied first, and then the current turned on very slowly, the patient's feeling serving as a guide as to the strength applied. At the end the strength of the current is again gradually decreased until it stops before the electrodes are withdrawn. The reason for so doing is that the vulva is much more sensitive than the vagina and uterus, and that a strong current is more endurable when it is increased and decreased gradually than when it begins and ceases suddenly. The cervix is also much more sensitive than the body of the womb.

3. *Galvanism*, or *chemical electricity*, is produced in a so-called *battery*, a combination of jars containing the elements and the exciting fluids. As strong currents are often needed, it is necessary to have a powerful battery.[1]

One of the *electrodes* is applied to the abdomen or, exceptionally, to the back. It ought to be very large, so as to distribute the current over a large surface, and thereby diminish its density. Apostoli's[2] external electrode consists of wet clay[3] in a bag of muslin 10 or 12 inches long and 6 or 8 inches wide. It has the advantage of adapting itself perfectly to the surface; but it has the drawback of soiling physician, patient, and office, and may, therefore, advantageously be replaced by *Engelmann's electrode*, which consists of a flexible plate of lead 7 by 6 inches, perforated with many holes and covered with punk and chamois; or *Martin's electrode*, which is a nickel-plated concave plate, 8 inches in diameter, covered with a membrane and containing a pint of warm water. The skin should be well moistened before the current is turned on, as otherwise a resistance is formed by the horny epidermis. It is an advantage to have the

divisions: 726 feet of No. 21 wire, tapped at 252 and 474 feet; 2,574 feet of No. 32 wire, tapped at 1,224 and 1,350 feet; and 4,662 feet of No. 36 wire, tapped at 1,632 and 3,030 feet. The machine is provided with a circle-switch, allowing the selection of the total length of the wire, or any part, or any subdivision of any part, of the coil, and with a rheostat for modifying minutely the strength of the current.

[1] A battery of forty large Leclanché cells, each with an electro-motor power of one and a half volts, or one of thirty acid cells, each producing two volts, is much used here.

[2] Electricity had been used in gynecology as long as it has existed as a special branch of medicine, and important work had been done in this line also in this country by Kimball of Lowell, Mass., Ephraim Cutter of New York, J. N. Freeman and John Byrne of Brooklyn, N. Y., and others. But since 1884, Apostoli of Paris has given this kind of treatment such an impetus by opening new and large fields for it, and introducing great improvements in its application, that his name is on all lips, and, therefore, this historical note may be pardoned as an exception.

[3] In order to prevent it from getting dry, it is a good plan to add glycerin to the water (Lapthorn Smith of Montreal, *Amer. Jour. Obstet.*, Aug., 1889, vol. xxii. p. 798).

cutaneous electrode immersed in plain warm water. To add salt is not always good, although it aids in overcoming the resistance of the skin; but when salt is used the sensibility increases, and consequently we cannot use so strong currents as without it.[1] The inner electrode is, as a rule, applied in the cavity of the uterus all the way up to the fundus.

Apostoli's intra-uterine electrode is made of platinum and shaped like a uterine sound, with a movable sheath of celluloid. This sound has the advantage of being incorrodible. It is, however, a disadvantage that it is stiff, has a tube hard to clean, and is very expensive. To obviate this, sounds have been constructed in which only the last two inches are made of platinum, while the remainder is a flexible gum-elastic catheter with a wire in the middle.[2] Aluminium cannot replace platinum, as it becomes corroded. Finding it sometimes difficult or impossible to introduce the flexible sound, I have had one made with a tip of platinum, No. 9 French, 2 inches long, mounted on a brass rod covered with hard rubber (Fig. 187). The anterior

FIG. 187.



Garrigues's Intra-uterine Electrode.

part is bent like a sound, the posterior end split for the introduction of the tip of the rheophore. This electrode is very easy to introduce and to keep clean, and has given me entire satisfaction.[3] The burning part being so small, it must, of course, gradually, both in the same sitting and at different sittings, be applied to different parts of the endometrium.

The stiff electrode should be introduced without speculum after disinfecting the vagina.[4]

[1] A. H. Buckmaster, New York, "The Galvanic Treatment of Fibro-myomata," *Brooklyn Med. Jour.*, Nov. and Dec., 1888.

[2] A still more flexible and cheap sound is Buckmaster's. It consists of a gum-elastic catheter, with a copper wire inside, and wound with platinum wire outside; but it is hard to keep aseptic.

[3] It was made by Waite and Bartlett, 143 East Twenty-third street, New York.

[4] In order to have the chemical cauterizing effect of the intra-uterine electrode, it has been calculated that it should present a surface of 1 square centimeter for each 25 milliampères (F. H. Martin, *Trans. Amer. Gyn. Soc.*, 1888, vol. xiii. p. 275). Apostoli has a series of seven intra-uterine electrodes made of gas-carbon, which conducts readily, is little subject to the corroding action at the positive pole, and may be had at small expense. The length is the same in all, 1 inch, but the thickness varies from 5 to 12 millimeters ($\frac{1}{5}$ to $\frac{1}{2}$ inch) in diameter. They are screwed on an insulated metallic stem, the insulating sheath of which has a circular groove for every inch. This electrode is used in irregular and deep uterine cavities, and by withdrawing it from groove to groove the cauterizing effect is extended from one part to the other (Apostoli, "Novelties," *Brit. Med. Ass.*, August, 1888, reprint, p. 26).

If the inner pole is applied to the vaginal roof, a ball of metal or gas-carbon, one-half to three-quarters of an inch in diameter, mounted on a hard-rubber stem with central wire, may be employed; but a thick layer of cotton should be wound around the bulb and made thoroughly wet. By so doing we avoid burning the vagina.

The current is led from the battery to the electrodes by means of *rheophores*, flexible cords of fine copper wire covered with gutta-percha and silk, with metal tips at the ends, which are easily adapted and kept in place by a set-screw or the elasticity of a cleft in the electrode.

To measure the strength, or so-called intensity, of the current a *milliampèremeter* is needed, a kind of galvanometer, the scale of which should show 250 milliampères.

In order to be able to turn the current on and off very gradually a *collector*, or a *rheostat*, is used. The *collector* is a differently constructed metal contrivance which allows us to use as many and as few cells of a battery as we wish. It ought to be so arranged as to enable the operator to include and exclude one element at a time. The rheostat is a bottle half full of water, into which dip two carbon plates connected with the zinc pole of the battery. Between the two is a third carbon plate connected with the carbon pole of the battery, bevelled at its lower end and ending in a platinum point. This plate can be moved up and down by means of a ratchet. When it is out of the water there is no current, and by gradually immersing it the current becomes stronger until the full strength of the battery is turned on.

The current coming from a battery may be used as a *constant* or as an *interrupted* current. The latter causes a shock and muscular contraction, but is more or less painful, and with strong currents even dangerous.

By using large and wet electrodes we chiefly get the *interpolar effect*, which is that of *electrolysis*. By using small and dry electrodes we chiefly obtain the polar effect, which, when the current is strong enough, becomes a *chemical cauterization*. By combining a large wet electrode on the skin with a small dry electrode in the uterus we avoid burning the skin and obtain the chemical cauterization of the uterus.

Experiments on living animals have shown that when a galvanic current of 50 M. is applied to the intestine of a dog, the same becomes blanched. When it is applied to the heart, and the part encompassed between the poles is examined under the microscope, the striæ of the muscular fibrillæ are found in a granular condition—a sign of beginning disintegration.[1]

That the molecules are moved by the galvanic current can even

[1] Buckmaster, *l. c.*, pp. 12–14.

be seen in a physical experiment. When a vessel is divided into two compartments by a porous partition, and the compartments are filled to the same height with water, and a galvanic current is led through them, the water rises in that compartment in which the negative pole is.

Different Qualities of the Poles.—The two poles of the battery have different physical and physiological effects. The positive pole attracts acids, while alkalies collect at the negative. The eschar produced by the positive pole is dry; that at the negative is softer, larger, and lets the galvanic current penetrate through it. The positive is, therefore, used against hemorrhage and leucorrhea, the negative, where it is desirable to draw blood to the interior of the uterus and for galvanopuncture. The negative pole has a more pronounced denutritive effect. But if, in spite of these general rules, the expected effect is not obtained, it is advisable to try the other pole, and in the course of the treatment of the same case it is often indicated to change poles according to the changed circumstances.

Apostoli's Method.—If possible, the operation should be performed in the patient's home, and she should stay in bed for several hours; but it has often to be performed on out-door patients. Then the patient should lie down when she reaches home. Sexual connection should be forbidden.

Before operating with a battery with collector, the physician should try the battery in order to ascertain that there is no break in the current, which would cause a shock. This may be done by including one cell after the other in the current and watching the deviation of the needle of the milliampèremeter.

The patient should remove her corset.[1] She lies on her back, with her knees drawn up. If there are any erosions of the skin, they must be covered with collodium or paper before the electrode is placed over them. Strict antisepsis is used in regard to hand, vagina, uterus, and internal electrode. The current should not be turned on until all pain caused by the introduction of the intra-uterine electrode has ceased. Then it is turned on slowly, so that it takes half a minute to a minute before the full strength is reached. In the beginning some pain is felt on the skin, due to the resistance offered by the epidermis. Then we wait till it has ceased before increasing the strength of the current. The strength of current used varies according to the nature of the case and the sensitiveness of the patient. As a rule, an intensity of little less than 100 milliampères is used, but when there is a subacute inflammation of the parts situated near the uterus, and in hysterical patients, only 40 to 50 milliampères can be tolerated.[2]

[1] In using Engelmann's electrode it is enough to open the lower part of it.

[2] When it is desirable to use strong currents in hysterical patients, they should go to bed an hour before treatment and take a full dose of morphine and atropine, and,

Under all circumstances it is advisable not to go too far at the first sitting, but to stop, say, at 50 M. There must never be any severe pain felt in the uterus. In large uteri the intensity must be increased or the surface of the intra-uterine pole diminished. The current is kept up from five to ten minutes, in most cases only five. At the end it is turned off as slowly as it was turned on. The vagina is again disinfected, and the patient is directed to use antiseptic injections the following days.

The sittings are, as a rule, repeated on out-door patients once a week, but in more urgent cases twice a week: in private practice the applications are made two or three times a week. But hemorrhage may call for treatment every day; and, on the other hand, where there is perimetric inflammation, it may not be tolerated more than once in eight or ten days. As a rule, the applications are made in the intermenstrual period, but if there is severe hemorrhage it may be necessary to operate immediately. Twenty or thirty sittings may be needed to effect a cure.

Immediate Effect.—Often some uterine colic is felt immediately after the treatment, and may last from a few minutes to several hours, or even till the next day. Sometimes the patient may lose a little dark blood, and on the following days, when the eschar is being thrown off, there is always some sero-purulent discharge. Exceptionally, even enormous amounts of a watery fluid are discharged through the vagina. It is therefore by no means rare that the symptoms, on the whole, get worse during the first five or six sittings before improvement begins. Sometimes fever and other signs of inflammation may necessitate the temporary interruption of the galvanic treatment.

Chemical Galvano-cauterization of the Cervix.—Apostoli has constructed a special bipolar electrode of carbon, to be used for cauterizing the cervix. It is used with strong currents (150 to 200 M.) for a very short time (two to ten seconds).

Galvano-puncture.—If a tumor is situated in the uterus in such a way that the sound cannot be made to enter the uterine canal, galvano-puncture is used. A trocar- or lance-head-pointed platinum or gold needle is pushed through the vaginal roof into the tumor, and then connected with the negative pole of the battery. In inserting the needle care is taken to feel for and avoid pulsating arteries, and to push in such a direction as to reach the uterus. On account of the bladder such punctures cannot be made in front, but only behind and to the sides of the cervical portion; and in the latter locality we must keep clear of the ureters and the uterine artery. Counter-pressure is made on the fundus through the abdominal wall. A fine needle

if that is not enough, chloroform is used. The current is used for ten minutes. The patient remains in bed for at least six hours after the treatment. In this way 200 to 400 milliampères have been tolerated (F. H. Martin, *Med. News*, Jan. 25, 1890).

should be used and introduced without speculum. The introduction of the needle may be much facilitated by making it the negative pole of a mild galvanic current. The puncture is made on the point where the uterus bulges most into the vagina. The needle is not pushed deeper in than a quarter to half an inch. It is either used to form a communication with the cervical canal, so that, the artificial canal once made, the usual galvo-cauterization may be performed on the uterine mucous membrane, or goes simply into the tissue of the uterus and perhaps a tumor situated in its wall. Hemorrhage may be stopped by interpolar action alone, without cauterization of the mucous membrane of the uterus.

Galvano-puncture is a more serious interference than galvano-cauterization of the inside of the uterus, and should not be repeated oftener than every eight or fifteen days. It has to be repeated several times before the canal remains open. It may be combined with positive or negative cauterization according to indications.

Galvanism combined with Aspiration, Injection, and Drainage.—For the treatment of pelvic abscesses, accumulation of fluid in the Fallopian tubes, or other cystic tumors, instruments have been devised which consist of a trocar and canula. The cyst is punctured, evacuated, and washed out with antiseptic fluids. The canula is used as galvano-cautery, and may be left in situ as a drainage-tube.[1] This procedure, rational and ingenious as it is, presents the danger of puncturing a loop of intestine, but may occasionally be available.

Thermal Galvano-cauterization.—The thermal galvano-cauterization differs from the chemical by using heat as the therapeutic agent. It is produced by another kind of battery especially constructed for the purpose. The principle is to produce a large quantity of electricity, which, being led through a comparatively thin platinum wire, that offers great resistance, heats the wire to incandescence. Two sizes of wire are used—a thin and a thick. The former forms a loop that can be drawn round and through a cylindrical body—*e. g.* the cervix uteri. The latter is shaped into knives and domes for cutting and burning.[2] By means of these galvano-cauteries diseased parts may be excised without loss of blood; but in order to obtain this the knife or wire must never be brought to a white heat, and they should be carried slowly and interruptedly through the part to be severed. The knife should be applied cold, in order not to wound the vagina while introducing it. If the wire loop cannot easily be applied, a furrow may first be made for it with the cautery knife. When the wire has

[1] E. C. Gehrung of St. Louis, *Amer. Jour. Obst.*, August, 1888; A. H. Goelet, *Med. News*, Jan. 25, 1890.

[2] The best instrument of this class is that of John Byrne of Brooklyn, N. Y., who also has constructed a special speculum for galvano-caustic operations (*Clinical Notes on the Electric Cautery in Uterine Surgery*, New York, 1873, and *Trans. Amer. Gyn. Soc.*, 1892, vol. xvii. pp. 42–46).

entered the submucous tissue, traction may be made with a volsella on the mass to be removed, so as to give to the cut surface the shape of a hollow cone.

Thermal galvano-cauterization does not only present the advantage over other cauteries (p. 177) that it can be applied with a flexible loop, but it has less radiating heat, and is, therefore, less liable to scorch the surrounding parts; it seems to possess a power of modifying the tissue, even at some distance from the cut surface, by diffusion of the electricity; and it has a powerful antiseptic effect, which appears clinically in the remarkable immunity from peritonitis, cellulitis, and septicemia which distinguishes it from other surgical procedures, and has been proved experimentally by direct application to germ-cultures.

Where there are large masses of diseased tissue in the interior of the womb, it is often preferable first to remove some of them with the curette before using the galvano-cautery. But then bleeding must first be stanched by irrigation with creolin, sponging, and the application of the cautery to open vessels. After that every part of the cavity is gone over repeatedly with the dome-shaped galvano-cautery, and each time that blood oozes from the searing tissues the cavity is to be sponged, until finally it is charred all over. The ragged borders of the excavation should next receive attention, and no raw spot should be permitted to escape the cautery. Finally, the cavity and the vagina are tamponed with iodoform gauze (pp. 174–175).

PART VII.

ABNORMAL MENSTRUATION AND METRORRHAGIA.

THE normal process of menstruation has been considered in the chapter on Physiology (pp. 114–119). This process is subject to disturbances which may occur in very different gynecological diseases or without any affection of the genitals. It may be absent (*amenorrhea*) or *scanty;* the bleeding may take place from another part (*vicarious menstruation*); it may be painful (*dysmenorrhea*); it may begin too early in life (*precocious menstruation*); or it may be profuse (*menorrhagia*).

Finally, there may be hemorrhage from the uterus at other times than the menstrual period (*metrorrhagia*).

CHAPTER I.

AMENORRHEA.

AMENORRHEA is the absence of the menstrual flow. This may either be so that the flow had begun and suddenly stopped, which is called *suppression of menses*, or so that it does not come on at all—*amenorrhea proper*.

1. *Suppression of Menses. Etiology.*—The suppression of menses may be due to exposure during menstruation, by which the feet or the skin becomes wet and cold (compare p. 127); to emotions, especially a fright; or to the appearance of an acute inflammation, such as pneumonia or erysipelas.

Symptoms.—The symptoms are sometimes slight or none, and the courses reappear at the next period; but sometimes the sudden suppression of the menstrual flow gives rise to acute congestion or inflammation of the womb or the appendages, to extravasation of blood into the peritoneal cavity or the pelvic connective tissue, and the amenorrhea may last long or be final.

Treatment.—It is proper to try to bring the flow back by hot applications to the abdomen, hot hip-baths, hot vaginal and rectal injec-

tions; but, as a rule, this medication succeeds only in so far as it relieves pain. The same is accomplished by opiates.

2. *Amenorrhea*, in the proper sense of the word, is the condition in which the menstrual flow fails to appear, although the patient has reached the proper age and feels as if she would be relieved by its coming, or where it does not reappear at the usual period in persons who have already menstruated.

Etiology.—We have seen above that menstruation, as a rule, is absent during pregnancy and lactation. In persons who have never menstruated the cause may be congenital faulty development: absence of the ovaries and tubes; absence or imperfect development of the uterus, such as a rudimentary or infantile uterus; absence or atresia of the vagina. Often, especially in young servants, the cause is overwork, sometimes combined with insufficient food. The causes may also be the same that are at work in making menstruation stop in those who have already menstruated. A common cause is a change of climate and habits. Thus amenorrhea is often found in women who move from the country to large cities, and in those who have recently immigrated from Europe. It is often a sequel of debilitating diseases, such as anemia, phthisis, malaria, typhoid fever, diabetes, or chronic mercurial poisoning. It is not rare in insane women and morphiomaniacs. It is sometimes found in the late stage of chronic metritis, in inflammation of the uterine appendages, in cases of malignant disease of both ovaries, or in women afflicted with a vesico-vaginal fistula. It is a frequent accompaniment of the development of obesity.

About the effect of the removal of the uterine appendages see p. 118.

Symptoms.—The symptoms of amenorrhea, besides the absence of the flow, may be insignificant, but it is quite common that the patient complains of headache, flashing heat, heaviness in the abdomen, nervousness, nausea or vomiting, and sometimes she may even suffer from convulsions of the hysterical or epileptic type. If the lack of flow is due to atresia of the genital canal, the fluid accumulates behind the partition, considerable pain is experienced at each recurrence of the menstrual period, and a tumor is felt in the pelvis corresponding to the distended vagina, uterus, or both. The abnormal sensations occurring at the time of the menstrual period are called the *menstrual molimen.*

Diagnosis.—The most important diagnostic question is if the amenorrhea might not be physiological and due to *pregnancy*, normal or ectopic—*i. e.* extra-uterine. In this respect every sign of pregnancy as taught in the books on obstetrics must be thought of, especially the early ones, such as the softening of the lower uterine segment, the increased diameter of the uterus in the antero-posterior direction, morning sickness, and small tongues of brown pigmentation shooting

out from the superior external circumference of the areola, the first beginning of what is known as the secondary areola.

In extra-uterine pregnancy we may, besides the signs of pregnancy, find a tumor outside of the uterus corresponding in size to the duration of the amenorrhea.

Treatment.—Idiopathic amenorrhea should not be regarded or treated as a disease. In the beginning of menstrual life it is quite common that a period or two are skipped. If the girl is otherwise well no treatment is called for. If the cause of the amenorrhea is anemia, be it from loss of blood, from defective assimilation, or from wasting diseases, the only aim should be to ameliorate the general condition by proper alimentation, tonics (p. 217), moderate exercise in the open air, horseback riding, mild gymnastics, or massage. Aperients have some influence in bringing on the flow, and the one most credited with emmenagogue power is aloes. In malaria quinine and arsenic are the chief remedies. If the nervous system is upset, bromides, antipyrin, or phenacetin is very useful. Hot vaginal and rectal injections, warm hip-baths, warm foot-baths with or without mustard, and long, warm general baths will sometimes bring back the courses. The mere introduction of the sound works as a stimulus to the uterus, and may have the same effect. Electricity in all its forms (p. 220) is a powerful remedy, especially bipolar intra-uterine faradization, with secondary current, and, best of all, galvanism, with the negative pole in the uterus.

Besides iron, quinine, strychnine, and aloes, the following drugs have more or less well-founded reputation as *emmenagogues:* Manganese in the form of the permanganate of potassium or the binoxide (gr. ij to iv, *t. i. d.*); chlorate of potassium (gr. v to xx, *t. i. d.*) in combination with iron; santonin (gr. ij or iij, *t. i. d.*); oleum sabinæ (♏iij to vj, *t. i. d.*); oleum rutæ (♏iij to vj, *t. i. d.*); oleum tanaceti (♏iij to vj, *t. i. d.*); oleum hedeomæ (♏ij to x, *t. i. d.*) or a warm infusion made of the herb; ergot (p. 219); radix gossypii (p. 219); tinct. cantharidis (♏x, xx, up to fʒj, *t. i. d.*); tinct. hellebori nigri (♏xx to xl, *t. i. d.*); and many others. As their effect is very uncertain, it is wise to combine several in one prescription—*e. g.*:

℞. Strychninæ sulph.,	gr. j;
Aloes Socotr.,	℈j;
Quin. sulph.,	ʒij;
Ferri sulph. exsiccat.,	℈ij;
Ol. sabinæ,	ʒj;
Extr. gentian. co.,	q. s.

Ft. pill. No. lx.

Sig. Three pills three times a day.

It is also well to use them in connection with the other remedial agents recommended.

If in cases of rudimentary uterus the development is so insufficient that there is no hope of help from electricity and the other remedies, and if the nervous symptoms are very distressing, the removal of the uterine appendages is indicated. If the apparent amenorrhea is in reality *retention* of the menstrual blood behind an obstruction in the genital canal, the removal of the obstruction by operations that will be described in treating of the diseases of the special organs, is the only means of saving the patient's life.

Scanty menstruation is a lower degree of amenorrhea, and is treated on the same principles especially with tonics and electricity.

CHAPTER II.

Vicarious Menstruation.

Vicarious menstruation, or *xenomenia*, consists in the occurrence, at the time of menstruation, of bleeding from another part of the body than the uterus, or of another secretion. The vicarious bleeding may sometimes take place alone, instead of the normal uterine monthly discharge, or it may be combined with it so as to be *supplementary*. In the latter case the flow from the normal source is generally scanty. Vicarious menstruation has been found to appear on nearly every mucous membrane and every part of the skin, the most common places being the stomach, the breasts, and the lungs. As to other secretions, serous diarrhea and increase of leucorrheal discharge have been observed to accompany or replace menstruation. I have myself seen colostrum in the breasts and profuse perspiration appear at the menopause.[1]

Vicarious menstruation is a rather rare condition. It is mostly found in weak, nervous, hysterical women. Wounds, ulcers, and varicose veins predispose to it.

Symptoms.—Generally the patient has both menstrual molimen in the pelvis and congestion, swelling, and pain in the place where the vicarious bleeding is to occur.

Prognosis.—The importance of the affection depends on the nature of the locality affected. A bleeding from the skin or the nose is far less serious than that from the stomach and the lungs. In general the chances of stopping the abnormal loss of blood are good if we succeed in bringing back or increasing the normal flow.

Treatment.—The treatment is chiefly directed to the relief of the amenorrhea or scanty menstruation (p. 231). The ectopic bleeding calls only for treatment if it becomes excessive, and is then treated according to the general rules of medical and surgical practice.

[1] Garrigues, *Amer. Jour. Obst.*, 1884, vol. xvii. p. 524.

CHAPTER III.

Dysmenorrhea.

Dysmenorrhea is the condition in which the menstrual process gives rise to pain in the pelvic organs. The pain may precede or accompany the flow. It may be due to disease in the ovaries, the tubes, the uterus, the pelvic peritoneum, or connective tissue, or be of purely nervous origin. If the dysmenorrhea is due to inflammation of the uterine appendages and the contiguous part of the peritoneum and connective tissue, it appears, as a rule, earlier—as much as eight days before the flow begins—and a relief is felt when the congestion is diminished by the physiological rupture of capillaries taking place in the mucous membrane (p. 116). The pain is situated in the sides of the pelvis or the iliac fossæ. Sometimes it seems only to be due to a toughness in the texture of the ovary which interferes with the free development of the Graafian follicle.

If the dysmenorrhea comes from the uterus itself, it may be due to inflammation of the mucous membrane or the muscular tissue (endometritis or parenchymatous metritis). There may be an intra-uterine polypus playing the rôle of a ball valve, or the simple swelling of the mucous membrane, especially at the internal os, may prevent the escape of the blood from the cavity, or the uterus may be so bent that the crookedness of its canal opposes a barrier to the free outflow of the blood.

It is especially anteflexion which predisposes to dysmenorrhea, but the more pronounced cases of retroflexion have a similar effect. The cervical canal may be too narrow, especially at the internal or external os (*stenosis*). Sometimes clots are formed in the uterus, the expulsion of which causes labor-like pain in the back and behind the symphysis. Sometimes the whole mucous membrane is thrown off and expelled with similar pains—a condition called *membranous dysmenorrhea*.

Uterine dysmenorrhea is felt more centrally and appears a shorter time before the appearance of the flow, and continues often for several days after it has begun.

That dysmenorrhea which is due to closure of the genital canal and retention of the menstrual blood has already been mentioned in the chapter on Amenorrhea (p. 230).

Nervous dysmenorrhea may be due to over-sensitiveness of the nerves, so that the normal congestion of menstruation is perceived as a painful pressure, and it may be caused by muscular contraction of the internal os.

The degree of dysmenorrhea varies from a slight discomfort to the most excruciating pain, that unfits the patient for any work and almost makes life unendurable.

Prognosis.—The prognosis varies, especially with the etiology. In most cases we may promise relief, if not a cure.

Treatment.—The treatment varies likewise very much with the causes. In young, undeveloped girls, without any inflammatory complications, we try to avoid a vaginal examination. Even a rectal one may be dispensed with for some time. Tonics (p. 217), exercise in open air, gymnastics (p. 188), general massage (p. 187), towel-baths, shower-baths, and sea-bathing (p. 184), are the chief remedies. Where there is any form of inflammation exercise can only be taken with great caution and within narrow limits, and the patient ought to stay in bed during the attack. The treatment of the special diseases causing dysmenorrhea will be found under the description of the diseases of the different organs, but for convenience's sake we will briefly refer to it here.

In all inflammatory conditions we use hot vaginal injections (p. 166), painting of the vaginal roof with tincture of iodine (p. 165), pledgets with glycerin, iodine-glycerin, or ichthyol-glycerin (p. 173), faradization with the secondary current (p. 221), galvanism or scarification of the vaginal portion (p. 183). In endometritis we make applications to the endometrium (p. 165).

In anteflexion the regular use of the uterine sound gives great relief. A retroflexed womb is replaced and a Hodge's pessary introduced into the vagina. Outerbridge's intra-uterine drainage pessary (p. 181) may prove useful. For flexions or mere stenosis the cervical canal is dilated with Hanks's and Garrigues's dilators (p. 153), either moderately (below half an inch) or to the full extent of the latter instrument (divulsion). The narrow canal may also be gradually dilated with the negative pole of the galvanic battery. In cervical anteflexion it may become necessary to split the posterior lip of the cervix (Sims's operation). In desperate cases of dysmenorrhea due to inflammation of the ovaries and tubes salpingo-oöphorectomy is the last resort.

The purely nervous dysmenorrhea is treated with tonics (p. 217) and sedatives (p. 218).

During the attack all forms need some immediate relief. Since these conditions often last long and a baneful habit might be acquired, we should be careful not to abuse narcotics, but in bad cases they are unavoidable. I often use an anti-dysmenorrheic pill of the following composition:

R. Extr. conii alc., ℥j;
Extr. strammon. alc.,
Extr. opii, āā. gr. v.
Ft. pil. No. x.
Sig. One pill at most three times a day.

In the milder cases hot dry or wet fomentations of the abdomen,

and hot drinks, such as hot tea or hot brandy and water or an infusion of anthemis or matricaria, may suffice. Antipyrin (gr. x), antifebrin (gr. v), and phenacetin (gr. viiss) should all be tried before narcotics are used; and they have often splendid effect. If necessary, a second dose is given after an hour, and a third after three hours. Viburnum prunifolium is also a uterine sedative: since the taste and odor of the fluid extract are most offensive to many patients, it is well to give it inspissated in capsules (dose ʒj of the fluid extract, *t. i. d.*).

Among the older drugs apiol (a capsule with ♏v from three to six times a day), pulsatilla (♏ij–iij of the fluid extract in water, three or four times a day during the week preceding menstruation), and cannabis Indica (20 drops of the tincture every three hours during the pain), are yet praised.

There is a widespread popular belief that marriage is a panacea for all sufferings in a girl, but nothing could be more erroneous. If marital relations may work as a stimulus, like electricity, to imperfectly developed genitals, calm an irritated nervous system, effectually cure a stenosis or flexion, by the occurrence of conception and childbirth, on the other hand inflammatory conditions of the pelvic organs get much worse by the congestion produced by coition and the stretching of all the organs unavoidably connected with pregnancy and childbirth (p. 127).

CHAPTER IV.

Precocious and Tardy Menstruation.

A single discharge of blood from the genitals is sometimes found in little children, even in the new-born, without any apparent disease. Irregular bleeding may take place from a sarcoma. But we can only speak of precocious menstruation when there is a regular return of the bleeding from the genitals every four weeks in children below the age of puberty. This is a very rare affection. It has been observed in a child less than a year old, and several cases are on record dating from the second year. As a rule, both the external and internal genitals and the breasts are abnormally developed in such children, and sometimes they show sexual appetite. Their constitution suffers under the untimely loss of blood. There is nothing to be done for them except to try to combat the general weakness, keep them quiet at the time of menstruation, and watch them in regard to masturbation. To check the flow might lead to vicarious menstruation.

Tardy menstruation is the appearance of the menstrual flow at an unusually advanced age. It has been seen to begin as late as thirty-one years. This condition has been considered under the subject of Amenorrhea.

CHAPTER V.

MENORRHAGIA.

MENORRHAGIA is too great a loss of blood from the uterus at the time menstruation is due. The increased loss may either be due to a shortening of the intermenstrual period, or to a protracted duration of the flow, or, most of all, to an increase of the amount lost at each period. Since the normal amount is not known, and, at all events, varies much, we cannot indicate in an exact way where menorrhagia begins, but, practically, we call the flow so if it suddenly becomes much more profuse than the woman usually has it, and if it weakens her.

Etiology.—Menorrhagia is in most cases due to a disease of the uterus, such as endometritis, chronic metritis, subinvolution, lacerated cervix, a granular condition of the os, a fibroid tumor, a polypus, or cancer. It may also be due to the different kinds of displacements of the uterus. Secondly, it may be due to ovarian diseases, especially oöphoritis and small ovarian tumors. Thirdly, certain general acute infectious diseases are apt to cause profuse menstruation, especially cholera, small-pox, scarlet fever, typhoid fever, and inflammatory rheumatism. Among the chronic diseases hemophilia, syphilis, chlorosis, and malaria especially give rise to profuse menstruation.

Sometimes the cause is to be sought in diseases of the heart, the liver, or the kidneys.

Sometimes no cause can be assigned—*e. g.* for the not infrequent menorrhagia found in young girls at the beginning of menstrual life.

Symptoms.—Besides the increased loss of blood, there are other symptoms due to it. If the loss is very heavy, it may cause acute anemia with rapid, flagging pulse, dyspnea, pallor, cold clammy skin, faintness, or syncope. But oftener we find a chronic anemia characterized by pallor, weakness, asthenopia, and backache.

Diagnosis.—The diagnosis between menorrhagia and *metrorrhagia* —*i. e.* uterine hemorrhage occurring independently of menstruation —is sometimes difficult or impossible when so frequent hemorrhages take place that the patient does not herself know what would be the regular time for a menstrual flow to come on; but in most cases the distinction can be made by the time elapsed since the last bleeding, by the sensations which generally precede the menstrual flow, by the

admixture of mucus with the blood, and by the gradual way in which it appears.

Prognosis.—It is doubtful if ever a woman has died directly of menorrhagia, but repeated losses undermine health and shorten life.

Treatment.—In the mildest cases we prescribe ergot and other internal hemostatics (p. 219), rest, cool diet, and abstinence from alcoholic drinks and coffee. The bowels should be kept open with saline aperients (p. 217). If there is any excitement, bromides and opiates, especially opium suppositories (p. 218) are indicated. If this treatment does not have the desired effect, vaginal injections with hot water may be added. If they do not check the hemorrhage, we add liq. ferri chloridi to the water (p. 177). If the bleeding continues, an intra-uterine injection of hot water with or without liq. ferri is given (p. 168). A bag with hot water applied to the lumbar region is sometimes effective. An ice-bag is placed over the symphysis (p. 183). If all this is ineffectual, or if the hemorrhage is alarming, we tampon the vagina (p. 174) or the uterus (p. 175).

In the intermenstrual period a treatment is instituted according to the cause of the menorrhagia. If the endometrium is affected, the uterus is treated with applications of liquor ferri (p. 166), curetted (p. 171), or cauterized by means of chemical galvano-cauterization (p. 225) with the positive pole in the uterus. Granulations are destroyed, the torn cervix united, a polypus removed, and a fibroid treated as taught under the discussion of that disease. Ovarian inflammation is treated with injections, applications, resolvents (p. 218), glycerin pledgets, galvanism, etc.

At the same time we try by means of hemostatics, tonics, and food to build up the patient as much as possible before the occurrence of the next menstruation (pp. 216–219).

In cases of heart disease a moderate bleeding gives relief, and should, therefore, not be checked too soon. Digitalis, strophanthus, and aconite are valuable remedies under such circumstances. When the liver is torpid, attention to diet, abstention from alcoholic drinks, and the administration of calomel, pulv. hydrargyri cum creta, or euonymin (gr. ss–v) are indicated. In kidney disease especial attention should be paid to the vicarious functions of the skin and bowels.

The physician must not forget that a moderate loss of blood is a normal condition, a kind of safety-valve, for the female economy. He must, therefore, allow a reasonable amount of blood to escape before he begins to check the flow. As a rule, I let patients suffering from menorrhagia bleed from two to four days before interfering, but a dangerous loss of blood should be stopped at any time by the most potent measures. How to act in a given case can only be learned by tact and experience. If everything else fails to check menorrhagia, Tait recommends the removal of the appendages.

CHAPTER VI.

METRORRHAGIA.

METRORRHAGIA is a profuse uterine hemorrhage occurring at another time than the menstrual flow. Its causes, symptoms, and treatment are essentially the same as those of menorrhagia, just described, with the exception that this flow, being entirely abnormal, need not be allowed, and may, therefore, be treated more actively from the very beginning, unless the bleeding has a beneficial influence on some diseased condition—*e. g.* pelvic inflammation.

CHAPTER VII.

GENERAL MENSTRUAL DISORDERS.

THE menstrual process being a general condition of which the secretion of blood from the mucous membrane of the uterus is only one feature, there is hardly any part of the body in which we may not find more or less important disturbances connected with it. These occur especially before the flow appears or in the beginning of the same. They may accompany a normal bloody discharge from the genitals, but are more commonly combined with amenorrhea or scanty menstruation.

The Nervous System.—Headache, especially in the shape of migraine, is quite common. Sometimes neuralgic pains are felt, especially in the arms and legs. Hysteria may be entirely due to menstrual disorders or get worse at every period. In exceptional cases it may reach the highest degree, so-called hystero-epilepsy. True epilepsy may only appear at the time of impending menstruation, or the attacks may be worse every time the period recurs. In insane women the influence of menstruation is very marked. As a rule, maniacal attacks get worse or appear only at that time. Symptoms of impulsive insanity, such as kleptomania or the impulse to murder, are sometimes decidedly increased by menstruation. The insanity of girls at puberty, especially that pyromania which drives them to set houses or hayricks on fire irrespective of consequences, may be parallelized with that of the menopause which we have already mentioned (p. 122).

The Eyes.—Existing inflammation gets very frequently worse. In those suffering from exophthalmic goiter the eyes are more prominent. The condition known as hysteric copiopia[1] acquires generally increased

[1] This disease, described by Foerster, is characterized by pain in the region of the

intensity. Blood may be extravasated into the anterior camera or behind the retina. Papillary inflammation, optic neuritis, neuro-retinitis, and complete amaurosis have been observed. The formation of sties is very common.

The Ear.—Vicarious menstruation may occur. Existing granulations swell; purulent discharge, buzzing sound, and deafness increase frequently.

The Nose.—Profuse epistaxis may be due to vicarious menstruation.

The skin is often the seat of exanthemata, such as acne, urticaria, eczema, exudative erythema, herpes, etc. The latter appears not infrequently on the genitals, which also are liable to become the prey of pruritus. The legs and the face may become edematous. Sometimes there is free perspiration, with or without an unpleasant smell, or seborrhea of the scalp. Besides vicarious menstruation in the shape of blood trickling out through fissures forming in the skin, there are sometimes minute ecchymoses in the same.

The Digestive Tract.—Sometimes the tongue is coated; the patient suffers from toothache, aphthous stomatitis, or sore throat. As mentioned above, the stomach may be the seat of vicarious menstruation, from a few teaspoonfuls to over two pounds of blood being vomited. There may also be a hemorrhoidal flow or diarrhea. In rarer cases a dull pain in the right hypochondrium betokens a congestion of the liver, which may even lead to jaundice.

The Respiratory System.—The thyroid body swells not infrequently, especially in those afflicted with goiter, and this swelling may cause such a compression of the trachea that tracheotomy becomes necessary. We have mentioned above that the lungs are one of the seats of predilection for vicarious menstruation. This hemorrhage may be dangerous in itself, and may be a precursor of phthisis.

The circulatory system does not suffer much, except that palpitations are not uncommon, and that angiomas and varicose veins are liable to increase.

The Urinary Organs.—The sufferings due to floating kidney become worse during the congestion preceding menstruation. There is a frequent desire of evacuating the urine, and the bladder may be the seat of vicarious menstruation.

conjunctival fold, in or behind the eye, the forehead, less frequently in the malar bones or the superior maxilla, and by a peculiar kind of photophobia experienced in regard to artificial light in a dark room, besides a great variety of hyperesthetic phenomena. It attacks both eyes. It is incurable, but disappears spontaneously, often after many years. It is frequent in the higher classes, and is by far more common in women than in men. It is said in the former to be a reflex neurosis from chronic parametritis. As treatment it is recommended to let the patient take ½ drachm of Canadian castoreum and 1 drachm of extract of valerian in the course of four days, which gives relief for several weeks. At the same time the patient should use eye-drops with acetate of zinc (W. A. Freund, *Gynäkologische Klinik*, Strasburg, 1885, vol. i. pp. 265–272).

The Genitals.—Displaced ovaries may become particularly painful, and the swelling of the ovary enclosed in a hernia may give rise to strangulation. Fibroids often grow larger, and intra-uterine polypi may be pushed down into the cervix or the vagina. In cases of atresia we have seen that the pain increases at each new outpouring of blood that finds no vent. Leucorrhea precedes or follows very frequently the menstrual flow, or appears, as stated above, as a substitute for it.

The breasts not uncommonly become swollen and painful, and they are one of the more frequent seats of vicarious menstruation.

Patients affected with divers chronic diseases often feel more discomfort during menstruation. It is claimed that amenorrhea, without the presence of any other disease, may cause edema and ascites, and that menstruation has a very bad effect on the progress of osteomalacia.

Treatment.—In all affections connected with amenorrhea or scanty menstruation the first indication is to try to bring on or increase the menstrual flow, except in those cases in which there is a general debility that, presumably, would be made worse by any loss of blood. Under these latter circumstances the first thing to do is to strengthen the general health. Secondly, the different special disturbances call for treatment. Headache and neuralgia are often relieved by the administration of phenacetin, antipyrin, antifebrin, caffeine (gr. j to iij *t. i. d.*), or the combination called effervescent granulated bromo-caffeine (a heaping teaspoonful), pulv. paulliniæ (gr. xx, *t. i. d.*), extr. cannabis (gr. $\frac{1}{4}$ to $\frac{1}{2}$, or 20 to 40 minims of the tincture, *t. i. d.*). A favorite combination of mine is—

℞. Phenacetini, ʒj;
Caffeinæ, gr. xxiv;
Sodii bromidi, ʒij.
M.—Div. in ptt. aequ. No. xii. Det. ad chart. cerat.
Sig. 1 powder repeated, if needed, after 1 and 3 hours.

In regard to the treatment of the manifold other disturbances mentioned above we must refer the reader to works on the practice of medicine, special treatises, and later chapters of this Manual.[1]

[1] Those familiar with German may find much valuable information in Leopold Meyer's *Der Menstruationsprozess und seine Krankhaften Abweichungen*, Stuttgart, 1890.

PART VIII.

LEUCORRHEA.

NORMALLY, the genital tract is just moist enough to be soft and slippery; nowhere a drop of fluid is visible. Any mucous, serous, or purulent discharge is abnormal, and constitutes in itself a disease or is a symptom of one.

The word "leucorrhea" means a white flow, but it is used to designate any discharge other than blood coming from the genitals. Popularly the disorder is called "the whites."

The discharge may come from the vulva, the vagina, the neck or the body of the womb. That from the vulva and the vagina is acid, that from the uterus alkaline. The microscope reveals flat epithelial cells in vulvar and vaginal leucorrhea, an abundance of mucous corpuscles in the cervical, and columnar epithelial cells, sometimes ciliated, in that coming from the uterus, be it from the neck or the body (p. 51). The fluid is serous, mucous, or purulent, and may have an admixture of a little blood. It may be colorless, white, yellow, green, red, or brown. The white color is due to the presence of epithelial cells, the yellow to pus, the red to fresh blood, and the brown to decomposed blood. It may be nearly as thin as water or more or less thick like cream and soft cheese. A colorless, thick fluid like the raw white of an egg is exclusively secreted by the goblet-shaped cells found in the depressions between the branches of the arbor vitæ (p. 51).

Leucorrhea is *idiopathic*, *specific*, or *symptomatic*. A leucorrhea is called *idiopathic* when it is not due to any permanent structural anatomical lesion. It is then constitutional and forms a disease in in itself.

The *specific* leucorrhea is that due to gonorrheic infection.

A leucorrhea is *symptomatic* when it is one symptom among others of a certain disease.

Causes.—1. *Idiopathic Leucorrhea.*[1]—Like other catarrhal affections, and often combined with them, it may be due to a cold, damp

[1] Fordyce Barker's paper, "Leucorrhea considered in Relation to its Constitutional Causes and Treatment," *Trans. Amer. Gyn. Soc.*, 1882, vii. pp. 130–141, contains many valuable hints on this topic that has disappeared from many modern treatises on gynecology.

climate or residence. It may be connected with plethora or anemia. It may be induced by anything that weakens the constitution, such as protracted lactation, bodily or mental fatigue, emotions, especially of a depressing kind, and insufficient nourishment. It occurs frequently in persons predisposed to pulmonary phthisis. It is sometimes brought on by local irritation, such as masturbation, frequent coition, gravidity, childbirth, or abortion; or it appears in consequence of amenorrhea or scanty menstruation as a supplementary or vicarious menstruation, not only during the period of menstrual life, but frequently after the climacteric has been established. In this way it may also take the place of lactation, suppressed perspiration, hemorrhoidal flow, diarrhea, and other discharges.

2. The *specific leucorrhea* due to gonorrheic infection will be considered under Vaginitis.

3. *Symptomatic Leucorrhea.*—It may be a symptom of rheumatism, scrofulosis, tuberculosis, malaria; of numerous local diseases of the genitals, such as vulvitis, colpitis, endometritis, metritis, subinvolution, granulations at the os or in the interior of the womb, ulcers, a lacerated cervix, polypi, fibroids, sarcoma, carcinoma; or of diseases in other organs which interfere with a free circulation in the genitals, such as disease of the heart and the liver.

Symptoms.—The leucorrheic discharge is a drain on the system, which has given rise to the popular belief that the white stuff coming out of the genitals is the spinal marrow that melts. While it may be brought on by anemia, it may also lead to it. The patients complain of weakness, backache, neuralgia in different parts of the body, and often an irritable bladder. Commonly they suffer from anorexia and dyspepsia. Frequently there are menstrual disturbances, especially too frequent, too long, and too copious menstruation, or, on the other hand, amenorrhea. Local changes in the cervix and the vagina, especially excoriations, ulcerations, granulations, and eversion of the mucous membrane, may be due to the irritation caused by the discharge, just as we find vegetations, eczema, erythema, intertrigo springing up in the groins, at the vulva, and on the inside of the thighs.

Prognosis.—Since leucorrhea is found under such extremely different conditions, nothing can be said in a general way about the prognosis. It depends mostly on the cause.

Treatment.—The same applies to the treatment, but here we may add that, as a rule, a general and a local treatment should go hand in hand. The more the condition depends on constitutional causes, the more general treatment is needed, and the more powerful it is; the more local disease predominates, the more actively must the leucorrhea be combated in its seat.

The most substantial food and invigorating drinks that the stomach

can digest must be given (p. 216), and digestion is to be helped, artificially if necessary. The patient must have a passage once in twenty-four hours. She must wear sufficiently warm clothes, especially woolen underwear (pp. 126 and 165). Tonic medicines (p. 217), general massage (p. 187), gymnastics (p. 188), and exercise in the open air, are useful. Change of climate, locality, and surroundings is a great help. The patient should, if possible, be sent to a warm dry climate or high up in the mountains, but at the same time pleasant company should be provided. A cold and damp dwelling must be exchanged for a dry and sunny one. Different kinds of baths (p. 183) are to be recommended: warm hip-baths, tepid general baths, Turkish or Russian baths, are especially indicated where there is a rheumatic diathesis. Otherwise, it is better to strengthen the nerves and harden the skin by means of towel-, sheet-, or sponge-baths, shower-baths, hydrotherapy, or sea-baths. In many cases of idiopathic leucorrhea a treatment carried out on these lines will suffice to effect a cure. This ought especially to be tried in intact girls, so that even a physical examination may be avoided.

In most cases, however, recourse to local treatment is an imperative addition to the general treatment. Applications of tincture of iodine, solution of nitrate of silver, carbolic acid, chloride of iron, chloride of zinc (20 to 50 per cent.), etc. are made to the affected parts (p. 165). If there is no free drainage from the uterus, the cervical canal should be dilated (p. 153). Vaginal injections with hot water or astringents are beneficial in most cases (p. 166). It may become necessary to remove granulations from the cervix or fungoid growths from the inside of the corpus and fundus, or to scrape the endometrium with the curette (p. 152), or to burn the cervical canal with the thermo-cautery (p. 177) or by means of thermic or chemical galvano-cauterization (pp. 227 and 223). The mucous membrane of the cervix may also be cut away.

As to the special indications to be met in regard to underlying general or local diseases, the reader is referred to works on the practice of medicine and to later chapters of this manual.

Some internal remedies, such as aletris (cordial, ʒj *t. i. d.*), hydrastis (fluid extract, gtt. xx, *t. i. d.*), cimicifuga (fluid extract, ʒss to ʒj), inula (a decoction of the root, ʒiij to water q. s. ad ℥iv, to be taken every morning), seem to have the special virtue of checking leucorrhea.

In phthisical patients the leucorrheal flow is by some regarded as a kind of issue, to dry up which would precipitate the destruction of the lung. The local treatment should, indeed, be of the mildest or may be dispensed with altogether, but all the internal remedies recommended, such as cod-liver oil, terraline, hydroleine,[1] etc., only

[1] Terraline is a product gained from petroleum. Hydroleine is a mixture of cod-

strengthen the whole constitution, and thus benefit the lungs indirectly, and the leucorrhea, if abundant, being in itself a drain on the physical strength, can hardly fail to have a bad influence on the pulmonary affection.

liver oil, boracic acid, and other substances. Both of these medicines have seemed to me to have so decided an effect in wasting diseases that I do not hesitate to mention them here.

DISEASES OF WOMEN.

II.

SPECIAL DIVISION.

SPECIAL DIVISION.

PART I.

DISEASES OF THE VULVA.

CHAPTER I.

MALFORMATIONS.[1]

1. *Absence of Vulva.*—By an arrest of development in the first month of fetal life the external genitals and the anus may be absent, the skin covering the region uninterruptedly. (See p. 32.) This condition is almost always combined with arrest of development in other organs, and is only found in non-viable fetuses.

If the anus is formed, life may be continued without external genitals, the urine being evacuated through the navel. Such a case is on record, and was cured by the formation of an artificial urethra and closure of the opening of the urachus at the umbilicus.

2. *Hypospadias.*—In consequence of an insufficient closure in the median line the lower wall of the urethra may be split more or less deeply (Fig. 188). If the defect extends very deeply, so as to divide the different sphincters of the urethra (p. 76), the patient cannot retain her urine. A small degree of hypospadias is, by far, not so important in woman as in man, and will hardly call for treatment. The complete congenital hypospadias has been successfully treated by paring and uniting the surrounding mucous membrane to such an extent as to form an artificial urethra, the relations of which to the bladder were much like those of a spout to a teapot.[2]

[1] In this chapter I have to some extent used my article on this subject in *American System of Gynecology*, edited by Mann, Philadelphia, 1887, vol. i. pp. 235-282.

[2] For details the reader is referred to T. A. Emmet's *Gynecology*, 2d ed., pp. 649-654.

3. *Epispadias.*—Epispadias (Fig. 189) is the name for the condition characterized by a lack of union of the upper wall of the urethra. It is generally combined with a similar defect in the anterior wall of the bladder (*extroversion*). The clitoris and the symphysis pubis may be cleft or not. These defects are due to the intracorporeal part

FIG. 188.

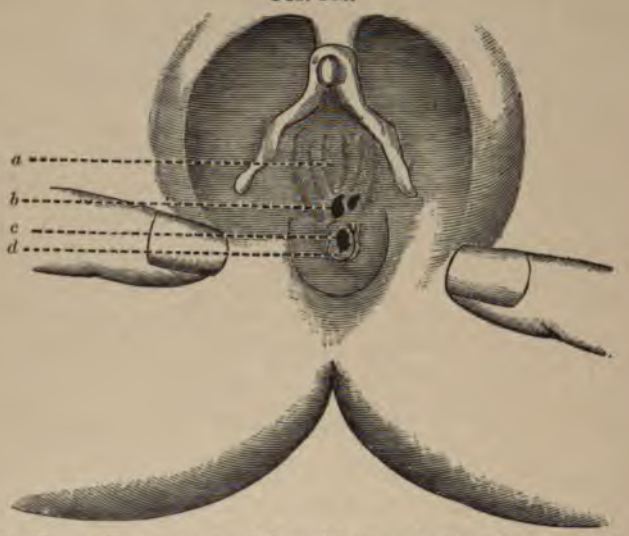

Hypospadias (Mosengeil); *a*, open canal, formed by the anterior wall of the urethra; *b*, posterior, closed part of the urethra; *c*, entrance to vagina; *d*, hymen.

of the allantois being pulled abnormally forward, becoming overfilled and finally bursting.

Epispadias, like hypospadias, has been cured by different plastic operations. One way is to form a transverse flap of the mucous membrane of the vestibule and stitch it to the meatus. Another is to denude two lateral surfaces and unite them in front of the open urethra.

4. *Abnormalities of the Clitoris.*—Sometimes the clitoris is *split* in two lateral halves, without any cleavage of the urethra or bladder, but in connection with a non-united symphysis and an opening in the abdominal wall above the bladder. Such cases are exceedingly rare. The cleavage of the clitoris is of no importance. The defect in the abdominal wall may be closed according to the general rules of plastic surgery.

The clitoris may be *absent* or very *small*, or, on the other hand, as *large* as a medium-sized penis.

This hypertrophy of the clitoris may be inconvenient, and can then

be remedied by *amputation* with the galvano-caustic wire (p. 227), with the écraseur, or with Paquelin's thermo-cautery (p. 177).

The prepuce is very frequently adherent to the glans, and in many cases this condition gives rise to reflex neuroses, even epilepsy and nymphomania.

Treatment.—The vulva should be washed with bichloride-of-mercury solution. A couple of drops of cocaine solution are thrown

FIG. 189.

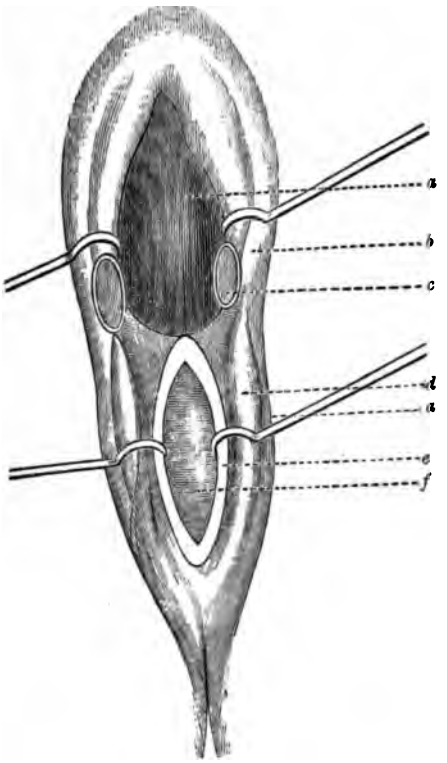

Epispadias (Kleinwächter): *a*, fissure in the bladder; *b*, labium majus; *c*, clitoris; *d*, labium minus; *e*, hymen; *f*, vaginal entrance.

into the glans clitoridis with a hypodermic syringe, and four or five drops more are thrown into the prepuce. If one margin of the prepuce is then seized with a fixation-forceps, the thumb-nail will easily complete the work of clearing the glans. Raw surfaces are sprinkled with aristol and the prepuce packed with a little ball of corrosive-sublimate gauze. As there is a marked tendency to recurrence of the

adhesions, and the consequent nervous reflexes, this packing must be repeated every two or three days until the appearance of normal smegma shows that the mucous surfaces have developed sufficiently to take care of themselves.[1]

5. *Abnormalities of the Labia Minora.*—The labia minora may be *absent.* They may be *multiple*, each being split lengthwise in two or three flaps. They are sometimes *too long*, which is found physiologically in whole tribes. (See, for instance, Hottentot apron, p. 37).

This condition may interfere with coition, and may then be remedied by cutting away the superfluous tissue and uniting the edges of the wound, which will heal by first intention.

6. *Abnormalities of the Labia Majora.*—These may likewise be *split* by longitudinal clefts, so as to become double or triple.

Alone or together with the labia minora they may extend so far back as to reach behind the anus, so that there is no perineum.

7. *Epithelial Coalescence.*—During the second half of fetal development the large and small labia may grow superficially together from behind forward. It is rare that the coalescence goes so far as to prevent micturition in the new-born child. Sometimes it may, however, give an inconvenient direction to the jet of urine. Menstruation may become difficult, and the small dimensions of the vulvar opening may oppose a serious obstacle to coition or childbirth.

If the coalescence is combined with hypertrophy of the clitoris, the sex may become doubtful.

Treatment.—The parts ought to be cut open in the median line on a director introduced through the existing opening, and kept separated during the healing process, or, if the cut surface is large, the edges of each side may be brought separately together by stitches.

It is not rare that the *urethra* alone is agglutinated, so that the child cannot pass its urine. All that is needed in such cases is to introduce a silver probe into the bladder. Once opened, the canal stays open.

8. *Hermaphrodism.*—Hermaphrodism, or *hermaphroditism*, is the condition in which the characteristics of the two sexes become more or less blended in one individual.

From the history of the development of the genitals we know that they are composed of three parts, each of which has its independent embryonal foundation—namely, the sexual glands, the two sets of ducts (Wolffian and Müllerian), and, finally, the external genitals (pp. 20, 22, 30, and 33). It is, therefore, not so difficult to understand how one of these parts may be developed according to a sexual type differing from that of the others.

[1] Robert T. Morris of New York, *Trans. Amer. Obstetricians and Gynecologists*, 1892.

It is more difficult to understand how there can be more than one set of reproductive glands, for we have seen (p. 22) that it is one and the same body that, identical in the beginning, later becomes either an ovary or a testicle. But while the connective-tissue part is identical in the two kinds of glands, ovary and testicle, it is not unlikely that the epithelial part of them has a different origin in the two sexes. Some anatomists claim, indeed, that the seminal canals in the testicle are formed as invaginations from the Wolffian duct, while we know that the follicles in the ovaries are derived from the germ-epithelium (p. 28).

We know, furthermore, that we may have supernumerary ovaries (p. 119), and the same is claimed in regard to testicles, although it is infinitely rarer with them than with ovaries.

Hermaphrodism is *true* or *spurious*. *True hermaphrodism* is that in which at least one ovary and one testicle are found in the same person. There may be found a complete double set of sexual glands—*i. e.* two ovaries and two testicles (*true bilateral hermaphrodism*); or there might be found one sexual gland on one side, be it a testicle or an ovary, and on the other both a testicle and an ovary (*true unilateral hermaphrodism*), but it is somewhat doubtful if such a case actually has been observed or not; or, finally, there may be one ovary on one side and one testicle on the other (*true lateral hermaphrodism*).

True hermaphrodism is at best exceedingly rare, and its existence is not even universally admitted.

Spurious hermaphrodism, or *pseudo-hermaphrodism*, is that condition in which the sexual glands belong to one sex, either masculine or feminine, and the passages leading from them, as well as the external parts, approach more or less the other. Spurious hermaphrodism is subdivided into *male* or *female* according to the nature of the sexual gland. Each of these classes comprises three groups: the first is formed by those cases in which the ducts alone belong to the opposite sex (*internal male or female pseudo-hermaphrodism*); the second, by those in which the external parts alone represent the opposite sex (*external male or female pseudo-hermaphrodism*); and the third, those in which both the ducts and the external parts approach the type of the other sex (*internal and external*—or complete—*male or female pseudo-hermaphrodism*).

Pseudo-hermaphrodism, as well as true hermaphrodism, is a malformation that dates from the earliest periods of fetal development. It is much more frequently found in the male than in the female sex, and reaches also a much higher degree in the former, so that a vagina, uterus, and tubes may be found more or less developed in an individual with testicles, vasa deferentia, seminal vesicles, and male external genitals. The presence of menstruation does not settle the sex, since a periodical bloody discharge has even been observed to

take place from normal male genitals, and especially in males suffering from hypospadias.

The external genitals being formed in both sexes of the same substance, it is impossible to have a double set of them, one male, the other female, but some portions may assume more the male, others more the female, type.

The general appearance of the body, especially in regard to the length of the hair, the development of the breasts, the prominence of Adam's apple, the breadth of the hips, and the angularity or rotundity of the form, presents a mixture of both sexes, the preponderance being, not with the real sex, as determined by the sexual glands, but with the external genitals.

The diagnosis of the sex of hermaphrodites is often difficult, sometimes impossible, in the living individual; nay, even the pathological specimens, when examined after death, present so many deviations from the normal conditions that they are interpreted in a different manner by different observers of equal ability.

When there is any doubt about the sex of an individual, it ought always to be declared a male. This will not only give it better chances to make a living and certain privileges in regard to political and hereditary rights, but it is also much safer to bring it up as a boy. A "girl" with a testicle can, if the sexual appetite awakens, do much harm in a boarding-school, and if it does not awaken she may marry without knowing that she, from a physical standpoint, is an unsatisfactory mate.

CHAPTER II.

Ruptures (Hernlæ).

Two kinds of herniæ find their way into the labia majora—viz. the *anterior, or inguino-labial, hernia* and the *posterior, or vagino-labial, hernia.*

1. *The anterior labial, or inguino-labial, hernia* in women corresponds with the inguinal hernia in men, and is not very rare. It comes out through the inguinal canal, follows the round ligament, and descends into the anterior part of the labium majus. It may be found on both sides simultaneously (*double* inguinal hernia). At first it forms a round tumor in the region of the external abdominal ring; later, when descending toward and into the labium majus, it becomes pear-shaped. It may contain the gut, the omentum, the ovary, and the uterus, and when impregnation takes place even a fetus in the uterus.

Diagnosis.—When near the external inguinal ring, it may be mis-

taken for a *tumor of the round ligament*, or *hydrocele*. In the labium it may be mistaken for an *abscess, cyst, or tumor*. As a rule, it will be possible to make the distinction by paying attention to the history, by a resonant percussion-sound, by the increase in size caused by coughing and abdominal pressure, by the possibility of bringing it back into the abdominal cavity through the inguinal canal, by the peculiar sensation of the gut slipping away under the fingers, by a gurgling sound heard during taxis, by the absence of local inflammation, and by the absence of fluid, or its nature when aspiration is made with a hypodermic syringe.

Treatment.—The treatment is like that in the male—as a rule, by means of a truss, sometimes by the radical operation. When it is strangulated and cannot be reduced, herniotomy is imperative. It may become necessary to extirpate an ovary found in the sac and to perform Cesarean section, or, preferably, Porro's operation when pregnancy occurs in the imprisoned uterus.

A variety of inguinal hernia found in little girls is the *hernia in the canal of Nuck*, corresponding with the hernia of the tunica vaginalis in the male. It is extremely rare. The treatment is the same.

2. *Posterior Labial, or Vagino-labial, Hernia.*—This form is much rarer than the preceding. The escaping abdominal viscera here descend in front of the uterus, along the vagina and bladder, between them and the levator ani muscle, and form a swelling at the posterior end of the labium majus. The course corresponds with the ascending branch of the ischium. It usually contains a part of the small intestine, but the large intestine and the omentum have also been found in it.

Diagnosis.—It differs from *anterior labial hernia* by its position farther back, by the freedom from swelling of the space between it and the inguinal canal and of the latter itself, and by being reducible, not in the direction of the external inguinal ring, but in that of the vagina.

The diagnosis from *other affections* is made in the same way as just pointed out for the anterior variety.

Treatment.—It is hard to hold this kind of hernia back, but, as it may become very large, the attempt should be made with vaginal pessaries, of which an inflatable rubber bag would be most likely to answer, or a truss. Once a surgeon obtained retention by denuding the mucous membrane in a circle round the lower end of the hernia, doubling it up and stitching it together; after thus having thickened the integument covering it, it could be held back with a truss.[1]

[1] Winckel, *Die Pathologie der Weiblichen Sexualorgane*, Leipzig, 1881, p. 284.

CHAPTER III.

Tumors connected with the Extrapelvic Portion of the Round Ligament.

In connection with the extrapelvic portion of the round ligament may be found: 1, *hydrocele;* 2, *hematocele of the canal of Nuck;* 3, *hematoma of the round ligament;* and, 4, *fibroma of the round ligament.*

1. *Hydrocele*[1] is a swelling due to an accumulation of serum in connection with that part of the round ligament which lies in or below the inguinal canal. It is a rather rare disease. The fluid may be contained in the canal of Nuck (p. 37), or in the surrounding connective tissue, or in the ligament itself. The space, if formed by the canal of Nuck, may yet communicate with the abdominal cavity, or may be shut off from all connection with it by adhesion between its walls at the upper end. It is covered by the skin, the superficial fascia, and the fascia transversalis. It is sometimes divided into several compartments. The *fluid* is, as a rule, serous and of a slightly greenish-yellow color, like serous collections in other parts of the body, but in traumatic cases it may be more or less bloody, and, when inflammation occurs in the sac, it may become purulent and contain gas. It begins as a small, painless, oblong swelling in the inguinal canal, and extends in its slow growth down into the anterior part of the labium majus. It may be found on both sides. At first it often disappears when the patient lies on her back or when it is being compressed. If the fluid is found in a closed sac, the swelling is immovable, elastic, not very tender unless inflamed, and translucent, as the corresponding affection of the tunica vaginalis in man. It may become as large as a child's head at term, and may interfere with locomotion, render coition impossible, and oppose a serious obstacle to childbirth.

Diagnosis.—The diagnosis is sometimes difficult, particularly in regard to *inguinal hernia.* The characteristic points are the slow development; the disappearance on pressure if there is communication with the peritoneal cavity, without the feel of any solid body being displaced; the elasticity if the sac is closed; and the translucency. When inflamed, hydrocele may cause vomiting, but not constipation, as does a strangulated hernia.

Treatment.—If the sac communicates with the peritoneal cavity, it may suffice to press it back and let the patient wear a truss until adhesion takes place between the walls. If the cavity is closed,

[1] A comprehensive article on this subject by Wm. C. Wile is found in *Amer. Jour. Obst.*, 1881, vol. xiv. p. 584.

simple aspiration has effected some cures. If that does not suffice, a few drops of tincture of iodine or carbolic acid should be injected after evacuating the fluid, so as to induce adhesive inflammation. During the injection the inguinal canal should be compressed, and the injected fluid should be sucked out again with the syringe. It may become necessary to make an incision, fill the sac with iodoform gauze, and let it heal from the bottom by granulation. The whole sac has also been extirpated. If the contents of the cyst have become purulent or sanious, it must be laid open and thoroughly washed with disinfecting fluids (p. 199).

2. *Hematocele of the Canal of Nuck.*—If hydrocele of the canal of Nuck is rare, hematocele of the same is unique.[1] In the only case known it was of nine years' standing, and dated from childbirth. It formed a tumor of the size of a large hen's egg lying on the descending ramus of the left pubic bone. It was of tense, elastic consistency, without pain or tenderness on pressure, and covered by the skin of the expanded labium majus and minus, which was normal and movable. Its surface was smooth. It was not translucent, could not be diminished by pressure, did not increase during cough, and gave a dull sound on percussion. From its upper end a rather hard pedicle could be traced into the inguinal canal. It contained a thick chocolate-colored mass of the consistency of an ointment. The wall was hard to cut through; the cavity was entirely regular and smooth.

Diagnosis.—It differs from *intestinal hernia* by the dull percussion, the immobility, and the lack of increase during cough; from *hernia of the ovary* by its lack of sensitiveness; from *hydrocele* by being less soft and by not being translucent; from *hematoma of the vulva* by the even surface and its chronic course, whereas hematoma of the vulva is soon absorbed or forms an abscess.

Etiology.—Injury (childbirth) in a person with a canal of Nuck the lower part of which has remained open, may cause an extravasation of blood into that cavity. The irritation of the foreign body causes the thickening of the surrounding membrane.

Treatment.—A long incision was made, the contents turned out, the sac washed, cauterized, and left to heal by granulation.

3. *Hematoma of the round ligament* has likewise, so far, only been found once.[2] It consists in a collection of blood in the interior of the round ligament. When operated on it had been noticed about four years. It formed a tumor in the right inguinal region of the size of a hen's egg, and had been taken for a hernia. The surface was smooth, the consistency tense and elastic, the skin normal and movable over the tumor. From the upper end a pedicle half an inch in diameter could be traced into the inguinal canal. The tumor was

[1] Robert Koppe, *Centralblatt f. Gynäk.*, 1886, vol. x. p. 179.
[2] Sigmund Gottschalk, *Centralblatt f. Gynäk.*, 1887, vol. xi. p. 329.

not diminished by pressure, nor could it be pushed up into the inguinal canal. It gave a dull percussion-sound, and was not translucent. An incision was made through skin, subcutaneous adipose tissue, and fascia, the tumor easily enucleated, the pedicle tied and cut off, and the edges united by interrupted silk sutures, without drainage-tube. The wound healed by first intention. The tumor proved to be a cyst, the wall of which was $\frac{1}{8}$ inch thick. The contents were a dark bloody fluid. Microscopical examination showed that the wall was composed of longitudinal unstriped muscle-fibers, and that the fluid was blood.

Diagnosis.—In regard to *intestinal and ovarian hernia*, *hematoma of the vulva*, and *hydrocele* we refer to what has just been said under Hematocele. From *hematocele of the canal of Nuck* it may, perhaps, be diagnosticated by the sensitiveness and pain found when the tumor is situated in the ligament, and consequently is dragged upon by any movement imparted to the womb.

Treatment.—To what has been already said is only to be added that the pedicle ought to be comprised in the sutures, so as to avoid a displacement backward of the womb.

4. *Fibroma of the Round Ligament.*—The round ligament may become the seat of the formation of a fibrous tumor anywhere in its course from the horn of the uterus through the pelvis and the inguinal canal to the groin and the vulva. The situation outside of the inguinal canal is the most common. The tumor appears first below the external inguinal ring, covering the inner third of Poupart's ligament, and extends by growth usually down into the labium majus, more rarely up through the inguinal canal and along the anterior abdominal wall up to the umbilicus. In the beginning it is more or less movable. It is hard, round, painless, and covered with normal skin. Sometimes a pedicle can be traced to the inguinal canal. It grows slowly, and has been found varying in size from a walnut to a cocoanut.

Diagnosis.—The diagnosis is often difficult. From intestinal and ovarian *hernia* it differs by its hardness, lack of sensitiveness, and lack of increase during cough; from *hydrocele*, by its hardness and lack of pellucidity; from *hematocele*, by its hardness; from *hematoma*, by its chronic course. Chronic inflammation or lympho-sarcoma of an *inguinal gland* forms an immovable tumor, without pedicle, and affects, as a rule, several glands. *Diffuse fibroma of the vulva* begins in the labia majora, and is immovable.

Prognosis.—In itself innocuous, it may become troublesome by its size and situation.

Treatment.—It is easily removed by an incision along its greatest diameter. The tumor is enucleated, the pedicle tied and comprised in the sutures uniting the edges.

CHAPTER IV.

INJURIES.

THE vulva may be the seat of bruises or wounds in consequence of a fall on some sharp object, for instance the back of a chair or the edge of a table, or of blows and kicks. The injury in such cases is mostly found on the labia majora. On account of the sharp edge of the ascending ramus of the ischium and the descending ramus of the pubes, even contact with a blunt object may cause a clear cut.

Coition seldom gives rise to traumatism of the vulva except in cases of rape. The fossa navicularis may, however, be penetrated, resulting in the formation of a permanent vulvo-rectal fistula.[1]

Children and old women are more liable to injury during sexual connection, on account of the lack of development in the former, and senile involution, with loss of elasticity, in the latter.

Parturition is the most frequent cause of injuries to the vulva. Lacerations of the perineum will be considered later. Superficial tears of the labia majora are quite common, but need no special attention if my antiseptic occlusion dressing is used.[2] Sometimes a tear occurs in the vestibule, near the clitoris, which gives rise to dangerous or fatal hemorrhage.[3]

The *symptoms* vary according to the cause and the degree of the violence. If the skin remains unbroken, there are pain, soreness, swelling, discoloration, or perhaps subcutaneous extravasation of blood (*pudendal hematoma*). If the skin is broken, the hemorrhage is often alarming (p. 41).

Treatment.—If the skin is unbroken, the pain is often best relieved by hot-water fomentations, to which may be added tinct. of arnica (ʒj to ℥j). After that lead-and-opium stupes (tinct. opii, liq. plumbi subacetat., āā ʒj; aquæ, ℥viij) may be applied with advantage. If the hematoma is of so large a size that complete resorption is not to be expected, the best treatment is to apply Braun's colpeurynter filled with ice-water in the vagina, and compression on the skin for three or four days. When, then, the danger of hemorrhage is passed, a free incision is made on the internal surface of the labium majus, parallel and near to its lower edge. The blood-clots are turned out, and the cavity washed out with antiseptic fluid, preferably creolin, on account of its hemostatic properties. If any vessels are seen bleeding, they should be tied with catgut, or if there is oozing the surface should be seared with the thermo-cautery. Next the sac

[1] Joseph Price, *Amer. Jour. Obst.*, 1886, vol. xix. p. 832.
[2] Garrigues, *Practical Guide to Antiseptic Midwifery*, Detroit, Michigan, 1886, p. 27.
[3] Mundé, *Amer. Jour. Obst.*, 1875, vol. viii. p. 537.

is packed with iodoform gauze. The dressing should be renewed every day, and the cavity washed out with antiseptic fluid.

If an abscess is formed, the pus should be given a free outlet by incision, and the wound treated antiseptically. A slight tear is dressed with iodoform ointment (p. 173). If there is any hemorrhage, a careful examination should be made for its source. Spurting arteries are twisted or tied. Bleeding surfaces are brought into contact and united by deep sutures. If this does not check the hemorrhage, the wound should be covered with styptic cotton (p. 177), the vagina tamponed (p. 174), and the external genitals covered with compresses or a folded towel tightly fastened with a T-bandage. A fistula is treated by paring the edges and uniting them with silkworm sutures. If the contusion has been considerable enough to cause the death of the tissue, the wound should be kept clean with an antiseptic solution, the dead tissue cut away as soon as feasible after a line of demarkation has formed, and the wound dressed with iodoform ointment.

CHAPTER V.

VULVITIS.

VULVITIS is inflammation of the vulva. It appears under five different forms: the *catarrhal*, the *follicular*, the *phlegmonous*, the *venereal*, and the *diphtheritic* inflammation.

Etiology.—The causes of catarrhal and follicular vulvitis are lack of cleanliness, irritation produced by discharges from the uterus or vagina, or from the bladder if the patient is afflicted with a vesico-vaginal fistula; masturbation, excess in coition, rape; friction produced by physical exercise in fat women; pin-worms that find their way from the anus to the vulva, and ants that creep in from the skin. The scrofulous diathesis predisposes to the disease, especially in children.

The phlegmonous form may result from the catarrhal or be caused by violence. It is mostly found in prostitutes. The venereal is due to infection with one of the three venereal diseases, gonorrhea, chancroid, or syphilis. The diphtheritic occurs in childbed and in grave fevers, such as scarlet fever, small-pox, and typhoid fever.

Symptoms.—The catarrhal vulvitis is either *acute* or *chronic*. The acute is more common. The mucous membrane is red, swollen, and covered with a muco-purulent secretion. There is a sensation of heat and pain, especially smarting during micturition. In the chronic form the mucous membrane is of a less bright red color, and often the seat of abrasions or superficial ulcers. On the denuded places

the papillæ are hypertrophied and bleed easily. Redness and excoriations are often found in the groin and on the inside of the thighs. Intolerable itching drives the patient mad, prevents sleep, and may easily lead to masturbation. Sometimes the glands of the groins swell, the lymphatics leading to them from the excoriated patches becoming inflamed.

In *follicular vulvitis* the seat of the inflammation is the hair-follicles, the sebaceous and sudoriparous glands, and, less frequently, the mucous follicles, the intervening mucous membrane remaining healthy.

FIG. 190.

Follicular Vulvitis (Huguier).

This gives a peculiar appearance to the vulva, the labia majora and minora being studded with small round red protuberances of the size of a millet-seed to a hemp-seed (Fig. 190). Often a hair comes out from the middle, and a drop of pus may be pressed out through the center. As a rule, the inflamed follicle bursts and shrivels up, but exceptionally the disease may end in induration, when small hard nodules remain after the inflammation has run its course.

In *phlegmonous vulvitis* the inflammation extends to the submucous and subcutaneous connective tissue. Deep abscesses and sloughs may form, and end in permanent fistulous tracts if not properly treated.

Gonorrheal vulvitis is much like the simple acute catarrhal, but redness and swelling are more intense, the discharge is more purulent,

and the inflammation has a tendency to implicate the urethra, and is usually accompanied by gonorrheal vaginitis. Micturition causes burning pain, the urethra is swollen and tender, and a drop of thick, creamy pus may be pressed out from it. In children the veins of the labia majora and minora are congested and varicose. The presence of gonococci may be revealed by the microscope. Valuable as these signs are from a diagnostic standpoint, they are not so pathognomonic that, called as expert in a lawsuit, the physician should not be careful not to be too positive in his assertions.[1] (See below under Vaginitis.)

Chancroids and *chancres* will be considered under Venereal Diseases.

Diphtheritic vulvitis is characterized by the formation of a gray diphtheritic membrane on and in the mucous membrane or wounded surfaces. The surrounding parts are edematous, dark red, or otherwise discolored. In this form there is also high fever and general disturbance of the whole system.

Prognosis.—The acute catarrhal and follicular forms are of little importance and short duration. The chronic form may be very protracted. The gonorrheal may extend upward, and is then, as we shall see later, a very dangerous disease. The infective agent has also a tendency to remain in Bartholin's glands, and may thus cause infection long after the woman is seemingly cured. The phlegmonous form is rather serious. The diphtheritic form is only found as part of the most severe diseases. Besides endangering the patient's life, it may lead to more or less complete destruction of important parts, coalescence, and atresia of the genital canal.

Treatment.—If the patient is feverish, she should be kept in bed, have a saline aperient and aconite; in the diphtheritic form large doses of quinine and alcoholic drinks, and in the later stage tinct. ferri chloridi. The genitals should be carefully cleansed, lukewarm or hot sitz-baths given two or three times daily; vaginal injections with carbolized water (p. 168) should be used as often. If there is any irritating discharge from the uterus or the vagina, it is a good plan to keep it away by means of a cotton ball introduced into the vagina. This ball ought to be wrung out of a weak antiseptic fluid. The genitals should be covered with fomentations of the same description, part of which should be applied between the labia. When the acutest stage is over the lead-and-opium wash may be substituted for the carbolic acid, or both combined. In the gonorrheal form hydrargyrum bichloride is preferable for injections and fomentations (p. 168).

Later, the mucous membrane of the vulva may be painted several times daily with Monsel's solution of subsulphate of iron or the liq.

[1] The reader is referred on this point to the timely warning of so high an authority as Robert W. Taylor, *Atlas of Venereal and Skin Diseases*, Philadelphia, 1888, pp. 57–58.

ferri chloridi, each of them diluted with eight parts of glycerin. If this does not effect a cure, the inflamed parts should be painted every other day with a solution of nitrate of silver (gr. x–ʒj) or tinct. iodinii co., diluted with two parts of water. When the mucous membrane has nearly recovered, dry powders, such as oxide of zinc, subnitrate of bismuth, iodoform, or even inert powders, as lycopodium, talcum, or corn starch, often hasten the process. These same powders are used for the accompanying intertrigo.

If the urine is alkaline, benzoate of ammonium or sodium should be given (gr. x–xx every four hours). When, on the other hand, the urine is too acid, bicarbonate of sodium or liquor potassæ are indicated:

℞. Tinct. belladonnæ, ʒij;
Liq. potass., ℥j;
Aquæ, ad ℥iv.
M. Sig. A teaspoonful in a wineglassful of water, *t. i. d.*).

In gonorrheal *urethritis* the urethra should be washed out with hot water or flaxseed tea by means of a reflux catheter. When the inflammation subsides somewhat, carbolized water ($\frac{1}{2}$ per cent.) or corrosive sublimate ($\frac{1}{40}$ gr. to ℥j), or nitrate of silver ($\frac{1}{6}$ gr. to ℥j), or chloral hydrate (gr. x–ʒj), should be used. Pain may be relieved by instillation of cocaine with a glass pipette. If necessary, a few drops of a strong solution of nitrate of silver (gr. x to xxx–ʒj) may be injected or applied with applicator through an endoscope. Antiblennorrhagic medicines (copaiva, cubebs, and sandal oil) should only be given in the subacute or chronic stage. Itching is relieved by chloral hydrate, camphor, or hydrocyanic acid:

℞. Chloral. hydrat., ʒj–ij;
Vaselini albi, ℥ij.

℞. Chlorali hydrat.,
Camphoræ, āā. ʒj;
Vaselini albi, ℥ij.

℞. Acid. hydrocyan. dil., ʒij;
Plumbi acetat., ℈ij;
Glycerini, ℥ij.

℞. Chlorali hydrat.,
Camphoræ, āā. ʒij;
Acidi olici, ℥ij.

When nothing else will help, the whole mucous membrane must be excised.

In the phlegmonous form abscesses should be laid open by free

incisions, washed out with disinfectants, and filled with iodoform gauze.

Parts affected with diphtheritic infiltration should be cauterized with chloride of zinc dissolved in equal parts of distilled water.[1] The healing process should be carefully watched, so as to avoid secondary deformities.

CHAPTER VI.

Inflammation of the Urethral Ducts.

The urethral ducts described on p. 76 may become inflamed. Their mouths are then seen outside of the meatus in consequence of the swelling and prolapse of the mucous membrane. They appear like very small ulcers of a yellowish-gray color, surrounded by a deep-red circle, and a purulent fluid may be pressed out of them. The lower third of the urethra is sometimes swollen. It is exquisitely tender to touch, and causes the patient much discomfort, but micturition is not particularly painful.

Treatment.—The ducts should be washed out by injecting carbolized water or the saturated solution of boracic acid. If a more active treatment is needed, tincture of iodine or a strong solution of nitrate of silver (1 : 4) may be injected, or a fine probe covered with nitrate of silver in substance may be introduced into them. In a recalcitrant case I obtained a cure by introducing a probe and slitting the canals open from the vagina with Paquelin's thermo-cautery (p. 177).

CHAPTER VII.

Gangrene of the Vulva.

The vulva may become gangrenous in consequence of contusion, or overdistension due to edema or extravasated blood, or from the use of a tampon with undiluted liquor ferri chloridi (p. 175). Gangrene may also be caused by inflammation, especially diphtheritic infiltration. It occurs sometimes in eruptive fevers. An idiopathic gangrene identical with noma is found in young children, and is said to be contagious. It begins as a white blister, which soon changes into an ulcer, that takes a diphtheritic aspect and becomes gangrenous. It is a dangerous disease, usually ending in septicemia.

[1] For the details of this treatment I must refer the reader to my other writings: "Puerperal Diphtheria," *Trans. Amer. Gyn. Soc.*, 1885, vol. x. p. 109; "Puerperal Infection," *Amer. Syst. Obst.*, ii. p. 363; *Antiseptic Midwifery*, p. 61.

Treatment.—The affected part should be cauterized with chloride of zinc dissolved in equal parts of distilled water or the thermo-cautery, and covered with iodoform or compresses dipped into a saturated solution of chlorate of potash. Tonics and stimulants should be used freely. As soon as a line of demarkation is formed the dead tissue should be removed.

CHAPTER VIII.

Exanthematous Diseases.

In exanthematous fevers the genitals may be the seat of an eruption like other parts of the body. They may also be attacked by skin diseases, such as furunculosis, erythema, eczema, etc.; but as these diseases offer nothing peculiar in this region, and are treated as in other parts, the reader is referred in regard to them to works on the practice of medicine and skin diseases. Only one exudative skin disease shall be described here, on account of its frequent occurrence and great diagnostic importance—viz. herpes.

Herpes Progenitalis.—Herpes progenitalis is a mild inflammatory affection, consisting of one or more vesicles or groups of vesicles. The eruption may occur without any prodromal symptoms, but in most cases it is preceded by a burning and itching sensation.

First appears a small round red spot. On this the epidermis is soon raised, forming a vesicle of the size of a pin-head to a hemp-seed, filled with clear serum. This ruptures and leaves a shallow ulcer of the size of the vesicle. Its floor is at first of a deep rosy red, with a finely uneven surface and its edges sharply cut as with a punch, and sometimes undermined, but, as a rule, not to the same extent as in chancroid. Sometimes there is so much edema of the labia minora that the eruption is concealed until they are separated. On the skin the vesicle is followed by a scab. The disease lasts from a few days to two weeks, but is apt to return. It may lead to the development of a bubo.

Etiology.—It is due to congestion and inflammation of the genitals and pelvic organs. It is only found in adults, especially in prostitutes. It appears often as a concomitant of menstruation.

Diagnosis.—It may be very like a chancre in the erosive stage, but this has a deeper and duller red, coppery color, and its floor is smooth and shining, without the small granulations found in herpes. Its areola is very slight and of a dark red color, and there is a general absence of inflammation about the lesion. On pressure a chancrous erosion does not yield any fluid, while a herpetic vesicle gives issue to several drops. The history may also offer some help to a

diagnosis, but it is advisable to be a little reserved until we see the course the disease takes.

Treatment.—The parts should be cleansed and all irritation avoided. Milder cases get speedily well when covered with lint soaked in—

℞. Acidi carbol.,	♏xl;
Glycerini,	℥ss;
Aquæ,	ad ℥iv.

The dry powders mentioned above (see Vulvitis, 261) hasten the healing, and the iodoform ointment (p. 173) relieves pain. Persistent neuralgic and burning pains require cauterization with carbolic acid or a strong solution of nitrate of silver (1 : 8), followed by the lead-and-opium wash.[1]

CHAPTER IX.

Trichiasis.

Inversion of the hairs of the labia is a rare condition which causes intense itching. The offending hairs must be removed and their bulbs destroyed by electrolysis.

CHAPTER X.

Pruritus Vulvæ.

Pruritus vulvæ is characterized by an itching sensation on the inner or outer surface of the vulva, sometimes extending up into the vagina or over the lower half of the abdominal wall. It may be *symptomatic* or *idiopathic.* When it is symptomatic it may be a symptom of a disease of the genitals, especially follicular vulvitis, eczema pudendi, or trichiasis, or it may be a *reflex* symptom of disease in other organs, such as hemorrhoids, pin-worms in the rectum, diseases of the kidneys, ureters, bladder, or urethra, congestion of the pelvic organs, etc.

Predisposing causes are pregnancy, menstruation, the menopause, old age, the gouty diathesis, or general nervousness. Sometimes the itching is due to direct irritation by parasites (lice or acarus scabiei), acrid discharges from the vagina or uterus, or urine containing sugar.

In other cases no cause, near or remote, can be found, and then it has been surmised that the disease is located in the nervous centers.

[1] For further details the reader is referred to Robert W. Taylor's *Atlas of Venereal and Skin Diseases*, Philadelphia, 1888, p. 72.

Symptoms.—The chief symptom is an itching that is so violent that it irresistibly drives the patient to scratch herself, a procedure which gives a momentary relief, paid for by increased itching. The scratching produces excoriations and inflammatory conditions, especially eczema, which, again, contribute to the morbid sensation.

In its higher degrees the disease is a very serious one. The patient scratches so that she wears off the hair of the mons Veneris and labia majora; she avoids company; she becomes melancholy and morose; she loses her appetite; her sleep is disturbed; she becomes the victim of an abnormally increased sexual desire or contracts the habit of masturbation; she may finally become insane, succumb to exhaustion, or end her miserable existence by suicide.

The itching may be continuous, but is more frequently interrupted by free intervals of hours and days. It increases by heat, and is, therefore, worse at night, in a warm room, and during physical exertion.

Prognosis.—The prognosis depends on the possibility of removing the cause. If no cause can be found, it is often very obstinate, and sometimes, it would seem, incurable.

Treatment.—First of all, we must try to find and remove the cause. If there are crab-lice among the hairs on the pubes, the hairs should be cut short or shaved off, and the skin smeared with blue ointment or Peruvian balsam, or washed with a strong solution of corrosive sublimate (1 gr. to alcohol and water *āā.* ℥ss), and general warm baths with 2 drachms of the same drug should be given.

If the acarus scabiei is the offender, as a rule a treatment for itch of the whole body will be needed. Locally, beta-naphthol in vaseline (gr. xxv to ℥j) or sulphur ointment should be rubbed in.

Inflammation of the vulva must be treated as described above (p. 260). Eczema is treated with unguent. diachyli. Pin-worms are removed from the rectum by means of extr. sennæ et spigeliæ fl. (℥ss, *t. i. d.*), given by the mouth, and rectal injections of a strong infusion of quassia (ʒij–Oj) or corrosive sublimate (gr. ½ in ℥viij of water). Hemorrhoids, glycosuria, and other diseases causing the pruritus should be treated according to the rules of medical and surgical practice.

The diet is of great importance. Besides the special diet called for by diabetes and gout, alcoholic drinks and spiced food should be avoided. The food should be nourishing, but bland. Milk in large quantities (two or three quarts a day) is to be recommended if it can be digested. If it causes dyspepsia in its natural state, it should be tried boiled, skimmed, and peptonized.

The general treatment should be tonic, sedative, and narcotic. Arsenic and quinine are particularly recommended. Bromide of potassium in large doses (ʒj–ij daily) is often very valuable. Tinct.

cannabis Indica (20 to 40 drops, *t. i. d.*) is preferable to opium. It may be necessary to procure sleep by means of chloralamid, sulphonal, urethane, trional, and the other modern hypnotics.

The local treatment is of the greatest importance. Vaginal injections and affusions of plain hot water, solutions of carbolic acid, bichloride of mercury, or borax should be freely used many times a day. If any irritating discharge dribbles from the vagina, relief is obtained by keeping it back by means of a cotton tampon wrung out of some mild antiseptic solution. The vulva may be covered with fomentations of lead-water with or without opium or the saturated solution of potassium bromide, or painted several times a day with glycerin mixed with chloroform (1 : 8), hydrocyanic acid (p. 261), or morphine (gr. ij or iij to ℥j), or the parts may be painted at longer intervals with a 10 per cent. solution of cocaine in water, a similar solution of carbolic acid, or a strong solution of nitrate of silver (p. 261), followed by cold applications. For base of ointment vaseline is the best. It may be mixed with acetate of lead, chloral, camphor (p. 261), or chloroform (of each ʒj–℥j). The affected part may be rubbed with a menthol stick or solid nitrate of silver. Some claim to have successfully applied the galvanic current.[1] As a last resort, when everything else had failed, the removal of the affected portions of skin or mucous membrane by cutting instruments has effected a cure in several cases.

During pregnancy only the milder of the above-named remedies may be used. Large and frequent vaginal injections must be avoided. A tampon soaked in equal parts of sulphurous acid and glyceratum boracis may be introduced into the vagina. One case is reported in which tobacco-smoking gave relief.

Burning Sensation in the Genitals and the Abdomen.—This affection is probably nearly related to pruritus, but differs from it in the character of the sensation. It is not very rare—in my experience, if anything, more common than its universally recognized sister, and still itself is hardly mentioned anywhere. It seems to be fully as recalcitrant to treatment, if not more so. Applications of compresses soaked in cold water to the abdomen, the above-mentioned vaginal injections, and bromide of potassium internally have given me the best results.

[1] W. Blackwood, *Polyclinic*, Philadelphia, 1885, No. 9, vol. ii. p. 141.

CHAPTER XI.

HYPERESTHESIA OF THE VULVA.

DR. T. G. THOMAS has described, under the name of hyperesthesia, a disease of the vulva that is sufficiently well marked to deserve a special place in the system of gynecological diseases.[1] Although by no means frequent, it is, according to him, not a very rare disease, either. It consists in an excessive sensibility of the nerves supplying the mucous membrane of some part of the vulva.

The slightest friction excites intolerable pain and nervousness; even a cold and unexpected current of air produces discomfort; and any degree of pressure is absolutely intolerable. Sexual intercourse is, therefore, hateful or impossible—a condition elegantly called dyspareunia (p. 120).

The disease appears near or at the menopause; hysteria and despondency predispose to it. Sometimes it is found combined with vulvitis or a painful urethral caruncle, but in other cases no cause can be found. It differs from pruritus by the absence of itching, and from vaginismus by not causing any spasmodic contraction of the vagina.

The *treatment* is unsatisfactory. Even the complete destruction of the mucous membrane of the sensitive area with caustics or its removal with the knife has failed to produce a permanent cure. Sexual intercourse should be absolutely forbidden. If feasible, the patient should be sent away from home to a place offering healthy surroundings and cheerful company. The general treatment should consist in tonics, sea-baths or warm general baths, and massage. The local affection should be treated with hot sitz-baths, injections, and affusions, and calmative, astringent, and derivative applications, as detailed in the preceding chapter.

CHAPTER XII.

TUMORS OF THE VULVA.

1. *Hyperplasia.*—Without containing diseased tissue, parts of the vulva may acquire abnormally large proportions. Thus we have seen that the labia minora in certain races become enormously developed (p. 37), and that in some individuals the clitoris may have the size of the male organ (p. 248).

[1] T. Gaillard Thomas, *A Practical Treatise on the Diseases of Women*, 6th ed., Philadelphia, 1891, p. 150.

2. *Varicose Veins.*—The veins of the vulva, especially of the labia majora, may swell so as to form tumors of considerable size, even that of the fetal head.

This condition is in most cases connected with pregnancy, but may occur independently thereof. It is produced by everything that obstructs the free flow of venous blood from the vulva, such as tumors pressing on the pelvic veins, lifting of heavy burdens, protracted standing, habitual constipation, etc.

The swollen veins form dark blue, nearly black, globular, oval, or serpentine soft swellings, that collapse on pressure, and refill immediately when the pressure is discontinued. They increase during pregnancy, and become smaller after the birth of the child; but often they do not disappear altogether. They cause an uncomfortable sensation of heat and weight, especially during bodily exertion, and sometimes pruritus. They may burst spontaneously, but usually that accident is produced by the passage of the child or by external injury. If the skin holds, a hematoma is formed; if it breaks, a serious, and sometimes fatal, hemorrhage follows (p. 41).

Treatment.—During pregnancy the patient should rest in a recumbent position in the middle of the day, in order to relieve the pressure of the child on the veins of the pelvis. At times even complete rest in bed or on a lounge is indicated. Fomentations with lead-water relieve heat and tension. A pad may be adapted in such a way as to compress the swelling. The patient should be informed of the dangers of hemorrhage, and instructed how to check it by compression till she can get help. When a rupture has taken place and the blood escapes, the hemorrhage should be controlled by means of deep sutures, tamponade of the vagina and vulva (pp. 174–175), combined with pressure on the skin by means of a compress rolled so as to form a hard cylinder placed against the cutaneous surface of the labia majora and retained with a T-bandage.

3. *Hematoma*, or *thrombus*, is a swelling due to extravasation of venous blood in the connective tissue of the vulva. It is most common in the labium majus, and, as a rule, it affects only one side.

Varicose veins predispose to hematoma. The exciting causes are external violence, such as a blow or a fall, and straining, especially during childbirth.

The hematoma may consist in a small swelling of the size of a hazelnut or acquire the dimensions of a fist or a fetal head at term. It is of dark blue or purple color and tender on pressure. The blood may be absorbed or the tumor may become inflamed, suppurate, and even fall a prey to gangrene. When inflammation sets in, swelling, tenderness, and heat increase, the skin takes a brighter purple color, the temperature rises, and symptoms of septicemia may develop. The swelling may oppose a serious obstruction to the passage of the child

or cause retention of urine. It may also burst, causing the dangerous hemorrhage just mentioned. As a complication of delivery it has proved fatal in 20 per cent. of the cases reported.

Treatment.—A small hematoma may be let alone or treated with cold, astringent, or absorbent fomentations (ice-bag, ice-water coil, lead-and-opium wash, arnica). If it is larger than a fist, it should be at once opened with a long incision, the clots turned out, bleeding veins secured by suture or forcipressure (p. 180), and the cavity packed with iodoform gauze or styptic cotton. As soon as pus is formed the hematoma must under all circumstances be opened and thoroughly disinfected.

4. *Papilloma* is a tumor produced by hyperplasia of the papillæ of the skin or mucous membrane, with corresponding development of the blood-vessels and epidermis. It appears on the female genitals in three well-marked forms: *common warts*, *vegetations*, and *mucous patches*.

Warts, generally of round form, more or less pediculated, of the size of a pea or a bean, with a dry, uneven surface of dark brown color, are occasionally found on the skin of the vulva, especially the mons Veneris, as in other parts of the body. They are insignificant, and do not call for any treatment.

Vegetations, also called *venereal warts* or *condylomata acuminata*, stand in special relation to the genitals, male and female. They are often found in patients suffering from gonorrhea, chancroid, or syphilis, especially gonorrhea, but may also be entirely independent of any venereal affection, and are then due to lack of cleanliness. They are most common on the fourchette, at the vaginal entrance, and the labia minora or majora, but may extend through the whole vagina and to the vaginal surface of the vaginal portion of the uterus, the inside of the thighs, and around the anus. On the mucous membrane they are soft; on the skin they are harder. They begin as small erosions, which soon change to pin-head-sized granular papules. After that they grow rapidly, forming sessile or pediculated, club- or cockscomb-shaped protuberances. Their color varies much: some are light gray, others are pink, deep red, or purplish. They vary in size from a hemp-seed to a raspberry, but if neglected the different isolated growths come in contact with one another and may form a tumor as large as the fetal head. Their surface shows always protuberances separated by deep furrows, and they can be separated into smaller cauliflower-like parts springing from a narrow base. They exhale a mucoid secretion of a sickening odor. Even the dry vegetations on the skin are apt to become eroded and secrete such fluid. The acrid secretion may cause vulvitis and vaginitis, and the tumors may mechanically obstruct the meatus urinarius, the vaginal entrance, and the anus, so as to interfere with micturition, coition, defecation,

and childbirth. When they are destroyed new ones are very prone to spring up. In elderly persons they have a tendency to become malignant and change into epithelioma. The secretion, if carried into the eyes, is apt to cause purulent ophthalmia. During childbirth there is the same danger for the eyes of the baby, and besides that the risk of puerperal infection of the mother. The tumors may also become gangrenous, and in that way cause the patient's death.

Diagnosis.—Flat and broad vegetations may sometimes be so like mucous patches that one affection may be mistaken for the other; but with mucous patches we have the history of preceding syphilitic infection and, as a rule, other concomitant symptoms of syphilis. They are few in number, and develop more slowly.

Treatment.—The sooner these tumors are removed the better. If they are small, they may be snipped off with curved scissors or scraped off with the sharp spoon, after which the base should be touched with liq. ferri chloridi or the actual cautery. They may also be destroyed with corrosive-sublimate collodium (ʒss–℥j) or salicylic acid dissolved in collodium (ʒj–℥j), glacial acetic acid, lactic, nitric, or chromic acid, and other caustics. The tincture of Thuya occidentalis is said to be a specific for these growths. They should be constantly moistened with it. In my experience the thermo-cautery has proved the only radical cure even for small vegetations.

If they are of medium size—up to an inch in diameter—they may be tied with a silk or rubber ligature. If they are still larger, the galvano-caustic wire is the best means for their removal.

At the same time, great cleanliness should be inculcated. Vaginal douches with carbolic acid or corrosive sublimate, hot sitz-baths, and hot affusions should be used several times a day. The affected surfaces should be kept dry and separated with antiseptic gauze.

If operation is contraindicated, even large tumors can be made to shrink by covering them with equal parts of calomel and salicylic acid.[1] If these vegetations have invaded the meatus urinarius, care must be taken to use methods that will not cause stricture.

Even during pregnancy vegetations should be removed by some of the above-named means, since they present a double danger for mother and child. Minor operations may be performed with cocaine (1 : 8 or 10); the larger require etherization.

Mucous patches will be considered later.

To papilloma seems also to belong a disease that has been described under the name of *oozing tumor*. It is a very rare disease if it is not simply the same as large flat vegetations. It is said to occur mostly in middle-aged, fat women. It forms a large flat tumor on one or both labia majora, divided with deep fissures, and is characterized by discharging a large amount of an acrid, stinking fluid.

[1] R. W. Taylor, *l. c.*, p. 30.

In a case operated on by Dr. Emmet[1] with knife and sutures the hemorrhage was profuse. It is therefore preferable to remove the mass with the thermo-cautery or galvano-cautery.

5. *Elephantiasis*, or *pachydermia*, is a chronic recurring inflammation of lymph-vessels accompanied by hyperplasia of the connective tissue, the skin, mucous membrane, and epidermis, leading to the formation of large tumors.

Etiology.—Sporadic cases are very rarely found in North America and Europe, but the disease is endemic in the West Indies, the coasts of Central and South America, Africa, and on the islands of the Pacific. It is mostly found in adults, but seems to begin in childhood. The dark races are much more frequently affected than the white. It occurs especially in marshy localities. It is mostly due to the presence of a parasite called *filaria sanguinis* in the blood, in which it is supposed to be introduced through mosquito-bites. It may also be due to primary occlusion of lymphatics and destruction of the lymphatic glands of the groin.

Symptoms.—The endemic form begins with all the symptoms of lymphangitis. The patient is feverish; the affected part becomes swollen and red; the redness may follow the lymphatics or blood-vessels as red streaks, or cover the whole surface as in erysipelas. The inguinal glands become swollen and tender. This acute stage lasts a week or two, subsides slowly, and leaves often the parts in an edematous condition. After that there follows a free interval varying in length from a month to several years, when the same process is repeated, each attack leaving the affected part more swollen and harder, until all pitting ceases and the tissue becomes hard as the rind of ham. The skin has a dark color. The surface may be smooth or rough, covered with warts, the seat of fissures, or, when the tumor is rubbed, ulcerations may form and allow a serous fluid to ooze out. Most frequently the labia majora are the seat of the disease, after them the clitoris, and most rarely the labia minora. The tumors may reach such a size that they hang down to the knees or even to the ankles, and weigh many pounds. They prevent sexual connection, and cause discomfort by their bulk and weight, but they do not affect the general health. They do not become strictly pedunculated, but when they are large the base, however, is somewhat narrower than the middle of the tumor. Exceptionally they may give rise to thrombosis and pyemia. Chyluria is a frequent accompaniment of elephantiasis.

Pathological Anatomy.—The swelling is chiefly situated in the skin and mucous membrane; the lymphatics are dilated and the papillæ enlarged. The underlying subcutaneous connective tissue and the epidermis are also increased in thickness. In the tissue compos-

[1] *L. c.*, p. 603.

ing these tumors are found yellow elastic fibers and deposits of pigment. According to the different consistency of the tumors the tissue contains more or less serum.

Diagnosis.—It differs from diffuse *fibroid* by the history of a feverish beginning or repeated attacks of lymphangitis. The inguinal glands are often affected. Not only the connective tissue, but the skin itself, is thickened. When the tumors are examined microscopically, we find dilated lymph-spaces and yellow elastic fibers.

Prognosis.—The disease never disappears spontaneously, and is only curable in the beginning. Its progress extends over many years. It does not shorten life except in the rare cases of thrombosis and pyemia.

Treatment.—During the acute stage antipyretics and cold applications are used. Change of climate is desirable. In young subjects sulphide of calcium (gr. 1–1½, twice a day) is claimed to have effected a cure in a month or two. Massage and electrolysis may, under similar circumstances, prove useful and may be combined with it. In cases of long standing amputation is the only remedy. This may be performed in different ways:

a. Schroeder's method is to cut from below upward, a small part at a time, and unite the edges by deep sutures before progressing with the operation.

b. Mundé introduced long pins through the base of the tumor, surrounded it with a temporary elastic ligature, cut the tumor off, loosened the ligature, tied bleeding vessels, and united the edges.

c. Silver-wire sutures may be drawn through the base before cutting, the vessels tied with catgut, and the sutures closed.

d. The tumor may be removed with the galvano-caustic wire or the thermo-cautery.

The cutting operations are preferable, since there is good hope of obtaining complete or partial union by first intention.

6. *Fibroma.*—A fibroid or fibroma is a tumor composed of fibrous connective tissue. It occurs in the vulva in two forms—the *diffuse* and the *circumscribed.*

The *etiology* is obscure.

The *diffuse fibroma* is much like elephantiasis in appearance, and the seat is the same; but while in elephantiasis the chief thickening takes place in the skin and the mucous membrane, the fibroma is formed by hyperplasia of the connective tissue, without growth of the skin and mucous membrane. The tumors are more or less irregular, often divided into lobes or shooting-off pedunculated portions. The skin covering them is pink, whitish, or brownish. They have no intrinsic tendency to ulceration, but through friction superficial ulcers may form, and again heal up, leaving cicatrices. These tumors are not sensitive nor the seat of spontaneous pain, except

when they become inflamed. They grow slowly, but may become very large. They do not affect the constitution, but incommode the patient by their size and weight, and are a hindrance to coition, sometimes amounting to complete dyspareunia.

Minute Anatomy.—The microscope shows connective-tissue fibers. with infiltration of round cells surrounding the vessels, but no change in the vessels themselves or the skin, and no yellow elastic fibres; which features distinguish fibroma from elephantiasis.

Treatment.—Amputation is the only remedy, and is carried out as stated under Elephantiasis.

The *circumscribed fibroma* is a rare affection. It is composed of the same tissue as the diffuse form, but soon becomes pedunculated, and hangs down from the labium majus.

The *treatment* consists in cutting the pedicle near its base, tying with catgut the artery that nourishes it, and uniting the edges with sutures.

7. *Myoma, Myxoma, Lipoma.*—Tumors entirely similar to fibromas may be formed of unstriped muscle-fibers (*myoma*); of a delicate fibrous reticulum, the meshes of which contain a homogeneous basis-substance and cells (*myxoma*); or of adipose tissue (*lipoma*). Quite commonly the different kinds of tissue are intermingled with more or less fibrous tissue, forming *myo-fibromas, myxo-fibromas,*[1] etc. They are all benign, but the only treatment is amputation.[2]

8. *Enchondroma of the Clitoris.*[3]—A single case has been reported of a pedunculated tumor, of the size of a fist, attached to the clit-

[1] On account of the great rarity of these tumors, I may be pardoned for stating that on March 12, 1884, I removed one from a Swedish cook, æt. 34: it had been first noticed nine years before. It hung from the middle of the left labium majus, to which it was attached by a pedicle of the length and thickness of a finger. The tumor itself was pear-shaped, measured 8 centimeters in length, 7 from side to side, and 4 in thickness. It had the color of normal skin, and was covered with peeling-off epidermis. At the lower end was seen an irregular slough of the size of a fifty-cent piece, surrounded by a suppurating line of demarkation which exhaled an offensive odor. In the pedicle was felt a pulsating artery of the size of the umbilical, and in it and near it on the labium majus were varicose veins. The tumor did not cause any pain, nor was it tender on pressure. I put a clamp on the base of the pedicle, formed two small flaps, tied the artery, and united the edges with catgut. It healed by first intention. When cut open a moderate amount of blood flowed from the tumor; the surface was smooth, the skin not thickened, but so intimately connected with the tumor that it could not be dissected off. Microscopical examination proved it to be a myxo-fibroma. I have, in St. Mark's Hospital, seen a case almost entirely like the preceding one.

[2] Geo. M. Tuttle of New York has removed a large *fibroma molluscum* from the labium majus. It measured 17½ in. in circumference; had a thick capsule, in cutting through which the appearance was strikingly like gut: thin, translucent, gaseous in feeling, and very resonant on percussion (*Amer. Jour. Obstet.*, June, 1891, vol. xxiv. p. 715).

[3] *Tumors of the clitoris* are extremely rare. Grace Peckham has described a cyst as large as a hen's egg, and collected twenty cases of different kinds of tumors of this organ (*Amer. Jour. Obstet.*, Oct., 1891, vol. xxiv. pp. 1153–1172).

oris, and composed of a cartilaginous mass, which in some places was softened, in others hard as a stone, probably through calcareous deposit. No microscopical examination seems to have been made. The treatment was, of course, removal of the tumor.

9. *Horn of the clitoris* is likewise a gynecological curiosity. A case is reported of a horny mass, in size and shape like the talon of a tiger, growing under the prepuce of the clitoris. Such a growth might wound the male during coition, and ought to be removed with the thermo- or galvano-cautery.

10. *Urethral Caruncle, Angioma, and Neuroma of the Vulva.*—The names *urethral caruncle, vascular tumor of the urethra, painful tumor of the urethra,* and *irritable vascular excrescence of the urethra* have been applied to a kind of growths found at or near the meatus urinarius, and characterized by their great vascularity. It is a quite common affection, and is often seen accidentally in patients examined for other complaints, without causing any symptoms. On the other hand, it may cause great pain, especially during micturition, and be so tender to the touch that sexual intercourse is rendered hateful or impossible. Even the friction of the clothes may suffice to start the pain. Sometimes there is only one such tumor, in other cases many. They are usually found just at the meatus, but may also develop more or less high up in the urethra. They are sessile or pediculated, of bright red color, usually sensitive, and apt to bleed after small injuries. They vary in size from a hemp-seed to a cherry. Even when thoroughly destroyed they are apt to recur or new ones to spring up in the neighborhood of the first.

Microscopical examination has shown that these tumors are full of dilated capillaries and nerve-fibers, with hyperplasia of the papillæ and connective tissue. Anatomically speaking, they are, therefore, angiomas and sometimes neuromas. The different composition accounts probably for the great difference in symptoms.

Vascular tumors (angiomata) and nervous tumors (neuromata) form in rare cases small tumors on other parts of the vulva and the perineum.

Diagnosis.—The bright red color, the great sensitiveness (when found), their insertion at the meatus, and their even, globular surface, make them easily distinguishable from *vegetations.*

Treatment.—The only thing that affords help is the removal of the tumor. If there is a thin pedicle, it needs only to be twisted off with a pressure-forceps. Small sessile tumors may be destroyed with chromic or nitric acid, neutralizing the superfluous acid by bathing the parts with a solution of bicarbonate of soda. Cocaine (10 per cent.) may be used for local anesthesia. Larger sessile tumors are best removed with the thermo- or galvano-cautery under general anesthesia. In the interior of the urethra they must be exposed with

a urethral speculum (p. 148), especially Jackson's, and cut or scraped off or destroyed with caustics. The latter should even be used on the base after cutting or scraping, in order to prevent recurrence.

11. *Cysts.*—Except those situated in the vulvo-vaginal glands, which will be considered later, cysts of the vulva are rather rare. They are single or multiple, and range in size from that of a pea to that of a fetal head. They differ much in origin. Some are *dermoid cysts*, with the characteristic hairs, bones, and teeth in the interior. Others are *atheromas*, formed by occlusion of a sebaceous follicle, and contain a pultaceous mass. Most of them are filled with a serous fluid. Some seem to be due to an old extravasation of blood or to expansion of lymphatic vessels.

If small, they do not give rise to any symptoms, but if they acquire large proportions, they may incommode the patient by their weight and size, and cause dyspareunia. If they become inflamed, they are painful, and are accompanied by fever and other systemic disturbances.

Treatment.—As they are intimately connected with the surrounding tissue, it may be difficult to enucleate them. If so, a part of the wall is excised, the interior cauterized, packed with iodoform gauze, and left to heal by granulation.

12. *Cancer.*—Compared with the uterus, the vulva is rarely the starting-point of cancer. Different kinds are found here—*epithelioma*, *medullary carcinoma*, *atrophic carcinoma* (or *scirrhus*), and *sarcoma*, with its variety *melano-sarcoma*, the cells of which contain brown pigment. They are all malignant, tending toward local destruction, undermining the constitution, and ending in death.

Epithelioma (Fig. 191) is in so far less malignant than the other varieties of cancer as its course is slower.

Etiology.—Cancer appears mostly after the fortieth year, but has even been found in childhood. Psoriasis of the parts has a tendency to become cancerous. Otherwise the cause is unknown.

Symptoms.—The most common starting-point is the sulcus between the labium majus and minus or the lower edge of the labium majus, more rarely the clitoris or the meatus urinarius. It begins as small nodules in the skin or mucous membrane, covered with an increased mass of epithelium, which often causes distressing itching. Later, these nodules become excoriated, secrete a thin, malodorous fluid, form ulcerations that become confluent, and spread over the neighboring parts. Soon the inguinal glands become swollen. The ulcers are irregular, have discolored margins, an elevated floor, and are often covered with a new growth of cancerous tissue, which gives them the appearance of a raspberry. They have no tendency to enter the vagina. They are liable to bleed and cause pain. Sometimes the surroundings become hard as a board, and the vaginal and urethral openings may become obstructed.

Prognosis.—The patients usually succumb at the end of two or three years.

Diagnosis—*Lupus* heals in one place while destruction extends in another, is not so hard, causes slight pain, and is inodorous. The

FIG. 191.

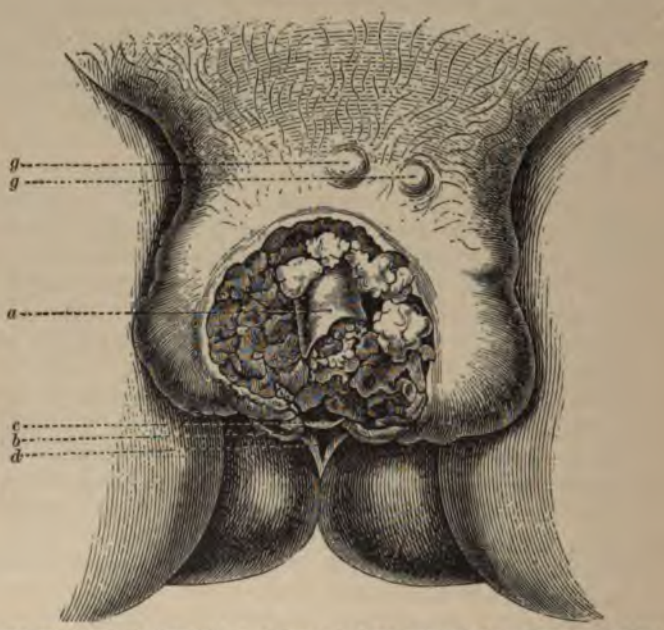

Epithelioma of Vulva (P. Zweifel): *a*, clitoris; *b*, fossa navicularis; *c*, vaginal entrance; *d*, torn perineum; *gg*, cancerous nodules in the skin.

inguinal glands swell late or not at all. The general health remains good. *Chancroid* is not indurated, has sharply-cut, perpendicular edges, and the inguinal glands are implicated much sooner. *Chancre* presents a surface much like that of the excoriated cancer nodule, and has the indurated floor, but the history, the early appearance of adenitis, and the development of other syphilitic symptoms will soon clear up the diagnosis. *Mucous patches*, even if excoriated, do not form destructive ulcers, and disappear soon under local and general treatment.

Treatment.—The nodules and ulcers ought to be eradicated at once. If possible, it should be done with knife and scissors, and the edges united by deep sutures, which allows of union by first intention; otherwise the thermo- or galvano-cautery is used. If the urethra is implicated, as much of it as feasible should be left, in order not to

interfere with the retentive power. If the inguinal glands are affected, they must be enucleated, but even if they are removed entirely, the disease cannot be arrested permanently.

13. *Lupus, Esthiomène* (Huguier); *Chronic Inflammation, Infiltration, and Ulceration* (R. W. Taylor).—The doubtful position of lupus of the vulva in the system of gynecological diseases necessitates an exception from the rule followed in this work not to enter into historical developments. In 1849, Huguier, a French physician, described a disease of the vulvo-anal region under the name of *esthiomène*, which was claimed to be identical with lupus as found especially on the face. The name "lupus" has prevailed, and a certain number of cases have been reported in different countries.[1]

The *pathology* of lupus itself is not yet settled, and so much the less can we decide whether the disease attacks the external female genitals or not. According to Koch's great authority, lupus is simply tuberculosis of the skin, and only that affection which is caused by the presence of his bacillus tuberculosis deserves the name; but this microbe has so far been looked for in vain in lupus vulvæ. Others claim that an infiltration with small round cells, clustering together in nodules, especially around the capillary vessels of the skin, or a diffuse infiltration of the papillary layer or around the glands and hair-follicles of the skin, constitutes lupus. Still others lay particular stress on the presence of giant cells in the clusters of small round cells. Others, again, contend that all this is not characteristic of lupus, but may be found in any inflammation with formation of granulation tissue and proliferation of the cells of the connective tissue.[2] R. W. Taylor[3] denies altogether the existence of lupus in the female genitals. Based on his large experience in Charity Hospital, he includes all the inflammations and infiltrations of the vulva of non-malignant origin in the following categories:

1. Small hyperplasiæ, caruncles, and papillary growths;
2. Large hyperplasiæ.
3. Hyperplasia resulting from acute and chronic chancroids;
4. Indurating edema of syphilis;
5. Hyperplasia resulting from chronic ulcers, so-called chancroids, in intermediary and old syphilis;
6. Hyperplasia in old syphilitics, presenting no specific character and occurring soon or long after the period of gummy infiltration, in some cases being coexistent with specific lesions elsewhere.

The cases of formation of tumors, combined with ulceration, con-

[1] Grace Peckham, in an excellent paper fortified by microscopical examinations by H. C. Coe (*Amer. Jour. Obst.*, 1887, vol. xx. p. 785), has collected 48 cases, of which she eliminates some as tubercular, carcinomatous, or not ulcerative, and retains 33, inclusive of her own.

[2] *Coe, l. c.*, Ira Van Gieson in R. W. Taylor's paper.

[3] R. W. Taylor, *N. Y. Med. Jour.*, Jan. 4, 1890.

stituting the condition commonly called lupus vulvæ, that have come under my own observation, were all developed on a foundation of recent or old syphilis.

What has been called lupus vulvæ (Fig. 192) consists in ulcerative lesions of the vulva characterized by their slow development,

Fig. 192.

Lupus of Vulva (Häberlin).

absence of pain, a violaceous color, thickening, induration, and formation of detached tumors. Hyperplasia and destruction go hand in hand, but the hyperplastic process preponderates. The deformity extends often to the perineum and the anus. The inguinal glands may become swollen, but are oftener not affected. The general health stays good for years, and those who are not cured succumb usually to constriction of the intestine and peritonitis. Locally, great destruction takes place. Fistulous tracts may burrow into the labia

and around the rectum, and fistulæ may open into the urethra, the bladder, or the rectum. Fortunately, this destructive hyperplastic affection of the vulva is a rare disease.

Etiology.—Those who do not look upon the ulcerative hyperplasia of the vulva as a disease *sui generis*, attribute it to the large vascular and nervous supply of the genitals, to the injuries they are frequently exposed to, to their dependent position between the thighs, to lack of cleanliness and care, and the irritation caused by uterine or vaginal discharges.

Diagnosis.—*Epithelioma* is usually more localized, of much greater density—even to stoniness—is productive of a large warty or papillamatous and ulcerated surface, and is very soon accompanied by enlargement of the inguinal lymphatic glands. The ulcerations of epithelioma are upon the surface, while those in so-called lupus are mostly found in interstices, fissures, and at the base of tumors. Epithelioma gives rise to lancinating pain; lupus is painless or causes only smarting or pruritus, especially after micturition. The discharge that emanates from the ulcers in lupus has little or no odor. An ulcerated part may heal spontaneously or in consequence of treatment, but the cicatrice is liable to be affected by a new growth of lupus. The microscope settles the question with certainty by showing the epithelioma to contain cancer-nests of concentrically arranged cells of the epithelial type.

Prognosis.—We have already stated that the disease is a very tedious one, extending over years. It does not in itself undermine the constitution, but may lead to intestinal obstruction and peritonitis or general exhaustion. In patients over forty any vulvar tumor, even a caruncle or a papilloma, may degenerate and become cancerous. If not checked, the disease may cause great destruction, and give rise to much annoyance by perforating the partitions between the different hollow pelvic viscera and the external genitals.

Treatment.—On account of the dangers lurking in the background treatment ought to be quite active. The indication is to remove tumors and heal ulcers. Simon's sharp spoon, strong caustics—*e. g.* nitric acid, the thermo-cautery, the galvano-cautery, the galvano-caustic wire—may all be used to advantage, but, if possible, it is preferable to cut away all diseased tissue and unite the edges with sutures. Fistulous tracts may be laid open by means of the elastic ligature. It goes without saying that the utmost cleanliness should be practised by means of baths, fomentations, and injections. Often a tonic treatment with iron, quinine, cod-liver oil, etc., or local or general antisyphilitic treatment, may be called for in combination with the mechanical local treatment.

CHAPTER XIII.

Tuberculosis.

Tuberculosis of the vulva is an exceedingly rare affection; which is strange, since one would think that occasions of direct inoculation, either from the same or another individual, by means of fingers, handkerchiefs, towels, or the sexual act, would present themselves frequently. But the fact is that the more we approach the surface of the body the rarer becomes tuberculosis in the genital system.

It forms ulcers with sharp edges, sinuous contour, and a depressed grayish-yellow bottom covered with a cheesy detritus. Around the ulcers are often found small opaque, yellow nodules. In the discharge of the ulcers and in the tissue forming them and the nodules are found tubercle bacilli. In the mucous membrane are found clusters of polygonal cells surrounded by a zone of small round cells, and containing giant cells, in the interior of which may be found tubercle bacilli. As a rule, similar affections will be found in other parts of the genitals and in the lungs.

Treatment.—The general treatment is the same as for tuberculosis in other parts—nutritious diet, tonics, sunshine, and fresh air. The local treatment consists in application of tincture of iodine or iodoform. If this does not suffice to eradicate the disease, removal with the knife or destruction with caustics or cautery is indicated in the early stages. If the patient is far gone, more palliative treatment with the curette and iodoform or aristol is all that should be attempted.

CHAPTER XIV.

Progressive Atrophy of the Nymphæ (L. Tait), Kraurosis Vulvæ (Breisky).

At or after the menopause, and quite exceptionally in younger years, is sometimes found a peculiar atrophy of the mucous membrane of the inner side of the labia minora. It begins as small red spots, depressed under the level of the surrounding mucous membrane, tender and prone to bleed, transitory or spreading. They may disappear in one place and reappear in another, or spread serpiginously. Later, the mucous membrane contracts, so as to cause considerable coarctation of the vestibule. The stenosis may be so great that hardly a finger can be introduced into the vagina. Coition becomes painful, and childbirth is accompanied by tears of the tissues. When the disease is fully developed, the labia minora seem to be absent. The

mucous membrane appears dry, smooth, and cicatricial. Sometimes there is a slight yellow discharge. In many cases itching or burning is complained of.

The *cause* of the disease is unknown. Its *course* is very slow.

Pathological Anatomy.—Microscopical examination of the red spots shows dilated capillaries, with thinned walls, and nerve-fibers. All over the affected part of the mucous membrane the rete mucosum is thin, so that in many places the horny epidermis-cells lie directly on the papillæ. These are of uneven length, mostly short; the papillary body is composed of straight fibers like a cicatrice, and the sebaceous and sudoriferous glands disappear.

Treatment.—Kraurosis vulvæ is a very intractable disease. Cocaine is said to increase the sufferings. Applications of strong carbolic acid and a pledget steeped in a saturated solution of acetate of lead are recommended. A cure has been obtained by cutting the affected part of the mucous membrane away and uniting by sutures. It may also be destroyed with the thermo- or galvano-cautery.

CHAPTER XV.

Diseases of the Vulvo-vaginal Glands.

The vulvo-vaginal glands may be the seat of *catarrh*, *cystic degeneration* and *abscess*.

1. *Catarrh* of the gland is rare. It is characterized by hypersecretion of mucus and redness of the mucous membrane surrounding the opening. The duct may become dilated, so that a uterine sound may be passed through it, or it may become closed, and then a retention cyst is formed. Sometimes the accumulated secretion may be thrown off in paroxysms, constituting a kind of nocturnal emission.

The *treatment* is not satisfactory. The duct should be dilated with probes, and astringent antiseptic fluids injected. On account of the emissions, it has been recommended to extirpate the glands.

2. *Cysts.*—There may be a superficial or a deep cyst. The former is supposed to be formed by the duct. It forms a small round tumor immediately under the mucous membrane, just outside the vaginal entrance. It may vary in size from that of a hazelnut to that of a hen's egg. The deep cyst is situated in the gland itself, and may be unilocular or multilocular. It forms a large tumor which is situated in the posterior part of the labium majus. Both form well-defined globular or oval, elastic tumors. The contents are ordinarily like the raw white of an egg, but may be chocolate-colored from admixed blood or purulent when inflammation has taken place. As a rule, the duct is closed, but by increased pressure it sometimes opens again. If

not inflamed, these cysts are indolent, but they may cause some discomfort by their size and be a hindrance during sexual intercourse.

The most common cause is gonorrheal infection.

Diagnosis.—*Hydrocele* is situated more forward, below the external inguinal ring. The same applies to anterior *labial hernia*. *Hernia of the ovary* is harder, and pressure on it causes a peculiar sickening feeling. *Posterior labial hernia* can be replaced through the vagina. *Vulvar abscess* has less distinct limits, is more tender, and the skin is red. *Abscess of the gland* is tender, hot, red, and accompanied by fever.

Treatment.—Part of the contents may be drawn out with a hypodermic syringe, and replaced by an injection of chloride of zinc (1 to 10). The contents may be withdrawn entirely, and an injection made with pure tincture of iodine or a 5 per cent. solution of carbolic acid. The anterior wall may be cut off, the cavity washed out with a solution of bichloride of mercury, and packed with iodoform gauze, which has to be renewed every few days till the cavity is filled by granulations. Finally, the whole gland may be extirpated, and union by first intention attempted by means of sutures. It may be advisable to use tier-sutures of catgut (p. 213). Pozzi[1] facilitates the extirpation by emptying the cyst with a hydrocele trocar, and injecting it with spermaceti molten at a low temperature and hardened after injection by the application of ice. Combined with injection of cocaine, the cold serves as an anesthetic.

3. *Abscess.*—With or without preliminary formation of a cyst the gland may suppurate and form an abscess. The left gland is more frequently affected. The process is accompanied by the usual signs of inflammation—pain, swelling, redness, heat, and considerable systemic disturbance. The inguinal glands are commonly implicated. If left to Nature's sole efforts, it breaks on the inside of the labium majus in one or more places, and often fistulous tracks remain. There is in many women a tendency to repetition of such abscesses. The pus has the same offensive odor as abscesses in the ischio-rectal fossa or near the fauces. Gonococci have been found in the pus-cells.

The abscesses may leave a *chronic suppuration* of the gland, or such a condition may develop without abscess. There is then little swelling and tenderness, but a continual discharge of a purulent fluid through the duct of the gland. This suppuration is perhaps always brought on by gonorrhea, and continually gives rise to new infection.

Diagnosis.—*Furuncles* are situated in the skin. *Phlegmonous vulvitis* has not the distinct limits and the peculiar situation of the abscess of the gland. A *stercoral abscess* originates nearer the anus.

Treatment.—The abscess must be laid open by a long incision on the

[1] Samuel Pozzi, "Traité de Gynécologie clinique et opératoire," Paris, 1890, p. 1032.

inner side of the labium majus, disinfected, and packed with iodoform gauze. The opening may conveniently be made with Paquelin's cautery. If there is frequent recurrence of the formation of such abscesses or a chronic suppuration, it is best to extirpate the gland *in toto*. It is not worth while trying primary union. It rarely succeeds, and it is better to pack the wound with iodoform gauze. The extirpation of the gland should be done at a time when the surrounding tissue is not inflamed. In using the knife, it should be remembered that the gland lies close up to the vulvo-vaginal bulb, only separated from it by a thin fascia. Wounding the bulb might give rise to troublesome hemorrhage.

CHAPTER XVI.

Venereal Diseases.

Venereal diseases form so great a part of the affections that come under the observation of the gynecologist, and are so often the cause of others treated by him, that a brief résumé of the most common features of these diseases seems desirable in a work of this kind.

1. *Gonorrhea.*—We have already spoken of the gonorrheal vulvitis (p. 259). It has so great a tendency to implicate the urethra that the presence or absence of urethritis has a certain diagnostic importance. It enters often the duct of the vulvo-vaginal gland, and may cause catarrh, cyst, abscess, or chronic inflammation of the gland. In most cases the inflammation spreads up the vagina to the vaginal portion of the uterus. Fortunately, it generally stops here, but sometimes it invades the cavity of the uterus, causing purulent endometritis; attacks the lining membrane of the tube, producing salpingitis and pyosalpinx; and reaches finally the ovary and the peritoneal cavity, giving rise to oöphoritis and peritonitis—conditions that may make the patient an invalid for life or necessitate capital operations.

It will, therefore, be seen that a gonorrhea in the female is a much more serious disease than the corresponding affection in the male.

If limited to easily accessible parts, the disease may be cured in a few weeks; but if it invades deeper parts, especially the vulvo-vaginal glands or the tubes, it may become chronic and persist indefinitely until the focus of infection is removed.

In regard to *treatment* of the external genitals, sufficient has been said in speaking of vulvitis (p. 260) and the diseases of the vulvo-vaginal glands. As to that of the internal genitals, the reader is referred to later chapters, where the diseases of the uterus, tubes, and ovaries are discussed.

2. *Chancroid.*—*Chancroid*, or *soft chancre*, is frequently found on

the vulva and surrounding parts of the skin, while it is rare on the walls of the vagina, but appears more frequently on the vaginal portion of the uterus.

Whether inoculation takes place at once in several places, or that from the first affected part the poison is carried to other points, as a matter of fact chancroids are commonly multiple in women. A chancroid is a contagious, inflammatory, destructive ulcer. On the mucous membrane it begins as a minute yellow spot surrounded by a red ring. Soon the epithelium over the spot is lifted so as to form a pustule, and is then carried off, leaving an ulcer. On the skin the ulcer may form without the intervention of a pustule. The ulcer is usually round or oval, but may become irregular by extension or the confluence of several single ulcers. The edges are cut perpendicularly, minutely jagged, and more or less undermined. The ulcer is surrounded by a red halo or areola. The floor is uneven and covered with a yellow film of débris. The secretion is in the beginning rather abundant, and has a peculiar, very penetrant, and nauseating odor. It is thinner than that of gonorrhea, and has a brownish color from admixed blood. Under the microscope are seen pus-corpuscles, red blood-corpuscles, and detritus, or broken-down tissue.

If properly treated, chancroids heal in a few weeks. If neglected, they persist for many months, go on forming new ulcers indefinitely, and may cause great destruction, and even, in rare cases, become fatal.

Complications are less common than in the male. It is even rare to see an inguinal gland become inflamed and form an abscess. Occasionally, however, in unhealthy and weak subjects *phagedena* may set in, and extend far over the nates and the abdominal wall.

Peculiar to women is what is called the *chronic chancroid*. It begins as an acute chancroid, but loses its infecting power, and causes often hyperplasia of the surrounding parts. (See Lupus, p. 277.) It is entertained by lack of cleanliness, gonorrheal and leucorrheal discharges, and drink. The term is even used in speaking of "any good-sized intractable ulcer" of the vulva, although there is no proof that it began as a typical acute chancroid.[1] For years women affected with such ulcers and hyperplastic formations may feel well, but in the course of time the ulcers may perforate the urethra, the bladder, and the rectum, or burrow far away under the skin, forming large cavities, which may open by fistulous tracts about the buttocks or the thighs. Hemorrhages of greater or less severity may take place, or erysipelas start from the genitals. In the course of years such women may fall a prey to pulmonary phthisis or succumb to kidney and liver complaints. Some are subject to chronic diarrhea and dysentery, or are finally carried off by pyemic infection.

Treatment.—The acute chancroid should be destroyed with undi-

[1] R. W. Taylor, *N. Y. Med. Jour.*, Jan. 4, 1890.

luted carbolic acid, nitric acid, or Paquelin's thermo-cautery, under local anesthesia with cocaine. The affected parts must be kept from contact with others by covering them with pieces of absorbent lint or pledgets of absorbent cotton dipped in some mild solution—*e. g.*,

℞.	Acidi carbolici,	♏xx to xl;
	Glycerini,	℥ss;
	Aquæ,	ad ℥iv,

or smeared with the iodoform-Peruvian-balsam ointment (p. 173). Vaginal injection with bicarbonate of soda or borax, followed by corrosive sublimate (1 : 5000), should be used several times daily. The substance that makes the ulcers granulate fastest after cauterization is iodoform, which is powdered on them daily.

As a colorless and odorless substance, salicylic acid mixed with 4 or 8 parts of subnitrate of bismuth is often preferred, and may answer a good purpose. When granulation is started, it may be hastened by dressing with sol. argenti nitrat. (gr. j–℥iv), liq. sodii chlorinat. (℥ij–℥iv), sol. acidi borici satur., or vinum aromat. diluted with 4 parts of water.

If a chancroid becomes phagedenic, the constitution of the patient must be improved with nourishing diet, stimulants, and tonics. The unhealthy tissue may be removed with the curette, or by touching it with nitric acid, bromine-glycerin (1 : 3), or Paquelin's cautery. After that the patient should use hot sitz-baths (98°–102° F.) from eight to twelve hours daily.

Bubos are painted with tincture of iodine. If they suppurate, they must be opened in their full length, washed out with disinfectants, packed with iodoform gauze, covered with a compress of the same material, and over that a peat-bag or a layer of moss impregnated with corrosive sublimate or a thick layer of plain cotton-wool. Pressure by means of a spica promotes recovery in a marked degree. This dressing is changed daily.

The curette may be used to remove broken-down glandular tissue. When the cavity granulates, the iodoform ointment or the pure Peruvian balsam is used for dressing. An occasional painting with nitrate-of-silver solution (gr. x or xx to ℥j) hastens the process of healing. Pure boracic acid is also excellent for dressing.

3. *Syphilis.*—The initial lesion of syphilis, the *hard chancre*, is often not to be found on the genitals of women. The cause of this is twofold: First, the lesion by which inoculation of the syphilitic virus takes place is much more frequently than in man situated on other parts of the body, especially the breast and the lips. This is so in 25 per cent. of all cases. Secondly, the characteristic induration of the true infecting chancre is often missing. The syphilitic neoplasm is there, but the new-formed cells are so few in number or so

loosely patched together that the characteristic sclerosis is not developed. When, furthermore, we take into consideration that the female genitals, on account of their shape, are much less open to inspection, even to the patient herself, and that the initial lesion may heal without leaving any visible cicatrix, it will be understood that sometimes it is entirely overlooked, and that secondary and tertiary symptoms may appear although there is no history of any sores on the genitals or elsewhere, and no evidence can be found of their previous existence.

The first period of incubation—that is, the time elapsing between the infection and the appearance of the hard chancre—varies in length from ten to seventy days. The *second period of incubation*—that is to say, the time from the appearance of the chancre to that of general or constitutional symptoms of syphilis—occupies from forty to seventy days. The first and second periods of incubation together commonly last from sixty to ninety days. During the second period of incubation the primary lesion acquires greater development and the inguinal glands become swollen. This happens from five to ten days after the appearance of the chancre.

The syphilitic poison may come from a hard chancre, from secondary syphilitic manifestations, especially mucous patches, or be inoculated with blood or lymph.

Any part of the vulva and its surroundings may be the seat of the initial lesion. Most commonly it is found on the labia majora. It is sometimes developed on the cervix uteri, but very rarely on the walls of the vagina.

It begins as a superficial, flat, reddish erosion, which soon forms a round or oval flat ulcer of dark red or grayish color, with smooth floor, sparse serous secretion, and sometimes a more or less hard base. Often an infection with pyogenic microbes takes place simultaneously with the introduction of the syphilitic virus. Then the secretion of the ulcer becomes more purulent and the floor shows local gangrene. Exceptionally, a syphilitic lesion may become phagedenic. If a double infection with syphilitic virus and that from a chancroid takes place simultaneously, the chancroid is first developed, and changes in the course of time its appearance, so as to form a syphilitic chancre (*mixed chancre*).

The primary lesion is commonly single, but may be multiple and may be combined with soft chancres. It stays a variable length of time—even several months—but, as a rule, heals readily, and may disappear without leaving any trace.

The inguinal glands form a cluster of indolent swellings. But where there is a suppurating ulcer, there may also occur inflammation and abscess of the inguinal glands.

Diagnosis.—Since the characteristic induration is often absent, the diagnosis of the primary lesion becomes more difficult in women than

in men. The following points[1] may occasionally be found useful in making a differential diagnosis: In *herpes progenitalis* the inguinal glands are not affected; the base is soft; the contour is polycyclic—that is to say, composed of regular segments of small circles that have been blended together; the development is more limited, and the excoriation heals rapidly; the affection itches; and, as a rule, the erosions are multiple. *Chancroid* is nearly always multiple. It forms a deep ulcer of yellowish red color, with perpendicular, undermined edges, uneven, worm-eaten floor, soft base, and abundant purulent secretion; the pus, when inoculated on the patient, forms another chancroid; the inguinal glands are not swollen or form an inflammatory bubo which may produce an abscess with simple or chancroidal pus.

Treatment.—The primary lesion being a symptom of an infection that already has taken place, cauterization is useless, and objectionable on account of the inflammation it brings about in the circumference. The genitals should be kept clean and the ulcer dressed with absorbent lint or cotton soaked in bichloride-of-mercury solution (1 : 1000 or 2000) or one of the other solutions mentioned above in speaking of chancroid, the dressing to be changed every two hours. If the ulcer suppurates or is the seat of molecular disintegration, it should be dusted with iodoform or equal parts of calomel and bismuth, or dressed with the lotio hydrargyri flava containing corrosive sublimate, or lotio hydrargyri nigra, made with calomel. In cases of considerable induration blue ointment may be rubbed on the seat of the swelling and applied to it spread on lint.

If the sore is covered with a pultaceous mass, cauterization with carbolic acid, nitric acid, or chloride of zinc, dissolved in equal parts of distilled water is indicated. In regard to phagedena the treatment is the same as described under Chancroid, combined with general antisyphilitic treatment.

Secondary Syphilis.—The vulva is the seat of predilection of *mucous patches* in women. In the vagina they are exceedingly rare, but appear more frequently on the cervical portion of the uterus. They are often found symmetrically on both sides of the vulva, not on account of auto-inoculation, but because the irritation is the same. They form round or oval spots, with a tendency to coalesce. They are a little elevated above the mucous membrane, and have well-defined steep borders. The color is rosy or grayish red. They have a somewhat granular surface, and secrete a malodorous serous fluid. They are quite amenable to treatment, but may, if neglected, form large cauliflower-shaped tumors like vegetations, and may, like them, become gangrenous. On the vaginal portion mucous patches appear as

[1] A. Fournier, *Leçons sur la Syphilis étudiée particulièrement chez la Femme*, Paris, 1873, pp. 261, 281.

small red erosions, or, more rarely, as superficial ulcers. Combined with general mercurial treatment, mild cauterization with nitrate of silver makes mucous patches soon shrivel and disappear, without leaving any cicatrix.

Tertiary Syphilis.—Gummous nodes are not rare in the labia majora. They form first deep-seated globular tumors, which may break and leave ulcers. These latter may be difficult to diagnosticate from other ulcers in the same locality, but are distinguished from them by being rapidly healed by the internal use of potassium iodide. At the same time, the usual precautions in regard to cleanliness and protection that have been detailed above should be observed.

CHAPTER XVII.

Prolapse of the Urethra.

To describe all the diseases of the urethra and the bladder would require more space than we can afford, and they do not strictly belong to those organs the diseases of which form the subject of this treatise. It might, however, be advisable to say a few words about prolapse of the urethra, on account of the diagnosis and the treatment.

While a slight eversion of the mucous membrane of the urethra is exceedingly common, especially in women who have borne children, the extrusion of a sufficiently large part of it to form a tumor is of rare occurrence. It is mostly found in children, old people, or weak subjects. It is caused by straining during micturition or defecation —*e. g.* when a stone is lodged in the bladder or the anus is the seat of a fissure.

The disease may implicate the whole circumference of the urethra or only a part of it, most commonly the lower. In the first case the urethral canal is found in the centre of the tumor; in the second, it is placed excentrically.

The prolapse gives rise to or increases vesical tenesmus and may produce cystitis. In the beginning the tumor has the appearance of the normal mucous membrane, but later it becomes darker and denser, and is sometimes excoriated.

Diagnosis.—When the prolapse is total, the presence of the lumen of the canal in its center settles at once the diagnosis. If it is partial, it may be taken for a *caruncle*, but it differs from the latter by always having a broad base and by being easily reduced.

Treatment.—Simple reduction with a finger or sound, followed by the use of a cupped bougie, with tannin or the application of tincture

of iodine, rest in bed, and hot vaginal douches and affusions, may be tried. If they do not succeed—which can only be expected in slight cases—operative interference is called for: 1. The tumor may be transfixed at its base, tied in two halves, and cut off. 2. The deeper part of the mucous membrane may be secured by inserting a suture on either side, and uniting the two edges of the wound with a continuous catgut suture after cutting the redundant tissue off. 3. Emmet's *buttonhole-operation* may be performed by placing the patient in Sims's position, introducing his speculum, making a longitudinal incision on the vaginal wall corresponding to the course of the urethra down to the mucous membrane of the latter, pulling this through the opening made, introducing some transverse sutures through the vaginal and urethral mucous membrane, cutting off the redundant tissue over the sutures, and closing the latter.

The prolapsed portion may also be cut off in front of the meatus with galvano- or thermo-cautery, but then steel bougies should be introduced during and after the healing in order to avoid stenosis. The cutting operations with sutures are the best.

CHAPTER XVIII.

MASTURBATION.

MASTURBATION consists in the production of venereal orgasm by means of the hand, the tongue, or any kind of body on one's self or another person. It is also called onanism, but not correctly, for a closer scrutiny of the ninth verse of the thirty-eighth chapter of Genesis will show that Onan had sexual intercourse with Tamar, but deprived her of his semen by spilling it outside of her body (an act called withdrawal). It is not usual to treat of this subject in works on gynecology, but since the thing exists, since it appears in innocent childhood, since it produces certain symptoms, since it may be the cause of the most serious diseases, since the physician called as expert in a suit for rape may be able to exonerate an innocent man by knowing the effects of masturbation,—it is, in my opinion, proper to give some information about it here.

Masturbation may be indulged in by infants of either sex who have no idea what they are doing.[1] They may either be taught the vice by unscrupulous nurses in order to make them quiet, or they may accidentally find out that certain movements produce a pleasur-

[1] A. Jacobi, "On Masturbation and Hysteria in Young Children," *Amer. Jour. Obst.*, vol. viii. No. 4, 1875, and vol. ix. No. 2, 1876.

able sensation. In older female children I do not believe the vice is so common as among boys, but later in life it is probably much more so in women than in men. This cannot be explained merely by the greater facilities offered the male sex for normal satisfaction of the sexual instinct without running the risk of having offspring. There are several reasons for it, one of which is the less degree of orgasm felt by women during normal sexual intercourse (p. 120). This, at least, would seem to explain the fact that many married women are given to this vice—a thing that certainly is exceedingly rare in the male sex.

The most common form of masturbation in women consists in titillation of the clitoris, be this executed by the person's own hand or that of another, or by the tongue of another human being or of a dog, or by any other object. Less frequently the finger or other more or less penis-shaped bodies, such as roots or needle-cases, are introduced into the vagina.

1. *Masturbation in Infancy.*—Masturbation in early childhood, being in many respects peculiar, we must consider its symptoms and treatment separately. In some cases there may be local changes, such as redness of the entrance of the vagina, moisture of the labia and vagina from over-secretion of the glands of Bartholin and the smaller muciparous glands of the vulva. But these cases are by no means frequent. Of much greater importance are certain other changes observable in the child, such as the occurrence of sudden redness in the face, followed by paleness, twitching of the muscles about the eyes, hurried breathing, and a deep sigh. These spells come on when the child is sitting on the floor, often rocking to and fro or pressing the fists into the iliac fossæ or against the genitals. These attacks lead to anemia, bloatedness, and irritability of temper.

Treatment.—First of all, infants and their nurses should be carefully watched. If there are pin worms in the rectum, they should be removed (p. 265). If the composition of the urine is abnormal, it should be remedied by proper medicine, especially alkalies and anodynes. The couch should be hard, the cover not warmer than what is necessary to protect the child. It should not have too rich food: large quantities of meat, eggs, spices, salt, and beer are injurious. Drugs that irritate the uropoietic system, such as cantharides or nitrate or chlorate of potash, should be avoided or handled with care. During the act the child should be taken up, her thighs separated, her hands removed from her abdomen, and her mind diverted. The anemia and nervousness should be treated with strychnine, iron, and arsenic.

2. *Masturbation in Older Children and Adults.—Symptoms.*—The frequently repeated act of self-abuse or masturbation with another person leaves certain local changes in the genitals which it is useful

to know. It is true that not one of them is pathognomonic, but the presence of several of them must, to say the least, awaken suspicion and may help to find out the truth. The clitoris is both thickened and elongated. The glans is red and protrudes beyond the prepuce. The prepuce is lax, red, and thickened. The labia minora are elongated, flaccid, wrinkled, of brown, gray, or slate-like color, with black irregular spots due to the deposit of pigment in the deep layer of the epidermis. This change in size and aspect is often unilateral. On the inner surface of the labia minora is found a series of minute white or yellow spots like insect eggs, formed by hypertrophied glands. Sometimes the labia majora are likewise enlarged, flaccid, and wrinkled. The hymen may be torn, but is more commonly not so, but so lax that the finger enters without meeting any resistance. The vaginal entrance and the rima pudendi may be gaping. Often leucorrhea and other signs of vulvitis (p. 258) are present. The vulvo-vaginal glands may be inflamed. The vulva may show fresh scratches or old cicatrices, and the clitoris has been found wounded and nearly bitten off—conditions which may cause hemorrhage or leave wounds slow to heal.

As to the general health, women seem to have a greater power of resistance in regard to the effects of masturbation than men. There are, indeed, women who are confirmed masturbators, and yet enjoy excellent health, but, as a rule, they pay as well as the other sex for their illicit pleasure by pain, ache, and ailment. The works of specialists in this line must, however, be read with more criticism than their authors usually show in writing them, nearly every known disease, inclusive of pneumonia, that ever has been observed in a woman addicted to masturbation having been put on the list of the consequences of the habit. Certain diseases are, nevertheless, found so often in masturbators, and the connection between them and the vice is so easy to understand, that we do not hesitate in looking upon them as cause and effect. We find inflammation of any part of the genitals, periuterine hematocele, and pelvic peritonitis—conditions which all stand in a natural relation to the irritation and frequent congestion of the genitals and pelvic organs.

The nervous system suffers more than any other, and in all its functions: the hands are apt to tremble or the gait may become unsteady; the perception of all the senses loses more or less of its acuteness; the memory weakens; interest in all intellectual matters diminishes; wandering pains of neuralgic origin are quite common; hysteria, epilepsy, chorea, paralysis, and insanity may be developed, but it may be hard to decide whether the masturbation was the cause of the insanity or if the lurking insanity impelled to masturbation. I have seen a peculiar nemesis in a young lady who was accustomed to discount the pleasures of married life, and who, when she married

a strong young man, failed to feel the slightest satisfaction in the normal relation between man and wife.

Nutrition suffers, as a rule, soon. The patient loses flesh, the face becomes pale, dark rings appear under the eyes, the appetite is poor, the digestion difficult, and the bowels constipated. It is said that fresh cicatrices are liable to break up and ulcerate.

The neighboring organs are apt to suffer. Sometimes the sphincter muscles of the urethra become paralyzed. Cystitis may be caused by the irritation, and the inflammation may spread up to the kidneys. Stone may form around foreign bodies used for masturbation which are lost hold of and enter the bladder—*e. g.* a hair pin. The sphincter of the anus may become relaxed and give rise to a prolapse of the rectum.

Masturbation entails often sterility or abortion, and if children are carried to term, they are apt to be puny, neurotic, and weak.

Treatment.—The treatment must be moral as well as physical. The physician must use every effort to impress upon the mind of the patient the bad consequences of her vice. Any palpable cause of irritation, such as pin worms, accumulated smegma, bladder catarrh, calculi, or hemorrhoids, must be removed. The food should be bland; alcoholic beverages and spicy dishes should be forbidden. The body should be tired with manual work, gymnastics, or walking; the mind occupied by attractive subjects. Cold baths should be used in the morning, but not in the evening on account of the following reaction. The patient should lie on a hard mattress, lightly covered, with the arms above the cover, and in a cool room. The nervous system must be quieted with camphor, lupulin, the bromides of ammonium, potassium, and sodium, or monobromide of camphor.

In the worst cases *clitoridectomy* is indicated, and has effected some remarkable cures. It is a simple operation, but, as it has led to septic peritonitis and death, it ought to be performed with antiseptic precautions. It is only the glans and body that are removed. This may be done with a bistoury or curved scissors and sutures applied, or with the thermo- or galvano-cautery. There is no reason why this little bit of flesh should not be removed, and, as it certainly is the most excitable part of the genitals, it is rational to do so in cases of abnormal excitability irresistibly leading to masturbation, ruining the health of the patient, depriving her of her mental faculties, or driving her to suicide.

PART II.

DISEASES OF THE PERINEUM.

CHAPTER I.

INJURIES.

HERE we only have to deal with the anal part of the perineal region, the injuries to the vulva having been considered above (p. 257).

For convenience' sake we will, however, simply call it the perineum. The perineum is exposed to injuries from without and from within.

I. *Injuries from Without.*—Contusions and contused, punctured, incised, or torn wounds, involving a more or less complete laceration of the partition between the genitals and the rectum, are produced by falling down on the upright of a chair, a slat of a fence, a pitch-fork, or similar pointed object, or by sliding down the balusters of a staircase against the boss of the newel-post. Similar lesions are sometimes caused by the horns of cattle or result from rape where there is a marked disproportion in the size of the organs that come in contact.

Treatment.—The treatment is the same as for injuries of the vulva.

II. *Injuries from Within.*—These are particularly caused by childbirth.

Lacerations of the perineum may be *recent* or *old*, *complete* or *incomplete*, *open* or *submucous*.

A. *Recent Lacerations of the Perineum.*—The recent laceration of the perineum is a condition that is considered at length in treatises on obstetrics.[1] Here we will only briefly allude to a few points which are necessary in order to understand the old lacerations, or have special surgical importance.

As we have seen in the description of the anatomy of these parts (p. 43), the parturient canal is, near and at its end, limited by two

[1] More detailed information on the subject may be found in my papers on "The Obstetric Treatment of the Perineum," *Amer. Jour. Obstet.*, April, 1880, vol. xiii. p. 231, *et seq.*; and on "So-called Lacerations of the Perineum," *Med. News*, April, 1891, vol. lviii. p. 454, *et seq.*

comparatively narrow openings, the vaginal entrance and the rima pudendi, the first of which is circular from the beginning, while the second becomes so when distended by the child being pushed through it. Of these rings the inner one is again the narrower. They are the seats where laceration commonly begins during childbirth, and from which it may extend more or less into the neighboring tissues. The inner ring, the vaginal entrance, being the narrower of the two, suffers more constantly. But a superficial tear here, even if it extend far up into the vagina, is of little importanee. A deep tear of this ring, involving the levator ani muscle with its two fasciæ (pp. 94–95), is, on the contrary, a fruitful source of future suffering. The tear in the levator ani muscle is usually found backward and outward in the direction of the tuberosity of the ischium, probably because the muscle gets caught between this point and the head, while in the median line the rectum furnishes a soft pad between the vagina and the levator ani muscle.

The external ring, formed by the extended vulva, escapes often any injury through childbirth, so that even the thin edge of the fourchette is found entire in women who have borne children. It may, however, suffer in different places. The most common is a tear in the median line, beginning at the posterior commissure, from which it may extend down to and into the anus and up to and through the vaginal entrance. More rarely this perineal rupture begins in the center of the perineum, and extends forward into the vulva, forming a similar tear as if it had started from the fourchette; and in the rarest of all cases the tear in the perineum becomes sufficiently large to admit of the passage of the child through it without implicating the rima pudendi or the anus (*central laceration*).

If the perineum escapes or suffers little, the injury often takes the shape of superficial tears on the labia majora or deeper tears in the labia minora and vestibule near the clitoris (p. 257).

Nearly all tears being due to circular expansion, the parts separate laterally, and the rents have a longitudinal direction more or less parallel to the axis of the parturient canal; but if the severed halves of the perineum do not unite by first intention, they heal separately, each forming one-half of a cicatrice, in which way cicatrices with a transverse direction are formed. This has given rise to the erroneous conception that the fresh tear also had been transverse, which it hardly ever is.

Sometimes nature can effect complete agglutination and coalescence by first intention of any tear. I have myself seen this in incomplete laceration where the whole perineal body was severed to the rectum, and I have heard of the same lucky result in cases of complete laceration, in which nothing was done except to tie the patient's knees together. But such a process is of so extremely rare occurrence that

it is foolhardiness to wait for it. In the great majority of cases the natural healing is altogether insufficient. An incomplete tear in the median line will heal together a little by granulation at the bottom of the angle; the remainder will only heal over and form a contracted transverse scar. A complete tear will leave the anal ring broken: the sphincter retracts, its ends being plainly marked by a little pit of the size of a large pea on either side; where the perineal body should be is seen a V-shaped cleft; the mucous membrane of the rectum rolls out, forming a little red, soft, puckered cushion at the posterior circumference of the anal opening; and the patient has no control over flatus and feces, which escape involuntarily and make the poor woman an object of disgust to herself and others.

A tear involving the levator ani and the sinewy structures at the vaginal entrance weakens the support of the pelvic structures above. As soon as she gets up the patient complains of a disagreeable feeling of looseness and bearing-down. In course of time the vaginal mucous membrane bulges out in front and behind, the bladder sinks down, the uterus is first retroverted, then retroflexed, then descends, and may finally hang between the legs. The strain on the utero-sacral and broad ligaments causes pain and backache. The vagina is inverted, and becomes unfit for one of its purposes. Exposed to friction against the clothes, the vaginal portion of the uterus becomes the seat of a deep ulceration.

Treatment.—Fresh tears should be united immediately after the termination of childbirth (*primary operation*).

Rupture of the Outer Ring.—If the tear begins at the posterior commissure and extends more or less far toward the anus without implicating it (*incomplete laceration*), and is not much over half an inch high (up toward the vagina), this may in most cases be done more easily and speedily, and with much less pain, by means of *serrefines* (Fig. 193)—fine self-holding clamps working on the principle of clothes-pins. These little instruments are applied, from one to three in number, by placing the patient on her left side, lifting the torn perineum between the thumb and index-finger, and embracing it with the legs of the serrefine. The first is placed half an inch from the end of the tear, the following with half an inch interval, and the last at the anterior end of the tear. Good serrefines should have so little spring-force that the obstetrician can put them on the web between his own thumb and index-finger without feeling pain, and the legs must be half an inch long beyond the crossing.[1]

FIG. 193.

Garrigues's Serrefine.

[1] Most serrefines on the market are of very inferior make, but Geo. Tiemann & Co. keep some good ones under my name.

In fat women the perineum cannot be folded as described, and, therefore, the serrefines cannot be used, and recourse must be had to sutures.

Sutures should always be used where the vaginal entrance is torn. If the tear extends up into the vagina, separate vaginal sutures should be passed, beginning at the upper end and going down as far as the perineal body. It may be done with catgut, by interrupted or continuous suture. For the perineal body silkworm gut is the best material. As a rule, three sutures are needed on the perineum proper. The patient is placed across the bed, with the buttocks drawn to the edge; the knees are bent and held by assistants, the feet are placed each on a chair; and the operator sits on a third between the two or kneels. The parts are irrigated with a disinfectant fluid, preferably creolin; a large cotton tampon with an attached thread is pushed up into the vagina above the tear, in order to keep blood away from the field of operation. Shreds that hang loose by a pedicle are cut off. The left index-finger is introduced into the rectum, while the assistants stretch the torn parts symmetrically from side to side. A rather long curved needle is inserted on the left side, a quarter to half an inch outside of the edge of the tear and at the same distance from the posterior end of the tear, and carried under the torn surface over to the corresponding point on the other side. The second suture is placed about half an inch farther forward, parallel to the first, and is likewise entirely imbedded. It embraces often the lower end of the mucous membrane above the tear. The third and last is placed a little below the posterior commissure. It goes only under the tear in the left labium majus; the needle emerges on the line of demarkation between this torn surface and the mucous membrane, is again entered on the corresponding point on the right labium, and is pushed out on the corresponding point of the skin. These three sutures correspond to sutures 2, 4, and 6 in Fig. 206. Executed with proper antiseptic precautions, this operation is nearly always successful.

Before closing the sutures the tampon is pulled out; the parts are again irrigated and dusted with iodoform. My *perineal pad*, or antiseptic occlusion dressing, is applied. This consists of (1) a piece of absorbent lint, 12 by 8 inches, folded twice lengthwise, so as to become 3 inches wide, the average distance from one genito-femoral sulcus to the other; or a pledget of absorbent cotton of somewhat larger dimensions, in order to allow for shrinkage; (2) a piece of gutta-percha tissue, 9 inches by 4; (3) a large pad of cotton batting; and (4) a piece of unbleached muslin ½ yard square. The lint or absorbent cotton is wrung out of some antiseptic fluid and carefully applied over the vulva and the anus. The gutta-percha is washed with the same solution and placed over the first layer, turning the edges forward against the thighs. The outer layer of cotton batting

serves only to give bulk, and is pressed up against the genitals by the muslin, which is folded like a cravat 5 inches wide and fastened to an abdominal bandage, so-called belly-binder, in front and behind. This dressing is changed three or four times in twenty-four hours, or oftener if the patient has a movement from the bowels or passes her urine in the mean time. Before a fresh dressing is put on the parts are irrigated externally with antiseptic fluid, the patient lying on a bed-pan. No vaginal injection is given; nay, the genitals are not touched.[1] The knees are bound loosely together, so as to prevent wide separation, but allow small movements. This is obtained by surrounding the knees with a wide ring of muslin, or two rings with a connecting piece like eye-glasses, which are prevented from sliding down by fastening them on either side to the abdominal binder by means of a long narrow strip of muslin called a suspender. The patient is allowed to urinate herself if she can, and the bowels are kept open by means of a mild aperient.

If the tear extends into the anus and more or less far up the rectum (*complete laceration*), the immediate operation is particularly indicated. Even if only partial success should be obtained, and a recto-vaginal fistula should remain, the general shape of the parts is retained and a subsequent operation much facilitated. Under these circumstances it is best to make a triangular suture, one row along the rectum, one along the vagina and vulva, and the third along the cutaneous surface of the perineum. The two first should be deeper, the last more superficial, by doing which the formation of a recto-vaginal fistula above the perineal body is best obviated. For the first two rows catgut or fine silk is used; for the last silkworm gut or silver wire is preferable. Special care should be taken to unite the ends of the sphincter ani muscle on the principle that will be described below in speaking of Emmet's operation for the old rent.

If the parts are very edematous, the edges of the wound will gape when the swelling subsides. In such cases it is advisable to wait twenty-four hours or longer before operating, or, instead of tying the suture, half a dozen perforated shot may be passed over the free ends, and the last compressed so as to hold the suture in place. When, then, the wound later is found to gape, the last shot is seized with a pair of forceps and pulled upon, carrying the suture with it, until the edges are again in contact, when the next shot is compressed and the first cut off.[2] With this method it is better to use silver wire, the ends of which may be turned out, so as to give a firmer hold on the shot.

Rupture of the Inner Ring.—Since the rupture of the ring forming the vaginal entrance has much more serious consequences than that

[1] More details and an illustration are found in Garrigues's *Antiseptic Midwifery*, p. 27, and *Amer. Syst. of Obst.*, ii. p. 351.

[2] J. H. Carstens, Detroit, Mich., *Amer. Jour. Obst.*, 1884, vol. xvii. p. 241.

of the outer ring, except when the latter implicates the sphincter muscles of the rectum, medical science calls for its immediate treatment; but in most cases medical diplomacy and other considerations will throw their weight into the other scale. These tears are mostly produced by an unskilful conduct of labor, such as the administration of oxytoxics, manual expulsion of the child by pressure on the fundus, a precipitate use of the forceps, or, at the very least, the omission of means to ensure a slow dilatation of the vaginal entrance and the vulva during the birth of the child; and accoucheurs who will commit such faults and midwives are not likely to examine for a tear that is not visible on the skin, and, if they did, would hardly be competent to remedy the injury. It will also be hard for the general prac-

FIG. 194.

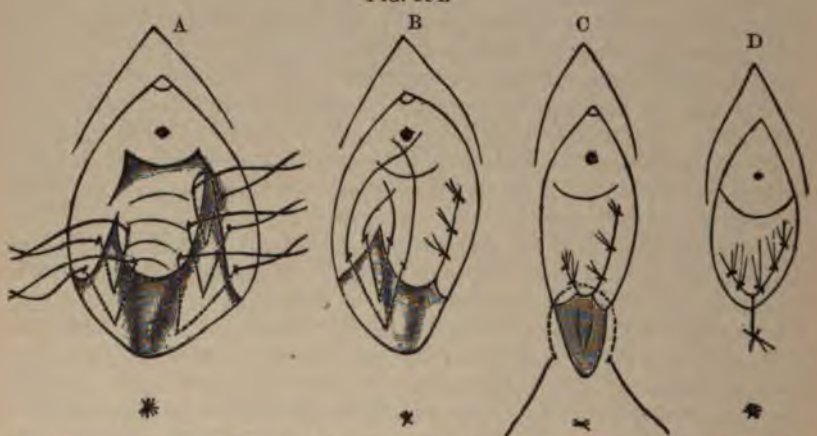

Recent Tears inside the Vagina and Suturing (H. Kelly): A, vaginal sutures passed; B, sutures tied on left side; C, sutures tied on both sides and cutaneous crown-suture in place; D, all sutures tied.

titioner to persuade the patient and her friends to allow him to perform a protracted operation for a condition the importance of which is doubtful to their minds. But if circumstances permit us to follow the dictates of science, the injury should be remedied by passing a row of deep sutures from above downward through the edges of the lateral tear. The needle should be carried well downward in the direction of the vaginal entrance and then up through the other lip, lifting up the pelvic floor, as will be explained in describing Emmet's operation for old tears. Catgut is the best material, since it need not be removed. A single cutaneous suture disposes of what is not united by the preceding sutures (Fig. 194). For the latter silkworm gut or silver wire is preferable.

If the sphincter ani is torn, its ends should be brought together

with two sutures—one corresponding to the innermost, and the other to the outermost, fibers, inserted in the way to be explained below in describing Emmet's method for old tears.

Serrefines are removed on the fifth day, sutures in the incomplete laceration on the eighth day. In the complete laceration the cutaneous are left in nine or ten days; the rectal take care of themselves, catgut being dissolved and silk being allowed to cut through; the vaginal, if silk has been used, are removed after three or four weeks, when the perineum is strong enough to allow the use of a speculum. The same applies to the deep laceration of the vaginal ring.

Intermediate Operation.—If several days have passed since the laceration took place and the surface has begun to granulate, it may yet be made to grow together. It is for this purpose scraped with the edge of a knife, dusted with iodoform, and united as described above with serrefines or sutures. Union by first intention has in this way been obtained in operations performed from one to three weeks after delivery.

The subcutaneous tear of the levator ani muscle might be treated in the same way as the open tear in the same locality, after making an incision through the mucous membrane down to the torn ends of the muscle. But, so far, nobody has undertaken this at the time of delivery, so far as I know, and I think such a procedure would meet with considerable opposition, not only in the public, but even in the profession. This accident is therefore left until bad consequences develop, and is then operated on according to the rules presently to be laid down.

B. *Old Lacerations.*—If the lacerated perineum has not been united by the primary or intermediate perineorrhaphy, the so-called *secondary perineorrhaphy* will in many cases become necessary. In the mean time, the patient has not only suffered, but some of the conditions enumerated above may have formed, and the shape of the parts involved has been changed. Instead of broad surfaces corresponding to one another, we have irregularly contracted cicatrices. In some way or other new raw surfaces must, therefore, be produced, and, as the cicatrices are much smaller than the original tear, it becomes necessary to borrow from the surroundings and unite tissues that do not belong to one another in the normal condition.

Of the very large number of operations invented for the repair of old lacerations of the perineum, we will only describe three, one of which, in my opinion, will give satisfaction in any case:

1. *Tait's Flap-splitting Operation.*[1]—*a. Incomplete Laceration.*—

[1] Tait's priority has been contested, and I have myself seen Demarquay operate by the flap-method in Paris in 1872, many years before anybody had heard of Tait's operation of this kind, but there can be no doubt that the revival and simplification of the operation are due to the great gynecologist of Birmingham.

The patient is placed on the table in the dorsal position, with knees drawn up by Clover's crutch or Robb's leg-holder (p. 194). The left index- and middle fingers are introduced into the rectum. One blade of sharp-pointed scissors, bent on the edge, is pushed in in the median line, midway between the anus and the posterior commissure, to a depth of about $\frac{3}{8}$ inch. It is next pushed over to the patient's left side in a curved line ending at the anterior edge of the labium majus, at a point situated at such a distance from the clitoris that there is left just room enough for copulation. All these tissues are cut through with one sweep of the scissors. These are now brought back to the starting-point, turned with the points to the right, and a similar incision is made on this side. The wound gapes, and is made to gape wider by pulling the cut surfaces apart. If arteries spurt,

FIG. 195.

Tait's Perineal Flap-splitting Operation for Incomplete Laceration (MacPhatter).

they are caught with pressure-forceps and may be tied with catgut (Fig. 195).

A handled needle, slightly curved near the end, is pushed through the skin $\frac{1}{12}$ inch outside of the wound, and about $\frac{1}{2}$ inch behind

One difficulty in describing his operation arises from the fact that he has performed it in different ways, and that those who have seen him operate have given very different descriptions of it—*e. g.* Macphatter (*Amer. Jour. Obst.*, Nov., 1889, vol. xxii. p. 1146) and Mundé (*ibidem*, July, 1889, p. 673). In the text I describe it as I have performed it myself with good results.

the anterior end of the incision,[1] passes under the cut surface, emerges on the boundary-line between the cut surface and the inner portion of skin (vaginal flap), is carried over to the other labium, reinserted at the corresponding point, pushed under the right cut surface, and out through the skin $\frac{1}{12}$ inch outside of the wound. A piece of silkworm gut 10 inches long is drawn through the eye of the needle; the latter is pulled back and freed from the suture, the two ends of which are held together with a pressure-forceps, and thrown up on the abdomen. Another suture is introduced in a similar way $\frac{1}{2}$ inch farther back. One of the sutures ought to catch the end of the vaginal flap. One, two, or three more, according to the size of the wound, are introduced under the whole cut surface behind the vaginal flap. In tightening the sutures care is taken to adapt the cut surfaces against one another. The outer flaps of each Λ on the two sides are turned outward, and the inner turned inward, and when the sutures are tightened they are in this way approximated

FIG. 196.

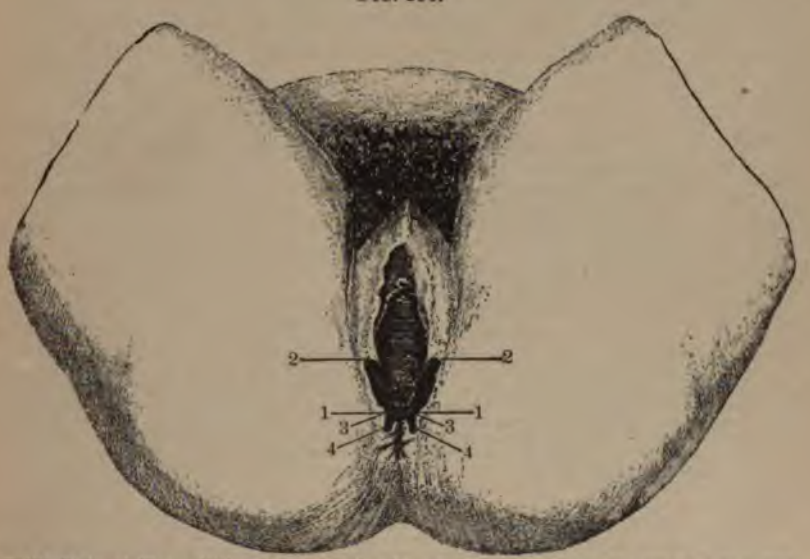

Tait's Perineal Flap-splitting Operation for Complete Laceration (MacPhatter): 1 to 1, first transverse incision; 1 to 2, incisions forming vaginal flap; 3 to 4, incisions forming rectal flap.

as plane surfaces, and so they unite. If there is much redundant tissue to dispose of, the vaginal flap is turned forward and a special

[1] Tait teaches to insert the needle well within the margin of the wound (*Diseases of Women*, i. p. 67), but in my hands the sutures cut through if placed in that way, and the skin is not accurately brought together.

suture passed through its whole width. Between each two of the deep sutures a superficial catgut suture is put through the skin alone.

b. Complete Laceration (Fig. 196).—The cicatrix in the recto-vaginal septum being put on the stretch by separating the buttocks, the scissors are run from one end of it to the other (Fig. 197, *A*), making an incision about ⅜ inch deep, by which are formed a vaginal and a rectal flap. From each end of this first incision another is

FIG. 197.

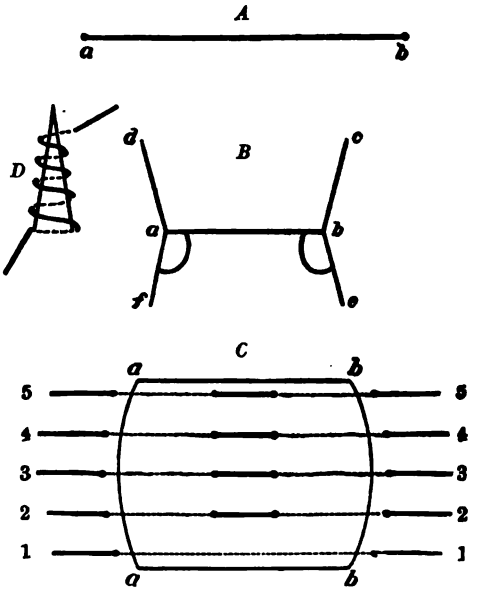

Diagrams illustrating Incisions and Sutures in Tait's Operation for Complete Laceration of the Perineum: *A*, first incision following the cicatricial line between rectum and vagina, the buttocks being stretched (natural size); *B*, incisions to anterior edge of labium majus and outside of anus (without tension); *C*, flaps thrown up and down and put on the stretch; sutures inserted in the order marked: the third corresponds to the angle between the flaps (the bottom of the first incision); the first goes right through the ends of the broken sphincter; *D*, continuous catgut suture carried through the edges of the wound, now turned into the vagina (the same as the upper edge of the first incision, *B*, *a b*).

carried at an obtuse angle, forward and outward, into each labium majus for about an inch (Fig. 197, *B*, *a d* and *b c*), and, again starting from the ends of the first, a fourth and fifth, one-third of an inch in length, are made backward and outward (Fig. 197, *B*, *a f* and *b e*) just outside of the ends of the torn sphincter.

The vaginal flap is held upward, the angles *d a b* and *c b a* being pulled by forceps diagonally upward and inward toward the median line. The rectal flap is held downward, the angles *f a b* and *e b a* being pulled in a similar manner downward and inward. Thus the

lines *d f* and *c e* become curved with convexity turned outward (Fig. 197, *C*, *aa* and *bb*). The needle is carried as described above, with this difference, that it is made to emerge about ¼ inch from the bottom of the wound and enter at the corresponding point on the opposite side (except the hindmost closing the sphincter, which is buried altogether). The sutures are inserted, beginning at the anus and going forward. Finally, the middle of the raw edge *a b*, now situated in the new-formed vagina, is seized with a tenaculum, and the wound closed with a continuous suture of fine catgut (Fig. 197, *D*).

If there has been much loss of tissue by previous denuding operations, deep relaxing incisions should be made parallel to the ramus of the ischium on both sides. The sutures are left in for three or four weeks, the bowels being kept loose. The ends of the sutures should be left rather long (½ inch), as they become deeply imbedded and are hard to find.

Tait's operation is by far the most expeditious perineorrhaphy, and results in the formation of a thick and broad beam between the anus and the vulva. For the complete tear it is, in my experience, superior to all others. It is easy to perform, takes a short time, and yields perfect results.

2. *Hegar's Colpoperineorrhaphy* (modified [1]).—*a. Incomplete Laceration.*—The patient is in the dorsal posture, as in the preceding operation. The object is to remove the mucous membrane over a triangular surface on the posterior part of the vagina and vulva, and bring the two halves together from side to side, and at the same time lift the posterior wall of the vagina up against the anterior.

According to the amount of tear and relaxation of the vaginal entrance and the perineum, a point (Fig. 198, *A*, *a*) is chosen in the median line more or less high up toward the cervical portion. This is pulled forward and upward with a pair of bullet-forceps with catch or a tenaculum-forceps. A small nick is made on the inside of each labium majus near the edge at such a distance from the clitoris that there will be left proper space for copulation (*b* and *c*). The triangle formed between these three points is put on the stretch, and another pair of bullet-forceps introduced where the side line of the triangle intersects the furrow on either side of the vagina (*d* and *e*). With a blunt-pointed pair of scissors, bent on the flat, and with the concave side turned toward the operator, a small incision is made through the mucous membrane just inside of the forceps on the patient's left side, and the scissors pushed up under the mucous membrane to the forceps at the upper end of the triangle, and then swept down to the third forceps on the right side, all of which is done with the greatest

[1] I describe this operation with such modifications as have proved of practical value in my own hands.

FIG. 198—*A*.

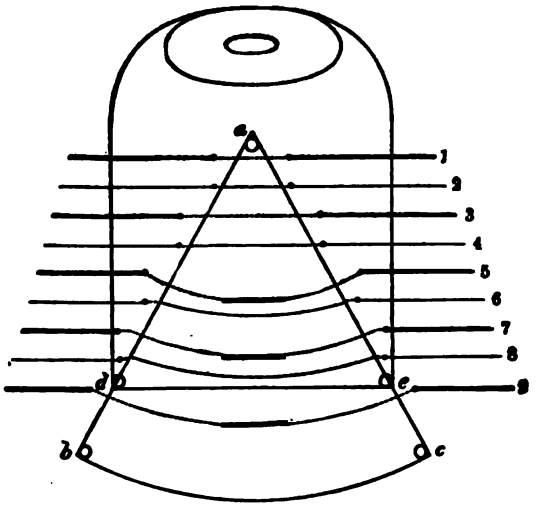

B.

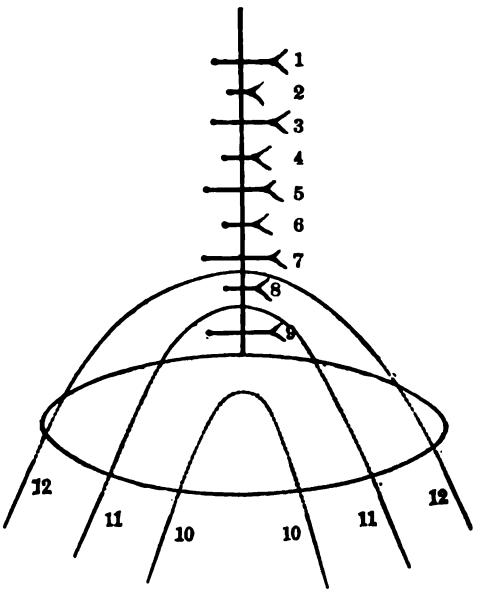

A, Hegar-Garrigues's Colpoperineorrhaphy: sutures 5, 7, and 9 slant downward toward the entrance, and are brought out about a quarter of an inch from the median line; *B*, the triangle shown in *A* having been closed, the perineal sutures are inserted—10, all buried; 11 and 12, partly free—all in a slanting direction.

facility and without loss of blood. Next, this upper part of the triangle is cut loose on the two lateral sides (*e a* and *a d*) and thrown down. The scissors are introduced with the point turned downward, and the lower part of the triangle is denuded in the same way. The more we approach the base (*b c*) the more the mucous membrane adheres, and it may be bound to the underlying parts by cicatricial tissue, which may require small nicks with the scissors. Finally, the flap is cut off along the lines *e c*, *c b*, and *b d*.

Sutures are put in from above downward at a distance of a quarter of an inch from one another, deep ones alternating with superficial ones, which latter go through the edges of the mucous membrane only. The deep are near the upper end, buried all the way under the raw surface. When the surface becomes broader, the needle is brought out a quarter of an inch from the median line and reinserted at the corresponding point on the other side. The following sutures (Fig. 198, *A*, 5, 7, 9) are not carried horizontally across, but made to dip toward the base of the triangle, so that when tightened they will raise the posterior wall forward and upward. Thus one suture is inserted and tied after the other until the lines *f c* and *f b* (Fig. 198, *B*) have the same length as *g c* and *g b*. Then a silkworm suture (10) is carried deep under the wound from a point about half an inch from the median line (*g*) and ⅜ inch from the edge of the denuded surface up under the wound, about two-thirds of the distance from the end of the closed line (*f*), and down to the corresponding point on the other side. A second suture (11) is inserted midway between the first and the point *c*, brought out on the edge of the denuded surface at *h*, reinserted on the other side at *i*, and brought out on the skin. Finally, the last suture (12) is inserted near the outer end of the wound (*c*), brought out at *k* midway between *h* and *c*, reinserted at *i*, the corresponding point on the other side, and brought out on the skin below *b*. These three sutures are not tightened until all are put in and the surface well irrigated. The direction given to the sutures ensures a very perfect adaptation of the edges, and makes the surfaces that come in contact sufficiently broad to form an excellent substitute for the original perineal body.

I use braided silk No. 4 for the deep, and No. 2 for the superficial vaginal sutures, and silkworm gut for the perineum. Each suture is tied and cut as soon as it is inserted. Large curved Hagedorn's needles can be used in most cases. Finally, if needed to repair imperfect adaptation of the edges, a couple of superficial catgut sutures are introduced on the perineum, between the deep sutures.

Buried Catgut Sutures.—Some prefer to close the whole wound with buried catgut sutures, either interrupted or continuous. The latter is begun at the upper end of the triangle, and the first circle closed with a knot, leaving the end three inches long. This end is

seized with a pair of forceps and pulled upward by an assistant, which facilitates the introduction of the remaining sutures very much. The needle is introduced through the edges of the mucous membrane and under the raw surface until the tension becomes too great, when the suture is continued in the depth of the wound down to the vaginal entrance. From this it is carried upward, forming a second row of buried spirals, after which it is brought down between the edges of the mucous membrane, and finally down the perineum. It is tied as stated in describing tier-sutures (p. 214).

b. Complete Laceration.[1]—The patient is in the dorsal position. The buttocks are pulled aside and the anterior vaginal wall lifted up with Sims's speculum. A sponge soaked in antiseptic fluid may be introduced into the rectum, and withdrawn before the last rectal sutures are introduced.

A tenaculum-forceps is introduced at x (Fig. 199) in the median

FIG. 199.

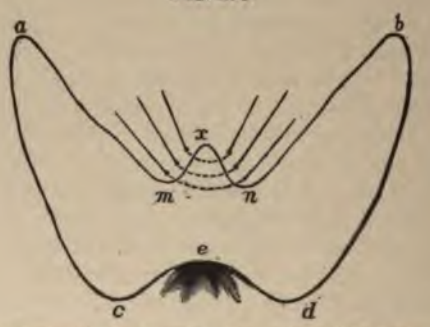

Hegar's Operation for Complete Laceration of the Perineum.

line of the posterior vaginal wall, three-quarters of an inch above e, which is the upper point of the tear in the recto-vaginal partition. Two other pairs of tenaculum-forceps are introduced at a and b on the lower edge of the labia majora, at the distance from the clitoris where we want the posterior commissure to be, slightly above the anterior end of the cicatrice marking the situation of the old perineal body. These three points are now put on the stretch, and, beginning at x, the operator draws, with the point of a scalpel, a curved line to b, with the convexity turned toward himself. Next he continues the line from b to d, with a slightly convex curve outward, down to a point just outside and behind the pit marking the torn sphincter. Next, an exact counterpart of this line is drawn on the right side. Finally, the pit is seized with a tenaculum and cut off with blunt

[1] For simplicity's sake I leave this operation under Hegar's name, but it has evolved gradually in the hands of Dieffenbach, Simon, and others.

scissors curved on the flat, and the strip continued along the whole edge of the rent in the rectum over to the corresponding point on the other side, so as to remove all the cicatricial tissue. The mucous membrane is seized in the middle of the incision, at *e*, with a toothed forceps, and the scissors pushed up under it to the limits of the surface circumscribed with the scalpel. Where it meets with resistance small nicks are made through the resisting tissue. Finally, the flap thus formed is cut off with the scissors.

It is rarely necessary to use hemostatic forceps on bleeding vessels. If so, the tissue grasped between the jaws of the forceps should be cut away before closing the wound, in order to avoid having any dead tissue in its depth. Fine silk (braided No. 2) is best for the rectal sutures, silkworm gut for the vaginal and perineal. Only round needles, straight and curved, two inches long, should be used. Cutting needles make large holes in the soft tissues to be united, which seriously interfere with success.

The first suture is put in a little below *x*, and followed by several others parallel to it running from side to side under the whole raw surface, *x m n*. In order to avoid penetrating into the rectum the movements of the needle are guided with the finger in the intestine.

Next, some rectal sutures are inserted. The needle is introduced on the rectal surface $\frac{3}{16}$ inch below the top of the rent, and at the same distance from the edge, and carried under the raw surface above the rent, pushed out in the median line, reintroduced with the point turned down in the same place, carried under the raw surface on the right side, and out on the rectal surface at a point corresponding to that of entrance. The following rectal sutures are merely pushed in a slanting line from the rectum to the raw surface outside it on the left side, introduced in the corresponding place on the right side, and carried down through the rectal wall. Thus raw surfaces are brought in contact and the edges turned into the rectum. The last two sutures are made to embrace the ends of the broken sphincter. The rectal sutures are quite close to one another, about $\frac{3}{16}$ inch apart, superficial alternating with deep. Next, the lines *m a* and *n b* are brought together with sutures $\frac{1}{4}$ inch apart, alternately a deep, reaching halfway under the raw surface, and a superficial. Finally, four or five are placed rather superficially on the perineum. Every suture is tied and cut immediately when inserted, the ends being turned up out of the way of the following suture.

If the tear is over $1\frac{1}{2}$ inches long, the upper half of it is stitched from the vagina alone, the septum being too thin for a vaginal and a rectal row of sutures. The lower half is treated as described above.

Silk threads entering the rectum become easily conductors of septic material, and small abscesses form, which often result in a small recto-vaginal fistula. This may be obviated by using buried *submucous*

catgut sutures (Fig. 200). These sutures are introduced from the raw surface a quarter of an inch from the edge to be united, and pushed out on the same surface quite near the edge, inserted on the corresponding point near the opposite edge, and pushed out a quarter of an inch from the edge on the raw surface. The vaginal sutures

FIG. 200.

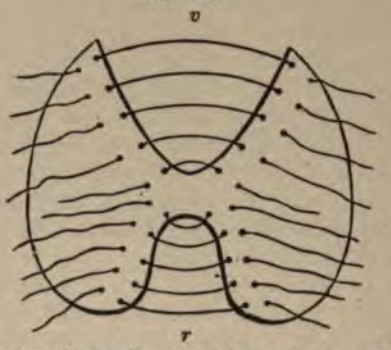

Submucous Sutures (Lauenstein): *r*, rectum; *v*, vagina.

are put in in the same way, and finally the perineum is closed with silver sutures.[1]

For incomplete laceration in cases where the inner ring has suffered much Hegar's operation is in my opinion the best. It interposes between the vulvo-vaginal canal and the rectum a strong wedge reaching up as far as the operator wishes.

In cases of complete laceration one is very apt to get a small recto-vaginal fistula.

3. *T. A. Emmet's Operation.—a. Incomplete Laceration.*[2]—The aim of this operation is to lift up the pelvic floor and dispose of a so-called rectocele.

The patient is in the dorsal position, with bent knees and with feet held up by two assistants.

First Step.—The top of the rectocele (Fig. 201, *A*, *a*) is caught with a tenaculum and held by an assistant over to the left side of the vulva. Another tenaculum is inserted at the caruncula myrtiformis on the right side (*b*). A third tenaculum is inserted at the posterior commissure (*c*). Finally, a fourth tenaculum is inserted at *d*; that is, a point so far up in the side sulcus of the vagina that it does not yield on being pulled down. The four tenacula being pulled in divergent directions, a rhomboidal part of the mucous membrane of the vagina is put moderately on the stretch, and the isosceles triangle, *a d b*,

[1] Carl Lauenstein, *Centralblatt f. Gynäk.*, 1886, vol. x. p. 50.

[2] This is Dr. Emmet's new operation. His old was like that for complete laceration with the exception of what has reference to the tear in the septum.

denuded with two snips of curved, rather sharp-pointed scissors from

FIG. 201.

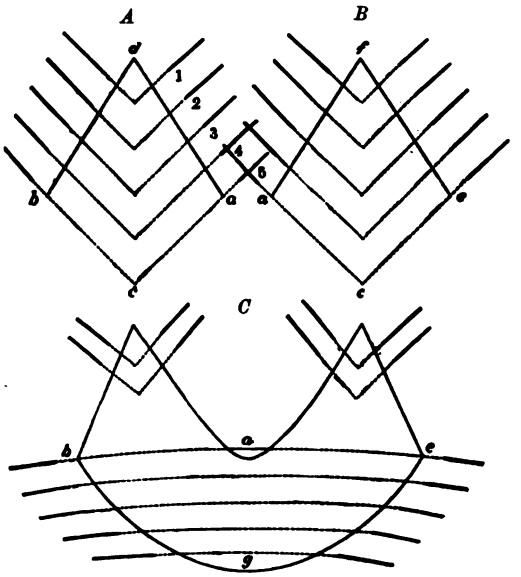

Diagram of T. A. Emmet's Operation for Incomplete Laceration of the Perineum.

below upward. Next, silver sutures are put in, forming curves, or rather angles, the top of which points down toward the vulva, the operator guiding himself by introducing a finger into the patient's rectum (Fig. 202). While they are being passed the assistant always lifts the last, in order to check hemorrhage.

FIG. 202.

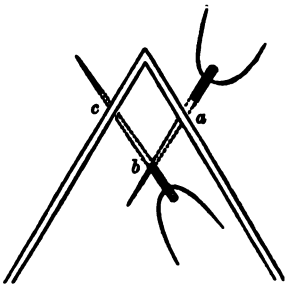

Emmet's Suture for lifting the Pelvic Floor: The needle is introduced at *a*, pushed out at *b*, and when it has been pulled through, it is reinserted at *b* and carried to *c*.

Second Step (Fig. 201, *B*).—The top of the rectocele is carried over to the right side, and the triangle, *a f e*, on the left side treated in the same way as the right.

Third Step (Fig. 201, *C*).—The patient's feet being lowered to the top of the table, the surface, *a b e g*—that is, all the mucous membrane between the top of the rectocele, the two carunculæ myrtiformes on the side of the vaginal entrance, and a curved line running a quarter of an inch inside of the posterior circumference of the rima pudendi and

parallel with it—is denuded, and sutures are put in from side to side. One is carried through the two carunculæ, *b* and *e*, and behind the tip of the tongue of mucous membrane left between the denuded surfaces, *a*. Three or four more are put in from side to side, as seen in the figure, all entering on the mucous membrane inside of the skin.

Fourth Step.—The sutures are twisted, beginning from the tops of the triangles, *d* and *f*, and ending at *g*, cut off, and bent backward into the vagina. When all are closed they form a Y, and are all in the vagina and the vulva, while the skin is not touched at all.

This operation reduces the parts to a condition very much like in appearance the normal one, but it requires more time, more skill, and better assistance than the other operations.

Cleveland's Suture.—Cleveland[1] has recommended the use of catgut and passing the suture in the shape of the figure 8. The first

Fig. 203.

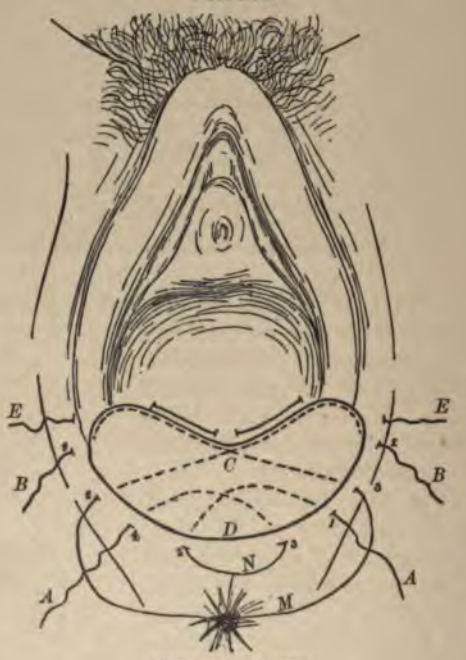

Cleveland's Suture.

suture (*A*, Fig. 203) is passed in at 1, midway between the posterior commissure (*D*) and the upper end of the denudation on the left labium, a quarter of an inch outside of the edge, is carried well back

[1] Clement Cleveland, *Medical Record*, Feb. 14, 1891, vol. xxxix. p. 193.

deep under the tissues so as to embrace the retracted muscles, across between the denuded surface and the rectum, to the center of the denuded surface, then down and out a quarter of an inch from the edge, at 2, situated on the right labium, midway between the point corresponding to 1 and the posterior commissure (*D*). It is then entered at 3, the point on the left labium corresponding to 2, brought under the denuded surface to its center, and then out at 4, which corresponds to 1.

The second suture (*B*) is passed in a similar way. It is entered at 1, a point just below the summit of the denudation on the left labium, and passed, buried close to the denuded edge, around the angle in the left sulcus to the highest point of denuded surface on the columna (*C*), and thence, still buried, across to 2, situated midway between the upper end of the denudation on the right labium and 4, where the first suture came out. Here it is brought out, a quarter of an inch from the edge, re-entered at 3, the corresponding point on the left labium, carried to *C*, then close to the edge of the denuded surface at the right lateral sulcus, and out at 4, which corresponds to the first point of entrance, *B* 1. As a protection a third suture (*E*) is usually introduced just above the upper end of the denuded surface on the left labium, carried through the labium, and out on the mucous membrane; then it takes up about a third of an inch of mucous membrane on the columna at *C*, and finally passes through the right labium. This protection suture should be of silver wire or silkworm gut. It becomes unnecessary if one of these materials has been used for the two other sutures.

The sutures are closed from behind forward in the order they have been put in.

In extreme cases of extension of the laceration into one or both sulci, the Emmet sutures may be used to close the angles, or the Cleveland suture may be applied separately to each angle before the two perineal sutures are inserted.

b. Complete Laceration.—Special care is taken to get the entire

FIG. 204.

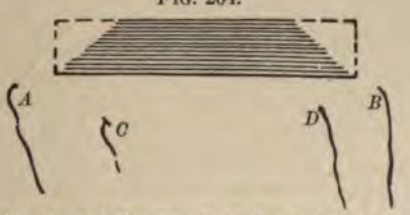

Diagram of Broken Sphincter Ani Muscles (T. A. Emmet): *D C*, first suture; *B A*, second suture.

ends of the broken sphincter brought together. The above-men-

tioned pits marking these ends are seized with a tenaculum and removed, together with a strip of mucous membrane on the posterior vaginal wall and the internal surface of the labia majora, as in Hegar's operation. The first suture (Dr. Emmet uses always silver wire) is inserted a quarter of an inch behind and *inside* the end of the broken and retracted sphincter muscle, which now forms a convex surface (Fig. 204), and carried under the denuded surface parallel to the rent in the recto-vaginal septum, so as to unite the innermost fibers of the sphincter (Fig. 205, *C*, *D*). The second suture (*A*, *B*) is inserted at the outer end of the broken sphincter and carried around the rent in the septum, parallel to the first. These two sutures when closed bring the two ends of the broken ring together, and unite it at the same time with the lower end of the septum. Next, a couple of sutures (Fig. 206, 3 and 4) are brought from the perineum under the whole denuded surface over to the other side, the uppermost comprising the end of the undenuded part of the vagina. The last but one (5) goes through the labium majus, emerges near the side sulcus of the vagina just on the line of demarkation between the pared and unpared surface, enters the

Fig. 205.

Diagram of Broken Sphincter Ani (T. A. Emmet), showing how the ends are brought together by tightening the sutures.

Fig. 206.

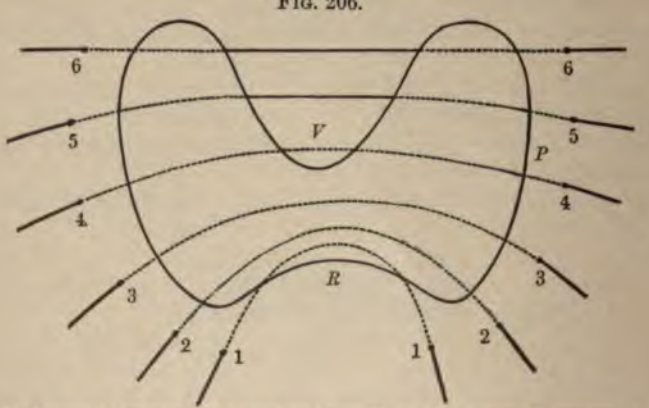

Diagram for Emmet's Operation for Complete Laceration of Perineum: *R*, rectum; *V*, vagina; *P*, perineum. The figures mark the order in which the sutures are inserted.

corresponding point on the other side, and emerges on the skin opposite the point of entrance. The last (6) unites the tops of the denuded surfaces on the labia majora.

If the rent in the recto-vaginal septum is *over one inch long*, it should be diminished by denuding the vaginal surface near the edges, down to the sphincter, and introducing sutures from side to side. When these have been removed after about nine days, and the denuded surfaces have grown together, the above-described operation for the closure of the sphincter and perineum is performed.

Preparation and After-treatment.—In regard to preparations for any of these operations for lacerated perineum, the reader is referred to what has been said in the chapter on Treatment in General (p. 192). The bowels are emptied and the labia are shaved, but the hairs on the mons Veneris need not be interfered with. The knees are kept tied together for two weeks. The diet during the first few days, until the bowels have been moved, should be exclusively albuminoid (milk, beef extracts, raw oysters, and eggs), so as to have as little fecal matter as possible.

As a rule, some pain will call for small doses of morphine (gr. $\frac{1}{8}$); otherwise opiates should be avoided, as they render the feces hard. The patient may lie on her back or her side, but should move slowly and with the assistance of her nurse.

On the morning of the fourth day Ol. ric. fl℥iij is given. When the patient feels that evacuation is near, four ounces of olive oil should be injected into the rectum. In this way an easy, loose movement or two are brought on. Thereafter every morning just enough castor oil (about ʒij) is given to have one easy movement. The urine should be drawn with a catheter. When, after a few days, there appears some discharge, a vaginal injection of carbolized water (℥ss to Oij) should be given morning and evening, and, in complete laceration, half a pint of lukewarm water injected at the same time into the rectum. If the patient is troubled with flatus, much relief is afforded by the occasional cautious introduction of a well-greased soft-rubber rectal tube of the size of the little finger.

As a rule, perineal sutures must be removed at the end of a week (compare Tait's method); vaginal, which are difficult to reach without risking the destruction of the union in the perineum, are left in for three to four weeks, or more if necessary; rectal are left to themselves. In removing vaginal sutures a virginal Sims speculum and Hunter's depressor (p. 145) will be found very useful. The ends of each suture are seized separately with the suture-twister and lifted a little. Great care should be taken to insert one of the points of a pair of pointed scissors into the loop, and cut close up to the entrance of the stitch-canal. The sutures should be removed from below upward, and when the rent begins to bleed the removal of the others should be postponed.

The patient may leave the bed after two or three weeks. Coition should not take place for two months.

CHAPTER II.

Garrulity of the Vulva.

Under the queer name "garrulity of the vulva" has been described a condition which is characterized by the entrance of air into the vagina and its expulsion with a noise from the same. Another name for the same phenomenon is *flatus vaginalis*.

Etiology.—It is a rare disease. It is only possible when the vulva and vaginal entrance gape. It may be due to tears of the perineum and vaginal entrance, episiotomy, loss of flesh, and varicose veins of the vulva.

Treatment.—The indication is to diminish the entrance to the genital canal by the performance of one of the operations described above for laceration of the perineum, or by excision of cicatrices and union by suture.

CHAPTER III.

Coccygodynia.

Under the name of "coccygodynia" are united different and partially unknown pathological conditions, the common feature of which is intense pain at the coccyx, whence it may radiate into the perineum, the hips, the uterus, and the bladder.

Pathological Anatomy.—Sometimes there are palpable diseases or deformities of the coccyx, such as caries, fracture, ankylosis, too great a length, luxation, or other displacement. In other cases the condition is combined with diseases of the uterus, ovaries, or rectum. In a third class it is of a purely neuralgic nature. It is not unlikely that the coccygeal "gland" (p. 103), with its exceedingly rich nerve-supply, has something to do with it. Still, this gland is found in both sexes and at all ages, while the disease is never found in man, and is exceedingly rare in childhood.

Etiology.—The disease is only found in women, especially adults who have borne children, but occurs also in virgins, and very rarely in children. By far the most common cause is childbirth. As a rule, it appears after tedious labor with long-sustained pressure, tears, or straining of muscles or ligaments, or after instrumental delivery; but it may also begin before delivery, and is then probably due to the pressure of the head against the last two sacral and the coccygeal nerves. The disease is sometimes due to violence from without, such as a kick, a fall, or horseback riding, or to exposure to cold, especially in individuals suffering from rheumatism. Sometimes it seems to be

a reflex neurosis due to muscular contraction of the sphincter ani, the levator ani, or the bulbo-cavernosus muscles, such as is found in consequence of painful caruncle or hemorrhoids.

Symptoms.—Severe pain is felt in sitting, especially in sitting down or getting up; nay, the tenderness may be so great that the patient can only sit on one-half of the nates, near the edge of a chair, using her hands to get up and down. All movements of the coccyx and the ligaments and muscles attached to it, induced by walking, riding, defecation, coition, etc., increase the pain enormously.

Diagnosis.—The condition is easily recognized by placing the patient on her left side and introducing the index-finger into the rectum, while the thumb rests on the skin over the coccyx. The slightest movement of the bone causes severe pain, and sometimes it may be possible to feel a diseased condition of the bone or the surrounding parts.

Treatment.—The general treatment consists in tonics or antirheumatics. Suppositories with five grains of iodoform or one-third of a grain of morphine; hypodermic injection of cocaine or morphine; inunction with ointments of veratrine or aconitine; blisters; cauterization; and galvanism or faradization with the secondary current with high tension (p. 222); besides treatment of concomitant diseases in neighboring organs,—have each effected cures. But cases that have resisted all other remedies have yet been cured by the *extirpation* of the coccyx, whether diseased or healthy. This operation is performed by placing the patient on the right side, introducing the index-finger of the left hand into her rectum, pressing it outward, and making an incision in the median line, from beyond the base to beyond the tip, down to the bone. The attachments of the bone throughout its whole length are freely separated on each side, and the knife passed through the articulation with the sacrum. The left hand is now disengaged and, armed with Ferguson's bulldog-forceps, used to seize the bone, which is pulled firmly outward, while the knife is passed behind it and severs all remaining connections. In exceptional cases it may become necessary to sever the bone with a cutting bone-forceps or a small saw. As a rule, there is not much hemorrhage, and the wound may be united by deep interrupted sutures (preferably silkworm gut). If there is much hemorrhage, it may be necessary to pack the wound with styptic cotton and let it heal by granulation.

CHAPTER IV.

HYGROMA.

UNDER the redundant name of "perineal cystic hygroma" has been described a cystic tumor formed by an accumulation of fluid in the cavities of the coccygeal gland. It forms a round, elastic, immovable tumor, situate between the anus and the tip of the coccyx, and covered with normal skin. It may attain the size of a fetal head at term, annoy the patient by its size and weight, cause dyspareunia, and present a serious obstacle in the way of childbirth. Like similar tumors in other localities, it may become inflamed and form an abscess.

Treatment.—If it resists the resolvent action of painting with tincture of iodine, it may be emptied through a hydrocele trocar and injected with the same. Part of the skin and subcutaneous tissue covering it may be cut off, the cavity packed with iodoform gauze, and left to fill by granulation. The whole tumor has also been successfully extirpated. If suppuration has occurred, the cyst should be freely laid open from end to end with a bistoury, washed out with disinfectants, and filled with iodoform gauze.

PART III.

DISEASES OF THE VAGINA.

CHAPTER I.

MALFORMATIONS.[1]

A. *Malformations of the Hymen.*

1. It is doubtful if the hymen is ever *absent.*

2. *Atresia hymenalis* is the condition in which the hymen forms an imperforate diaphragm. It is probably due to an excess of growth of the hymen. Like a transverse septum situated higher up in the vagina, it prevents mucus, cast-off epithelial cells, and menstrual blood from flowing out, and causes, therefore, an accumulation of blood or mucus above it. Such an accumulation of blood in the vagina is called *hematocolpos;* in the uterus, *hematometra.* If the blood is changed to pus, the conditions are respectively called *pyocolpos* and *pyometra.* As a rule, the blood forms a thick, dark brown, tarry mass.

Even in young children the closure of the hymen may give rise to a retention of mucus, forming a tumor which bulges out between the labia and obstructs micturition and defecation. But much more commonly it is at the time of puberty that the accumulation of menstrual blood causes pain, increasing at each menstrual period, and the formation of a tumor gradually growing in size from below upward. First the vagina is distended, then the cervix, the two forming one globular mass, on the top of which is felt the undilated body of the uterus, until, finally, this also takes part in the dilatation. The tubes form sometimes large tumors filled with blood (*hematosalpinx*), which not always communicate with the uterus, the blood not being pressed up from the uterus, but coming from the mucous membrane of the tubes themselves. Diverticula may bulge out from them. They may be divided into a series of three or four compartments by internal lamellæ growing from the wall or by bands of peritonitic

[1] I have treated this subject somewhat more extensively in *American System of Gynecology,* vol. i. pp. 257–278.

origin, forming constricting rings without, and they may be bound to the wall of the pelvis by strong adhesions.

The tumor formed by the vagina and uterus may nearly fill the pelvic cavity and press on the rectum and the bladder, causing dysuria and dyschezia. The hymen becomes thick and fleshy, as do the walls of the vagina, especially the muscular coat, above any transverse septum wherever located. It may form a tumor in the perineum as large as the fetal head, which flattens out the frenulum and is continuous with the skin on the distended perineum and labia of the vulva. In front is found the meatus urinarius. This tumor is fluctuating.

Strangely enough, imperforate hymen may be found combined with pregnancy, which can only be explained by supposing that there has been a minute opening, admitting spermatozoids, which has closed after menstrual discharge had stopped.

Diagnosis.—The bulging of the perineal region is pathognomonic. Often an occlusion is found at the lower end of the vagina, just above the hymen, but this does not form a tumor in the perineum, and on close inspection the hymen with its opening will be found below and in contact with the occluding membrane.

Prognosis.—In itself, the condition leads to rupture of the vagina, uterus, or tubes, and even operative interference is fraught with danger.

Treatment.—Spontaneous rupture through the hymen being very rare, and rupture of the tube being much more likely to occur, an outlet must without delay be given to the accumulated fluid. The operation consists in making a crucial incision through the closed hymen or in cutting it off along its insertion. This may simply be done with knife or scissors. If the membrane is removed, it is well to stitch the edges of the wound together. Some prefer the thermo-cautery or galvano-cautery for slitting open the diaphragm, in order to protect the wound against infection. No pressure should be exercised on the tumor, as it might lead to rupture of the tubes. But the uterus should be washed out with a warm alkaline solution (bicarbonate of sodium or liquor potassæ, ℥ss–Oij), which dissolves the thick blood, and, after that has been removed, with a disinfectant. Permanent irrigation of the vagina has been used as after-treatment, which prevents the entrance of air and keeps up some degree of pressure.

If hematosalpinx can be made out before the operation, it is best first to perform laparotomy, and remove the distended tubes with the ovaries.

Dangers of the Operation.—The membrane being comparatively thin and of easy access, there is no difficulty in incising or removing it; but, simple as the operation appears, it has more than once proved

fatal. The two dangers are rupture of the tubes and sepsis, the latter of which, being so much more common, must carry greater weight in deciding the measures to be adopted. In regard to the first, the operator should, as stated above, abstain from pressure, or may perform preliminary extirpation of the tubes. In order to avoid the second, a large opening should be made and the accumulated fluid washed out immediately. The use of the cautery, sutures, and permanent irrigation is also based on the fear of sepsis.

3. *Abnormal Openings.*—Instead of having one opening, the hymen may have two placed side by side. If the bridge between them is broad, the condition is called *hymen biforis* or *hymen bifenestratus.* If it is narrow, it is called *hymen septus.* Sometimes such a partition grows out from the anterior or posterior wall without reaching the opposite wall, which formation is called *hymen subseptus.*

There may also be many small openings, a condition known as *hymen cribriformis.*

4. *Double Hymen.*—The hymen may be double in different ways. One may be placed above the other, which probably is only due to the presence of a transverse septum in the lower part of the vagina. One may also be placed beside the other, the vagina itself being double.

Treatment.—If the shape of the hymen interferes with coition or childbirth, the condition is easily remedied by removing the septum, making a crucial incision, or removing the whole membrane.

5. *Fleshy Hymen.*—Sometimes the hymen becomes so thick that it is not ruptured in contact with the penis, but constitutes an insurmountable obstacle to its entrance into the vagina. This may cause considerable pain, and become a source of much nervous irritability (*vaginismus*).

The condition is easily remedied by cutting the offending part off with curved scissors and stitching the edges of the wound together.

B. *Malformations of the Vagina.*

1. *Atresia and Stenosis.*—The word "atresia" means a lack of bore, and ought only to be used in speaking of a complete closure of the vagina, whereas "stenosis" means narrowness, and may properly be applied to any condition in which the vagina has not its proper width. But authors often use the word atresia even when there is an opening in the septum obstructing the vagina, and then divide atresia into *complete* and *incomplete.*

The lower end of the vagina may be closed by a thin membrane (*septum retrohymenale*), or one or more solid transverse septa may be found higher up in the vagina, or, finally, there may be a complete absence of the vagina. In such cases the uterus is commonly absent too, but sometimes a more or less normal uterus may be found beyond the tissue where the vagina ought to be.

Complete vaginal atresia gives rise to retention of the menstrual flow and the other conditions described above in treating of atresia of the hymen. It prevents impregnation, and, if the septum is situated low down, it causes more or less dyspareunia. The pouch may, however, in course of time, by continued use, become considerably deeper. Sometimes connection takes place in the urethra or the rectum, especially the former, and, strangely enough, such considerable dilatation causes only exceptionally incontinence of urine.

Much more common than this complete closure is the presence in the vagina of a transverse septum with one or more openings. Sometimes the opening is so minute that it can only be discovered at the time of menstruation, when blood may be seen trickling through it. Under such circumstances impregnation becomes possible, and we may, therefore, find labor obstructed by a transverse septum in the vagina, presenting an obstacle similar to that of an imperforate hymen.

Different theories have been proposed in order to explain the formation of transverse septa in the vagina. One is, that adhesion and coalescence have taken place between opposite walls of the vagina; another is, that the Müllerian ducts failed to be tunneled in the place where the diaphragm is found; and, according to a third, the vagina above the septum is formed by one of these ducts, and below the septum by the other.

A *general narrowness* of the vagina may be due to an arrest of development—a condition often combined with an infantile uterus—and sometimes only one of the Müllerian ducts is developed, while the other disappears, so that there really is only half a vagina. This narrowness may cause dyspareunia.

The *treatment* consists in general dilatation by means of the bivalve speculum or plugs of glass or hard rubber, and the use of lubricants in attempts at coition. This same treatment is to be followed when the narrowness is *relative;* that is to say, when the female organs are normal, but the husband has an excessively large penis.

So far, we have only had in view *congenital* conditions, which constitute what is called malformations. But similar septa may be *acquired*. They may be the result of sloughing and adhesion consequent upon disease, or be the result of violence, strong acids, or even a red-hot iron, being applied in the vagina by fiendish wretches.

Treatment.—The reader is referred to all that has been said about the dangers of imperforate hymen and its treatment. But, besides what has been said there, the transverse septa and the absence of the vagina offer special features. The thinner the septum is, the more the treatment will be like that for imperforate hymen; the thicker it is, the more it approaches that for absence of the vagina, which we now will consider.

The first thing to do in a case of absence of the vagina is to make

a thorough examination, preferably under ether, by using simultaneously a hand on the abdomen, a finger in the rectum, and a catheter in the bladder, and, taking the presence or absence of menstrual molimina into consideration, to find out whether the patient has a uterus and ovaries or not. If there is no uterus, no attempt should be made to make a vagina. It is not only hardly justifiable to expose the patient to the dangers of the operation merely in the hope of forming an organ of copulation, but experience has shown that the hope is futile. Where there is no uterus the artificially formed vagina closes again. The situation is entirely different if there is a uterus and the menstrual flow takes place internally. Then the operation becomes imperative, in order to save the patient's life, and by proper care the new-formed vagina may be kept pervious. If even ovaries are present, impregnation and childbirth may take place, but would be attended by great danger.

Modus Operandi.—The patient is placed on her back with her knees drawn up. The vulva is stretched from side to side. The mucous membrane is seized with a tenaculum, and a transverse incision made midway between the urethra and the anus. Now the operator works his way slowly and very carefully up between the bladder in front and the rectum behind, using a pair of closed blunt scissors and his forefinger to tear the connective tissue between both, and keeping a metal catheter in the bladder and his left forefinger in the rectum, until he reaches the os, which can be felt from the rectum. He introduces the scissors through the os, when the accumulated mucus and blood flow out. With a dilator he stretches the cervical canal about half an inch, washes out the uterus with warm solution of bicarbonate of sodium (ʒj–Oj) and after that with creolin (1 per cent.).

A hollow glass plug (Fig. 207) in proportion to the size of the new-formed vagina is introduced into it, covered with antiseptic gauze and cotton, and held in place by a T-bandage. I think it is an improvement to have a hole (*a*) at the bottom of the plug in order to allow escape of fluid, and one (*b*) on each side of the rim from which a string goes to the bandage surrounding the pelvis.[1]

The wound heals over the plug, epithelial cells growing out from the vulva in the course of a month, during which time the plug is taken out and cleansed every day and the vagina disinfected. If healing is slow, it may be furthered by painting the raw surface once a day with a weak solution of nitrate of silver (gr. ij–℥j). The patient should wear the plug daily for at least an hour during a whole year, but as this is tiresome and hurts some, she is liable to neglect it, and then the canal shrinks again from the uterus downward, and it becomes necessary to dilate it gradually or repeat the operation, which is

[1] John Reynders & Co., cor. Fourth ave. and Twenty-third st., have made such plugs for me.

still more difficult and dangerous than the first time, when the tissue yields more easily.[1]

Other Methods for Keeping the Canal Open.—Instead of the permanent use of the plug, some prefer, after granulation is well estab-

FIG. 207.

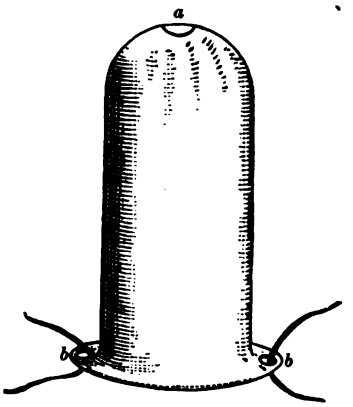

Vaginal Glass Plug.

lished—say, the end of a month—to dilate with finger and *speculum* every two or three days—a very painful procedure.

To cut out *flaps* of the surrounding skin and turn them into the new-formed vagina is not advisable, on account of the hairs growing on these parts; but flaps of mucous membrane have been obtained from the vulva and used with success. Thus, Küstner cut loose the labia minora to their posterior end, split them open by a longitudinal

[1] On Jan. 25, 1890, I operated on Annie K——, American, fifteen and a half years old, for absence of vagina, combined with uterus unicornis. She had for some time complained of severe abdominal pain; had a temperature of 101° and a pulse of 128. The hymen was normal, but the vagina was only a quarter of an inch deep. Through the abdominal wall, the vagina, and the rectum was felt a hard, slightly elastic swelling, nearly filling the pelvis, especially in the left side, and extending up into the left iliac fossa. I had to form a vagina to the full length of my index-finger, 2½ inches, and there was so little tissue between the bladder and the rectum that only a thin transparent membrane was left between the artificial opening and the rectum. There was no cervix, but the os could be felt far upward and backward. Finally, I succeeded in introducing the scissors into the os. A considerable amount of thick yellowish mucus, mixed with old blood, flowed out. The tumor diminished, and was washed out as stated in the text. She improved immediately, and made a good recovery, and menstruated three times while she was under my observation. She was ordered to use her glass plug one hour every day, but soon got tired of it. When I saw her again, about a year later, the upper half of the vagina had contracted again to the size of a cervical canal, just admitting the sound. She had a cyst in the left iliac fossa, without connection with the genitals, from which I evacuated a yellowish clear fluid. This was thereafter successfully treated with injection of iodoform ether, and I have not seen her since.

incision, and stitched them together so as to form a sac outside of the vulva, which sac he then stitched to the artificial canal formed between the rectum and bladder. In another case he successfully lined the hollow with the mucous membrane of a part of the resected intestine of another patient.

If the atresia is only partial, the wound may be covered by stitching the edges of the upper and lower segments of the vagina together.[1]

Oöphorectomy.—If absence of the vagina is combined with absence of the uterus, but active ovaries are present, causing menstrual molimina, the ovaries should be extirpated by laparotomy.

2. *Double Vagina.*—The vagina may be divided by a more or less complete longitudinal partition into two halves, each of which corresponds to one Müllerian duct. Commonly, but not always, double vagina is combined with double uterus.

The two halves of the vagina may be unequally developed, the larger one alone being used for coition. If this one is closed above, fecundation can, of course, not take place.

Instead of a long partition there may only be found a more or less narrow band as remnant of the original septum between the Müllerian ducts.

As a rule, a fully-developed double vagina does not give any trouble, and is discovered accidentally. If childbirth takes place, the septum is more or less completely torn.

Treatment.—If the septum interferes with coition or impregnation, it may be split lengthwise. Both halves are distended with specula and retractors, so as to put the septum on the stretch, and then it is severed midway between the anterior and posterior walls by means of the thermo- or galvano-cautery.

A mere band oftener causes dyspareunia and dystocia, and may be severed with scissors. If there is any bleeding, it is checked by cautery, styptic cotton, or tampon. If the band is fleshy, it is preferable to tie near the two ends and cut out the middle piece.

Double Vagina with Atresia.—Double vagina may be combined with atresia on one or both sides. If one side is pervious, menstruation and impregnation may take place, and the condition is, therefore, often overlooked for a long time. The right half is much more liable to be closed than the left. The uterus is with few exceptions two-horned.

Menstrual molimina, due to retention in the closed half, are present, combined with menstrual flow through the open half. The tumor formed by the retained fluid bulges very much into the latter, and may distend the vulva and interfere with micturition. The upper part of the tumor lies on the side of the uterus. The lateral atresia leads much more frequently to spontaneous rupture than

[1] O. Küstner, *Centralblatt für Gynäk.*, vol. xvi. No. 23, p. 533, June 10, 1893.

atresia of the single vagina, and the perforation always takes place in the septum of the cervix uteri; but this does not effect a cure. The contents are only partially evacuated, air and microbes enter, the stagnating fluid becomes purulent or putrid (*lateral pyocolpos* and *pyometra*), and causes inflammation and ulceration of the walls. The inflammation may extend to the tubes and the peritoneal cavity. At times the tumor increases again in size until, after great pain, a new discharge takes place through the opening in the septum. For diagnostic purposes it is of importance that pressure on the vaginal tumor causes a purulent discharge through the os uteri of the open half of the vagina.

Diagnosis.—Lateral atresia has been taken for *hematocele*, but the history of a chronic disease with monthly exacerbations, and the shape and position of the tumor, will help to avoid this mistake. In lateral atresia the tension of the wall often varies at different times, and if it is not very great it is sometimes possible to invaginate the lower part of the tumor and feel the muscular ring formed by the os.

If the septum is situated very high up, the tumor may also be confounded with *cysts* adherent to the uterus or a *myoma* in the wall of the latter. An exploratory puncture may become necessary to settle the diagnosis.

Treatment.—Sims's speculum is introduced in the open half, and the septum slit open with knife, scissors, or preferably thermo- or galvano-cautery. In cases of double atresia one side is first opened, as in atresia of the single vagina, and afterward the septum incised.

3. *Blind Canals.*—Immediately above the entrance of the vagina, laterally, are occasionally found blind canals, which may be an inch and a half long and wide enough to admit the little finger. They are lined with smooth mucous membrane, and are probably only unusually developed lacunæ. They are without practical importance, except that they may become receptacles for gonococci. If the affection cannot be cured with injections, it may become necessary to lay the canals open.

4. *Faulty Communications.*—Familiarity with the history of development (p. 31) allows us to recognize as consequences of developmental arrest certain abnormal conditions sometimes met with. Thus we have complete *atresia*—*i. e.* absence of any opening on the cutaneous surface leading into the intestinal or urogenital canal, while under the skin is found a common cloaca into which open bladder, vagina, and rectum. The next step in development is represented by cases where this cloaca has an opening on the surface of the body. The rectum opens apparently into the vagina or vulva (*atresia ani vaginalis* or *vestibularis.*) It may have a sphincter or not. In other cases the vagina and the urethra apparently open into the rectum, but in reality these cases are only modifications of a *persistent cloaca.*

If the development has been arrested still later, the partition between the rectum and the urogenital sinus may have been formed, but the urethra seems to open into the vagina. This is really due to a *persistent urogenital sinus.*

Complete atresia is only found in non-viable fetuses. The other conditions hardly ever become the object of operative interference. If the rectum opens into the vulva or vagina, an artificial anus might be made; but if there is a sphincter, it might lose its innervation, and the patient be left in a worse condition than she was before. In very rare cases there is a normal anus, but a communication between the rectum and vagina higher up—a *congenital recto-vaginal* fistula. This may be closed in the same manner as the acquired fistula.

It is likewise very rare that a *ureter opens into the vagina* instead of the bladder. This may be loosened and fastened with sutures in the wall of the bladder.[1]

CHAPTER II.

Vaginal Enterocele.

Vaginal Enterocele, or *vaginal hernia*, is a tumor formed by the intestines, and sometimes the omentum or ovary, by inverting the vaginal wall. Sometimes the protrusion takes place through an opening in the muscular coat of the vagina, so that there is a hernial ring, and the prolapsed intestine is only covered by the mucous membrane. Commonly this protrusion begins in Douglas's pouch, but it may also occur between the uterus and the bladder.

Causes.—The hernia may be caused by a fall, lifting a heavy burden, straining at stool, but most commonly it is due to pregnancy and childbirth.

Symptoms.—In acute cases there is a sudden pain and feeling of a rupture. If the development is chronic, there is a dragging sensation, constipation, and dyspareunia. No case of strangulation is known, but during childbirth a dangerous pressure is exercised on the tumor when it is being pushed down in front of the presenting part. On examination is found a pear-shaped, soft tumor protruding in the lumen of the vagina or descending through the vulva. It increases on cough, can be pushed up into the abdominal cavity, may give a gurgling sound on handling, and, if accessible in front of the vulva, will give a tympanitic percussion-sound.[2]

[1] W. H. Baker of Boston, *New York Medical Journal*, Dec., 1878.

[2] On account of the great rarity of this affection the following notes of the only case I have ever met with may be of interest: Elise V., æt. 27, widow, unipara,

Diagnosis.—It has been mistaken for a *uterine polypus*—a mistake that seems impossible except in consequence of unjustifiable carelessness. It may be much like a *vaginal cyst*, but this does not diminish on pressure.

Treatment.—The intestine may sometimes be reduced and kept up by some form of *pessary*, especially the more bulky ones, such as Hoffmann's, Fowler's, Garriel's, or a globe-shaped one which will be described in treating of the uterus. Thomas has performed *laparotomy*, inverted the sac, and fastened it in the abdominal wound. Perhaps *colporrhaphy* (p. 331) may succeed in retaining the intestines in the pelvic cavity. As a last resort, the sac may be opened, superfluous tissue cut away, and the edges united by interrupted sutures.

Prolapse of the intestine into an unusually deep Douglas's pouch (p. 91) is a somewhat kindred condition, which may give rise to constipation, a sensation of weight, and other discomfort. The intestine may perhaps be kept up by one of the above-named bulky vaginal pessaries. If this does not succeed and the condition causes considerable trouble, an incision may be made in the posterior fornix and the pouch closed by a continuous suture of catgut.

CHAPTER III.

Prolapse of the Anterior Wall of the Vagina; Cystocele.

Any part of the vaginal tube may be pushed into its own caliber, so as to form a swelling there. We have already mentioned enterocele, which is the rarest of these prolapses, and in which the intestine is found in the tumor. Little less rare is a bulging out of the lateral walls, because these normally are drawn to one side by the attachment of the levator ani muscle and bands of connective tissue interspersed with elastic fibers extending to the rami of the pubes and the ischium. The most common of all, on the contrary, is a prolapse of the anterior wall, and on account of the shortness and tightness of the connective tissue between the vagina and the bladder this latter organ

of robust appearance and excellent constitution, applied at the German Dispensary on October 10, 1893. She had been perfectly well until three weeks before I saw her, when she fell down into a cellar and struck the right side of the abdomen against a wooden box. Since then she had bloody discharge from the uterus and abdominal pain. By vaginal examination the uterus was found retroflexed and very tender, but it could easily be replaced. In the left and posterior wall of the fornix was found a soft elastic tumor of the size and shape of a hen's egg and very tender. It could be partially pushed back into the abdominal cavity, when a sharp oval ring was felt surrounding it, probably an opening in the pelvic fascia.

always follows the anterior wall of the vagina more or less in its descent.

Causes.—By far the most common cause of this displacement is childbirth. During pregnancy all the constituent parts of the vagina and the surrounding connective tissue grow and become infiltrated with serum. During childbirth these parts are bruised and torn. During the lying-in period, and when the patient gets up, the weight of the accumulated urine presses on the yet soft and yielding anterior vaginal wall. If the perineum has been ruptured or the vaginal ring is broken or over-distended, there is a still greater lack of support from below. The increased weight of the vagina itself, due to subinvolution, contributes also to the prolapse.

Cystocele may occur apart from childbirth, in consequence of excess in venery, or even in virgins who work hard and are underfed; but such cases are exceedingly rare.

Symptoms.—The condition gives rise to frequent and often imperfect micturition. The bladder is not entirely emptied, and the retained urine undergoes alkaline decomposition and produces catarrh. When the patient lies on her back with flexed and separated knees, the anterior vaginal wall is seen forming a round swelling protruding through the vaginal entrance. By means of a catheter we can easily satisfy ourselves that this swelling contains the base of the bladder. If the condition is complicated with procidentia uteri (see below), the bladder forms in front of the uterus, which hangs between the thighs, a large soft swelling.

Treatment.—Minor degrees of cystocele may be successfully treated with astringent suppositories or injections, by galvanism, by repairing a torn perineum and a posterior vaginal wall, and by a general tonic regimen. More pronounced cases call for direct surgical interference. These operations are called *anterior colporrhaphy*. It may be *median*, *lateral*, or *bilateral*. The median operation may be performed according to Sims's or Stolz's method.

Sims's Method (Fig. 208).—The patient is in the dorsal position, the knees drawn up and separated by means of Clover's crutch or Robb's leg-holder (p. 193). The posterior wall is pulled down with a single Sims speculum, a tenaculum-forceps is fastened in the median line just below the point corresponding to the inner end of the urethra, which is marked by a transverse ridge (Fig. 137, p. 162), and another at the lowest point near the cervix. The operator seizes the mucous membrane of the anterior wall of the vagina somewhere near the lateral sulci with two tenacula, and draws them together. Thus he ascertains how much tissue is redundant, and makes a snip with a pair of scissors on each side, in order to mark the greatest width of the surface to be denuded. Just outside of these points he inserts a tenaculum-forceps, so that the whole surface to be pared may

be put on the stretch. With a pair of scissors curved on the flat a strip of mucous membrane about ¼ inch wide, and extending from the lower forceps to the upper, is cut off. Similar strips are cut off parallel to the first on the right side until the landmark is reached. Then the same procedure is repeated on the left. In this way an elliptical surface, with the long axis in the direction of that of the vagina, is denuded. Next silk or silkworm-gut sutures are inserted from side to side, alternatively deep, under the whole surface, and superficial, only through the edges. It is very convenient to use irrigation instead of sponges (pp. 177, 195, and 215). The sutures are removed from nine days to four weeks after

FIG. 208.

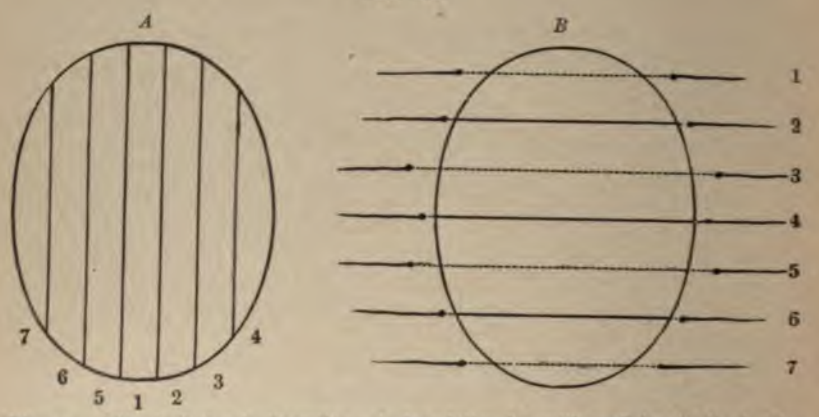

Diagram of Sims's Cystocele Operation: *A*, denudation by cutting off longitudinal strips of mucous membrane with scissors; *B*, insertion of sutures, alternatively deep (1, 3, 5, 7) and superficial (2, 4, 6).

the operation, according to their accessibility, which again depends on whether other operations are performed simultaneously on the perineum and on the posterior wall of the vagina or not. This method leaves a linear cicatrix in the median line. Some prefer a continuous catgut suture inserted in superposed tiers (p. 213).

Stolz's Method (Fig. 209) differs from Sims's by the circular shape of the denuded surface and the insertion of a purse-string suture along the circumference. The denudation is made in exactly the same way. For the suture is used a strong silk thread (No. 4 or 5 braided), armed at both ends with a medium-sized curved needle without cutting edges except quite near the point. One of the needles is given to an assistant; the other is seized with a needle-holder, introduced in the median line (*a*) ⅛ inch behind the denuded surface, carried ¼ inch to the left under the mucous membrane, then made to emerge ⅛ inch outside of the denuded surface (*b*), reintroduced ¼ inch nearer

to the meatus, and carried in the same way alternately below and above the mucous membrane at a short distance from the denuded surface. Arriving a little beyond the middle line (*c*), under the meatus (*m*), the operator hands this first needle to an assistant, and introduces the other exactly in the same way on the other side, until the whole denuded surface is surrounded with the thread. The two ends are now pulled together, while the assistant pushes the denuded surface back with a uterine sound. The suture is tied, and the two ends fastened with adhesive plaster to the abdominal wall. Thus the pared surface is brought together and closed like a tobacco-pouch.

FIG. 209.

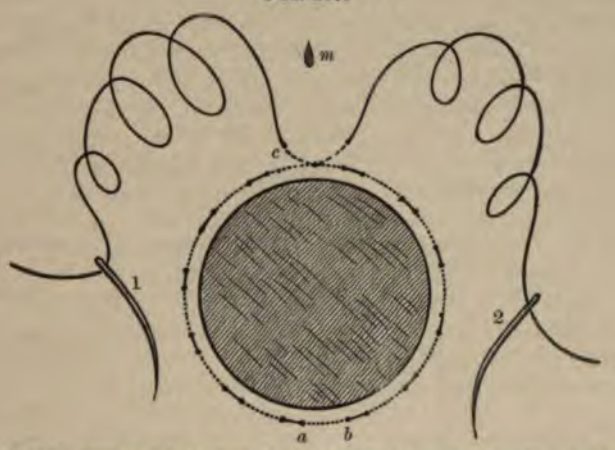

Diagram of Stolz's Cystocele Operation: 1, first needle; 2, second needle; *a*, first point of entrance; *b*, first point of exit; *c*, last point of exit with first needle; *m*, meatus urinarius.

There is formed a small puckered cicatrice, which gives excellent support to the bladder.

The suture is removed after nine or ten days if of easy access; otherwise it may stay for weeks.

Watkins's Method[1] is lateral or bilateral. According to its author, laceration of the anterior vaginal wall is unilateral or bilateral. It is usually submucous, and occurs at or near the insertion of the fascia into the bony pelvis. The location and extent of the tear are detected by touch and by inspection of the change in the shape that occurs in the anterior vaginal wall, which normally presents a convexity corresponding to the urethral curve, a marked concavity corresponding to the trigone of the bladder, and a straight line or slight convexity from this point to the uterus.

[1] T. J. Watkins of Chicago, Ill., *Jour. of Gynecology*, Toledo, O., Aug., 1891, vol. i. No. 5, p. 305.

For Watkins's operation the patient is placed in Sims's position, and the anterior vaginal wall exposed with his speculum. A point of the mucous membrane to the side of the urethra, near its meatus, is caught with a tenaculum. The denudation is carried from this point, along the antero-lateral wall of the vagina, to a point beyond the prolapse. This point may be opposite the neck of the bladder, or the denudation may extend even as far back as the lateral aspect of the cervix uteri. The breadth of the denuded surface is dependent upon the extent of the urethrocele and cystocele, all the redundant tissue of which it should take in. The denudation is made on one or both sides according as the laceration is unilateral or bilateral. Silkworm-gut sutures are passed, beginning at the uterine end of the denudation, from side to side in a curved line which has its convexity outward and forward. Each suture as inserted is tied, and traction is being exerted toward the cervix while the next suture is being introduced and tied. The sutures should include as much connective tissue as possible, care being taken not to injure the bladder, the ureters, or the urethra. After passing the trigone of the bladder the sutures should be passed deeply into the lateral wall near its insertion into the pubes, and as deeply into the anterior vaginal wall as the increased thickness of the vesico-vaginal septum from this point outward will permit. The stitches may be removed after a week or be allowed to remain for two or three weeks. It is claimed that this operation cures the incontinence of urine that sometimes is a distressing feature of cystocele and urethrocele. (Compare Pawlick's operation for incontinence, under Urinary Fistula.)

In any of these operations the bladder should be emptied every four hours. If the patient can urinate, she may be allowed to do so. If not, the urine is drawn, preferably with a soft-rubber catheter. The patient should stay in bed three weeks.

Cystopexy.—A new French operation for cystocele, by which the anterior wall of the bladder is fastened to the abdominal wall, has been performed several times with success. The bladder is injected with five ounces of solution of boracic acid. A transverse incision 2½ inches long is made through the abdominal wall in the hypogastric region. Two catgut sutures are carried through the lower edge of the wound except the skin, then through the outer layers of the anterior wall of the bladder, and through the upper edge of the wound. After tying these sutures the skin is stitched together. During the first six days the catheter is used twice a day only.

CHAPTER IV.

Prolapse of the Posterior Vaginal Wall; Rectocele.

Next to the prolapse of the anterior wall, that of the posterior is the most common form of prolapse of the vagina. It is commonly called "rectocele," but this name is only used correctly if the prolapse contains the rectum, which, as a rule, is not the case. The connective tissue between the rectum and the vagina being much longer and looser than that between the bladder and the vagina, the latter slides away from the rectum, doubles up, and forms a round swelling bulging out through the vaginal entrance. By pinching this fold and by introducing a finger into the rectum we can easily satisfy ourselves that this is so. But in the course of time the anterior rectal wall, lacking its normal support in front, may become distended and form a pouch descending inside of that formed by the vagina.

Etiology.—The causes are similar to those enumerated for cystocele, except the weight of the bladder, for which here is substituted constipation.

Symptoms.—The symptoms are a similar dragging sensation. Constipation, besides being a cause of rectocele, is a sequence of it, and may lead to proctitis with ulceration of the mucous membrane. When the patient lies on her back with separated knees, a globular swelling, formed by the posterior wall of the vagina, is seen protruding through the vaginal entrance—a swelling that increases in size when she bears down or stands on her feet.

Treatment.—Posterior colporrhaphy consists in the denudation on the posterior wall of an elliptic surface similar to that described in treating of Cystocele, but is seldom resorted to. As a rule, the perineum and the vaginal entrance have been injured, and the operation called for is Hegar's or Emmet's *colpoperineorrhaphy*. (See pp. 303 and 308.)

Vaginal Prolapse and Inversion.—When the whole vagina sinks down all around, the condition is particularly called *prolapse* of the vagina, and if this goes so far that the whole tube is turned inside out and forms a sausage-shaped mass hanging between the thighs and surrounding the prolapsed uterus and bladder, and sometimes the rectum, it is called *inversion*.

The mucous membrane, exposed to the air, becomes dry and scaly, and, on the other hand, the thrown-off epithelial cells, if the parts are not kept clean, form a white, malodorous smegma in the pouch between the prolapse and the perineum, which irritates the mucous membrane and gives rise to vaginitis. This condition is connected with prolapse of the uterus, and will be considered in treating of that disease.

CHAPTER V.

Injuries; Thrombus or Hematoma.

The tear in the *hymen* produced by the first coition may cause a severe and even fatal hemorrhage. If an artery is found spurting, it must be tied. In other cases an application or injection with liquor ferri will suffice to check the hemorrhage (pp. 166 and 168). In order to prevent its recurrence the tear should be given time to heal, and some vaseline applied before intercourse until the vaginal entrance is dilated.

Much more serious are the tears in the *vagina* that occur under similar circumstances. The wall has been found torn from the vaginal entrance to the fornix. Tears are also occasionally produced during coition with women who have had frequent intercourse or even borne children, but then there is a strong suspicion, sometimes corroborated by confession, that some hard object has been introduced simultaneously with the penis. Such a tear may also be caused by coition with old women where senile atrophy has taken place, or with women afflicted with stenosis or atresia of the vagina or double vagina. Transverse tears of the fornix have occurred during coition after the operation for lacerated perineum. In such cases it is probably due to the shortening of the posterior wall. Sometimes the lesion is due to unusual postures during the act.

During childbirth the vagina is quite frequently torn. In most cases the lesion extends only through the thickness of the mucous membrane, and is then of little importance, but it may penetrate through the whole thickness of the wall into the surrounding connective tissue. In regard to these lesions the reader is referred to works on obstetrics.

The vagina may also be injured by falls on a pointed object, by attacks of horned animals, etc., or by obstetrical and surgical operations, especially the extraction of the child by means of the forceps, the replacement of an inverted uterus, or the removal of a large uterine fibroid. Even a fall with the abdomen against the sharp edges of a step on a staircase has indirectly caused a tear of the mucous membrane of the vagina.[1]

Symptoms.—These tears are, of course, accompanied by considerable pain. They may cause severe hemorrhage. Sometimes the intestine prolapses and may become gangrenous, leaving an ileo-vaginal fistula. There may also remain an opening into the peritoneal cavity, through which the intestine can slip out and be brought back. All

[1] *Centralbl. für Gynäk.*, 1892, No. 31, xvi. p. 614.

the symptoms of septicemia may be developed. A permanent recto- or vesico-vaginal fistula may remain.

Prognosis.—With proper surgical help the prospects are good.

Treatment.—The vagina is cleaned of clots, spurting arteries tied with catgut, the edges of the wound united with sutures, and a few pledgets of iodoform gauze placed over the wound. These are renewed about every three days.

Thrombus or *hematoma* is a swelling formed by the extravasation of blood under the mucous membrane. It is nearly always due to childbirth, and the reader is, therefore, referred to works on obstetrics for information concerning it.

CHAPTER VI.

Foreign Bodies.

Foreign bodies are by no means rare in the vagina. Most commonly they are objects used by the patient herself in masturbating or as preventives of conception. Sometimes they have been placed there for therapeutic purposes by a physician or a midwife. In rare cases their introduction is due to brutal jokes or acts of vengeance.

The most diverse objects, such as pessaries, sponges, hairpins, sticks, needle-cases, snuff-boxes, glasses, pomade-jars, bottles, etc., have been introduced and remained for months or years in the vagina. Intestinal worms and insects have found their way to the same place.

Symptoms.—According to their size, shape, and length of sojourn foreign bodies may give rise to a great variety of symptoms. The patient complains of pain in the pelvis, the hypogastric and the lumbar regions, or shooting down along the inside of the thighs. A purulent and stinking discharge, dysuria, dyschezia, and dyspareunia are developed. The presence of the foreign body may cause ulceration; gangrene; fistulous communications between the vagina and the urethra, the bladder, or the rectum; peritonitis; and pelvic abscess.

Diagnosis.—Often the patient has forgotten the origin of her trouble or is restrained by shame from telling it. Besides a vaginal examination with finger and speculum, often the examination through the rectum or with catheter or finger in the bladder may be of great help in arriving at a diagnosis. The object may change much in shape by the deposit of calcareous matter around it. It may become entirely hidden from view by burrowing into the tissues, which close over it, or migrate into the abdominal cavity. A sponge giving rise to hemorrhage and a foul discharge has more than once been taken for a carcinomatous cervix.

Treatment.—The treatment consists in the removal of the foreign

body and in combating the inflammation and other disorders caused by its presence. While the first indication in most cases is simple enough to fulfil, in others all the ingenuity of a surgical mind and the resources of a good armamentarium are required. As a rule, the object can be removed through the vulva, but in exceptional cases it has been found advantageous to withdraw it through the rectum or the bladder. Lengthy objects occupying a transverse position must be seized near one of the ends. Large objects must sometimes be broken with shears or lithotriptic instruments. Considerable help is often afforded by introducing a finger into the rectum and hooking it over the body from above. In regard to hairpins, it must be remembered that they almost invariably are introduced with the ends pointing downward to the vulva, which ends must be freed before the pin can be extracted. Sometimes an incision must be made to reach the body. If the vagina contains pieces of broken glass with sharp edges, the walls should be lubricated and plaster of Paris poured in, which will settle around the pieces and form one mass with them that may be withdrawn without cutting the vagina.[1]

The second indication will in most cases be met by using antiseptic and astringent vaginal injections. Sometimes a consecutive endometritis calls for treatment, and in rare cases fistula operations, or even laparotomy, may be required.

CHAPTER VII.

VAGINITIS.

VAGINITIS is the word commonly used in America to designate inflammation of the vagina, but as the suffix *-itis* is of Greek origin and *vagina* Latin, exception has been taken to it. German authors have substituted the term *colpitis*, and English sometimes use *elytritis*.

Under the term "vaginitis" are comprised so very different conditions that it is necessary to admit certain divisions and subdivisions of the subject, which is done in many different ways by different authors choosing different standpoints.

Thus we distinguish between *acute* and *chronic* vaginitis, the difference being not only limited to the time the disease lasts, but also to the greater and lesser intensity of the symptoms. The acute form commonly ends in less than a month; the chronic has no definite limit.

A vaginitis is called *primary* when it appears first in the vagina; *secondary* if the inflammation invades this organ from another part

[1] R. J. Levis of Philadelphia.

of the body, especially the vulva, the uterus, the rectum, or the urethra.

In regard to the chief feature of the disease we distinguish between *catarrhal* vaginitis, characterized by a discharge from the mucous membrane; *exudative* vaginitis, in which a solid inflammatory exudation takes place either on the surface of the mucous membrane (*croupous* vaginitis) or in the depth of the same (*diphtheritic* vaginitis); and *phlegmonous* vaginitis, also called *dissecting* vaginitis or *perivaginitis*, in which the inflammation has its seat in the connective tissue surrounding the vagina, and leads to the severance and expulsion of the whole tube.

As subdivisions we unite under the term "catarrhal" the following forms of vaginitis: 1, the *granular* (also called *follicular*, or *glandular*); 2, the *simple;* 3, the *adhesive*; 4, the *gonorrheal;* 5, the *exfoliative;* and 6, the *emphysematous* vaginitis. To the diphtheritic vaginitis belongs the *dysenteric*.

A. *Catarrhal Vaginitis.—Pathological Anatomy.*—In *granular* vaginitis the epithelium as a whole becomes thicker, the papillæ become larger, and circumscribed groups of small round cells are formed under them and send proliferations into them. When the papillæ increase in length and width, the epithelial cover immediately over them, and the tongues it sends in between them become thinner; at the same time the blood-vessels are much developed. These cell-groups and the swollen papillæ on their top form on the surface of the vagina circular prominences as large as lentils.

In *simple* catarrhal vaginitis a similar process takes place on a smaller scale, so that the cell-groups and the swollen papillæ remain under the level of the epithelium. In the chronic form pigment is imbedded in the deeper cells of the epithelium.

The *adhesive* form is especially found in old women, but clinically a similar condition is also observed in young children. The vagina is spotted or striped, being the seat of ecchymoses and superficial ulcerations, and there is great tendency to coalescence between the surfaces lying in contact with one another. The microscope reveals similar cell-groups under the surface as the two other forms, but here the whole epithelial layer is lost over the infiltrated spots.

In the discharge is commonly found an infusorial animalcule called *Trichomonas vaginalis.* It contains also several species of diplococci, microbes shaped like a coffee-bean. One of these, the *gonococcus*, is by many supposed to be pathognomonic of gonorrhea. It is found in the interior of the epithelial cells and of pus-corpuscles.

Etiology.—Old women are liable to have vaginitis without any other particular cause than their age. Young children often suffer likewise from vaginitis, due to the accumulation of old epithelial cells in the vagina, whence they do not easily escape on account of the

smallness of the opening in the hymen. The great afflux of blood and formation of new tissue that take place in pregnancy lead very frequently to it. Even menstruation is liable to cause it, or make it worse if already present. Anemia and scrofula predispose to it. Often it accompanies eruptive fevers, especially measles. Direct causes are exposure to cold, especially sitting on a cold stone; excessive coition, masturbation, or rape; the presence of foreign bodies, especially pessaries; the use of too hot or too strong injections; operative interference; the irritation caused by urine or fecal matter entering the vagina through fistulæ, or by an acrid discharge coming down from the uterus or from a pelvic abscess. The most common cause by far of the acute form is infection with gonorrheal discharge in whatever way the infecting principle may enter the vagina.

Symptoms.—The patients have a disagreeable sensation of heat in the vulva and the vagina. They have pain in the pelvis and the groins, which increases by walking or any other exercise. They complain of general malaise, and are often feverish. Micturition is accompanied by a burning sensation. Defecation may also be painful. The vagina is so tender to the touch that the introduction of a speculum causes great pain, and sexual intercourse becomes impossible. The mucous membrane is red and swollen. At first it is dry, but in a day or two a discharge begins, which first is mucoid, then muco-purulent, and finally consists of thick creamy pus. The vaginal portion presents a deep red areola around the os, which easily bleeds on being wiped, and a plug of thick muco-purulent matter is seen in the cervical canal. By pressing on the urethra a drop of pus is commonly brought out. The inflammation is apt to remain long in the upper part of the vagina. Sometimes it spreads to the vulvo-vaginal or the inguinal glands, where it may end in resolution or induration, or cause the formation of an abscess. At the menstrual periods the symptoms of vaginitis are apt to become more marked, and a decided exacerbation is caused by pregnancy and childbirth.

In *chronic catarrhal vaginitis* the symptoms have much less intensity. The patient may, however, complain of a sensation of heaviness or smarting. The chief symptom is the discharge, which sometimes is more purulent, in other cases more mucoid. The vagina is of a dark red, bluish, or grayish color, and often the seat of erosions. The mucous membrane is thickened, folded, and often more or less prolapsed.

Vaginitis may have the chronic type from the beginning, or the chronic may be a continuation of the acute form. Gonorrheal vaginitis is particularly liable to become chronic, because the infecting element is retained in the urethral ducts, the ducts of the vulvo-vaginal glands, or the small vestibular glands.

The chronic form is often secondary, due to an irritating discharge

trickling from the uterus, or of constitutional origin in scrofulous or chlorotic women. It is a frequent accompaniment of old age, and is quite common during pregnancy.

Diagnosis.—The signs of vaginitis are so distinct that the disease is easily recognized. Still, the physician must be on his guard in order not to mistake for vaginitis a *discharge from the interior of the womb* due to endometritis, cancer, fibroma, or other affections of the uterus, or a *pelvic abscess* discharging its contents through a fistulous tract into the vagina.

The differential diagnosis between gonorrheal and simple non-virulent catarrh is of great importance, both as to treatment and from a medico-legal standpoint, but science, as a rule, does not warrant us in going beyond a diagnosis of probability in this respect. We try to obtain the history of the case. Very often the mere behavior of the patient furnishes already a strong suspicion that her conscience is burdened with guilt, and by following this hint the physician may be able to elicit a confession. Sometimes it is possible to examine the man who is the source of the infection. The presence of purulent ophthalmia in children of the family makes the gonorrheal nature of the vaginitis probable, the germs of the disease having been carried to the children by fingers, sponges, towels, etc. On the other hand, the presence of a gonorrheal vaginitis in a child may be traced to the same disease in the mother or other female member of the household, and thereby an innocent man, who is accused of rape, saved from unmerited punishment. There is no feature in the disease itself that with absolute certainty can serve to prove whether it is of gonorrheal origin or not. Severe cases of common catarrhal vaginitis produce a pus that is contagious. Certain circumstances, however, are more frequently found in gonorrhea than in non-specific catarrh. The mucous membrane is of a particularly bright red color; the discharge consists of thick creamy pus; as a rule, the cervical canal and the urethra are implicated; there is greater tendency to inflammation of Bartholin's glands; the development of vegetations, if the patient is not pregnant, speaks also in favor of the specific nature of the case. The presence of recent tears and bruises may be of great importance as evidence of rape, in which connection it may be worth mentioning that, unfortunately, there reigns a wide-spread superstition among uncultivated men that a gonorrhea is cured by connection with a virgin, which often leads to assaults upon little girls.

The most conclusive proof is by many thought to be the presence of gonococci, but, according to the latest investigations, these have been found not only in the secretions of the vagina when no infection has taken place, but in diphtheritic puerperal ulcers, in the secretions accompanying ulcers of the mouth, and in the saliva of patients affected with whooping-cough. The only quality that is claimed as

being peculiar to the gonococcus is that of penetrating into living tissue and multiplying there. It enters epithelial cells and colorless blood-corpuscles, and forms there *round* groups, in which respect it differs from other non-pathogenic diplococci. This whole doctrine is so little convincing, and so open to mistakes, that it would be unjustifiable to base on it an assertion which may cause the conviction of an innocent man accused of rape or cast the opprobrium of infidelity on a faithful wife. From a clinical standpoint we must say there is always doubt as to the specific or non-specific nature of vaginal catarrh, and therefore, when called upon to give an opinion as experts, we must give the accused the benefit of the doubt. I have seen cases of urethritis followed by epididymitis where it was as sure as any human thing can be that neither husband nor wife had worshiped strange gods, and I have also seen a newly-married girl, of good family, æt. 17, get all symptoms of gonorrhea, inclusive of salpingitis, although the husband was examined by a prominent andrologist, who declared there were no gonococci, but many other kinds of cocci, in his urethra.

Prognosis.—Non-virulent catarrhal vaginitis is, as a rule, not a dangerous disease. The acute form yields readily to treatment: the chronic form may be protracted through years. Gonorrheal vaginitis is a much more serious disease than gonorrhea in men. It is true that urethritis, on account of the wideness, shortness, and comparatively straight course of the canal is cured more easily than in men, even without treatment, the mere gush of urine serving the purpose of a thorough cleansing. But, on the other hand, the disease is apt to linger in the folds of the vagina, in the deep depressions of the plicæ palmatæ, in the cervical canal, in Bartholin's glands, in the urethral ducts, and in the smaller vestibular glands, so that it is hardly possible to prognosticate its duration. If it extends up through the uterus and the tubes to the peritoneal cavity, it becomes not only a disease hard to cure, and sometimes calling for capital operations, but it jeopardizes of itself the life of the patient. Even in children it has become necessary to remove the appendages of the uterus on account of pyosalpinx due to gonorrhea. Apart from the danger to life and health, it is apt to cause sterility by closure of the tubes or by imbedding the ovaries in exudative inflammatory masses. If the woman conceives and gives birth to a child, the chances of catching puerperal infection are much increased, probably because the presence of gonococci facilitate the development of pyogenic microbes.

Treatment.—Patients affected with severe acute vaginitis should stay in bed for eight or ten days, or at least lie quietly on a lounge. They should be given a saline aperient. Their diet should be bland in quality and moderate in amount. Vaginal injections of plain hot water should be given, and in order to reach all the recesses of the

vagina it is best to stretch it by means of a wire speculum—*e. g.* Blakeley's resilient speculum. If the tenderness is so great that no instrument can be introduced, much relief is experienced by frequent hot alkaline affusions of the external genitals (borax or bicarbonate of soda ʒj to Oj, with addition of tinct. opii ℥j). To the water used for injection may be added emollient or aromatic substances, such as linseed meal or chamomile flowers. When the pain and tenderness subside and the discharge diminishes, bichloride of mercury (1 : 5000) or chloride of zinc (1 : 100) are used. In pregnant women it is better, on account of the risk of mercurial poisoning, to avoid the corrosive sublimate, and use creolin or permanganate of potassium (1 per cent.) instead. Still later it is well to paint the affected part of the vagina with nitrate of silver in substance or in a strong solution (ʒss–℥j) twice a week. If the uterus is affected, that should be treated separately. If it is not, a tampon of absorbent gauze with astringent substances mixed with glycerin, such as subnitrate of bismuth (1 : 4), boroglyceride (1 : 16), tannin (1 : 8, see p. 173), is introduced, and changed every day. Iodoform gauze has also a very good effect, but has an offensive and tell-tale odor. After the nitrate of silver has been used several times, powdered boracic acid may be introduced through a speculum into the fornix vaginæ, and retained by means of a tampon.

Antiblennorrhagic drugs (ol. santali, bals. copaivæ, and cubebs) are less well borne by women than by men, and should, therefore, be given in somewhat smaller doses. They should only be used in the subacute and chronic stages.

In chronic vaginitis astringent injections and applications are used. Extr. pini Canadensis, used on tampon, is praised. For chronic urethritis small rods made of iodoform and cacao-butter are introduced and squeezed against the walls. If the gonorrheal poison lurks in glands and ducts, these must be slit open, touched with pure carbolic acid, and dressed with iodoform gauze. For further information the reader is referred to the chapter on Leucorrhea (p. 241).

Exfoliative, or *Epithelial, Vaginitis* is a rare disease. It is mostly combined with exfoliative endometritis (membranous dysmenorrhea) and found in hysterical women. The vagina shows the usual changes due to catarrh. Membranes as much as an inch in diameter, and consisting of the epithelium and blood-corpuscles, are, with larger or shorter intervals, sometimes as often as twice a week, found lying loose in the vagina, or are easily detached from it without causing bleeding. At other times the membranes consist of coagulated fibrin, including blood-corpuscles and epithelial cells.

Astringents make the condition worse. General treatment, especially with bromide of potassium in large doses, has had better effect.

Emphysematous Vaginitis (*Colpohyperplasia cystica*—Winckel).—

[illegible] disease is frequent enough to have [illegible] different gynecologists, and some have [illegible] prominent gynecologist of this city has [illegible] he was consulted about a case of this [illegible] what it was. It is characterized [illegible] part of the vagina and on the vaginal [illegible] pink, gray, or blueish, soft cysts, [illegible] to a hazelnut. They are situated [illegible] fluid, and often gas. Some have a [illegible] they give a crackling sensation like [illegible] gas escapes with a distinct wheezing [illegible] The disease is most common in preg- [illegible] but always in women suffering [illegible] It does not give rise to any symp- [illegible] of the speculum is painful, and it [illegible] childbirth.

[illegible] where the gas is found, whether in the [illegible] lymph-follicles, or lymphatic vessels; [illegible] condition is caused by stasis in veins [illegible] blood, and decomposition of the same, [illegible] atmospheric air should be drawn in and [illegible] of the entrance seems hardly pos-

[illegible] no treatment is needed, since the [illegible] disappears after childbirth. In others [illegible] dilute hydrochloric acid (1 per cent.) [illegible] on the affected parts, or use injections [illegible] or corrosive sublimate.

[illegible] of fungi may grow in the vagina— [illegible] *Oïdium albicans*. Leptothrix con- [illegible] spores. Oïdium has hair-like branches. [illegible] as the one forming thrush in the

[illegible] rise to hardly any discomfort. Oïdium [illegible] a burning sensation, swelling, dis- [illegible] The disease may end in a few days, but [illegible] months, especially in pregnant women. [illegible] vagina is red, tender, and studded with [illegible] only be removed together with the epi- [illegible] scope prove to be composed of hyphæ

[illegible] pregnancy predispose to the development [illegible] brought in during coition with men [illegible] which frequently is accompanied by [illegible] the prepuce and the gland. They may

also be carried on fingers that have handled flour—*e. g* those of millers or bakers.

Prognosis.—The prognosis is good, and the disease can be cured in a fortnight.

Treatment.—Frequent vaginal injections with sulphate of copper (1–2 per cent.), salicylic acid (1–2 per thousand), carbolic acid (3 per cent.), creolin (1 per cent.), or corrosive sublimate (1–2 per thousand). The last-named substance should not be used in pregnant women, on account of the danger of absorption (p. 199). The same solutions may be used for swabbing the vagina through a speculum. Warm sitz-baths, with addition of a little soda or borax, or injections with flaxseed tea and similar emollient substances, are particularly indicated in the beginning, if the inflammation is more acute.

B. *Exudative Vaginitis.*—A fibrinous exudation takes place on the surface or in the mucous membrane of the vagina. It makes its first appearance as discrete spots not larger than millet-seeds, but soon these spots extend in all directions and melt together, so as to form one or more large, thick patches. The parts surrounding the patches are more or less swollen, dark red, brown, or dirty greenish.[1]

It is not settled whether this condition is identical with the process that takes place in the throat in the disease called diphtheria or not.

Etiology.—It is the most common form of puerperal infection. It appears also in severe general diseases, such as typhus, small-pox, and measles. Gonorrhea rarely gives rise to it. Local irritants, such as too strong injections of bichloride of mercury, may cause it.[2]

Prognosis.—When due to local irritation exudative vaginitis is of slight importance; when symptom of a general disease, it is a sign of serious systemic disturbance; and when caused by local infection during childbirth or in the puerperium, there is imminent danger of general infection, which may end in death.

Treatment.—If the condition is due to local irritants, they must, as far as possible, be removed and mild healing substances, such as vaseline, glycerate of tannin, a weak solution of borax, used for application or injection.

If it appears as result of local infection, an entirely different course should be followed. In my experience the best practice is to use cauterization with chloride of zinc dissolved in equal parts of distilled water. Others use pure carbolic acid, Monsel's solution of subsulphate of iron mixed with glycerin, tincture of iodine, iodoform, etc.

When it is a part of a general systemic infection, the preparations

[1] For further details see Garrigues, "Puerperal Diphtheria," *Trans. Amer. Gyn. Soc.*, 1885, vol. x. p. 96.

[2] Garrigues, "Corrosive Sublimate and Creolin in Obstetric Practice," *Amer. Jour. Med. Sci.*, 1889, vol. xcviii. p. 115.

[illegible] may be used locally in connection with general

[illegible]—This is a variety of exudative vaginitis, [illegible] suffering from chronic dysentery, and [illegible] through which the dysenteric process [illegible] of the vagina. Small gray membranes, [illegible] epithelium, and superficial ulcers surrounded [illegible] blood-vessels, form on the mucous [illegible] the epithelium are found layers of micro-

[illegible] the affection of the intestine—espe- [illegible] astringent medicines, injection with a [illegible] of bismuth in a cupful of boiled starch, or [illegible] acid—the vagina must be treated as

[illegible]—Phlegmonous vaginitis is the inflam- [illegible] surrounding the vagina.

[illegible] most characteristic, is that known as [illegible] whole vagina, with the vaginal por- [illegible] by suppuration from the neighboring [illegible] Only a few cases of this affection [illegible] peared in the course of severe feverish [illegible] r, pneumonia, perhaps gonorrhea, and [illegible] mediately after menstruation.

[illegible] mplains of more or less intense pain. [illegible] The labia majora are swollen and the [illegible] The mucous membrane of the vagina [illegible] After the expulsion of the vagina the [illegible] nd considerable stenosis is liable to

[illegible] d in camphor emulsion—

[illegible]	℥ss;
[illegible] acaciæ,	℥j;
[illegible]	℥iv.

[illegible] wall—

[illegible] vagina until all necrosed tissue is separated. [illegible] be aided by cautious pulling and cutting of [illegible] After expulsion the surface should be dusted [illegible] with iodoform ointment, and stenosis should [illegible] by the use of tampons and the frequent introduction

[illegible] phlegmonous vaginitis is caused by the *burrow-* [illegible] *abscess*. For a time a fluctuating swelling is [illegible] wall of the vagina, and later this opens into

the vagina or the rectum. Often fistulous tracts remain for a long time, and the suppuration may finally exhaust the patient's strength and lead to her death.

Treatment.—An abscess of the latter kind should be freely opened from the vagina as soon as felt. The cavity should be injected with antiseptic fluids and loosely packed with iodoform gauze. Later it may be necessary to dilate fistulous tracts with laminaria or the knife.

CHAPTER VIII.

Gangrene of the Vagina.

Etiology.—Gangrene of the vagina may be caused by the presence of foreign bodies—*e. g.* pessaries, or the contact with caustics—*e. g.* a tampon soaked in undiluted liquor ferri chloridi (p. 175). It may be due to pressure of the head of the child where, in consequence of mechanical disproportion between the child and the pelvic canal, impaction is allowed to take place. The most common locality of this occurrence is the upper part of the anterior wall of the vagina, which is caught between the head of the child and the symphysis pubis, and leads after the separation of the necrosed plug to the formation of a vesico-vaginal fistula.

Gangrene of the vagina, like that of the vulva, may appear in conjunction with noma, and is then perhaps due to direct transmission of toxic material from the cheek to the genitals. It may also be brought about by diptheritic vaginitis (p. 341).

Morbid Anatomy.—The whole mucous membrane, inclusive of that covering the vaginal portion of the uterus, may be changed to a black, pulpy malodorous mass, and the destruction may extend more or less into the depth of the underlying tissue.

Symptoms.—Gangrene is accompanied by pain, dysuria, inability to walk, and sometimes hemorrhage, which may even become fatal. Fever is not always present.

Treatment.—The vagina should be injected with solutions of carbolic acid, creolin, or acetate of alumina (1 per cent.), and a tampon with the above-mentioned camphor emulsion (p. 342) or a saturated solution of chlorate of potash left in it. Dead tissue should be removed as soon as feasible. The granulating surface should be dusted with iodoform or smeared with iodoform ointment, and care taken to obviate stenosis (pp. 321–322). The general treatment consists in a liberal use of stimulants, tonics, and a nourishing diet.

CHAPTER IX.

Erysipelas of the Vagina.

In a patient who died of general erysipelas the affection had spread to the vagina. The entire mucous membrane was red, swollen, wrinkled, and studded with vesicles, and in some places the epithelium had been thrown off.

Treatment.—If the erysipelatous inflammation is discovered in time, the vagina should be cleaned with creolin injections and dusted with iodoform in conjunction with the general treatment of erysipelas.

CHAPTER X.

Cicatrices.

The vagina is often the seat of cicatricial tissue, resulting from inflammation, ulceration, or gangrene.[1]

Etiology.—The most common cause is a laceration and sloughing occurring in childbirth. Cicatrices may also be formed by the use of caustics—*e. g.* chloride of zinc for diphtheritic ulcers (p. 341). Unsuccessful plastic operations, where large surfaces heal by granulations, leave also large scars.

Symptoms.—The presence of such cicatricial tissue may give rise to pain, which, although the lesion is permanent, may be intermittent or remittent. This pain is probably due to irritation of fine nervous fibrillæ enclosed in the scar. By reflex action neighboring organs often become painful, so that the patient suffers from dysuria and dyschezia; but reflex neuroses may also appear in remote parts of the body—*e. g.* in the pit of the stomach, under the left breast, etc. Cicatricial bands extending between the walls of the vagina or between them and the vaginal portion of the uterus, or ring-shaped contraction of the vagina, may cause dyspareunia, and, when the constriction is considerable, even dysmenorrhea. The condition may end in complete atresia with all its consequences.

The cicatricial band may frustrate the use of vaginal pessaries, and place serious obstacles in the way of success in operating for vaginal fistulæ.

The scar tissue is harder, less elastic, of lighter color than the normal vaginal wall, and has a smooth surface. During pregnancy

[1] A valuable paper on this subject by Skene, with important remarks by T. A. Emmet, is found in *Trans. Amer. Gyn.*, 1876, vol. i. p. 91, *et seq.*

it softens very much, so that even extensive scars need not give trouble in a subsequent childbirth.

Treatment.—As prophylaxis care should be taken, in employing caustics, not to use them on larger surfaces nor to a greater depth than is absolutely necessary. To prevent the formation of these cicatricial bands after childbirth by the use of sutures is hardly feasible, since they are formed on bruised and sloughing tissues which could not be united in that way. Sometimes a judicious use of tampons or dilators during the healing of a suppurating surface may, however, limit the evil considerably.

The curative treatment has recourse to three methods—incision, excision, and insertion of flaps of healthy tissue. A projecting thin band may simply be severed.

If the cicatrice is imbedded in the tissue like a cord and is not too extensive, it may be cut out, and the edges united with sutures. If it is very long, it is divided into sections; the edges of which are separated half an inch or more if possible, and healthy tissue brought in between from each side to fill the gap, where it is secured by interrupted sutures.

If the cicatricial surface is spread out and superficial, it is to be snipped through with the points of a pair of scissors at regular intervals. Another parallel column of incisions is formed in the same manner, but in such a way that the cuts are placed opposite the spaces between two and two incisions in the first column. Thus the whole surface is gone over and kept on the stretch during the healing process by means of a glass plug (p. 321), or better by Bozeman's vaginal dilators, consisting of cylinders of hard rubber with rounded ends and attachment for a string. Others recommend slippery-elm bark made into a roll and beaten till it is soft. Before introduction it is dipped in carbolized water (1 per cent.). It swells slowly and promotes healing.

CHAPTER XI.

VAGINISMUS.

VAGINISMUS consists in a painful tetanic contraction of one or more muscles surrounding the vagina.

According to its seat it may be divided into two species—*superficial* and *deep* vaginismus. The superficial has its seat at the entrance of the vagina (see p. 43), probably in the bulbo-cavernosus muscle. The deep is a spasm of the levator ani muscle. The superficial is commonly found in women with an intact hymen, the disease itself

preventing sexual connection, but may be developed in women who have even borne children.

Etiology.—Nearly always some palpable local disease is found in the genitals or the neighboring organs, such as an inflamed hymen, irritable carunculæ myrtiformes, fissures of the fourchette or vaginal entrance, a neuroma of the fossa navicularis, a urethral caruncle, a fissure of the neck of the bladder or of the anus, vulvitis, vaginitis, a granular os uteri, endometritis, displacement of the uterus, or pelvic inflammation. An unusually large male member or awkwardness in its use may bring about some of the above-named conditions, and thus be the cause of the disease, but more frequently the underlying fault is a nervous disposition and fear of pain in the female. Lead-poisoning is also said to produce vaginismus.

Symptoms.—In superficial vaginismus it is not only the attempt at coition that brings on a spasm of the muscles surrounding the vaginal entrance, which closes it against the introduction of the penis, but the spasm is observed when the physician tries to make a digital examination or introduce a speculum; nay, the slightest touch with a feather or a camel's-hair brush or the introduction of a catheter into the urethra may suffice to bring about the tetanic contraction. Sometimes the sphincter ani muscle may enter into a similar condition, or even general convulsions of the whole body be added. I have seen opisthotonus arise which would have sufficed to throw any man aside.

Deep vaginismus also called *penis captivus*, is a much rarer affection, consisting of a similar spasm in the depth of the vagina. It occurs during coition or during a digital examination. No difficulty is experienced at the vaginal entrance, but in the depth of the tube a resistance is met with in the shape of a tetanically contracted circular band, which prevents further progress. If the spasm occurs after full introduction of the penis, the corona is encircled, and the attempts to withdraw the penis cause great pain to both participants in the act.

Prognosis.—If neglected, vaginismus is a source of great physical and moral misery; if properly treated a cure may always be effected.

Treatment.—If one of the above-named causes is found, it must first of all be removed. Fissures of the hymen, vaginal entrance, or anus are best treated with pledgets soaked in a 4 per cent. solution of chloral hydrate. Others recommend ointments with opium, belladonna, or other narcotics. Neuromata, urethral caruncles, and carunculæ myrtiformes are snipped off with curved scissors. A fissure of the neck of the bladder is treated with overdistension, cocaine bougies left to melt in the urethra—

℞. Cocainæ hydrochlorat., gr. xij;
Ol. theobromæ, q. s.
M. Ft. bacilli, No. xii,
Sig. One morning and evening—

and application of a strong solution of nitrate of silver. In regard to the other affections named, the reader is referred to the chapters in which they are discussed.

Much benefit may be derived from the use of warm hip-baths, suppositories with iodoform (gr. v), atropine ointment (gr. ij to ℥j), and the application twice a week of a solution of nitrate of silver (gr. x or xx to ℥j) to the vulva and hymen, followed by cold, and later lukewarm, applications.

The galvanic current, with the soothing positive pole on the affected parts, has given good results.

The general treatment is of the very greatest importance, and its aim must be to brace the patient up physically and morally. If feasible, she should be separated for a time from her husband, and, at all events, all attempts at sexual intercourse must be strictly forbidden. She should have pleasant surroundings, cheerful company, and much exercise in the open air, preferably on horseback. She should take a regular course of gymnastics tending toward muscular development of other parts and control over the nerves. Hydrotherapy is also very useful in drawing away the abnormally concentrated sensibility from the genitals.

If these two lines of treatment, removal of the cause and general tonic treatment, do not lead to a cure, sharper local treatment is required. The patient is anesthetized and the vaginal entrance forcibly distended with two fingers or a plurivalve speculum. As after-treatment a vaginal glass plug (p. 321) is used morning and evening for a couple of hours.

Sometimes the removal of a fleshy, resistant. hyperesthetic hymen by means of a pair of curved scissors will promptly lead to a complete recovery. In other cases it is necessary to follow this operation up with incision of the vaginal entrance.

The simplest way of doing this is to insert a Sims speculum under the pubic arch, put a finger into the rectum, press the sphincter ani up against the posterior vaginal wall, and divide with scissors on each side of the median line the fibers encircling the vaginal entrance, leaving a space of three-quarters of an inch between the two incisions (T. A. Emmet).

Another mode of incision is to imitate the tear in the median line through the perineal body that often takes place in childbirth (T. G. Thomas).

Sims's operation is a very bloody one, and may with advantage be replaced by one of the two already mentioned. After excision of the hymen the left index and middle fingers are introduced into the vagina and spread out, so as to dilate the vagina as much as possible and put the posterior commissure on the stretch. Next a deep incision is made with a scalpel through the vaginal tissue on one side of

the median line, downward and inward, ending in the raphe of the perineum. This incision forms one branch of a Y. Then the knife is reintroduced into the vagina, which is yet kept dilated by the fingers, and a similar incision is made on the other side from above downward and inward. These two incisions are united in or near the raphe, and prolonged as a single incision to the integument of the perineum. Each of these incisions will be about two inches long—namely, half an inch above the edge of the bulbo-cavernosus muscle, half an inch across its fibers, and an inch from its lower edge to the skin of the perineum. The glass plug is introduced immediately, and effective compression exercised by means of compresses and a T-bandage.

Neurotomy of the pudic nerve in the perineum has been advised, but reference to the anatomical description (p. 107), will show that not even its main branch, the perineal nerve, is within reach. The branches of the latter may indeed be cut by deep lateral incisions, but the danger of a hemorrhage hard to control is very great, and simply severed nerves grow easily together.

The *deep vaginismus* is treated by attention to the cause, especially a granulated os, by the same general treatment as recommended for the superficial form, and to overcome the spasm that keeps the penis captive the introduction of a finger into the rectum has been recommended. All attempts at violent separation must be desisted from. The captive has to remain imprisoned until the subsidence of the spasm or erection allows an easy withdrawal. If ether is available, the mere administration of it would probably end the spasm, even before anesthesia is produced.

CHAPTER XII.

NEOPLASMS.

1. *Cysts.*[1]—Cysts are rather frequently found in the vagina. As a rule, the patients are adults, but congenital cysts have been seen in the vagina of new-born children. Commonly these cysts are single, but occasionally two or more are found in the same individual. They are most frequently situated on the anterior wall. They are globular or oblong, mostly sessile, but may become pedunculated and hang out from the vulva. They grow very slowly, and have often been observed for many years. They vary in size from that of a pigeon's egg to that of a goose egg, but may exceptionally reach the size of the fetal head at term.

[1] An exhaustive paper on the subject by Dr. G. W. Johnston of Washington, D. C., can be found in *Amer. Journ. Obst.*, 1887, vol. xx. p. 1121.

The *wall* varies in thickness from half a millimeter ($\frac{1}{50}$ inch) to a centimeter ($\frac{2}{5}$ inch). It is composed of connective tissue, and sometimes muscle-fibers. The inside may be lined with simple or ciliated columnar or flat epithelium, or be without epithelium.

The *contents* may also vary very much. They may be serous, yellowish, purulent, or thick and chocolate-colored. Sometimes they do not contain form-elements; in other cases we find blood-corpuscles, pus-corpuscles, oil-globules, granular cells, epithelial cells, or cholesterin crystals.

As a rule, the mucous membrane covering the cyst is freely movable and normal, but sometimes is becomes atrophic. The cysts may burst spontaneously with or without suppuration, or be ruptured by injury, especially childbirth. The contents may be discharged into the vagina, the bladder, the urethra, or through the perineum.

Vaginal cysts may have a very different origin. They may be formed by condensation of the perivaginal connective tissue round an extravasation of blood. They may be retention cysts, due to closure of the outlet of the glands of the mucous membrane which some observers have found (p. 44). Some have been explained as dilated lymphatics. Another theory is that some are developments of part of one of the Müllerian ducts which has failed to unite with its fellow in the formation of the vagina. Some are most likely formed in Gartner's canal.[1] Perhaps some are developed from periurethral glands.

Symptoms.—If these cysts are small they may not give rise to any symptoms, and are discovered accidentally during delivery or gynecological examination instituted for other purposes. If they are of considerable size, they cause dyspareunia and a bearing-down sensation. They may also cause leucorrhea, dysuria, and dyschezia. Sometimes they are fluctuating.

Prognosis.—Many of them give no trouble; they grow slowly or become stationary; if necessary they can easily be removed.

Diagnosis.—*Cystocele* may resemble a cyst very much, but the swelling disappears when a catheter is introduced into the bladder. In *emphysematous vaginitis* there is a large number of small cysts in the fornix, and on being punctured they are found to contain gas. Cysts of the vagina are single or few in number, of larger size and filled with a fluid. From *solid growths* they differ by their fluctuation or elasticity, or by yielding fluid when exploratory puncture is resorted to. *Hydatids of the pelvis* are filled with a clear, colorless fluid without albumin, containing the characteristic hooklets, or perhaps a piece of cuticula with its pathognomonic parallel structureless layers.

[1] Garrigues's report on a cyst extirpated by Dr. R. Watts, *Amer. Jour. Obst.*, 1881, p. 849, and a note on Gartner's canals in *New York Med. Jour.*, March 31, 1883, vol. xxxvii. p. 348.

Treatment.—The best way is to extirpate them and unite the edges by suture. In order to facilitate the extirpation if the wall is thin, they may be emptied and injected with melted spermaceti, which is thereafter solidified by the application of ice.[1] But their relation to the bladder may be so intimate that we would risk cutting into that viscus. Under such circumstances partial excision of the wall is preferable. The most prominent point is seized with tenaculum-forceps or volsella and the anterior wall of the cyst cut off with the covering mucous membrane of the vagina, leaving the bottom of the cyst undisturbed. In order to arrest hemorrhage and avoid suppuration the edges of the mucous membrane may be sutured to those of the cyst (Schroeder's method), the wall of which changes character and becomes like the rest of the vagina. It may also simply be left, and is later exfoliated. During this process antiseptic injections should be used.

2. *Fibroids* (*Fibroma*, *Myofibroma*, *Fibromyoma*).—Fibrous tumors of the vagina are rather rare, especially when compared with their frequency in the uterus. Their most common seat is the upper part of the anterior wall. They are very rarely pure fibroids; that is to say, composed of connective tissue alone. As a rule, this tissue is intermixed with a greater or lesser amount of unstriped muscular fibers. Their starting-point may be in the submucous or perivaginal connective tissue or in the muscular coat of the vagina. Sometimes a fibroid in the recto-vaginal partition is in reality a uterine fibroid that has developed downward, just as, on the other hand, a true vaginal fibroid may extend into the vulva.

According to the predominance of the connective or muscular element, these tumors are harder or softer. Like similar tumors of the uterus, they may undergo a softening by accumulation of serous fluid in the meshwork of their interior.

Originally they are globular sessile tumors imbedded in the wall of the vagina, but when their weight increases they have a tendency to become pedunculated, and may then even protrude through the vulva. Such pedunculated tumors are called *fibroid vaginal polypi*. Exposed to the air and friction of the clothes, they may begin to ulcerate on the exposed surface. In the lower part of the vagina they often become intimately adherent to the urethra.

As a rule, they are single.

Etiology.—They may be small as a pea, but they may also become quite large and weigh up to ten pounds. Their growth is a very slow one, and may extend over many years. They are commonly found in adults, but may occur in children. The cause that produces them is unknown.

Symptoms.—When small they give rise to no symptoms, and are

[1] Pozzi's method. (Compare p. 282.)

found accidentally. When they increase in size they cause leucorrhea. When they become still larger and heavier, they cause a dragging sensation, dyspareunia, dysuria, dyschezia, and may oppose a very serious obstacle to childbirth. Sometimes they are accompanied by severe hemorrhage.

Diagnosis.—When small or middle-sized, they are easy to diagnosticate by their elastic hardness. It is true, a thick-walled *cyst* gives a somewhat similar sensation, but all doubt may be dispelled by means of an aspirator. When they are large enough to fill the vagina, it may be difficult to differentiate them from uterine fibroid polypi. If it is possible to reach the os, this will be found undilated, and no pedicle passes out through it. From *sarcoma* a fibroid is distinguished by its slow growth; it does not undermine the constitution; and the microscopical structure is entirely different.

Prognosis.—The prognosis is favorable. Small fibroids give no trouble. They grow slowly, and if necessary they can be removed by operation. When they suppurate, there is, however, danger of septicemia.

Treatment.—A *pedunculated* fibroid may be removed by tying an elastic ligature around the pedicle, which will be severed in a few days. Or it may be cut at once with an écraseur or a galvano-caustic snare, or transfixed with a needle armed with a strong double silk ligature, which is cut in the middle, and the two halves crossed and tied on either side, when they are interlocked like the links of a chain. Finally the tumor is cut off. Any of these methods prevents hemorrhage.

A *sessile* fibroid is removed by making an incision over its longest diameter and enucleating it. In order to avoid hemorrhage, fingers and blunt instruments should be used as much as possible. The galvano-caustic knife or the thermo-cautery may occasionally be used to advantage when there is much hemorrhage. If the tumor is large, a part of the mucous membrane covering it is included between two curved incisions blending at their ends, and left on the tumor. After plain enucleation the edges of the wound are brought together with deep sutures. Otherwise the wound must be packed with iodoform gauze.

3. *Mucous Polypi.*—Rarer than the hard fibroid polypi are soft growths of similar shape, in structure like the mucous, or glandular, polypi so common in the cervical canal. They give rise to the same symptoms as fibroid polypi. They are very vascular, and the safest way to remove them is, therefore, by means of the elastic ligature or by transfixion of the pedicle, as just described.

4. *Sarcoma.*—This is a rare disease. It appears in two forms—one *circumscribed*, forming interstitial globular tumors like fibroids; the other *diffuse*, extending along the surface like carcinoma.

It has been noticed that of the small number of cases recorded comparatively many have occurred in early childhood.

In the circumscribed form the development is slower, and may take a couple of years, but, as a rule, the malignancy of the tumor reveals itself by its rapid growth.

The *prognosis* as to a complete cure is very doubtful, as this affection has great tendency to relapse even after complete extirpation.

Symptoms.—In adults they are insignificant in the beginning. Later there are leucorrhea, hemorrhage, dysuria, and sensation of pressure. The tumor ulcerates and discharges a sanious fluid. The neighboring organs become implicated, and the general health is undermined. In children the symptoms referable to pressure on the organs in the pelvis soon become pronounced.

Diagnosis.—The diagnosis from *fibroid* and *carcinoma* can only be made by microscopical examination.

Treatment.—Circumscribed tumors are extirpated like sessile fibroids (p. 351). The diffuse form may be kept in check for a time by curetting and cauterization with thermo- or galvano-cautery, or chloride of zinc as in cancer of the uterus.

5. *Carcinoma.*—*Primary* carcinoma of the vagina is a rare disease. As a rule, it is *secondary*, either propagated by continuity from neighboring organs, especially the cervix uteri, or appearing as *metastatic* deposits from carcinoma in remote parts.

It is found in two forms, either as a *circumscribed papillary* growth, and then it is epitheliomatous in structure, or as a *diffuse* carcinomatous infiltration, which again may have the *medullary* or *scirrhous* type. The diffuse form affects sometimes the shape of a ring.

The cause is unknown. The disease is rarely found before the age of thirty years.

Cancerous tumors develop rapidly. The center ulcerates while the periphery spreads over the neighboring tissues. In consequence of the central breaking down, fistulous communications with other canals may be formed, the most frequent of which is a recto-vaginal fistula. The lymphatic glands in the pelvis and at the groin soon swell.

The chief *symptoms* are the sanious, dirty, ill-smelling discharge from the ulcer, hemorrhage and pain, to which may come the common symptoms due to pressure and obstruction, dyspareunia, dysuria, dyschezia, and dystocia.

Diagnosis.—The broad basis, the friable substance, and the hemorrhage caused by touch are characteristic. The friability, the ulceration, and the hemorrhage serve to distinguish the papillary epithelioma from simple papillomatous *vegetations* (p. 269). From *sarcoma* carcinoma can only be distinguished by means of a microscopical examination. In regard to treatment the distinction between primary and secondary carcinoma is of great importance. Bearing in mind that

the vagina is rarely the original seat of carcinoma, we must carefully examine all neighboring organs from which it may have spread, and even other organs from which germs may have been detached and carried to the vagina.

Prognosis.—The disease, as a rule, has made so much headway before it comes under treatment that a radical cure is impossible. Even after seemingly complete extirpation relapse is common. The whole body is gradually infected, and the disease soon ends in death.

Treatment.—If there is any possibility of operating in healthy tissue, the whole tumor should be *extirpated* and the wound closed by sutures, which both will arrest hemorrhage and bring about union by first intention. In this respect it is advised not even to abstain from excising parts of the bladder and the rectum, the edges having good tendency to unite if properly brought together by sutures.

In most cases only a palliative treatment can be attempted, but life may be prolonged and sufferings alleviated by a judicious use of the sharp curette, thermo- or galvano-cautery, chloride of zinc, or bromine, applications or injections of chloride of iron, creolin injections, tonics and narcotics, in which respect the reader is referred to the chapter on Carcinoma of the Uterus.

6. *Tuberculosis.*—Tuberculosis of the vagina is much more common than that of the vulva, but is still rather rare. It forms ulcers on the posterior wall of the vagina, owing to stagnation of infecting material from the uterus, the disease in the vast majority of cases being only found in connection with tuberculosis of that organ. Miliary nodules, ulcers, and caseous masses are visible in the vagina and on the vaginal portion of the uterus, and the microscopical examination shows the presence of bacillus tuberculosis. Tuberculous ulcers form easily fistulæ opening into the bladder, the urethra, or the rectum. The tuberculous nature of these fistulæ is revealed by the presence of nodules and bacilli around their opening.

Such fistulæ must be cut out in a wide circumference. Operations for their closure offer scant hope of success. For further information the reader is referred to what has been said about the same affection in the vulva (p. 280).

CHAPTER XIII.

FISTULÆ.

Definition.—A fistula is an abnormal opening leading from the genital canal to the urinary tract or the intestines.

In a more limited sense the word is only applied to such openings the edge of which is covered with epithelium, leaving out fresh

wounds extending from one canal to the other, or ulcers eating their way through the partition between them.

Pathological Anatomy.—According to the nature of the extraneous matter that finds its way through the fistulæ into the genital canal they are divided into *urinary* and *fecal* fistulæ.

A. *Urinary fistulæ* are again divided, according to the organs through which the fistula goes, into (1) *vesico-vaginal*, (2) *urethro-vaginal*, (3) *uretero-vaginal*, (4) *vesico-uterine*, (5) *vesico-utero-vaginal*, (6) *uretero-uterine*, and (7) *uretero-vesico-vaginal*.

There may be one or more fistulæ, and in size they vary from a scarcely perceptible aperture to an opening measuring two inches in diameter.

1. *Vesico-vaginal Fistula.*—The most common urinary fistula is the *vesico-vaginal* variety. The following description applies, therefore, more particularly to it, and the peculiarities of the rarer forms will be mentioned later on.

Etiology.—By far the most common cause of fistula is *childbirth*. The mechanism may be twofold. The abnormal communication may be due to a tear, and appear immediately after delivery, or it may be due to pressure with consequent necrosis, and not be developed before several days or even weeks have elapsed since parturition took place. Tears are especially found in old primiparæ or after the use of ergot or in cases in which the forceps was applied before the cervix was sufficiently dilated. Pressure is due to a disproportion between the child and the genital canal, a distended bladder, a loaded rectum, a stone in the bladder, abnormal presentations, etc. In this connection it must be noted that the tissues withstand much better the same degree of pressure if it is exercised for a shorter time. Fistulæ from pressure are, therefore, as a rule, not due to the use of forceps, but to improper delay in their use. As soon as the presenting part becomes impacted and does not move to and fro during and between labor-pains, artificial help ought to be given immediately. In consequence of the improved midwifery and the much more frequent use of the forceps fistulæ have become much rarer now than they used to be, and come mostly from remote localities where proper assistance is not available.

Fistulæ are sometimes due to *operations*, not only the bungling attempt of the ignorant abortionist, but also in legitimate operations performed by skillful operators. Thus the formation of a vesico-vaginal fistula is a not uncommon accident in vaginal hysterectomy—*i. e.* the removal of the uterus.

In rare cases *foreign bodies*, such as a pessary in the vagina or a stone in the bladder, have gnawed a hole through the partition between the urinary and genital tract.

A *pelvic abscess* opens sometimes in such a way as to give rise to a urinary fistula.

Symptoms.—The chief symptom is the more or less constant dribbling of urine from the vagina, but this does not suffice for a diagnosis, as the same takes place if the sphincters of the urethra are lost or paralyzed, and, on the other hand, if the urinary fistula is situated high up, the urine may be retained for a long time in the erect posture, and in urethro-vaginal fistula it may be entirely retained except during voluntary micturition.

In spite of the utmost cleanliness fistula patients have a disagreeable ammoniacal odor. If the fistula is large, it may be felt by digital examination.

In most cases it can be seen by introducing a speculum and placing the patient in different positions, especially Sims's, the genu-pectoral, and the dorsal with elevated pelvis (p. 193).

Sometimes, however, the opening is so minute that it cannot be discovered, or it may be hidden by a projecting cicatrix. By injecting a colored fluid—for instance, milk—into the bladder the presence of a vesico-vaginal fistula may be established. A good way of finding a minute opening is to cover it with a piece of linen. Urine will go right through it and make it wet (Bozeman). Sometimes it cannot be made visible and accessible before intervening cicatricial bands are cut and distended (p. 345).

Prognosis.—Small fistulæ heal sometimes spontaneously, even after a number of years. A later pregnancy has been seen to effect a cure. Until Sims's time most urinary fistulæ were, however, practically incurable. Now, on the contrary, the operations have been brought to such a degree of perfection that very few resist treatment. It is, however, quite frequent that two or more operations are needed before complete success is obtained. With proper care the danger of the operation is very small.

Treatment.—The remedies at our command are cleanliness, cauterization, and closure by means of suture, either at the fistula or at a more or less remote point.

1. *Cleanliness.*—A fresh fistula, even of considerable size, may be much diminished, and sometimes closed altogether, by giving hot vaginal injections and using remedies that render the urine normal. As it has a tendency to become alkaline and deposit phosphates, acids are indicated, especially benzoic, boric, nitric, and phosphoric.[1]

Phosphatic incrustations should be removed mechanically, and the parts lubricated with vaseline or zinc ointment. Raw sur-

[1] Dr. Emmet recommends Acid. benzoici ʒij, Sodii borat. ʒiij, Aqu. ℥xii.—M. Sig.: A tablespoonful in water three or four times a day. When the urine has become acid the dose should be reduced. The benzoates of ammonium, lithium, or sodium (gr. v–xxx have the same effect. I have also seen good effect of a saturated solution of boric acid, a tablespoonful four times a day; 8 drops of dilute nitric acid in a medicine four times a day; and Horsford's acid phosphates, a teaspoonful in a wineglass of water, three times a day.

faces are brushed over with a solution of nitrate of silver (gr. x to ℥j) twice a week. Sitz-baths, once or twice a day, are also very useful.

2. *Cauterization.*—This method is little used now-a-days, since the perfection of the closure by suture. It may, however, be tried for small fistulæ, and is often used successfully, when a small opening remains or forms in a stitch-canal after the operation by suturing.

The part is rendered senseless by means of cocaine (p. 203). The galvano- or thermo-cautery may be used. Among chemical caustics, the nitrate-of-silver stick, nitric acid, carbolic acid, and tincture of cantharides are the best. The cauterization ought not to be repeated until granulations have developed, and do not grow any more. The effect of the cauterization is much enhanced by the use of a permanent catheter.

3. *Closure by Suture at the Seat of the Fistula.*—This is the most reliable and satisfactory of all methods. We must consider separately the preparatory treatment, the operation, and the after-treatment, all of which are of great importance in effecting a cure.

The best time for operating is six or eight weeks after confinement. Before that period spontaneous closures might take place or cauterization might suffice for the purpose. The lochial discharge would be unfavorable for healing by first intention, and the sutures would be more liable to cut through the friable tissue. Later the bladder contracts and cicatrices become harder.

The *preparatory treatment* consists in the same measures we have just mentioned under the heading of Cleanliness—namely, hot vaginal douches, sitz-baths, acid medicines, removal of incrustations, the use of mild ointments, and painting with astringents. Hairs that are incrustated with urinary deposits are cut off. Cicatricial bands are cut with knife or scissors and the vagina dilated by the introduction of a Bozeman dilator (p. 345). When the first incisions are healed, new ones may be made and treated in the same way. By this combination of cutting and pressure not only room is gained, which renders the fistula more accessible, but the cicatrical traction which is a serious obstacle to agglutination is done away with.

This local preparation may occupy from three to five weeks or longer.

Of no less importance is the general preparation. The patient's general health should be improved as much as circumstances will permit. If the fistula is due to hysterectomy for cancer, it is not worth while trying to close it until sufficient time has elapsed to prove that the surrounding tissue is healthy. If the patient has syphilis, that should first be treated. Anemic patients should undergo a preparatory tonic treatment. Faults in the digestion should be remedied. Sometimes a sea-voyage or a sojourn in the country may be a great help in building up the debilitated constitution.

The operation is performed according to different methods, which may be divided into two groups: the *denudation* methods and the *flap-splitting* methods. To the first belong the methods of Sims, Bozeman, and Simon; to the latter those of Blasius (Tait), and Walcher.

Sims's Method.—The patient is placed in Sims's position (p. 135), Sims's speculum, or one of the self-holding modifications thereof (p. 145), is introduced. The most dependent part of the circumference of the fistula is seized with a tenaculum, and the edge cut off all around in one strip with scissors. In so doing we go close up to the mucous membrane of the bladder without implicating the same, as that causes troublesome and sometimes dangerous hemorrhage. If the denuded surface is not broad enough, a second strip is cut off from the vaginal mucous membrane outside of and contiguous to the first (p. 328). The edges should be brought together in that direction in which there is least tension. At the angles the denudation is carried far enough away from the fistula to include the folds of mucous membrane which will be formed when the edges of the fistula are brought in contact. Thus even a very small round hole may necessitate an elliptic denudation half an inch wide and an inch long.

Silver wire is used for suturing (pp. 199 and 210). It is pulled through with linen thread. Round, slightly curved needles made cutting near the point (p. 210), and 1 inch long, are best. They are introduced with Sims's needle-holder. If possible, the needle is seized below the eye, but if the fistula is being closed in a transverse line, the needle must be seized at its blunt end and held in the long axis of the needle-holder (Fig. 176, p. 208). The needle should be entered about a quarter of an inch from the edge of the denuded surface, brought deep into the tissue, pushed out just in front of the mucous membrane of the bladder, and carried through the corresponding points of the opposite lip. Five sutures are put in for each inch of line of union. As to the use of the counter-pressure hook, twister, suture-shield, and cutting of wires, the reader is referred to the general rules given above (pp. 211–212).

The patient is now turned on her back, the bladder washed out with a double-current catheter, and Sims's self-retaining, sigmoid, block-tin catheter with many small side openings introduced. This catheter should be bent so as to move freely behind the pubes as a key turns in a lock. Many now prefer soft-rubber or glass catheters.

After-treatment.—The patient should lie on her back, at times stretched out, at others with a round pillow under her knees. A dose of opium is given to relieve pain, and repeated daily in order to keep the bowels constipated until the sutures are removed. This is generally done on the eighth, ninth, or tenth day. The next day the bowels are moved by means of an aperient and an olive-oil enema (℥iv).

The catheter is taken out and cleaned several times a day. A

FIG. 210.



Bozeman's Operating Table.

small flat cup (a bird bathing-tub) is placed under it to catch the urine dripping from it. It is left in a few days after the removal of the sutures. The patient is allowed to sit up some time during the third week after the operation.

FIG. 211.

Bozeman's Speculum: *a*, surface of third blade which is applied to the vagina; *b*, a short plate which is pushed under the ends *c* and *d*, and thereby kept in place.

Bozeman's Method.—Bozeman places the patient in the knee-elbow position, in which she is retained by a special apparatus of his (Fig. 210). His speculum (Fig. 211), which allows one to operate with less

assistance and throws light into every part of the vagina, is introduced. The denudation is made perpendicularly, or so as to form a steep funnel, and comprises occasionally the mucous membrane of the bladder. He cuts with knife or scissors. He uses silver wires, but he secures them by means of his *button;* that is, a small concave plate of thin lead (Fig. 212) with a hole for each suture. The concave side is pressed against the wound, a perforated shot is pushed down over the two ends of each suture, and crushed with a forceps so as to serve as a clamp. The wires are cut at a short distance from the shot and turned down over its sides.

FIG. 212.

Bozeman's Button.

Bozeman uses permanent catheterization, and removes the sutures on the seventh day.

Simon's Method.—The patient is placed in the dorsal position, with raised pelvis and the legs drawn up—so-called *breech-back position,* because the breech presents as in deliveries with breech presentation. Large broad specula and retractors are used, according to circumstances, on the anterior, posterior, and lateral walls. The vaginal portion of the uterus is seized with a volsella and pulled down to the entrance of the vagina, where a couple of strong threads are drawn through it and used to pull on instead of the volsella. The edges are cut off with a knife perpendicularly or in a slightly slanting direction. The incision goes through the mucous membrane of the bladder. Fine silk is used for the sutures. These are of two kinds, deep *relaxing* sutures and superficial *uniting* sutures, which alternate with each other. From eight to ten are inserted for each inch of union. No catheter is left in the bladder. The patient may urinate herself if she can. Otherwise the urine is drawn with catheter every four hours. The bowels are kept loose. The patient may lie in what position she prefers, and eat every thing she likes. If easily accessible, the sutures are removed on the fourth or fifth day; in difficult cases they are left till the sixth or seventh day. On the eighth day the patient is allowed to get up.

The Suprapubic Method.—For fistulæ that cannot be reached in any other way Trendelenburg makes a transverse incision just above the symphysis pubis, through the abdominal wall. Next he makes a transverse incision in the bladder, if necessary all across. Then he denudes the edges of the fistula and inserts silk sutures, which he ties in the vagina, or catgut sutures, which he ties in the bladder.

Blasius's Method.—This is a flap-splitting operation which has been revived by Lawson Tait and others. Nothing is cut away. There is merely made an incision parallel to the vaginal and vesical mucous membrane. This incision is made on the white line of cicatrice at the edge to the depth of from one-eighth to three-eighths of

an inch, according to the thickness of the septum. If the fistula is small, it is surrounded by a suture like the string of a tobacco-pouch in the following way: a curved and eyed handled needle is introduced through the mucous membrane of the vagina a quarter of an inch outside of the lower end of the incision, and made to travel in the thickness of the vesico-vaginal septum in a curved direction, following the curve of the separation of the flaps till it comes to the opposite pole of the diameter of the fistulous opening, and then the point of the needle is made again to emerge into the vagina. The needle is now threaded and withdrawn, one-half of the fistula being thus embraced by the suture. The needle is again made to pass similarly round the opposite half of the fistula, the points of ingress and egress being identical with those of the first half of the proceeding. The needle is again threaded and withdrawn, and in this way the circumvention of the fistula is completed. When the thread or wire is drawn tight and secured, it will be found that the flap of vaginal mucous membrane is made to front into the vagina, and that of the vesical mucous membrane to front correspondingly into the bladder, whilst the raw surfaces between them are brought fully together.

If the fistula is so large that it is advisable to close it in a linear direction, the needle is made to enter the raw surface of the vaginal flap at the line of incision, burying it deeply in the tissue of the septum just beyond the point of division of the limbs of the V formed by the incision, and bringing it out on the corresponding point of the posterior limb of the same V. The needle is then threaded and withdrawn. Next, the needle is pushed in the same way through the two limbs of the V on the other side—*i. e.* the anterior and posterior flap; it is threaded with the distant end of the first thread and pulled back. When a sufficient number of such threads are placed parallel to one another, the sutures are closed. Tait uses always silver wire. He says it is generally much easier to insert the sutures by means of the forefinger guiding the needle without any speculum than with the assistance of the latter instrument.[1]

Walcher's Method (Fig. 213).—All cicatricial tissue is cut away, sparing as much as possible all healthy mucous membrane. When the cicatricial tissue is thoroughly removed the edges of the fistula acquire an astonishing mobility, and can be applied to one another without tension. On the place most remote from the field of operation, on the side turned toward the bladder, he makes a superficial incision around the cicatricial edge of the fistula Next he makes a similar incision around the cicatrix in the vagina, and then he cuts out the whole cicatrix as deep as possible. In some places larger cicatricial masses have to be removed; in others, where healing had taken place by first intention, the edge is simply split into an anterior

[1] L. Tait, *The British Gynecological Journal*, Nov., 1887, Part xi. p. 368.

and posterior flap. As long as there are immovable parts or parts moved with difficulty, the cicatricial tissue has to be removed or cut through. Finally the wall of the bladder becomes so movable that in many cases it can be pulled out through the wound like a loose sac. Now the vesical flaps are brought together in a line by a row of catgut sutures. He introduces the needle on the raw surface a quarter of an inch from the fistula, and pushes it out on the line of demarkation between the raw surface and the mucous membrane of the bladder, just comprising the latter in the suture (compare submucous sutures, p. 308). Next, the needle is carried through the corresponding points on the other side. When all the sutures are in place they are tied. After thus closing the bladder the vaginal flaps are united in a line above the other by means of silk sutures.

FIG. 213.

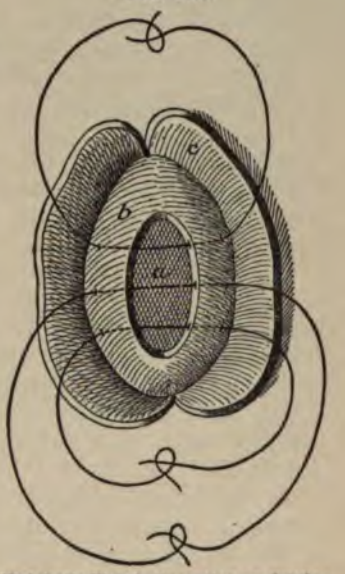

Walcher's Fistula Operation: *a*, fistula; *b*, bladder; *c*, vaginal wall rolled out.

Dangers and Difficulties.— With ordinary care there is not much danger of sepsis. In operations near the fornix the *peritoneal cavity may be opened*, an accident which used to be much dreaded, but now has lost most of its importance.

Primary hemorrhage may be quite considerable. Often it may be arrested by injecting hot or ice-cold water into the bladder and the vagina, or by temporary pressure, but sometimes it may become necessary to ligate an artery. This may be done by inserting a silver wire through the vaginal wall so as to embrace the bleeding vessel, which experience has shown usually comes from the neck of the bladder or the neck of the womb (T. A. Emmet).

Secondary hemorrhage is very rare. Bloodclots in the bladder should be broken up with catheter or dull-wire curette. Hot and ice-cold injections should be made. If these measures do not check the hemorrhage, the sutures must be removed and the bleeding vessel looked for and tied.

One of the greatest dangers in fistula operations is that of *injuring or ligating the ureters*. The first accident may lead to the formation of a uretero-vaginal fistula more difficult to heal than the original vesico-vaginal fistula. The ligation of a ureter leads to acute hydro-

nephrosis with high fever and vomiting. If the field of operation extends more than half an inch from the median line, the operator should look out for the ureter. Sometimes it can be seen at the edge of the fistula. Then the ureter must first be split open from the bladder to the extent of half an inch and the edges of the wound allowed to heal separately, so as to throw the mouth of the ureter further back into the bladder before the fistula is closed.

The operator should note the number of sutures he introduces and be sure to remove them all, as an overlooked or cut-off suture may form the nucleus of a *calculus* in the bladder.

When there is *great loss of substance* it is often impossible to unite the edges on one line. It may then become necessary to give to the line of union the shape of a Y, a T, or an H.

In large fistulæ it is also sometimes found advantageous not to denude the whole edge at once, but to *operate in sections*, paring and uniting one part before the next is taken hold of. In this way much blood may be saved and the field kept clean.

Long fine fistulæ in front of the cervix have been closed by freshening the surface with a dentist's engine, substituting cutting edges for the blunt ones, and approximating the vivified walls with deep sutures.[1]

If the fistula is *situated near the bone* the flap-splitting operations may hold out the best prospects for effecting a cure.

Before removing the sutures it may be well to *try if the fistula is closed* by injecting a little milk into the bladder. If the edges and stitches look healthy and there is a leakage, complete closure may be obtained by leaving the sutures in for a day or two longer.

Combination of Methods.—By a judicious combination of the best features of the operations described above an operator may obtain better results than by adhering tenaciously to the rules laid down by one of the inventors of methods. Preparatory cutting and stretching of cicatrices are of great importance. Bozeman's or Simon's position give sometimes better access to the fistula than Sims's. It is often impossible to pull the fistula down so as to operate near the vaginal entrance. The dislocation of the uterus may give rise to pelvic hemorrhage or inflammation. It is, therefore, better to operate in situ, and for this silver wire is much preferable to any other material. The largest speculum that finds room should be used, but, as a rule, the larger the fistula the smaller the speculum must be. The permanent catheter is liable to cause cystitis, which again interferes with healing by first intention. It is also very uncomfortable for the patient to lie constantly on her back. The introduction of a hard catheter has sometimes mechanically interfered with healing. If the bladder has retained a reasonable degree of capacity, it is better to let the

[1] Thomas, *Diseases of Women*, 6th ed. p. 274.

patient urinate or draw the urine with a velvet-eye, soft rubber catheter. But in large fistulæ with great retraction of the bladder the use of the permanent catheter is preferable. It is a decided advantage to keep the bowels open and let the patient take plenty of substantial food.

2. *Urethro-vaginal Fistula.*—In this kind, the wall of the septum being very thin, the denudation must be extended over the nearest part of the vagina. The edges are brought together from side to side over a metal catheter, and if the tension is great, an incision is made on both sides parallel to the line of union.

Atresia of the upper part of the urethra may be combined with a vesico-vaginal fistula. Then the closed canal may be perforated with a trocar and kept open by the daily use of sounds. Another method is to cut out the closed portion of the urethra and unite the lower to the neck of the bladder.

If the atresia is situated between a urethral and a vesico-vaginal fistula, the occluded position is bridged over by uniting the upper edge of the vesical fistula with the lower of the urethral, or if the loss of substance at the base of the bladder is so great that this cannot be done, or would cause so much tension on the urethra that incontinence would follow, an artificial transverse vesico-vaginal fistula is made just above the neck of the bladder, between the two other fistulæ. The upper edge of this artificial fistula is stitched to the lower edge of the urethral fistula, and after healing has taken place, the edges of the original vesico-vaginal fistula are brought together from side to side.

The whole urethra may be destroyed and restored by borrowing tissue from the surrounding mucous membrane (compare p. 247).

3. *Uretero-vaginal Fistula.*—Remembering the relations between the ureter, the neck of the womb and the fornix of the vagina (p. 81), we can easily imagine how a fistula may be formed between the ureter and the uterus or the ureter and the vagina, but it is fortunate such communications are rare, since they are difficult to cure.

A uretero-vaginal fistula is situated on the anterior wall of the vagina, a little below and outside of the vaginal portion of the uterus. It is distinguished from a vesico-vaginal fistula by introducing an elastic catheter, which, if the fistula is ureteral, can be pushed deep in in the direction of the corresponding kidney, and urine will be secreted in jets from it. Milk injected through the urethra will come out immediately through the fistula if it is vesico-vaginal, but will not pass through a ureteral fistula. Often that part of the ureter which is situate between the fistula and the bladder becomes obstructed. If under such circumstances the fistula were closed, acute hydronephrosis with all its dangers would be the result. The perviousness of the lower portion of the ureter is made out by introducing one probe through the fistula and an another through the urethra, which will

come in contact in the bladder if there is free communication between the fistula and that organ.

The *causes* of uretero-vaginal fistula are pressure during childbirth, the gnawing of a pessary, or the operation for a vesico-vaginal fistula, in consequence of which the ureter may be injured.

Treatment.—The fistula has been directly closed in different ways.

a. Bandl's Method (Fig. 214).—Bandl made an elliptic incision around the fistula in the course of the ureter, cut out some tissue at the

FIG. 214.

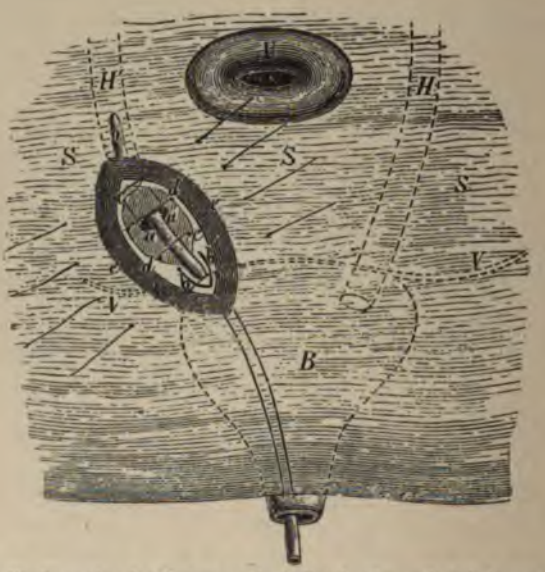

Diagram of Bandl's Operation for Uretero-vaginal Fistula (the patient is in genu-pectoral posture): SS, vaginal wall; V, line of union after closing a vesico-vaginal fistula in a previous operation, which had led to the formation of the uretero-vaginal fistula; B, bladder; U, vaginal portion of uterus; H, right ureter; H', left ureter opening at *a* into the vagina; *cc*, first incision; *de*, flat denudation in the vagina; *b*, artificial opening into the bladder.

lower end of this incision and made an opening into the bladder, pressing it out from behind with a sound. Next he introduced a fine flexible catheter (French No. 2) into the bladder through the urethra, drew its point with a forceps through the artificial opening made in the bladder, out into the vagina, and pushed it into the ureter. Next he denuded the vagina outside of the first line of incision and brought the raw surfaces together with four silver wire sutures, over the catheter. He used Bozeman's position, speculum, and button, and left another catheter in the bladder.[1]

[1] Ludwig Bandl, *Die Bozemansche Methode der Blasenscheidenfistel-Operation und Beiträge zur Operation der Harnleiter-und Blasenscheidenfisteln*, Wien, 1883, p. 42.

b. Schede's Method.—Schede cut out an oval piece with an area of three quarters of an inch square and having the opening of the ureter at its upper end, and stitched the vesical and the vaginal mucous membranes, together. Two weeks later he introduced a flexible catheter with the eye-end into the ureter and with the other into the bladder, whence he pulled it out through the urethra. Like Bandl he left a narrow strip of undenuded tissue round the ureteral fistula, denuded outside of this and closed the fistula.[1]

c. Pozzi's Method.—Pozzi used the flap-splitting method in a case of uretero-vesico-vaginal fistula. He placed the patient in the knee-chest position, made a transverse incision extending half an inch beyond the borders of the vesico-vaginal fistula and a perpendicular at each end so as to form an H. Next he dissected the two flaps off to a distance of half an inch, brought them together over the openings of both fistulæ with three deep silver-wire sutures and three superficial sutures.[2]

4. *Vesico-uterine Fistula.*—Fistulous communication between the urinary system and the uterus can only take place in the cervix. The other end of the fistula may be in the bladder or in the ureter, and it is of vital importance to distinguish between these two conditions. Common for both is the discharge of urine from the os uteri. The vesico-cervical fistula forms a small round hole opening in the middle of the cervix, a condition which has been brought about by imperfect healing of a tear through the anterior wall of the cervix and the base of the bladder.

Diagnosis.—Sometimes a probe can be brought from the bladder through the fistula into the cervical canal, where it comes in contact with a uterine sound held there. Milk injected into the bladder will come out of the os uteri. If the cervical canal is plugged with a laminaria tent, no systemic disturbance will result, while acute hydronephrosis is developed if it is a uretero-cervical fistula.

Prognosis.—This kind of fistula has an unusual tendency to spontaneous healing, which probably is due to the thickness of the wall in which it is situated.

Treatment.—This tendency to spontaneous closure may be furthered by cauterization. If that does not succeed, closure by suture may be attempted in different ways.

a. Emmet's Method.—The anterior lip of the cervix is split open in the median line, so as to reproduce a condition similar to that obtaining when the injury was fresh. In this way the fistula is reached, and pared, and the wound united by silver-wire sutures from side to side.

b. Folet's Method.—The urethra is dilated so as to admit the index-

[1] For the difficulties he met with before he obtained success the reader is referred to his own article in *Centralbl. f. Gynäk.*, 1881, vol. v, p. 549.

[2] Pozzi, *Traité de Gynécologie clinique et opératoire*, Paris, 1890, p. 934.

finger, and the cervix is pulled down to the vaginal entrance. A transverse incision is made in front of the cervix, the bladder dissected off, and the opening in the bladder closed, the finger in the urethra aiding the introduction of the sutures.

It seems that even the somewhat risky dilatation of the urethra (p. 140) may be dispensed with.[1]

As a last resort the cervix may be turned into the bladder by suturing it to the borders of a hole cut from the vagina into the bladder.

5. *Vesico-utero-vaginal Fistula.*—This fistula goes from the bladder through the anterior lip of the cervix and ends in the vagina.

Treatment.—If there is left enough of the anterior lip of the cervix a denudation is made here and stitched together with a correspondingly pared surface on the anterior wall of the vagina.

If there is not tissue enough left in front the posterior lip of the cervix is pared and brought together with the anterior lip of the opening in the bladder. By this procedure the cervix is turned into the bladder, and the menstrual flow is secreted with the urine through the urethra.

6. *Uretero-uterine Fistula.*—In this variety, as in the vesico-uterine, urine flows from the os, but the exact condition can be made out in different ways. Milk injected into the bladder will not come out through the os. If the cervical canal is plugged there will soon appear symptoms of acute hydronephrosis, such as pain in the lumbar region, vomiting, and fever. The most conclusive test is, however, that of Bérard. The bladder is emptied with catheter, and the patient is placed on a vessel that will collect all the urine coming from the vagina. At the end of two hours the urine is again drawn from the bladder by means of a catheter. The amount obtained will equal that which has flowed from the vagina, each being the secretion of one ureter. The ureter may perhaps be felt swollen (p. 163). That it should be possible to introduce a ureter-catheter into the uterus from the bladder (p. 162) is very unlikely.

This variety of fistula is exceedingly rare.

Treatment.—The cervix must be turned into the bladder as described above. As the lower portion of the ureter is usually obliterated, it is not allowable simply to close the os uteri, apart from the trouble that might be anticipated by the stagnation of urine in the uterus.

Another method more dangerous, but offering the advantage of not interfering with fertility, consists in *nephrectomy;* that is, the removal of the corresponding kidney through an incision made in the lumbar region (Simon).

7. *Uretero-vesico-vaginal Fistula.*—When the ureter has been partly

[1] A. Benckisser, *Centralblatt f. Gynäk.*, 1893, vol. xvii. p. 847.

destroyed at the same time as a vesico-vaginal fistula is formed, the opening of the former is found somewhere on the edge of the latter. We have seen above how this condition may be cured, either with or without slitting up the ureters.

Genital Cleisis.—When it is impossible to close a fistula, relief from the troublesome, constant escape of urine may be afforded by closing the genital canal below the seat of the fistula, an operation called cleisis or closure.

We have already alluded to the closure of the uterine os (*hystero-cleisis*), the turning in of the cervix into the bladder (*hystero-cysto-cleisis*). The vulva may be made the seat of the closure (*episio-cleisis*), but this is a very objectionable procedure, since it not only renders impregnation impossible, but prevents coition, and gives rise to the stagnation of urine and the formation of stone in the lower part of the vagina. The most common seat of this closure is the vagina (*colpocleisis*). In performing this operation the operator should always keep in view the desirability of preserving as much of the depth of the vagina as possible. Closure should therefore not be made at a lower point than necessary, and often much can be gained by giving the line of union a slanting direction.

The patient is placed in Simon's position (p. 359). A narrow strip is cut off from the mucous membrane of the vagina in such a way that the denuded part of the anterior wall fits to the posterior. These are now brought together by sutures according to general rules. During the insertion of sutures on the anterior wall a sound is kept in the bladder, and while working on the posterior wall the operator uses a finger in the rectum as a guide.

Through the development of better methods for the direct closure of urinary fistula, the use of genital cleisis has become more and more rare. Still, the operation is yet occasionally indicated in cases of great loss of substance, when there is much cicatricial tissue around the fistula partly adherent to the bone, when the bladder is inverted and filled with intestines, and especially in certain cases of uretero-uterine and vesico-utero-vaginal fistula. (See above.)

When the urethra had been lost or its lower edge was too weak to be pared and stitched, Von Nussbaum combined cleisis with the formation of an artificial *supra-pubic urethra*. He punctured the bladder above the symphysis, and left the canula in place for two weeks. Then the patients were allowed to get up, and directed to empty the bladder every two or three hours with a female catheter. At the end of a few months the catheter could be dispensed with, the urine being driven out at will, in a jet, by contraction of the abdominal muscles. In the interval the recti and pyramidales muscles kept the little opening closed.

Urinals.—If for some reason or other no operation can be per-

formed, the patient may derive more or less comfort from the use of a urinal. These may be divided into two classes, the extra- and intra-vaginal. To the first belong rubber bags with a wide opening covering the vulva, and fastened to the pelvis and the thigh. To the second belong the ingenious apparatus of Bozeman and Jay. Bozeman's consists in a flat pear-shaped receiver of silver with a number of holes on the side that comes in contact with the anterior vaginal wall. The urine enters through one or more of these holes, and is led through a tube to a rubber bag attached to the thigh. Jay's consists in a strong soft-rubber ring, to which is attached a bag of the same material, ending in a tube which is compressed by a shut-off. The ring is introduced into the vagina where it stays by its own expansion. The patient takes a daily sitz-bath, and slips the nozzle of a syringe into the exit-tube and fills the urinal repeatedly with warm soap-suds.[1]

I have, however, found that patients, for different reasons, such as pain, excoriations, lack of coaptation, get tired of wearing urinals and prefer to protect themselves with towels.

Pawlik's Operation for Incontinence.[2]—It happens sometimes, after a complete closure of a fistula, that the patient continues having a constant dribbling of urine, which now escapes involuntarily through the urethra. This condition may be due to the loss of the sphincter muscles of the urethra, or to traction being exercised on the urethra, by which it is kept open, or simply to the habit of contraction acquired by the bladder while the fistula was open. Sometimes a spontaneous cure takes place by shrinkage of a cicatrix running across the neck of the bladder; but this is at best slow work. Pawlik has devised an operation by which the condition is remedied at once (Fig. 215). The patient is placed in knee-elbow position. The urethra is pulled to one side with a tenaculum as far as possible (*a*). The limits of the fold thus formed are marked on the mucous membrane. From these points two parallel lines are drawn up and made to converge at their upper end near the subpubic ligament. Next the meatus is pulled as far as possible toward the clitoris without using undue force, and that point marked (*b*). The lines of incision are now continued in a slightly convergent direction to *b*. The thus circumscribed tissue is cut out in the shape of a wedge, and the

FIG. 215.

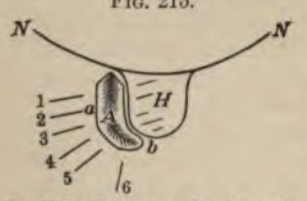

Pawlik's Operation for Incontinence: *H*, urethra; *A*, denudation; *a*, point to which the urethra can be pulled to a side; *b*, point to which it can be pulled in the direction of the clitoris.

[1] John C. Jay, Jr., *New York Medical Record*, Aug. 28, 1886, vol. xxx. p. 251. The urinal is made by Parker, Stearns & Sutton, 228 South street, New York.

[2] Pawlik, *Wiener Med. Wochenschrift*, 1883, Nos. 25–26, p. 772, and *Zeitschrift für Geburtshülfe und Gynäk.*, 1882, vol. viii. p. 38.

wound united with deep sutures of carbolized silk and covered with iodoform. After seven days the sutures are removed, and, the wound having healed by first intention, the other side is treated in the same way.

The object of this operation is to stretch the urethra from side to side, and at the same time to bend it in the direction of the clitoris, by which double process its posterior and anterior walls are brought in contact.

The same operation may be performed when the urethra is gaping and the patient suffers from incontinence without having had a fistula.

B. *Fecal Fistulæ.*—A fecal fistula is one leading from the intestine to the genital canal. They are much less common than urinary fistulæ.

Pathological Anatomy.—There may be one or more openings. The fistulous communication may take place between the rectum and the vulva—*recto-vulvar or recto-labial fistula;* the rectum and the vagina—*recto-vaginal fistula;* between the ileum or the sigmoid flexure of the colon and the vagina or uterus—*entero-vaginal*, *ileo-vaginal*, and *ileo-uterine fistula.*

The size differs from that of an opening so fine that it may be very difficult to discover to that of one easily admitting a finger. Often the aperture is larger on the vaginal side than on the intestinal. The seat varies also very much. A fecal fistula may be situated anywhere between the intestine and the vagina, but it is most commonly found either immediately above the sphincter ani muscles or at the fornix. As a rule, it is found on the posterior wall of the genital canal, but the entero-vaginal variety may exceptionally open in front of the uterus. Sometimes the length is almost nil, the rectal and vaginal walls coming in contact in the thin septum between the two. In other cases, when the fistula is the result of an abscess, the inner opening may be as much as three inches and a half up the rectum, while the outer is found on the inside of the labium majus.

Etiology.—The causes of fecal fistulæ are in many respects like those determining urinary fistulæ. The most common is *childbirth*, and the fistula may either be due to pressure between the fetal head and some bony prominence in the pelvis or remain as the result of imperfect spontaneous healing of a tear through the perineal body. It may be brought about by rupture of the vagina or uterus, an intestinal knuckle being caught in the rent and becoming necrotic, or by diphtheritic and gangrenous processes due to puerperal infection.

Frequently a fistulous opening remains just above the artificially united perineal body after *perineorrhaphy.* Rarely *hysterectomy* has led to the formation of such a fistula at the fornix.

Occasionally the fistula is due to a neglected vaginal *pessary*, that gnaws a hole into the rectum.

Abscesses, either pelvic, vulvar, or prerectal, end sometimes with the formation of a fecal fistula. At the fornix it is due to a suppurating dermoid cyst or extra-uterine pregnancy; at the vulva the inflammation begins often in Bartholin's glands.

We have mentioned above that direct injury, especially violent coition, may cause a permanent fistula (p. 257) and that the solution of continuity may be due to ulcers—cancerous, tubercular, or syphilitic—perforating the partition between the two canals.

In syphilitic patients the fistula is often found just above a stricture of the rectum.

Symptoms.—The escape of flatus and, when the bowels are loose, thin fecal matter, through the vagina soon attracts the patient's attention. The irritating contact with the excrementitial matter causes catarrhal vulvitis and vaginitis.

Of entero-vaginal fistulæ there are two varieties with very different symptoms. If the opening is small (*ileo-vaginal fistula*), they do not differ materially from any other fecal fistula, but if the whole circumference of the intestine has been destroyed and the edges have coalesced with the rent in the vagina (*preternatural anus*), all the feces find their exit through the vagina. If the affected part, as usual, is the ileum, undigested food mixed with bile will make its appearance at the fistula about two hours after meals, and the patient will loose flesh and finally die from starvation. Her weakness may also cause amenorrhea.

Large fecal fistulæ can be felt, small ones may be seen, but are often hard to find on account of their diminutive size. Probing and injection with colored fluid may help to find the inner opening.

In an entero-vaginal fistula, a whole intestinal knukle having been destroyed, there may be two openings with a so-called *spur* between them.

Prognosis.—Fecal fistulæ have in so far a better prognosis than urinary as a larger number of them heal spontaneously, but, on the other hand, those which have no such tendency, are harder to heal by operation, the reason of which is doubtless that while urine is harmless or can easily be given an exit, the intestine is always full of pathogenic microbes, which it is difficult or impossible to keep away from the wound. Mechanical difficulties are likewise of much importance in jeopardizing closure by first intention. If we induce constipation large fecal masses will accumulate, and their final expulsion may tear open the already healed fistula. If, on the other hand, we keep the bowels loose, the contraction of the perineal muscles during the act of defecation is liable to cause a fistulous tract to remain just above the sphincter ani muscles.

We have already intimated that in certain forms of fecal fistulæ nutrition becomes insufficient.

Treatment.—Preventive Treatment.—Much can be done to prevent the formation of fecal fistulæ by having their etiology in mind. Thus an enema of soap-suds should invariably be given in every labor case before the head enters the pelvic cavity.

The pelvis should be carefully examined before labor in regard to narrowness or projecting points, and according to circumstances recourse should be had early to the high-forceps operation, version, craniotomy, or even Cesarian section.

Pessaries should always be kept clean with daily vaginal injections, and removed at least once every two months. If there is any gnawing, the pessary should be left out for a week and carbolized injections used until all abrasions or ulcers are healed.

It goes without saying that most strenuous efforts should be made to prevent syphilitic ulcers from forming fistulæ. Perhaps we will soon have in one of the many remedies now being experimented with a means of checking tuberculous ulcers in their destructive progress.

Even at the height of sexual passion men should exercise a reasonable control over themselves, especially if nature has endowed them with an unusual development of the part concerned. Pus in the pelvis or near the lower end of the rectum should be given an exit by timely operative interference.

Curative Treatment.—A cure may be obtained by cleanliness, the elastic ligature, or cutting operations.

A. Since many small fecal fistulæ have a decided tendency to close of themselves, this happy result should be facilitated by scrupulous *cleanliness*, especially sitz-baths, rectal and vaginal injections, and prevention of constipation, combined with *cauterization* (p. 356).

B. *Ligature.*—In recto-labial fistula, which we have seen often extends far up the gut, a cutting operation would be liable to cause great hemorrhage, and by forming a cloaca leave the patient in a worse condition than she was before. This affection is treated successfully by changing it into a common fistula in ano, and treating that with the elastic ligature.[1] The usual surgical silver probe, armed with an elastic ligature, is introduced into the labial orifice, pressed down to the perineum just outside of the sphincter ani, where the end is liberated by an incision and the probe withdrawn. A more ductile one is substituted, and passed through the sinus from the labial opening to the rectal opening, having the eye threaded with the other end of the ligature. The finger introduced into the rectum recognizes the probe, which is then curved and gently drawn through the rectum and anus. The two ends of the ligature are tied, shotted, and clamped (Fig. 216). The labial orifice is left to itself and closes in a few days,

[1] This method originated with Rhea Barton of Philadelphia, and was improved by I. E. Taylor of this city, who, on November 18, 1885, read a paper on *Recto-labial and Vulvar Fistulæ* before the New York State Medical Association.

or at most two weeks, for just as soon as the rectal opening is united and the ulceration or sinus gradually healing up, there can no longer pass any gas or fluid feces through the sinuous tract and the labial orifice.

This treatment is so little painful that the patient need not even be kept in bed. The ligature will cut through in from three to eight days, and if the elastic thread ceases its pressure the remnant of

FIG. 216.

Barton-Taylor's Operation for Recto-labial Fistula: *A*, anal end of ligature; *B*, labial fistula; *C*, incision in perineum. The fine dotted lines mark the course of the recto-labial sinus; the heavy dotted lines represent the ligature where it is imbedded in the tissues.

embraced tissue is easily severed with scissors or Paquelin's cautery.

C. *Cutting operations* may be performed from the perineum, the vagina, or the rectum.

I. For a *rectal fistula situated low down* three different suture-operations recommend themselves.

1. *Emmet's Method.*—Split the perineal body with scissors in the sagittal plane up to the fistula, cut its wall away and unite as for ruptured perineum (p. 311).

2. *Tait's flap-splitting method* with circular suture (p. 360) is well adapted to these small openings.

3. *Fritsch's Flap-sliding Method.*—A crescent incision is made on the vaginal wall with the convexity turned down and just touching the upper border of the fistula. A similar incision is made

between the ends of the first extending half an inch below the fistula. The enclosed crescent-shaped part of mucous membrane is dissected off. Finally, the flap above the fistula is drawn down so as to cover this denuded surface and the fistula, and fastened all around with sutures[1] to the mucous membrane or the skin.

Whichever method be used it is best first to paralyze the sphincter ani muscle by overstretching it.

II. *Rectal fistulæ situated higher up* in the vagina are, as a rule, operated on from the vagina in one of three ways: Sims's operation, as for vesico-vaginal fistula, Tait's flap-splitting operation, or Hegar's colpo-perineorrhaphia posterior.

They have strongly beveled edges, the vaginal opening being much larger than the rectal.

1. *Sims's Operation* (compare p. 357).—Sometimes the vaginal edges can be brought together after making lateral incisions in the vagina, but cases are occasionally met with in which no extent of division of tissue on the vaginal surface will permit of the edges being brought together. In such a case it is necessary to split the edges of the fistula on each side to a depth sufficient to permit the edges of the rectal wall to be brought together below, leaving the vaginal opening to be filled up by granulation.[2]

Denudation in fecal fistulæ must be made much larger than in urinary. In the lower part of the vagina the edges are, as a rule, united from side to side. In the upper, when there is much loss of substance, the edges must sometimes be brought together in a transverse line.

2. *Tait's flap-splitting* with interrupted suture (p. 360) may be available.

3. German authors recommend a denudation and adaptation from side to side as in *Hegar's operation for incomplete rupture of the perineum* (p. 303).

Operation from the Rectum.—In exceptional cases it may be impossible to bring the rectal fistula into view on account of a cicatricial band at the outlet of the vagina. As this band works as a substitute for the lost sphincter urethræ by keeping the walls of the urethra in contact (compare p. 368) it should not be divided. Under such circumstances the operation is performed from the rectal side.[3]

The intestine should not only be cleaned out by high enemas of water and irrigated with an antiseptic solution during the operation (p. 215), but it may even be good to try to combat the germs in the upper part of the intestine by the internal administration of naphthaline (gr. ij to viii pro dosi, up to gr. lxxx in twenty-four hours) or

[1] H. Fritsch, *Centralblatt f. Gynäk*, 1888, vol. xii. p. 806.
[2] T. A. Emmet's *Gynecology*, p. 662.
[3] Emmet, *l. c.*, p. 666.

salicylate of bismuth (gr. x every two hours). The sutures are put in near the edge on the rectal side, but should go out a quarter of an inch from the edge on the vaginal side.

Entero-vaginal Fistulæ.[1]—If the fistula is only lateral it may be closed by denudation and suture like another fecal fistula. In a case of vaginal anus it must be ascertained if the lower part of the bowel is pervious, as it is evident that no closure must be attempted unless an exit can be given to the fecal matter.

Different operations have been performed or proposed for the relief of this kind of fistula.

1. If there is a double opening the spur between the two may be cut by introducing Dupuytren's enterotome, or another strong pair of forceps, to the depth of one and a quarter inches, and the edges of the fistula denuded and united by sutures.

2. Laparotomy may be performed, the intestine cut loose from the vagina or uterus, and the ends united by enterorrhaphy.

If the lower end is closed or too narrow an anastomosis may be effected between the upper end and the large intestine.

3. It has also been proposed to loosen the intestine and insert it in the rectum from the vagina.

4. After having made an artificial rectovaginal fistula, colpocleisis may be performed under it.

General Remarks about the Operation for Fecal Fistulæ.—In operations from the vagina or the perineum Simon's position (p. 359) should be used. It is often a help to introduce a small Sims speculum under the symphysis pubis and lateral retractors on the sides of the vagina. In operations from the rectum Sims's position or the genupectoral should be used.

Silver-wire sutures are preferable. If used in the rectum they should be turned down toward the anus sa as not to offer any resistance to the exit of the feces. They may be left in two weeks while silk must be removed at the end of the first week. The bowels should of course be emptied before operating. After the operation they are best let alone for three days. After that daily loose passages should be secured by means of medicines (pp. 217 and 313). The patient may urinate herself.

[1] Thirty-nine cases have been collected by H. L. Petit, *Annales de Gynécologie*, vols. xviii., xix., xx., 1882–83.

PART IV.

DISEASES OF THE UTERUS.

CHAPTER I.

MALFORMATIONS.

MALFORMATIONS of the uterus may be due to *excessive development and precocity, to arrest of development* or to *irregular development.* Those due to arrest of development correspond again either to the first or the second half of fetal life. By bearing in mind the history of the normal development of the uterus (p. 30) the many abnormal forms of uteri due to arrest of this development are easily understood. Since the uterus is formed by the fusion and further development of the middle part of the Müllerian ducts we have no difficulty in realizing that that part may originally have been absent or may have been destroyed, or that the originally solid filaments may have failed to become tunneled, or that the muscular tissue which should be formed around them may do so in an imperfect way, or that fusion does not take place between the two tubes, or does so only partially, or that only one of the tubes undergoes its regular development, while the other stays rudimentary or is absent.[1]

A. *Excessive Development and Precocity.*—Sometimes the uterus in the new-born child has the size and shape of that of a girl at puberty (p. 33).

As to menstruation during early childhood we refer to what has been said on p. 235.

B. *Arrest of Development during the First Half of Intra-uterine Life*—1. *Absence of Uterus.*—Complete absence of every vestige of a uterus is a rare occurrence. It may, however, be found in otherwise well built women, but it is mostly combined with other defects in the genitals or in other parts of the body.

Diagnosis.—The total absence of the uterus cannot be diagnosticated in the living woman, and even in post-mortem examinations the pathologist must be on his guard.

[1] Those who want more information about malformations than that warranted by the limits of this book are referred to my article on the subject in the *Amer., Syst. of Gynecol.*, vol. i., pp. 238–257.

2. *Rudimentary Uterus.*—In some extremely rare cases the uterus has only been represented by a *solid* fibrous or muscular mass. In others it consists of a membranous *vesicle.*

In none of the cases of rudimentary uterus authenticated by autopsy was there any menstrual flow, but often molimina.

3. *Uterus Duplex Separatus* or *Uterus Didelphys.*—This variety is produced when the two Müllerian ducts do not even come in contact with one another in that part of their course in which they usually melt together forming the uterus. Consequently there are two entirely separate uteri, but each of them represents only one-half of the total organ. Each half has at its upper end one Fallopian tube and one round ligament. At the lower end the double cervix opens into a single or double vagina, or this organ may be more or less defective.

The uterus didelphys is mostly found in still-born children, but occurs also in adults.[1] Pregnancy and childbirth may be entirely normal.

It is hardly possible to diagnosticate this uterus from a uterus bicornis in the living woman, through the closed abdominal wall.

4. *Uterus Unicornis.*—The one-horned uterus is due to the development of one of Müller's ducts, while the other is absent or stays rudimentary. It is always very long, forms a curve with the concavity turned outward, and ends in a point without fundus.

The diagnosis may sometimes be made by bimanual and rectal examination, by the shape and position. Pregnancy and childbirth may take their normal course.

But attached to the point where the cervix merges into the body of the unicorn uterus is sometimes found a *rudimentary horn.* If pregnancy takes place in that, the condition is a very grave one, the rudimentary horn being incapable of producing the necessary muscular tissue to form a sac for the growing fetus. The condition is, then, practically the same as in tubal pregnancy, from which it cannot be distinguished clinically. Even anatomically the examiner may be led into error, if he does not bear in mind that the round ligament forms the line of demarkation between the uterus and the tube (p. 58). A tube, be it ever so narrow, if situated inside of the round ligament, is a horn of the uterus, while the Fallopian tube starts from the same point as the round ligament and extends outward.

The *treatment* is also like that for tubal pregnancy—namely, a strong electric current for the purpose of killing the fetus, or removal by means of laparotomy.

In very rare cases menstrual blood has accumulated in the rudimentary horn, forming a tumor (*hematometra*). In such a case lapa-

[1] I have seen one in performing laparotomy on a girl twenty years old. In this case the vagina was normal.

rotomy, ligature of the pedicle, and removal constitute the only means of relief. (Compare Salpingo-oöphorectomy under Diseases of the Tubes).

5. *Uterus Bicornis* (Fig. 217).—When the Müllerian ducts remain more or less separated from one another in that part which forms the uterus, this organ appears with two more or less distinct horns at its upper end. There may be a complete partition going all the way down to the external os, so that there is a double cervix, or the cervix may be single, or the partition may be absorbed more or less high up between the two horns, until it is only represented by a ridge at the

FIG. 217.

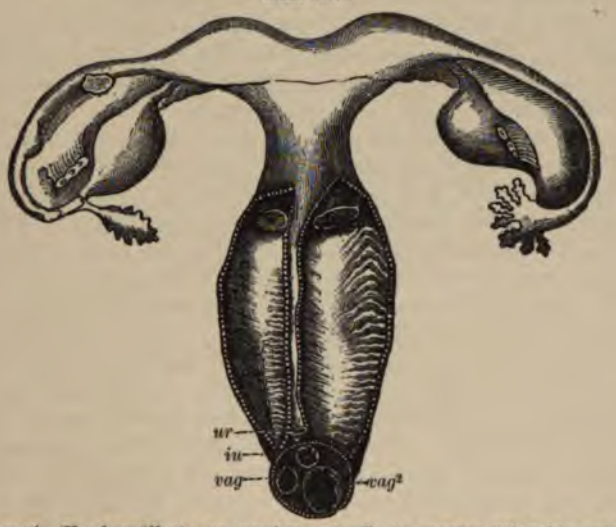

Uterus Bicornis (Hunkemüller): *ur*, urethra cut off; *iu*, meatus urinarius; *vag* and *vag²*, entrance to the double vagina, the anterior wall of which has been removed, showing the two vaginal portions of the two-horned uterus.

fundus inside, while the horns are only separated by a corresponding slight depression on the outside, so that both the external contour and the cavity have somewhat the shape of a heart on playing-cards.

6. *Uterus septus, or bilocularis*, is a uterus with a complete partition between the two halves, but with the normal shape of a uterus outside, a kind that is of much rarer occurrence than the corresponding bicornute variety.

If part of the septum has been absorbed, the uterus is called *subseptus—i. e.* partially partitioned.

In all forms of double uterus, be it horned or not, the vagina may be single or double (p. 323). The menstrual flow may come from one or both halves, and if from both, it may either come from both sides at the same time or alternately from each half.

Pregnancy may take place in either half or in both at once. Even if it is confined to one side, the other, as a rule, partakes in the process, forming a decidua, and producing muscular hyperplasia and hypertrophy.

The presence of a double uterus serves to explain many cases of *superfetation*, an occurrence that is impossible in a single uterus after the third month of gestation.

Childbirth takes in most cases a normal course, but complications are comparatively much more frequent than with a normal uterus.

Diagnosis.—The presence of a two-horned uterus may sometimes be felt by bimanual examination or from the rectum.

The condition of the septum in a double uterus is ascertained by simultaneous use of two sounds, one in either half of the uterus. If there is a communication between the two, the sounds may be brought in direct contact.

7. *Atresia Uteri.*—Just as we have seen above (pp. 317 and 319) that the hymen or the vagina may be closed, the uterine canal itself, although more rarely, may be the site of atresia. The mucous membrane of the vagina may cover the whole vaginal portion without forming any external os, or the cervix forms one uninterrupted muscular mass without bore. In such cases the vaginal portion is little developed or totally absent. In a bicornute uterus one horn may be closed.

In regard to symptoms, prognosis, diagnosis, and treatment, we refer to what has been said above in treating of atresia of the hymen and the vagina (pp. 318–321). Wherever the genital canal is closed the symptoms due to retention, such as amenorrhea, pain, menstrual molimina, and the formation of a tumor, are the same. Here we will only mention a few special features belonging to atresia when it is situated in the uterus. Then the vagina can be explored to its full extent with the finger and the speculum. Above it the uterus forms a round elastic tumor, in the differentiation of which the examiner must especially think of pregnancy, fibroma, and hematocele.

In a case of *pregnancy* the patient will, as a rule, have menstruated before being impregnated, and more or less of the well-known signs of pregnancy will be present. A *fibroid* forms a hard nodular tumor, and causes often menorrhagia. *Hematocele* appears suddenly and forms a broader mass, which pushes the uterus forward.

If the uterus is double, the atresia is found much more frequently on the right side. As a rule, the tumor will begin to form at the time of puberty and increase with every monthly period, as in atresia of the single uterus, but sometimes the development is slow and irregular. Blood may accumulate in the corresponding tube, which gives way before the stronger uterine wall is ruptured. The closed

horn may become adherent to the anterior abdominal wall, and rupture take place through it. The hematometra may also rupture into the stomach or the intestine, which leads to septicemia and death. The least dangerous rupture is that through the partition into the pervious part of the uterus, in which way a permanent cure may be effected; but in other cases the opening closes again and a new accumulation takes place, which in consequence of the entrance of pyogenic bacilli becomes purulent (*pyometra*). This abscess may again open into the normal half of the uterus, from which the pus then flows out, or it may burst into the peritoneal cavity, causing septic peritonitis.

Exceptionally, the contents of the closed horn are only mucus (*hydrometra*). If a purulent collection becomes decomposed gases are formed in the cavity of the uterus, a condition called *physometra*.

Treatment.—If the uterus is single a puncture should be made through the cervix and enlarged with bistoury. After evacuation a drainage-tube should be inserted in order to keep the cervix open. Later, curetting of the endometrium and packing with iodoform gauze will combat endometritis and help to bring the distended and, as a rule, hypertrophied uterus back to a normal condition.

If the accumulation is found in one half of a double uterus it is still an advantage, if possible, to enter through the cervix, but often there is no choice and the tumor must be punctured at its lowest point in the vagina. Puncture alone, even repeated, rarely effects a cure, and it should, therefore, be followed by an incision, or even an excision, of a portion of the wall, so as to insure permanent communication with the open half of the genital canal. When the closed half has been punctured and evacuated it may be possible to dilate the open half by Vulliet's method (p. 154) and remove a part of the partition between the two halves of the uterus.

If the swelling cannot be reached from the vagina, laparotomy should be performed and the affected horn or the whole uterus removed as for a fibroid.

If blood has collected in the Fallopian tube, and there is no communication with the uterine cavity it is best to let it alone, as it may perhaps be reabsorbed. If the tubal sac grows it may be punctured from the uterus or the vagina, especially by Gehrung's method of combined aspiration, galvano-cauterization, injection and drainage (p. 227). Laparotomy and removal of the distended tube may be tried, but it is liable to prove difficult or impossible on account of adhesions.

C. *Arrest of Development during the Second Half of Intra-uterine Life.*—1. *Fetal and Infantile Uterus.*—Some adult women have a womb that in size and configuration corresponds to that of a fetus toward the end of pregnancy or that of a young child. Sometimes

it is only an inch and a half deep; in other cases it has the size of a virgin uterus, but is characterized by the preponderance of the neck over the body and the thinness of the walls of the latter. The folds of the mucous membrane may either be confined to the cervix or extend more or less up into the cavity of the body.

The fetal uterus may at the same time be two-horned (p. 377), as the result of a double arrest of development. The other organs may be normal, but often the condition is combined with other abnormalities, especially of the ovaries.

2. *The pubescent, or congenitally atrophic, uterus* is one that is characterized by its small weight, which does not exceed one ounce, but the cervix and body have about the same length.

Etiology.—Besides simple arrest of development from unknown causes, exudative perimetric inflammation, chlorosis, and tuberculosis may cause the deficient development of the uterus.

Symptoms.—Menstruation is, as a rule, absent or scanty. Often the patient suffers from dysmenorrhea, and sometimes vicarious menstruation (p. 232) takes place. All sorts of disorders in organs outside the pelvis (pp. 238–240) may occur with, or instead of, the menstrual flow.

Sexual appetite may be unimpaired, but as a rule women with too small a uterus are sterile, or if they conceive they are apt to abort.

Prognosis.—The prognosis, especially in regard to sterility, should be guarded, but a late development of the uterus, leading to conception and childbirth, has been observed.

Diagnosis.—The condition can, as a rule, be made out by palpation, especially through the rectum, and the use of the sound.

Treatment.—If tuberculosis or chlorosis be present, the practitioner should carefully abstain from any local treatment that is likely to bring on the courses: the patient being anemic, her condition will only become worse by losing blood. In such cases a general tonic treatment is indicated (pp. 216–218).

If the patient is in good health, and sterility the chief complaint, galvanic treatment with the negative pole in the uterus and faradization have often good effect.

If she suffers from dysmenorrhea, vicarious menstruation, and dysmenorrheic disorders outside of the pelvis, she should be treated according to the rules laid down above (pp. 232, 234–235, 240) in discussing those conditions, especially with tonics, a strengthening regimen, sedatives, electricity, and the uterine sound.

3. *Uterus Parvicollis and Acollis.*—Sometimes the body of the uterus is well developed, but the cervix is too small, or the vaginal portion is absent. In other cases the body is likewise too small, but the hypoplasia is most pronounced in the neck. These deformities have more pathological than clinical interest.

4. *Anteflexion* of the uterus is often congenital, and simply a continuation of the shape of the uterus found in the fetus and young children. This condition will be considered together with other displacements of the uterus.

D. *Irregular Development.*—1. *Obliquity.*—The uterus may be congenitally bent to one side (*lateroflexion*), the two Müllerian ducts that formed it not having kept pace with one another. Or a similar condition may be produced by fetal peritonitis and cicatricial shrinkage of one of the broad ligaments.

A normally shaped uterus may be tilted to one side (*lateroversion*), especially when there is a beginning ovarian hernia.

2. *Malposition.*—In consequence of an uneven development of the broad ligaments the uterus may be placed not in, but to one side of, the median line of the pelvis, *lateroposition.*

A similar irregular development of the parts situated in front of and behind the uterus leads to *anteposition*, when the uterus is situated too near the symphysis, or *retroposition*, when it is drawn too near to the sacrum.

3. *Hernia Uteri.*—The uterus has been found in a congenital inguinal hernia. In such cases the ovary descends first through the inguinal canal, just as the testicle descends, or rather is drawn, into the scrotum. The uterus has also been found in a crural hernia. Such herniæ are exceedingly rare. The patient may become impregnated and the fetus develop in the hernia, whence it has to be removed by Cesarian section. If the condition comes under observation earlier and gives trouble, hysterectomy might be performed.

4. *Elongated Cervix* and *Stenosis of the Cervical Canal* are often found as a congenital irregularity, but will be treated of together with the same conditions when acquired later in life, in a subsequent chapter. (See Hypertrophy of Uterus).

CHAPTER II.

Injuries.

A. *Injuries of the Body.*—On account of its position in the depth of the pelvic cavity the unimpregnated uterus is little exposed to injuries, but when during pregnancy it rises up from the pelvis and rests gainst the abdominal wall it is so much more frequently the seat of traumatic lesions, such as goring with a bull's horn, kicks with heavy boots, stab-wounds, or shot-wounds.[1]

[1] An interesting case of the last kind was reported by Dr. George A. B. Hays, of Plaqueminos, La., in Gaillard's *Med. Jour.*, Nov., 1879, p. 402, *et. seq.*

While in such cases injury is inflicted through the abdominal wall, the pregnant uterus is exposed through the vagina to the manipulations of abortionists. In reading the evidence in suits for malpractice one is at a loss to decide whether the rascality, the recklessness, or the ignorance of these people is the greatest. In their eagerness to destroy the fetus they sometimes make a wound in the uterus large enough to admit the thumb and allow the intestines to enter the uterus.[1]

But even in legitimate gynecological operations the uterus is occasionally wounded. Some uteri are so soft that they are easily penetrated by the sound or the dull-wire curette. Sometimes in performing laparotomy the gravid uterus has been mistaken for an ovarian cyst and a trocar thrust into it.[2]

In regard to rupture of the gravid uterus during labor the reader is referred to works on obstetrics.

Prognosis.—With the exception of the simple perforation of the uterus with sound or curette, which if the instruments are clean, and injection of irritating fluid is omitted, has no bad consequence, most of these injuries are very serious, lead, as a rule, to miscarriage, and are sometimes accompanied by hemorrhage or peritonitis and death. Still, if the ovum has not been opened, and occasionally even after evacuation of the liquor amnii, pregnancy may take its course to term. In those cases in which a pregnant uterus is ripped open by the horn of cattle the prognosis is better than one would expect from the violence of the injury, which can only be accounted for by the excellent health of the persons wounded in this way.[3]

Treatment.—In cases of wounds through the abdominal wall rest, opium, and antiseptic dressing of the wound probably offer the best chances, but if there are signs of internal hemorrhage, laparotomy should be performed, and the bleeding vessel tied. If possible the fetal sac should not be disturbed.

When the uterus has been wounded from within, as a rule, no treatment but rest is required. If there is prolapse of the intestines laparotomy should be performed in order to withdraw the intestine and close the uterus. If the intestine is gangrenous, part of it may be resected; or it may be left undisturbed, when an *intestino-uterine fistula* will form, a condition that not only is compatible with life, but may be cured by nature's sole efforts.

If the gravid uterus is punctured in laparotomy and the ovum opened, Cesarean section should be performed, but if the trocar does

[1] Cases of this kind were mentioned by Thomas, Mundé, and Nœggerath in the N. Y. Obst. Society, April 5, 1881, *Amer. Jour. Obst.*, 1882, *Supplement*, p. 5.

[2] An interesting paper on this subject by Dr. C. C. Lee is found in *Trans. Amer. Gyn. Soc.*, 1883, vol. viii., p. 154.

[3] Out of 14 cases 9 recovered, R. P. Harrison, *Amer. Med. Jour. Sci.*, Oct., 1891, vol. cii., p. 376, and Monograph: *Abdominal and Uterine Tolerance in Pregnant Women*, Philadelphia, 1892, pp. 12–15.

not enter the ovum the opening in the uterus may be closed with silk sutures and pregnancy allowed to take its normal course.

B. *Laceration of the Cervix.*—By far the most common injury to the uterus is that sustained by the cervix during childbirth, when it is ruptured, or lacerated, that is to say, torn.

Pathological Anatomy.—These tears occupy always the direction of the radius of the os. They may be *complete*—that is to say, go through the whole thickness of the cervix—or *incomplete*, when the tear in the cervical canal does not reach the mucous membrane of the vagina. There may be one, two, or many tears. The one most commonly observed is the *bilateral*, and next to that the *unilateral*, which is more frequent on the left than on the right side, doubtless on account of the greater frequency of the left occipito-anterior position of the fetus. The laceration may also be *stellate;* that is, when there are at least three tears forming a starlike figure. It is *funnel-shaped* when there are several incomplete tears, which result in a patulous os. Sometimes it becomes *crescentic* through the bulging of a hyperplastic anterior lip. In other cases the tear is found in the posterior or anterior lip alone.[1]

The tear extends often more or less beyond the vaginal junction and enters the parametrium or the connective tissue behind the uterus, or extends into the bladder. Often it gives rise to cellulitis in these parts, which through cicatricial contraction may lead to displacements of the uterus. If the tear implicates the bladder, it may leave a vesico-vaginal or vesico-uterine fistula (pp. 354 and 366).

Commonly the laceration of the cervix is followed by chronic inflammation of the neck and the body of the uterus. In consequence of hyperplasia and hypertrophy of the glands of the cervical mucous membrane, infiltration with round cells in the interstitial connective tissue, which later are replaced by new fibers, and abnormal afflux of blood, the mucous membrane becomes swollen, red, and rolls out (*ectropium*), and the lips become separated, a condition which is increased by pressure against the posterior wall of the vagina. Often the outlet of the glands becomes closed, and then small round cysts are formed, which are filled with a fluid like the raw white of an egg, feel like shot, and appear as translucent yellowish spots.

The connective tissue in the muscular layer of the cervix becomes also hyperplastic, so that the cervix becomes larger and harder than normal. The lips, especially the anterior, become elongated.

The body of the womb does not undergo the normal involution, but stays large and heavy, and becomes the seat of a chronic inflammation.

Tears may heal completely by first or second intention, but in the

[1] Most of these varieties are beautifully represented on colored plates accompanying an excellent article on the *Indications for Hystero-trachelorrhaphy* by P. F. Mundé in the *Amer. Jour. Obst.*, 1879, vol. xii. p. 134.

latter case the process is often incomplete.: a cicatricial plug of hard connective tissue is formed in the angle between the lips, and the lower part of these does not unite.

On the other hand, the tear may heal from the tip of the cervical portion to near its base, leaving a small opening, which constitutes a *utero-vaginal fistula* without importance. A similar opening may remain after artificial closure.

Symptoms.—In the moment the laceration takes place, it may be accompanied by arterial hemorrhage. An old laceration gives also frequently rise to abnormal loss of blood, be it menorrhagia or metrorrhagia (pp. 236 and 238) from the cervix or from the endometrium of the body. In the interval, the patient suffers from leucorrhea. This double drain produces soon anemia. The patient loses her strength. She gets easily tired, becomes nervous and irritable, and has often neuralgic pain in the localities described above (p. 132), and sometimes strangely perverted sensations and hallucinations.[1] She loses her appetite, her nutrition becomes insufficient, she is pale, and her features have a suffering expression.

Laceration of the cervix is often accompanied by secondary sterility, probably in consequence of the uterine catarrh to which it gives rise. The hyperplastic lips and the unyielding cicatricial plug in the angles between them oppose a considerable resistance to the dilatation of the cervix in childbirth, entailing a tedious and painful labor.

Digital examination reveals the tear in the cervix, the thick, velvety everted mucous membrane, often studded with small hard bodies formed by the obstructed glands. Pressure with the nail in the angle causes often great pain on the spot or in remote places.

The condition is best seen by means of Sims's speculum. The tubular speculum, by pressing the lips apart, is apt to conceal the true condition entirely. The bivalve is liable to make the laceration and ectropium appear larger than they really are. In general, the laceration is plainer to the touch than to inspection, but when exposed by means of Sims's speculum the original shape of the cervix may be approximately reproduced by hooking a tenaculum in each lip in front of the red cervical membrane, where the os uteri was situated before the laceration occurred, and pulling the two lips against one another.

Diagnosis.—By the means just indicated it is easy to demonstrate the laceration. Sometimes the hyperplasia of the lips and the cystic development may be so great that the diagnosis from *cancer* may become difficult, but the effect of treatment will soon dispel all doubt.

[1] A curious instance of this kind is found in my paper on *Laceration of the Cervix* [illegible] ber, 1881. The same paper contains a description [illegible] of the tissue removed in trachelorrhaphy, and a [illegible] tion for the operation.

Some women have a congenital cleft of the vaginal portion in one or two places. The lips thus formed may become the seat of a chronic inflammation, and thus a condition may be brought about in a nulliparous woman that is entirely like a bilateral laceration.[1]

Prognosis.—Many lacerations of the cervix heal spontaneously and give rise to no trouble. Sometimes the nervous phenomena mentioned above may, however, develop even if the tear is completely healed. If the laceration is neglected the whole constitution suffers, as we have seen above, and even a phthisical condition may be the end. Tears of the cervix seem also decidedly to predispose to cancerous degeneration. If properly treated the laceration and its consequences may be entirely cured.

Treatment.—The prophylaxis consists in abstaining from giving ergot or other ecbolic drugs, from pressing on the fundus uteri, or from using the forceps before complete dilatation has taken place. On the other hand, the use of drugs that favor dilatation of the cervix, such as belladonna, chloral, and antipyrin is beneficial.

The accoucheur should not feel or look for lacerations of the cervix except in case of arterial hemorrhage.[2] Otherwise he exposes his patient to infection, that may do much more harm than lacerations, most of which probably heal spontaneously.

If, however, a fresh tear has been discovered and gives rise to hemorrhage, it should be closed with silver wire sutures. If circumstances do not allow of such an operation, a very densely packed tampon and a tightly fitting T-bandage suffice to arrest the hemorrhage.

Fresh tears that do not bleed may be treated with antiseptic vaginal injections or the application of a strong solution of nitrate of silver (ʒi–℥i).[3]

Old tears are treated differently, according to their size and the other local and general conditions. Small nicks round the os may be looked upon as a nearly normal incident of childbirth and need no treatment.

Medium tears are often cured by curetting, and the application of liquor ferri subsulphatis, twice a week, or pledgets with glycerite of

[1] I have treated a girl who was about twenty years old and had an anteflexion of the womb. The hymen was not ruptured, but very lax, probably in consequence of masturbation. The anterior vaginal wall was everted. The cervix was split into an anterior and a posterior lip, which were entirely separated, and bent forward and backward into the fornix. The opening in the cervical canal formed a transverse slit ¼ inch wide. The anterior lip measured 1 inch, the posterior ¾ inch in length. The everted mucous membrane was edematous, bled easily, and was covered with abundant glairy mucus.

[2] Garrigues, "The Immediate Closure of the Laceration of the Cervix," *Amer. Jour. Obstet.*, vol. xxiv. No. 11, 1891.

[3] Elwood Wilson, *Gynecological Trans.*, 1886, vol. xi. p. 92.

tannin (ʒi–℥i), changed morning and evening, and the use of hot vaginal injections.

Unilateral tears can, as a rule, be treated successfully in a similar way.

Large bilateral tears, or even healed tears if they cause neuralgia, call for operative help, an operation that is called after its inventor *Emmet's operation*, *trachelorrhaphy* (*i. e.* neck-sewing), or, more explicitly, hystero-trachelorrhaphy (*i. e.* womb-neck-sewing).

Preparatory Treatment.—Before performing this operation the inflamed mucous membrane should, however, first be treated with tincture of iodine, Monsell's solution, chloride of zinc solution, sulphate of copper solution, or tannin glycerite and hot douches. Cysts should be pricked with a scarifier and painted with Churchill's tincture of iodine. This preparatory treatment may take several months. If circumstances do not warrant so protracted a treatment, the whole mucous membrane may be excised at the time of the operation.

Trachelorrhaphy.—The pubic hairs having been shaved off and the genitals, inclusive of the vagina, disinfected, the patient is placed in the dorsal position, the legs tied with Robb's legholder, and the perineum drawn back with a single Sims speculum. A Schroeder's vaginal retractor (p. 205) helps often considerably in making the parts accessible. Emmet's trocar-pointed half-curved needles and his needle-holder are used.

I begin the operation by inserting a strong linen thread through the middle of each lip (Fig. 218). These guides serve to steady the

Fig. 218.

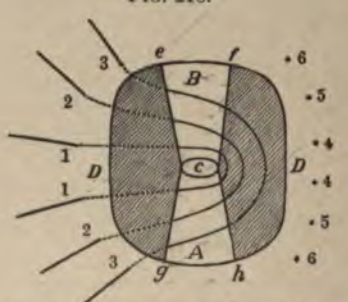

Diagram Illustrating Trachelorrhaphy in a case of Bilateral Laceration: *A*, posterior lip; *B*, anterior lip; *C*, cervical canal (apparent os surrounded by red and swollen mucous membrane, which used to be regarded as an ulcer). The numbers mark the order in which the sutures are inserted. When they are tied *A* comes in contact with *B* and forms the real os (*e*, *f*, *g*, *h*). The reader can easily realize the whole effect of the operation by copying this figure on a piece of paper and folding it at a line uniting *D* and *D*, which represents the angle between the lips.

uterus, separate or approach the lips, mark the canal which is to be kept open, and they facilitate the operation very much. Next, a

tenaculum is hooked into the cervical mucous membrane on one side of the posterior lip. With a long, strong, blunt, curved pair of scissors a piece is cut off going in under the tenaculum, and the strip is continued into the angle of the tear.[1] A corresponding surface is denuded on the anterior lip. Then similar strips are cut off on the other side, leaving an undenuded surface corresponding to the cervical canal. This ought to be about half an inch wide at the os, as contraction always takes place later, and would result in too narrow an os if there had not been left tissue enough. Particular care should be taken to remove the cicatricial plug from the angle. The cut surfaces bleed freely, but there is, as a rule, no hemorrhage of consequence.

The result of the cutting is that we have four denuded surfaces, which two and two melt together in the depth of the angle, and between the denuded surfaces a trumpet-shaped undenuded piece of mucous membrane.

The second step is to introduce the sutures. The first needle is pushed in a quarter of an inch outside of one of the denuded surfaces of the posterior lip near the angle. It is pushed transversely under the denuded surface and made to emerge just on the line of demarkation between this and the undenuded central portion. Next it is inserted on the corresponding point of the anterior lip, and carried under the denuded surface and made to emerge a quarter of an inch outside of it, on a point corresponding to the first in which the needle was pushed in. When the point of the needle emerges anywhere the assistant holds the *counter-pressure hook* (p. 211) in under it, and presses against the tissues in order to facilitate the passage of the needle. The needle carries a loop of linen thread (p. 210) into which is hooked a silver wire 10 inches long. This is closed temporarily as explained on p. 211, and held aside so as to be out of the way. As a rule, three such sutures are inserted on either side, and when they all are in place they are twisted and cut off, beginning nearest the angle. The ends ought to be left at least half an inch long, as they are apt to become imbedded and are hard to find when you want to remove them. It takes a little more time to use silver wire than other material, but in this particular operation I have found decided advantages in using silver wire. In so doing one need not pull the uterus so far down, greater nicety in adapting the edges is obtained, and suppuration is more certainly avoided.

Before and after closing the sutures I thoroughly irrigate with some antiseptic fluid.

Originally, the operation was performed in Sims's position, but the insertion of the needles and disinfection are much facilitated by the dorsal position.

[1] Special scissors have been invented by Emmet, Skeene, Dawson, Hanks, and others.

After having described the most common form of trachelorrhaphy we must mention some of the many conditions that call for a modification of the operation.

Modifications.—If it has been necessary to cut very deep into the angle between the lips, the wound cannot be closed in a reliable way by inserting the sutures from the vagina as described above. Then the uppermost should go much deeper in than it is possible to get it when starting from the vagina. This is obtained by using two needles, each with a loop of thread. One of them is introduced from the cervical canal and pushed out through the posterior lip, the other is in the same way carried from within outward, through the anterior lip. Next the posterior loop is passed through the other, and the latter pulled out through the anterior lip, carrying the posterior loop with it. Finally, the silver wire is hooked into this loop and carried back through both lips.

In the unilateral tear only one side is operated on.

In the stellate tear it is sometimes necessary to cut off a whole lobe between two fissures on one or even both sides.

If there is much glandular hypertrophy and cystic degeneration, it may be necessary to remove the whole mucous membrane from one or both lips. This may be done before the operation by means of Simon's spoon, and hemorrhage staunched with liquor ferri or tamponade. The operation is then postponed until the parts are healed over. It may also be done at the time of the operation by omitting to leave an undenuded strip in the center for the canal. If this is done on both sides, some provision must be made for preventing the cervical canal from growing together. I have used an intra-uterine glass stem for the purpose. Others leave a silk thread or introduce a probe repeatedly during the healing process or reopen the canal by electrolysis.[1]

When there is much hyperplasia, so that the lips stand far apart, and when brought together offer two convex surfaces, it is necessary to hollow the denuded surfaces well out in order to approximate them.

If one lip is longer than the other, the position of the angle must be changed by cutting the tissues in such a way as to get the angle over on the longer lip, and thus obtain two lips of the same length that will form a regular os.

If the perineum is torn the cervix should first be operated on. To do both at one sitting is risky. If there came secondary hemorrhage necessitating tamponade the perineal work would be destroyed, and if menstruation came on unexpectedly, which sometimes happens, it might be hard to diagnosticate (p. 215).

[1] Geo. Engelmann of St. Louis, *Gyn. Trans.*, 1885, vol. x. p. 202, and 1886, vol. xi. p. 90.

As a rule, there is no more hemorrhage than that the operator can go on as described above. If, in very exceptional cases, the circular artery bleeds considerably the deepest suture should be inserted immediately on the bleeding side. As soon as the two lips are in apposition all bleeding stops. In rare cases it may be necessary to cut out a cicatrice from the fornix of the vagina. Here, also, an artery may spurt that should be seized with pressure-forceps. It will hardly be necessary to tie any artery.

If the operator has denuded a larger surface than he can cover there may come serious hemorrhage, which, however, can be controlled with styptic cotton and a tampon of common cotton, and need not interfere with a perfect result.

Great care should be taken to have a perfect line of union, the vaginal mucous membrane on one lip coming in contact with that of the other. If necessary one or two superficial catgut sutures may be inserted besides the silver wire.

Upon the whole, small as the field is, and free from danger as the operation is, if performed aseptically, trachelorrhaphy requires, in my opinion, as much judgment and skill as any other gynecological operation I know of.

At the end of the operation I insert four small pledgets of absorbent cotton, wrung out of a solution of corrosive sublimate and dusted with iodoform. One covers each line of union, one is placed in front, and one behind. The patient may urinate herself. The bowels are kept open if necessary. On the fourth and the seventh day the tampons are changed and the vagina swabbed with corrosive sublimate solution. On the tenth day the sutures and the tampons are removed, and some vaginal injection administered morning and evening. The patient stays nine more days in bed.

The effect of the operation both locally and as to general health is wonderful. The womb diminishes in size, the nervous phenomena disappear, the patients grow fat, a new period full of comfort and blooming health follows in the course of a few months, and very often conception puts an end to sterility.

The stitched surface may, of course, be ruptured in a new labor, just as the intact cervix was, but very often it goes uninjured through subsequent childbirths.

CHAPTER III.

Foreign Bodies.

Foreign bodies are by far not so common in the uterus as in the vagina. Still, occasionally an intra-uterine instrument, especially a glass tube, may break and the end remain inside, or absorbent cotton used for applying drugs to the interior may come off. Sometimes a leech applied through Ferguson's speculum to the vaginal portion has slipped into the interior of the womb. A hairpin used to produce abortion has also been found there.

Treatment.—If any object is in the womb which cannot be withdrawn, the patient should be anesthetized, the cervix dilated, and the foreign body removed with finger, curette, or forceps. If it is a living leech, a strong solution of table-salt injected into the womb will make it loosen its grip. If there is any hemorrhage the uterus should be tamponed with iodoform gauze.

CHAPTER IV.

Metritis.

Metritis is inflammation of the uterus.

As in vaginitis a large number of different forms of metritis are described according to the special part affected, the cause, the course, and certain peculiarities. As this is not a treatise on morbid anatomy, but above all a guide to the recognition of the diseases of the female genitals and their treatment, it would not only lead us too far, but cause unnecessary repetition and confusion, if we were to admit all these distinctions as special diseases. We will only mention such varieties as are clinically distinct or call for different treatment.

In regard to time and severity of symptoms we distinguish between *acute* and *chronic* metritis.

Acute Metritis.—In the acute inflammation the whole organ—body, cervix, mucous membrane, muscular layer, and peritoneal covering—is more or less implicated. The peritoneal inflammation—so-called *perimetritis*—is, however, not always found, and if found extends generally to neighboring parts of the peritoneum, and will therefore be treated of under Pelvic Peritonitis.

The inflammation of the mucous membrane is called *endometritis*, that of the muscular layer *parenchymatous metritis*, that of the cervix has been designated as *cervicitis*, and that of the mucous membrane of the cervix as *endocervicitis*.

Pathological Anatomy.—The whole uterus is enlarged and softened,

the cut surface is red with yellow points. The mucous membrane is swollen and red. Microscopical examination shows both in the mucous membrane and between the muscle-fibers an abundant infiltration with small round cells, dilated blood-vessels, and masses of extravasated blood. The inflammation extends sometimes to the peritoneum and the pelvic connective tissue, either through the tubes or through the lympathics (p. 62). Sometimes it is combined with vaginitis.

It is doubtful if ever an abscess is formed in the uterine tissue, except in puerperal cases where the metritis appears as part of a more comprehensive infection.

Etiology.—Menstruation being accompanied by a development that has much in common with that of inflammation, predisposes to the latter. Thus exposure to wet or cold is more liable to end in acute metritis during the menstrual period than at other times. Coition during menstruation may have a similar effect. Parturition and miscarriage are the most common causes, either through direct puerperal infection or as a predisposing element: if a woman who has recently given birth to a child or aborted, fatigues herself, catches cold, or has sexual intercourse, she is more liable to have an acute inflammation of the womb than otherwise. Coition ought not to take place before involution is completed—say, two months after childbirth and one month after early abortion.

Acute metritis may be brought on by any gynecological operation, even the mere introduction of a sound, and still more easily by curetting, or by the irritation caused by an intrauterine stem or even a badly-fitted vaginal pessary. Trachelorrhaphy or incision of the cervix has often led to endometritis extending through the tubes to the peritoneal cavity and ending fatally. Retained blood may become decomposed and cause acute metritis. The true agent in all these cases is doubtless the introduction of pathogenic microbes, for by proper antiseptic precautions the evil may be avoided.

Acute metritis appears sometimes in the exanthematous fevers, typhoid fever, cholera, acute yellow atrophy of the liver, phosphorus-poisoning, and in persons affected with syphilis.

As we have seen above (pp. 129 and 283), gonorrheal infection invades sometimes the uterus.

Symptoms.—Acute metritis is accompanied by fever, a sensation of heat in the pelvis, bearing-down pain, a painful sensation of contractions called *cramps*, or pain extending up to the lumbar region. Sometimes the patient complains of vomiting, diarrhea, dyschezia, and dysuria. Often she suffers from suppressio mensium or menorrhagia, or has a purulent discharge from the uterus. In gonorrheal metritis there is especially an abundant secretion of thick creamy, often blood-tinged pus, teaming with gonococci. The abdomen is tympanitic and tender.

Vaginal examination reveals a hot vagina, a swollen, congested cervix, with patulous, often eroded, os, and a large, soft, tender body.

Prognosis.—In most cases the disease ends in recovery in the course of from two to four weeks. Repeated attacks of acute metritis are, however, liable to end in chronic metritis. The possibility of the extension of the inflammation to the tubes and the peritoneal cavity, especially in gonorrheal and septic metritis, must also make us cautious in our prognostication.

Treatment.—Prophylaxis.—A perusal of the causes of acute metritis gives the necessary indications in regard to how to avoid the disease. At the time of menstruation, in the puerperal state, and after abortion, women should be particularly careful to avoid too great bodily exertion and exposure to cold. They should abstain from sexual intercourse. Obstetricians and gynecologists should use all antiseptic precautions, even in normal deliveries, as well as small gynecological manipulations and operations.

Curative Treatment.—The patient should stay in bed. An ice-bag or ice-water coil should be applied over the symphysis (p. 183), except when the cause is suppression of menses by exposure to cold. In the latter case a warm poultice or hot-water bag is substituted.

If there is no bleeding, some bloodletting by means of leeches, the artificial leech, or simple scarification (p. 182) sometimes affords considerable relief; but all these manipulations necessitate the use of a speculum, and, if the tenderness is great, this does more harm than good.

Vaginal douches of plain warm water should be administered three times a day or oftener. In these acute cases lukewarm water (100°–105° F.) has often a more soothing effect than the hot (110°–115°). The addition of flaxseed or slippery elm increases perhaps this effect of the douche somewhat (p. 168).

A lukewarm sitz-bath (p. 183) once or twice a day or a general warm bath every other day is also useful if the slight movements inseparable from these procedures do not hurt the patient. Anodynes are best given as opium suppositories (p. 218). Five grains of quinine should be given every four hours, and the bowels kept open.

When the most acute symptoms have subsided, the ice-bag may to advantage be exchanged for Priesznitz's compress (p. 183), tincture of iodine may be painted on the abdomen and on the roof of the vagina (p. 184), and glycerin tampons (p. 173) may be introduced into the vagina.

Gonorrheal metritis necessitates a more active treatment. The uterus should be washed out (p. 168) at least once a day with a solution of corrosive sublimate (1 : 3000) or chloride of zinc (1 : 100) through a glass tube. Twice a week the interior of the uterus should

be painted all over with a solution of chloride of zinc (20 per cent.) or nitrate of silver (1 : 12). Some use curetting (p. 171). A milder treatment, with a somewhat similar effect, consists in packing the uterus once or twice with iodoform gauze (p. 175) in order to remove all pus and some of the epithelium, and finally leave a strip well dusted with iodoform in the uterus. Far from causing pain, it seems to have a soothing effect.

Diphtheritic Metritis.—A particular variety of the acute metritis is the diphtheritic, in which there is a yellow exudation in and on the endometrium. This condition is mostly due to puerperal infection, but is also found as part of general diphtheria. It occurs combined with gangrene of the vagina (p. 343) in scarlet fever, typhoid fever, cholera, and other infectious diseases.

FIG. 219.

Dissecting Metritis.[1]

In puerperal cases the diphtheritic infiltration may extend in a

[1] Specimen expelled by B. R. at Maternity Hospital, on Oct. 20, 1883. This was the eighth case of the report published in *N. Y. Med. Record*, vol. xxiv. p. 664. The figure taken from a photograph is a little below natural size.

layer from the endometrium to the neighborhood of the peritoneum, cutting off a large part of the muscular tissue, which, after weeks or months, is expelled as a pear-shaped body (Fig. 219), a condition which is little known, but of which I have observed and described under the name of *dissecting metritis* not less than eight cases.[1]

Diphtheritic metritis is, as a rule, combined with a similar condition in the vulva and the vagina, and may be made visible when it attacks the cervix. Dissecting metritis cannot be diagnosticated before the loose body is expelled, but its existence may be surmised if after diphtheritic vaginitis and cervicitis there continues an abundant purulent discharge from the uterus.

If the cervix is attacked its whole inner surface should be thoroughly painted once with chloride-of-zinc solution, 50 per cent. The uterus should be washed out with carbolized water once a day. An iodoform pencil

℞.	Iodoformi,	ʒv;
	Amyli,	ʒss;
	Glycerini,	fl. ʒss;
	Acaciæ,	ʒj.

M. Sig. Divide in three suppositories of the size and shape of the little finger.

should be introduced up to the fundus and left to melt. The internal treatment consists in the administration of quinine, stimulants, and chloride of iron.

B. *Chronic Metritis.*—While we have treated of the acute form of metritis as one entity without distinguishing between the inflammation of the mucous membrane and that of the muscular tissue, in regard to the chronic form of inflammation of the uterus, it is better to describe endometritis and parenchymatous metritis separately. It is true that the inflammation of the mucous membrane always extends somewhat into the muscular layer, and that an inflammation of the latter always implicates the former, but still there are marked clinical differences between the two, and certain points in the treatment apply only to one or the other.

1. *Chronic Endometritis.—Pathological Anatomy.*—In the chronic form of endometritis the mucous membrane of the uterus is swollen, soft, friable, of dark red or slate color. In some places are seen ecchymoses. On account of the swelling the mucous membrane does not find room enough in the uterus and bulges out through the os, forming a so-called *ectropium*. The glands of the cervix become occluded and form cysts most of which are small as hemp-seed or peas, and

[1] Garrigues, "Dissecting Metritis," *New York Medical Journal*, 1882, vol. xxxvi. p. 537; *Archives of Medicine*, April, 1883; and *Archiv für Gynäkologie*, 1890, vol. xxxviii. p. 511.

shine with a white or yellow color through the surface of the vaginal portion. In olden time these retention cysts were mistaken for the human ovulum and are yet known under the name of *ovula of Naboth*. Occasionally these cervical cysts acquire, however, the size of a cherry. When pricked open a thick colorless fluid, like the raw white of an egg, flows out from them. The interior of the body has lost its even smoothness, and is raised in ridges or in papillary growths, or long club-shaped polypi hang down from the fundus and the side walls. This has been described under the name of *hyperplastic* or *fungous endometritis*. Similar *mucous polypi* form in the mucous membrane of the cervix and may hang out from the os as pedunculated tumors.

Around the os, on the outer surface of the vaginal portion, is found a red velvety area, and similar red spots may be found further out on the vaginal portion, apart from the os. They are often called *erosions*, and they form what is known as a *granular os*. They used erroneously to be called ulcers of the cervix, an expression that is yet often used by patients.

Microscopical examination shows that the swelling of the mucous membrane in chronic endometritis is due to a great development of its glands, to infiltration with round cells, and to dilatation of the blood-vessels. The glands penetrate into the muscular layer. When this considerable development of glands takes place, the condition is sometimes designated as *benign adenoma* as opposed to *malignant adenoma*, which is beginning cancer of the mucous membrane.

The fungoid growths on the inside of the uterus are sometimes nearly exclusively formed by glands; in others they consist of round cells like the granulations on a wound; and in a third variety they are almost entirely composed of dilated blood-vessels. In some places the formation of connective tissue gets the upper hand, and the glands become atrophic or disappear. A similar difference is observed on different points of the membrane, if it remains comparatively smooth.

The so-called erosions are due to a change in the epithelium covering the vaginal portion, which normally is flat like that of the vagina, but becomes columnar. In the interior is found an infiltration with round cells, as in all inflammations. By invagination the epithelium forms bays and tubules, which constitute new glands and, when they become closed, are transformed into cysts.

Etiology.—Many points have already been discussed in the chapter on Etiology in General (pp. 125–128), and the reader is referred to what is stated there about hyperemia of the pelvic organs, constipation, exposure to cold, improper dress, neglect during menstruation, certain abnormalities in regard to coition, puerperal infection, and abortion.

The influence of gonorrhea has been spoken of on pp. 129 and 283, and we have seen how it may cause acute metritis (p. 391), but after the acute stage is over it may remain as a chronic inflammation.

During childbirth the cervix, and especially its mucous membrane, is subjected to such pressure and abrasions that often a chronic endocervicitis follows. This is especially the case if the cervical portion is torn (p. 383).

Parts or the whole of the decidua may remain after childbirth and abortion and continue to live as part of the endometrium, a condition that has been described as *decidual endometritis.*

Old age gives rise to a peculiar form of endometritis called *atrophying endometritis.* The normal columnar epithelium becomes changed to an irregular horny one, more like the flat epithelium of the vagina. There is a profuse purulent discharge. Sometimes the opposite walls grow together, especially at the internal os, which gives rise to *senile pyometra.*

Symptoms.—A prominent symptom is pain. In the general division of this book we have enumerated the order of frequency with which a neuralgic pain is found in certain localities (p. 132). Besides, the patient, as a rule, complains of "bearing down," a disagreeable sensation of heaviness extending from the interior of the pelvis to the external genitals, and often of "cramps," a painful feeling of muscular contraction of the uterus caused by retention of blood or mucus above the internal os. Sometimes, although the ophthalmologist finds no fault in her eyes, she complains of pricking pains in them, of weak eyesight and photophobia, often combined with pain at the back of the head, where the visual centers are located.

It is not rare that a feeling of discomfort necessitates frequent micturition although the urine is normal, a condition designated as *irritable bladder.*

As a rule, the menstrual discharge is preceded and accompanied by more or less severe dysmenorrhea (p. 223).

Secondly, abnormal loss of blood from the uterus is of frequent occurrence, and easily explained by the vascular development described in the paragraph on morbid anatomy. There may be menorrhagia (p. 236) or metrorrhagia (p. 238), or both, and often protracted menstruation, the menstrual process extending over an unusual number of days, although perhaps the total loss of blood does not exceed the normal quantity. When loss of blood is a prominent feature the condition has been described as *hemorrhagic endometritis.*

In very weak patients endometritis is, on the other hand, occasionally accompanied by amenorrhea.

A third symptom that brings the patient to seek help is leucorrhea, which is easily accounted for by the hyperplasia of the normal glands and the constant formation of new ones. The fluid secreted by the

cervix is like raw white of an egg (p. 241), that from the interior of the body is more milky. Both are alkaline, and both may become purulent, which is especially the case in gonorrheal and atrophying endometritis. As to the microscopical composition, see p. 241. If the discharge is at all abundant it weakens the constitution (p. 242). When leucorrhea predominates, the disease has been called *catarrhal endometritis* or *catarrh of the uterus.*

In some patients there is a very free discharge of a muco-serous fluid, a condition called *hydrorrhea.* At times the secretion may be retained above the internal os, probably on account of the swelling of the mucous membrane or a spasmodic contraction of the surrounding muscular tissue. The uterus may then become quite distended, and the patient has considerable pain until the obstacle gives way, and the accumulated fluid rushes out in a gush, when she feels relieved until the same process repeats itself. Apart from pregnancy hydrorrhea is a rare disease.[1]

The hydrorrhea of pregnancy, *hydrorrhea gravidarum,* on the contrary, is rather common. Watery fluid may be discharged any time during pregnancy, but it is most common during the last month of gestation, and gives often rise to the erroneous supposition that the "waters have broken."

A similar condition is sometimes found after childbirth—*puerperal hydrorrhea.* It is then commonly due to the retention of a portion of the placenta or of clots, but a polypus may produce like results.[2]

The patient afflicted with endometritis loses her appetite, and suffers often from nausea, dyspepsia, and constipation. She becomes weak and pale, with black rings under her eyes.

Some patients complain of a feeling of oppression in breathing. Some have palpitations.

The nervous system suffers much. These patients are quite frequently despondent and melancholy. I have seen cases of acute mania and epilepsy. The group of symptoms classed as hysteria is so rare that it is doubtful if there is a causative relation between it and endometritis.

An inflamed endometrium does not seem to be a favorable ground for the implantation and development of the ovum. The abundant leuchorrhea helps also perhaps to expel it. So much is sure that patients afflicted with endometritis are often sterile, or if they conceive they have a tendency to abortion. It is also claimed that pla-

[1] I have seen a case in which the uterus was purple, slightly tender, and measured, when the patient consulted me, 3½ inches, but before that it had been as much as 5 inches, as measured by other gynecologists of this city. Her discharge was so copious that "she used forty diapers a day, that it wetted sheets, and that she could pass it on a bed-pan and fill bottles with it."

[2] R. Barnes, *Diseases of Women,* London, 1873, p. 81.

centa prævia may be caused by it, the ovum sinking down to the os internum before it becomes fastened to the endometrium.

By vaginal examination we find, in most cases, at least in women who have borne children, the os patulous, velvety, or granular, often studded with small, round, hard bodies (*ovula of Naboth*). In nulliparous women, on the other hand, the external os is often too narrow, and the secretion accumulates in the cervix or in the body of the uterus or in both simultaneously.

The cervix is quite commonly enlarged, either too soft, when the cellular infiltration, the formation of glands and cysts, and the dilatation of the blood-vessels predominate, or too hard, when the hyperplasia of connective tissue has caused atrophy or disappearance of the softer structures. The uterus is tender on pressure.

The introduction of the sound and dilator is unusually painful and often causes some bleeding. By moving the sound along the interior surface it is often felt to be rough or the seat of polypi.

Diagnosis.—In *lumbo-abdominal neuralgia* certain parts of the uterus, especially on the level with the internal os may be tender on pressure, but then all the other symptoms, especially hemorrhage and leucorrhea, are absent.

A *fibroid tumor* often causes hemorrhage and leucorrhea, but the presence of the tumor can be made out by bimanual examination. If it is a *fibroid polypus*, it can be felt with the sound.

The diagnosis from the early stage of *cancer* may be difficult. In cancer we find, however, such friability of the tissue that parts can be scraped off with the nail, or are spontaneously expelled from the interior of the womb, which is never the case in endometritis. On the other hand, this softness is surrounded by tissue that it is much harder than in the mere inflammation. Cancer is accompanied by a profuse discharge of a watery fluid or thin pus with a peculiar pungent and offensive odor. As to hemorrhage, when the patient is in the prime of life, has a subinvoluted uterus, and suffers merely from menorrhagia, the probability is in favor of hyperplastic endometrits, and against malignant disease. On the other hand, bleeding after the menopause is a very suspicious symptom. Many lay much stress upon irregular bleeding in the intermenstrual period, especially after coition, but I have often seen this in cases of lacerated cervix with ectropion. Pain is, as a rule, absent in beginning cancer, but sometimes the patient has vague shooting pains in the pelvis. Cancerous tissue is well differentiated from the surroundings, forming a glistening prominence not unlike currant jelly. The effect of treatment will soon dispel all doubt. The diagnosis is made sure by cutting out a piece of the suspicious tissue from the cervix, imbedding it and preparing microscopical specimens of it. In the same way the malignant or benign nature of scrapings from the interior of the womb is ascertained.

Mere "teasing" with two needles does not furnish conclusive specimens.

Prognosis.—Chronic endometritis is at best a very tedious disease, and it is not safe to promise more than improvement. This applies particularly to the catarrhal discharge. But even this is sometimes completely cured. As to conception, the prognosis should be still more reserved, especially in cases of catarrhal endometritis involving the body of the womb.

Hemorrhage may undermine the constitution and even prove fatal, but in this respect our therapeutic resources are manifold and powerful.

As to pain and other nervous phenomena, the outlook is favorable.

Treatment.—What prophylactic measures are to be taken, is self-evident by reference to the above paragraph on etiology. Here we will only notice the importance of removing the endometrium with a curette after abortion, and of not allowing pieces of placenta or membrane to stay behind after delivery.

In patients affected with gonorrhea of the urethra and vagina, the extension of the disease to the uterus may perhaps be prevented by the use of a tampon soaked in the following solution:[1]

℞. Acidi tannici,
Iodoformi, āā ʒii;
Glycerini, ℥v.—M.

Patients affected with chronic endometritis need a good deal of rest. Gymnastics, dancing, bicycling, machine-sewing, and similar fatiguing movements, make their condition worse. Moderate exercise in the open air is good, but the patient ought never to walk so much as to increase her pain. In order to avoid pelvic congestion, she should abstain as much as possible from sexual intercourse. For the same reason the bowels should be kept open if she is constipated (p. 217). An elastic belt surrounding the whole abdomen (p. 186) is often useful in stout women by shifting over on the spinal column and the lower extremities some of the pressure exercised on the uterus by the intestines and other abdominal organs.

A warm bath (p. 183) twice a week has often a very soothing effect on the nerves, and probably withdraws blood from the uterus by dilating the capillaries of the skin. Warm sitz-baths have a similar effect. By the use of the bath-speculum (p. 184) this may still be enhanced. Sea-bathing, shower-, sponge-, sheet-, or towel-baths, or a regular hydrotherapeutic treatment is excellent in combating catarrh, hemorrhage, and debility. Certain spas (p. 184) have a reputation for being beneficial in chronic endometritis.

The disease being of long duration, we should use anodynes

[1] H. Fritsch in *Billroth's und Luecke's Handb. d. Frauenkr.*, vol. i. p. 1043.

[illegible] Backache is temporarily relieved by rub- [illegible] with a mixture of 1 part of chloroform with 3 parts [illegible] times a day. The pain in the eyeballs accompany- [illegible] rapidly under the use of a douche of cold water [illegible] times a day for five minutes against the closed eyes. [illegible] are accompanied by a nozzle in the shape [illegible] watering-pot, which answers the purpose. With this [illegible] as a rule, scarification of the cervical portion [illegible] administration of tonics (p. 217).

[illegible] I use the following mixture:

℞. [illegible]	ʒij;
[illegible]	℥j:
[illegible]	ad ℥iv.

[illegible] in a wineglassful of water 3 times a day, [illegible]

[illegible] hemorrhage the reader is referred to what has been [illegible] described there fail to check the uterine hemor- [illegible] artery may be ligated on both sides (p. 177). [illegible] oophorectomy has been performed, nay, even [illegible]

[illegible] endometritis the endometrium is studded with [illegible] (p. 171) has a prompt effect. If the whole [illegible] intra-uterine chemical galvano-cauterization [illegible] method is excellent. The galvano-cautery [illegible] purpose, but is probably an unnecessarily [illegible]

[illegible] amenorrhea is discussed on p. 231. It occurs [illegible] to four months after curetting, and should [illegible] with, as it is a beneficent pause after the drain [illegible] when the curetting was done.

[illegible] of leucorrhea directions are found on p. 242. [illegible] how the glands of the mucous membrane [illegible] dip into the muscular layer, it is easy to under- [illegible] all applications prove, and how important it [illegible] with local treatment.

[illegible] irritants, the actual cautery, and other powerful [illegible] only by removing sick tissue, but the tissue is [illegible] state, and taking a new start the new-formed [illegible] healthy.

[illegible] inflammations are treated with bromides, especially [illegible] (gr. i–x, *t. i. d.*, in emulsion or capsules).

[illegible] pricked open and then painted with tincture of

iodine. Exceptionally, the whole cervical portion may be one agglomeration of cysts, which do not yield to this treatment. Then they should gradually be destroyed with a needle-shaped Paquelin's cautery or galvano-cautery.

For erosions there is no better treatment than to bathe the vaginal portion in a tubuliform speculum for a couple of minutes with acidum pyrolignosum rectificatum twice a week; but this substance has such a pungent odor that it is disagreeable to most people. A 10 per cent. solution of sulphate of copper applied in a similar way for a few minutes two or three times a week is also very good. Erosions may also be treated with carbolic, chromic, or nitric acid, followed by a solution of bicarbonate of soda in order to neutralize the superfluous acid. Injections of chloride of zinc, chloride or subsulphate of iron, and nitrate of silver are also valuable. I often combine curetting by means of Simon's sharp spoon with the application of liquor ferri chloridi.

I have obtained excellent results by applying to the eroded os, through Cusco's speculum, the positive pole of a galvanic battery in the shape of a ball of gas-carbon wound with very little cotton, squeezed nearly dry. It is used for five minutes with as strong a current as the patient can stand (about 40 milliampères). It leaves an eschar followed by suppuration. A few such applications repeated once a week produce a healthy mucous membrane in shorter time than any astringent. Apostoli has constructed a special electrode for the purpose (p. 226).

If the cervix is lacerated, trachelorrhaphy should be performed (p. 386).

In the interior of the body of the uterus the above-named acids and astringents are also used. The substances I personally use for treating the endometrium are Churchill's tincture of iodine, chloride of zinc, nitrate of silver, and chloride of iron, and I apply them all on absorbent cotton wound around Budd's applicator (p. 166).

Iodine is the mildest and the most generally useful; chloride of iron is best in the hemorrhagic, chloride of zinc and nitrate of silver in the catarrhal form.

Besides the intra-uterine application, I paint the vaginal roof with tincture of iodine (p. 165), which probably acts as a counter-irritant.

The patient herself introduces a pledget with glycerin morning and evening (p. 173). As we want the iodine to enter the tissue by endosmosis and glycerin causes a powerful exosmosis, it is better not to introduce the pledget immediately after painting the vagina.

As an astringent on a spongy cervix, glycerite of tannin is very good (p. 173). Duke recommends boracic acid in powder applied with a tube and piston (p. 166).

Scarification is used not only for opening and destroying cervical cysts, but also to give exit to some blood. When the uterus appears congested, this procedure gives often great relief (p. 182).

If the external os is too narrow, mucus often accumulates in the cervix, which is distended in the shape of a barrel. In such cases the treatment must begin by gradual dilatation of the cervical canal (p. 153). If the os is so small that not even a common uterine sound can enter, it is necessary first to make a little nick with a knife.

In chronic endometritis of gonorrheal origin the treatment is similar to that in the later stage of the acute (p. 392).

Exfoliating Endometritis.—Exfoliating endometritis, also called *menstrual endometritis*, or *membranous dysmenorrhea*, is a rare variety of endometritis that presents so peculiar features that we are obliged to treat it separately. It forms a link between acute and chronic endometritis in so far as it is an acute process that repeats itself every four weeks.

Pathological Anatomy.—The mucous membrane of the body of the womb is swollen and red. It is thrown off in shreds an inch in diameter or even as one piece representing a cast of the uterine cavity with an inner smooth and outer rough surface and three openings corresponding to the internal os and the apertures of the Fallopian tubes.

Microscopical examination shows that the uterine glands are unchanged, but that there is great hyperplasia of the cells of the endometrium, which retain their normal size, but are packed so closely together that little space is left for the inter-cellular substance.

Etiology.—Exfoliating endometritis is a form of chronic endometritis. It is sometimes allied to fibroids, and occurs in women affected with syphilis, tuberculosis, or suffering from acute phosphorus-poisoning.

Symptoms.—The disease is characterized by severe pain in the pelvis recurring at each menstrual period and followed by the expulsion of the above described parts of the endometrium. It may be found at any age during menstrual life. Persons affected with it may become pregnant, and are liable to abortion, but may even give birth to children and then again be affected in the old way.

Diagnosis.—Exfoliating endometritis is, as we have said, a very rare disease, and assertions to the contrary are based on errors of diagnosis. A chief point in the diagnosis is the regularity of the expulsion of membranes, but even that may be simulated for some time by regularly repeated abortions. The microscope alone can positively settle the diagnosis. The presence of villi chorii is absolute proof that the specimen is a product of conception, and even the decidua of pregnancy differs from that of menstruation by the large size of the cells of the endometrium.

In extra-uterine pregnancy a similar expulsion of the endometrium may take place. In order to avoid errors as much as possible the pelvis must be examined most carefully for a tumor that might be the fetal sac, and all signs of pregnancy, genital, pelvic, abdominal, stomachic, mammary, cutaneous, and nervous, looked for.

Treatment.—Spontaneous cures are reported, but, as a rule, the intervention of the healing art is solicited. The endometrium should be destroyed so as to give a chance for a new and better growth. This is done by the curette followed by the application of tincture of iodine or iodoform pencils, or by the galvano-chemical cauterization according to Apostoli's method.

2. *Chronic Parenchymatous Metritis.—Pathological Anatomy.*—The size and weight of the uterus are increased, the wall is thicker, the cavity larger, and the tissue harder. Microscopical examination shows that the muscular bundles are separated by much broader layers of connective tissue than in the normal uterus. The walls of the arteries in the muscular tissue of the uterus are thickened and partially changed to connective tissue. The lymph-spaces are enlarged, and the peritoneal covering thickened. If the case is due to subinvolution after childbirth or abortion, the muscular fibers are found enlarged and abnormally numerous (hypertrophy and hyperplasia).[1]

Etiology.—The parenchymatous metritis may arise by extension from chronic endometritis. Frequent attacks of acute metritis may finally lead to the chronic form. It may be due to exposure to cold, especially living in a cold climate and in a damp basement.

Too frequent coition and still more a connection that is interrupted without ending in orgasm and the normal sensation of contact with the ejaculated semen, abortion, subinvolution after childbirth, and too rapidly recurring pregnancies, favor its development. It frequently accompanies displacements,—especially retroflexions,—fibroids, and cancer of the uterus, as well as ovarian tumors.

Symptoms.—As a rule, the patient has no fever, but occasionally a rise of temperature up to 102° Farenheit shows an acute exacerbation in the chronic condition. She has an unpleasant bearing-down sensation, often combined with pain in the groins and backache. Menstruation is usually more or less painful. Quite often the patient feels an irritation of the bladder, compelling her to empty that organ frequently, although the composition of the urine is normal. Constipation is very common.

Hysteria is not found oftener than in other women, and is, therefore, probably independent of the disease.

Menorrhagia and leucorrhea are very common. Nervous reflexes, such as swelling of the breasts, mastodynia, and intercostal neuralgia, accompany it frequently.

[1] Welch of Baltimore, quoted by A. P. Dudley, N. Y., *Med. Jour.*, Sept. 4, 1886.

The dilatation and growth of the uterus during pregnancy is accompanied by pain, and is often interrupted by abortion.

Some patients have, in the middle of the interval between two periods, a so-called *intermenstrual pain*, much like that occurring with menstruation, but of shorter duration, and sometimes accompanied by the excretion of bloody mucus.

Vaginal examination reveals the enlargement and tenderness of the body of the uterus, and often a thickened, hard, eroded, and granular vaginal portion.

In nervous and anemic persons a tumor is sometimes felt in one of the edges of the uterus at the junction of the neck and the body. It may become as large as a hen's egg. It is semiglobular, of the consistency of a myoma, and sensitive on pressure. It is only congestive, is formed during hemorrhage, and disappears when the bleeding stops. After the bleeding follows an offensive discharge like lochia. These tumors have been described by French authors under the name of "*tumeurs fluxionnaires*," and are supposed to be due to metritis.

Diagnosis.—*Cancer of the body* of the womb causes greater hardness, forms a tumor that can be felt, and is accompanied by a thin, purulent, malodorous discharge. By means of the sound the inner surface of the womb may be found to be irregular and to contain spots where the tissue is unusually soft.

Prognosis.—Chronic parenchymatous metritis does not, as a rule, threaten the patient's life unless the hemorrhages should be profuse enough to undermine her constitution, but it is an exceedingly tedious disease, sometimes extending over many years, and a perfect cure is rare, although much can be done to alleviate the sufferings of the patient.

Treatment.—In order to avoid needless repetition the reader is referred to what has just been said about chronic endometritis, which always accompanies the parenchymatous form. Here we will only add measures particularly indicated where the muscular coat of the uterus is implicated.

Among internal medicines, a long-continued use of small doses of *chloride of gold*, or of *corrosive sublimate* (p. 218) may succeed here as in other parts of the body in reducing the abnormal deposit of connective tissue.

In cases of subinvolution, Tait praises the effect of chlorate of potassium, gr. viiss, *t. i. d.*, given in a medicine with a few drops of dilute hydrochloric acid.

Faradization has a similar effect by causing muscular contraction. The bipolar intra-uterine method (p. 221) is particularly recommendable. Apostoli praises the primary current.

The *galvanic current* (p. 222) may help to reduce the bulk of the uterus by electrolysis.

Massage (p. 187) causes absorption by mechanical manipulations.

Finally, operative interference not only serves to remove redundant tissue mechanically, but experience has shown that it so modifies the nutrition of the womb that that organ may shrink considerably in the course of several months following the operation. If the cervix is lacerated, *trachelorrhaphy* (p. 386) should be performed. If it is not torn, but much enlarged, it may be diminished in different ways.

1. *Gordon's Method.*[1]—If the cervical canal is so large that it can be done without causing stenosis, a wedge-shaped piece may be cut out, having the base at the os and the apex at or somewhat beyond the utero-vaginal junction. This operation is performed exactly like trachelorrhaphy, and recommends itself by its safety and simplicity and by leaving a normal vaginal portion, which may be needed for the adaptation of a pessary.

2. *Hegar's Method* consists in the removal of the whole vaginal portion. The patient being in dorsal decubitus, the vaginal portion is exposed by means of a single Sims speculum (p. 144) and side retractors (p. 205), and the uterus pushed and pulled down. The cervical portion is split open with scissors on both sides up to the vaginal vault. Each lip is seized with a volsella and cut off with scissors bent at right angles. In dealing with the anterior lip the operator must take care not to go beyond the boundary-line of the bladder. Next, the mucous membrane of the cervical canal is united by a row of sutures to that of the vagina (Fig. 220). Sometimes it

FIG. 220.

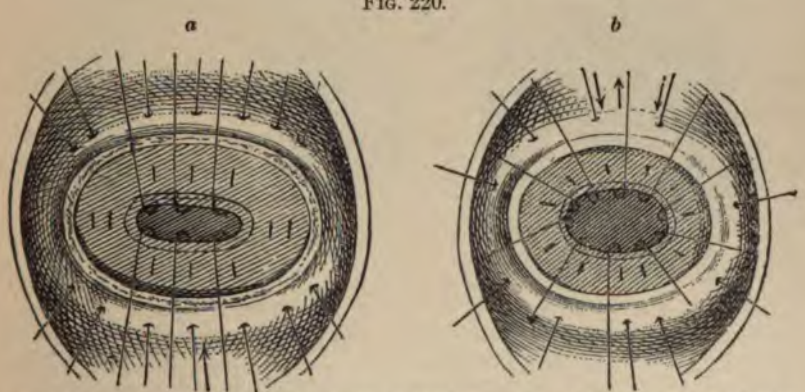

Hegar's Amputation of the Cervical Portion: *a*, two sutures on each side do not enter the cervical canal; *b*, all sutures are passed from the vaginal to the cervical mucous membrane. In both cases a portion of the cut surface is skipped in inserting the sutures.

is better only to do this in the middle, and to unite the vaginal mucous membrane in front and behind at the sides. This is done with rather

[1] S. C. Gordon of Portland, Me., *Amer. Jour. Obst.*, 1884, vol. xvii. p. 1205.

FIG. 221.

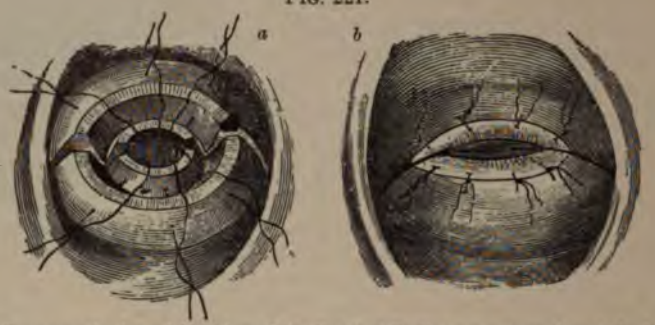

Simon's Cone-mantle-shaped Excision of the Cervical Portion: *a*, sutures inserted; *b*, sutures tied. (There ought to be one or two on each lateral incision).

strong, curved, round, crescent-ground, or trocar-pointed needles or the fishhook-shaped needles (Fig. 174, *f*, *g*, and *l*), held in a needle-holder.[1]

FIG. 222.

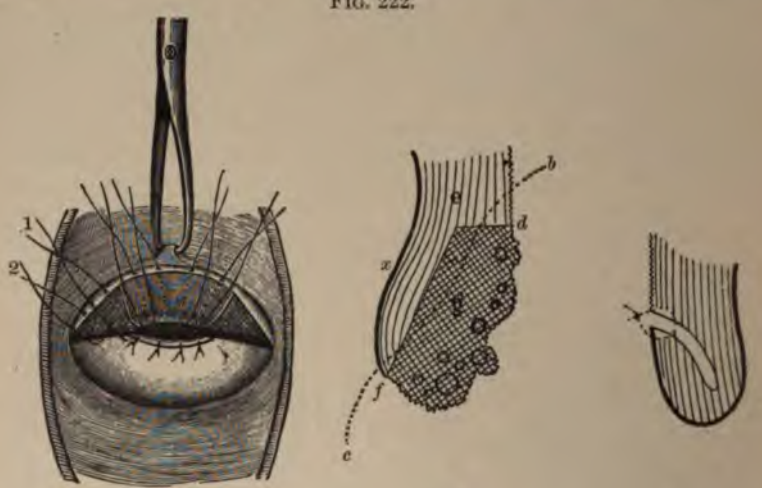

Schroeder's Single-flap Excision of the Vaginal Portion: A, excision made, sutures placed on anterior lip and tied on posterior; 1 and 2, lateral sutures. B, longitudinal section through cervix; *d e*, transverse incision; *f e*, longitudinal incision joining the first and severing the mucous membrane and part of the muscular tissue from the cervix; *b c*, course of a suture; *g*, ovula of Naboth. C, longitudinal section after the sutures are tied.

3. *Simon's Method*, the so-called *cone-mantle-shaped excision.*—After having made the two lateral incisions a wedge-shaped piece is

[1] I have had some especially made by Reynders & Co., corner Fourth avenue and Twenty-third street, New York.

cut out with a knife of the whole width of each lip from side to side. Next, the two flaps of each lip are united by sutures, and, finally, the two lateral incisions are similarly closed (Fig. 221).

This method is especially indicated when the cervix is very thick and hard and the mucous membrane of the cervical canal healthy.

4. *Schroeder's Method.*—The same lateral incisions as in the other methods are used, but then the whole mucous membrane of each lip with part of the muscular tissue is cut away. For this purpose a transverse incision is made through the mucous membrane of the cervix at the base of each lip, and then a wedge-shaped piece is cut off from the os to the first incision. Each of the lips is folded transversely, and the lower end of the cut surface united to the upper. Finally, the side incisions are closed (Fig. 222). This method is more difficult to perform, but is preferable when the cervical membrane is in a bad condition.

The removal by means of the galvano-caustic snare is less appropriate than the cutting operations, since it necessitates the healing of the wound by granulation and may lead to stenosis of the cervical canal.

If there is leucorrhea, menorrhagia, or metrorrhagia, it is proper to combine *curetting* with the amputation.

In dangerous hemorrhage *salpingo-oöphorectomy* may be performed, and if that does not suffice to arrest the loss of blood, the uterus may have to be removed by *vaginal hysterectomy*.

CHAPTER V.

Closure of the Uterus (Acquired Atresia).

In the description of malformations we have seen that atresia of the uterus may be *congenital* (p. 378), but the uterus may also become closed later in life—*acquired* atresia.

Although not so rare as the congenital form, the acquired is still a rare affection.

The closure is most common at the external os, after that at the internal os, but more or less of the whole cervical canal may be closed.

Etiology.—This condition may be brought about by adhesions forming after childbirth or abortion, cauterization with strong acids or nitrate of silver, the red-hot iron, or the galvano-caustic apparatus (p. 227). Ulceration of the cervix, diphtheria, small-pox, and scarlet fever may lead to it. Sometimes it is simply due to old age, and is especially found in old women suffering from prolapse of the uterus.

Symptoms.—In menstruating women the acquired closure gives rise to similar symptoms as the congenital closure, such as amenorrhea,

abdominal pain, menstrual molimina, and swelling of the uterus in consequence of accumulation of blood (*hematometra*), mucus (*hydrometra*), or pus (*pyometra*). If the contents of the uterus become decomposed and gases are formed, it is called *physometra*. Under these circumstances the percussion-sound becomes tympanitic, whereas otherwise it is dull.

After the menopause the atresia hardly gives rise to any symptoms, unless it is complicated with some other disease of the womb, especially cancer or fibroma.

The size of the womb in hydrometra hardly surpasses that of a fist. The walls are distended and sometimes thinner than in the normal condition. If the closure is at the external os, the cervix and the body form together one globular tumor.

The course is chronic. Sometimes the disease, especially in physometra, terminates spontaneously, the obstruction in the cervix giving way and the gas escaping.

Treatment.—The cervix should be perforated with a curved trocar and then dilated. The uterine cavity should be washed out with an antiseptic fluid, and packed with iodoform gauze (p. 175). In regard to the dangers of the operation the reader is referred to what has been said in speaking of atresia in other parts of the genital canal (p. 318).

CHAPTER VI.

Stenosis of the Cervix.

Stenosis, or narrowness, of the cervical canal is somewhat similar to atresia, but the difference is that the cervical canal is open, although the caliber is too small. Like atresia it may be *congenital* or *acquired*. It is often combined with a *conical cervix*, which may be hypertrophic, of normal dimensions, or atrophic. It accompanies also displacements, especially anteflexion.

It is most common at the external os, which forms a round opening, sometimes so narrow that it does not even admit the common uterine sound (*pinhole os*). Less frequently it is found at the internal os. Sometimes the whole cervical canal from end to end takes part in the stenosis, but in other cases it is, on the contrary, dilated between the two narrow openings so as to form a barrel-shaped cavity.

The *etiology* of the acquired form is identical with that of atresia.

Symptoms.—If the menstrual blood is secreted in larger amount than what can pass in the same time through the narrow cervix, the patient has pain (*obstructive dysmenorrhea*). Often the blood coagulates, and the clots are expelled with painful cramps. Also mucus

may stagnate in the cervix or the body and give rise to bearing-down pain, relieved from time to time by the expulsion of the accumulated fluid. Sometimes all the symptoms of chronic endometritis and parenchymatous metritis (pp. 396 and 403) are developed.

Some women are, however, in excellent health in spite of their stenosis, and they consult us only on account of sterility. Although pregnancy may take place when there is only the smallest opening admitting the spermatozoids, it is indisputable that a narrow cervical canal is a great impediment to conception.

Diagnosis.—The stenosis of the external os can be felt by a practised finger and is seen by means of the speculum. That of the internal os can only be inferred from the difficulty with which the sound passes. The beginner must, therefore, be on his guard, as he will find many cases of stenosis of the internal os, which in my experience is by no means common. The normal bore is only $\frac{1}{8}$ inch (p. 49), and it is tight enough to be distinctly felt as a yielding obstruction, when the knob of the uterine sound passes it. Before diagnosticating a stenosis of it, the physician must make sure that the end of the sound is not caught between the folds of the plicæ palmatæ or arrested by a flexion. For this purpose it must be introduced in all directions and with different degrees of curvature. The best proof that a stenosis really exists is that the common sound is arrested while a thinner probe passes.

Treatment.—Stenosis used to be treated with incision, either bilaterally or in the median line of the posterior lip. The cervical portion was split open up to the vaginal junction with *Küchenmeister's scissors*, that have a blunt and longer blade for entering the cervix and a shorter blade ending in a sharp hook, which prevents the scissors from sliding. Besides, the incision was carried more or less up to or through the internal os with *Sims's uterine knife*. For cutting the internal os and more or less of the whole cervix *Simpson's metrotome* was used, a sheathed knife, the excursion of which is regulated by a screw, and which cuts in one direction at a time, or *Greenhalgh's metrotome*, that cuts both sides at the same time. When it was found that this deep cutting not infrequently was accompanied by dangerous or fatal hemorrhage or by not less dangerous and fatal pelvic septic inflammation, superficial trachelotomy was substituted.[1] I believe that all cutting for stenosis has in a great measure fallen into desuetude. I make only a very small nick at the external os if it is necessary for the introduction of the sound. I also cut out a wedge-shaped piece of the cervix if the os besides being too narrow is situated excentrically. There is no hemorrhage, and inflammation is avoided by the use of antiseptic precautions (pp. 195 and 199).

In all other cases I only use dilatation with blunt conical and

[1] Peaslee, *Amer. Jour. Obst.*, 1876, vol. ix. p. 374.

diverging instruments (p. 153), which is much safer than any degree of incision or the use of tents. I have, indeed, never seen any trouble arise from rapid dilatation. In most cases I treat the patient in the office twice a week. I use first the lower numbers of Hanks's dilators, and then my own diverging dilator up to one-half inch expansion. I never go farther in one sitting than that the patient can stand the pain without an anesthetic. In more exceptional cases I operate in the patient's house, etherize her, use the strictest antiseptic precautions, and open the dilator to full expansion, one and a quarter inches in all directions. In order to avoid tearing the tissues this must be done very slowly and gradually. I introduce some iodoform into the cervix, and cover it with four pledgets of absorbent cotton wrung out of a solution of bichloride of mercury and powdered with iodoform. The patient is kept in bed for four days. A glass stem (see chapter on Flexions) is placed in the cervical canal while it is contracting.

The canal of the cervix may also be enlarged by means of electrolysis. For this purpose the galvanic current is to be used with the negative pole in the uterus, the positive on the abdomen. For the latter I have used Engelmann's electrode (p. 222), for the former Fry's, which has six nickel-plated conical tips, ranging from 11 to 25 millimeters in circumference, to be screwed on the same handle. I have, however, not found any advantage in the electric treatment over the mechanical.

CHAPTER VII.

Ulcers of Cervix.

We have mentioned, in treating of chronic endometritis (p. 395) that the term ulcer is often erroneously applied to *erosions* and *granulations* of the cervix. But the cervix may be the seat of true ulceration—*i. e.* an inflammatory process in which there is molecular loss of substance. Such ulcers may be *chancroids, chancres, tubercular ulcers, simple ulcers,* or *corroding ulcers.*

Chancroids have been described on p. 283 and chancres on p. 285, tuberculous ulcers p. 280 and p. 353, in treating of the diseases of the vulva and the vagina.

Simple ulceration takes place when the cervix protrudes through the vulva, be it in consequence of hypertrophy or prolapse. It is due to friction against the clothes. There is a flat more or less irregular loss of substance surrounding the os, or what seems to be it, if the case is complicated with bilateral laceration of the cervix. The surroundings have a blue or purple color and are harder than normal. With proper treatment these ulcers heal easily. If they accompany simple

hypertrophy, the cervix is amputated and no treatment directed to the ulcer. If the uterus is prolapsed, it should be replaced, kept inside the vagina by a perineal bandage, and the wound covered with a piece of lint smeared with the ointment of iodoform and Peruvian balsam (p. 173), to be changed morning and evening.

Corroding ulcer looks much like a cancerous ulcer, and is destructive in character. It may open into the bladder, but on microscopical examination no epithelial elements are found. It seems to be due to senile gangrene induced by calcification of the *internal iliac artery.*[1]

The diagnosis can only be made by means of the microscope.

The treatment is the same as for cancer, especially total extirpation before the formation of a fistula.

CHAPTER VIII.

Hypertrophy of the Uterus.

An increased size of the uterus, apart from neoplasms, is commonly due to subinvolution or chronic metritis (p. 403), but it may be due to simple hypertrophy independently of all inflammatory action. The uterus presents abnormally large dimensions, but there is no change in structure.

This hypertrophy may be *general* or *partial.*

General hypertrophy is a very exceptional condition. Partial hypertrophy has rarely its seat in the body. As a rule, then, it is the cervix that is the affected part. We distinguish between *infravaginal* and *supravaginal* hypertrophy.[2]

A.—*Infravaginal hypertrophy* consists in an increase in size of the vaginal portion of the uterus, which, as a rule, takes place chiefly or exclusively from above downward, resulting in an *elongated cervix.*

This hypertrophy may be *congenital* (p. 381) or *acquired,* and the condition differs somewhat in the two classes.

The congenitally hypertrophied cervix is only elongated, cylindrical, or conical, sometimes trunk-shaped in consequence of the greater development of one of the lips, mostly the posterior, or more rarely club-shaped. The os is round, of normal size, or too narrow. The elongation may be slight or so considerable that the cervix protrudes penis-like from the vulva.

In the acquired form of hypertrophy the cervix is commonly not

[1] John Williams, *Trans. Obst. Soc.. of London*, vol. xxvii., reprint.

[2] Schroeder has added as a third category the hypertrophy of what he calls the *intermediate portion ;* that is, that part of the cervix that is bound to the bladder in front, but has behind the deep pouch formed by the posterior fornix of the vagina (p. 42); from a practical standpoint this variety may be taken together with the supravaginal.

only elongated, but thickened, and it is frequently thicker near the end than at the base, forming a club- or cabbage-shaped mass. The os is large and forms a transverse slit. Very often the cervix has sustained bilateral laceration (p. 383), and frequently the condition is combined with prolapse of the uterus, but in these two classes of cases I think we have to deal with chronic metritis, and no longer pure hypertrophy. The acquired form is exclusively found in women who have borne many children.

Etiology.—The cause of the congenital hypertrophy is unknown. The acquired is evidently due to childbirth.

Symptoms.—Sometimes hypertrophy of the cervical portion does not give rise to any symptoms. In other cases the patient complains of a bearing-down sensation and discomfort in walking or sitting down. Sometimes she has considerable dysmenorrhea, but this is probably due to the accompanying stenosis of the os (p. 408). The friction against the vaginal walls may cause leucorrhea. When the cervix protrudes from the vulva it is liable to become ulcerated (p. 410). If the hypertrophy is pronounced, it gives rise to dyspareunia, the male member meeting with an obstruction, which is pushed forward, causing discomfort and even pain to the female, and sometimes to the male too. The semen, being ejaculated into the deep pouch formed behind the cervix, does not easily enter the os, and sterility is, therefore, quite common.

Diagnosis.—The diagnosis is easy. By vaginal examination the finger may be carried round the hypertrophied cervix. The vaginal vault is found normal. The sound may enter from three to six inches, and yet bimanual examination finds the fundus uteri at its normal place.

Prognosis.—The disease is chronic and has no tendency to retrogression. In virgins, in whom the vaginal walls and the uterus have preserved their normal resiliency, an elongated cervix does not find room enough, but is pushed down in the direction of the outlet and serves as a lever to tip the uterus backward into the position called retroversion.

Treatment.—Slight degrees of elongation may successfully be treated with dilatation (p. 152), which enlarges the os and shortens the canal. In more pronounced cases the redundant tissue must be removed by amputation. For simple elongation, Hegar's method (p. 405) is the best; for hypertrophy with thickening of the cervix Simon's cone-mantle-shaped excision (p. 406) recommends itself. In order to control hemorrhage it is a good plan to surround the base with an elastic ligature. If feasible, this should even be placed above one or two needles perforating the cervical portion at right angles and preventing the ligature from slipping, or sewed to the cervix with a few stitches. The common écraseur has the fault of having a tendency

to pull in neighboring tissue while being tightened, by which the peritoneal cavity or the bladder may be opened.

The galvano-cautery, and still more the common cautery, expose to stenosis of the cervical canal (p. 408).

B. *Supravaginal hypertrophy* consists in the increase, especially elongation, of that part of the cervix that is situated above the utero-vaginal junction.

Pathological Anatomy.—The supravaginal part of the cervix is felt as a long cylindrical body, somewhat flattened in the antero-posterior direction. As a rule, it is of normal circumference, but exceptionally it may either be thinner or thicker than normal. The dimensions of the infravaginal portion and of the body are not much increased. In growing the cervix descends, and pulls the neighboring organs down with it. Thus the vaginal fornix sinks down. In front the pouch formed by it disappears entirely, while behind more or less of it still remains. The vagina becomes inverted. The bladder forms a swelling in front of the hypertrophied cervix (cystocele); Douglas's pouch descends with it behind, and sometimes there is a rectocele, but in many cases the rectum retains its place. The os uteri forms a large slit, and descends to or beyond the rima pudendi. The interior of the uterus measures from six to ten inches in depth, the increase coming nearly exclusively from the elongation of the upper part of the cervix.

Etiology.—This condition is due to prolapse of the vagina (p. 331). The body of the womb remaining in its place, and the cervix being pulled down, it is drawn out like a rubber tube. At the same time free circulation is impeded, the blood stagnates, and chronic metritis sets in, with formation of new cells, new connective tissue, and new muscle-fibers, rendering the total increase in bulk possible.

Those conditions which promote prolapse of the vagina, such as laceration of the vaginal entrance, frequent childbirth, too early getting up after delivery, subinvolution, occupations that keep the woman in a standing position, and venereal excesses, lead indirectly to hypertrophy of the supravaginal cervix.

Symptoms.—The symptoms are like those of prolapse of the vagina and uterus, combined with those of infravaginal hypertrophy. The patient complains of bearing-down, backache, an uncomfortable sensation in the vagina, especially in walking and sitting down. She has often dysmenorrhea. She has frequent desire to micturate, and finds it often difficult to empty the bladder. She is constipated. The friction in the vagina produces leucorrhea, especially in the posterior pouch. Connection is rendered unsatisfactory.

That part of the vagina that is turned out of the body becomes horny, like epidermis. The enlarged cervix is seen and felt, while the body of the uterus is felt above of nearly normal size, often anteflexed, and the infravaginal portion is not much elongated, if at all.

Nearly always there are signs of bilateral laceration of the cervix, and the cervix partakes in the inversion, so that the lips of the os uteri are situated far apart, and the inverted cervical canal appears between them, more or less inflamed or even ulcerated (p. 410).

Diagnosis.—A *polypus* and an *inverted uterus* have no opening at the lower end. In the *infravaginal hypertrophy* the vaginal vault is normal. The chief point in the diagnosis is the distinction from *prolapse of the uterus*, with which the supravaginal hypertrophy is often confounded, but the finger-shaped mass formed by the cervix is easily felt by bimanual palpation with one finger in the rectum; the uterus is felt in its place; the uterine cavity is much deeper; a catheter introduced into the bladder is not felt from the rectum, the uterus intervening between the two canals. Frequently, however, the hypertrophy is combined with prolapse.

Prognosis.—No spontaneous cure is to be expected.

Treatment.—In the lesser degrees the uterus may be pushed up, the body becoming strongly anteverted, and much comfort may be afforded by the use of a cup-shaped supporter attached to an abdominal belt. (See *Prolapse.*) If this plan does not succeed, recourse must be had to an operation.

1. *Hegar's Method, funnel-shaped excision* (Fig. 223).—Dorsal posture. The cervical portion is exposed with a single Sims specu-

FIG. 223.

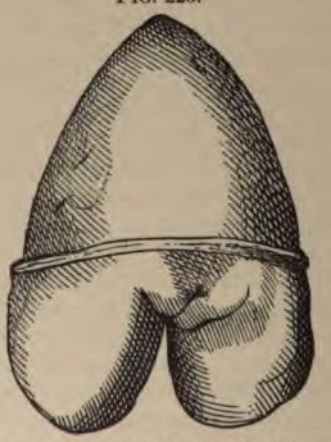

Hegar's Funnel-shaped Excision of Supravaginal Cervix (natural size).

lum and lateral retractors, seized with a volsella, and pulled down. A circular incision is made below the utero-vaginal junction. From this the knife is carried in a slanting direction upward and inward to the cervical canal. When the canal has been opened in front and the

hemorrhage is considerable, a suture is passed immediately under the whole wound in the cervix, and so as to comprise the mucous membrane of the canal. If there is not much bleeding, the excision is continued from the sides and from behind with knife and scissors. The excised piece forms a cone, the length of which above the utero-vaginal junction may be $1\frac{1}{4}$ to $1\frac{1}{2}$ inches or more. The mucous membrane of the cervix is sutured all around to that of the vagina, passing the sutures with small, strongly curved needles under the whole wound—a procedure that is very difficult. Some prefer, therefore, to apply the thermo-cautery as soon as a part is cut, and continue alternating with the cutting and the searing instrument.

2. *Schroeder's Method* is still more radical. A circular incision is made as in Hegar's. If vaginal arteries bleed, the hemorrhage is

FIG. 224, *A*.

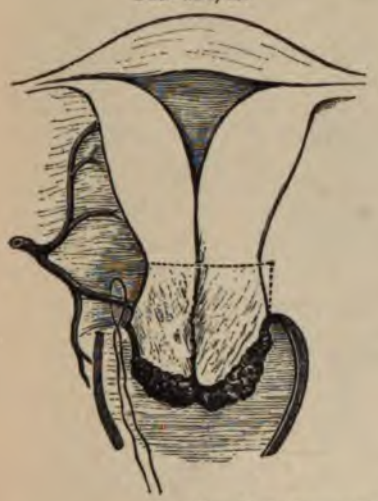

FIG. 224, *B*.

Shroeder's Supravaginal Amputation of Cervix.

checked with ligatures or clamps. Then the cervix is separated with the finger and blunt instruments in front and behind. Next it is pulled over to one side, and with a half-blunt aneurism-needle bent to the side (Fig. 258) a ligature is carried around the tissue going to the side of the cervix and containing the blood-vessels. After having tied the ligature tightly and cut the tissue between the ligature and the cervix, another ligature is placed above the first. The other side is treated in the same way.

When the cervix has been loosened sufficiently high up, the anterior wall is cut through to the cervical canal, and a deep suture is carried through the vaginal wall, the parametral connective tissue, and

the severed cervical wall, and out through the cervical canal. If necessary to check hemorrhage, several such deep sutures are passed and tied before the posterior wall is severed. These sutures are left long, and serve to keep the uterus down. When the posterior part of the cervix has been cut, it is treated in the same way as the anterior, thus stitching the uterus all around to the vagina.

If it happens that the peritoneal cavity is opened, the rent may be closed separately with silk or catgut, or comprised in the sutures fixing the posterior cervical wall to the vagina.

The vagina being much larger in circumference than the cervix, it forms folds and on the sides two gaps, through which the ligatures hang down.

3. *Kaltenbach's Method* (Fig. 225).—After emptying the bladder and pushing the intestines up from Douglas's pouch, the cervix is

FIG. 225.

Kaltenbach's Supravaginal Amputation of the Cervix.

constricted at the vaginal entrance with an elastic ligature, which is stitched to the inverted vagina, or the uterine artery is secured on both sides (p. 177). A circular incision is made, and the elongated supravaginal cervix is easily separated from the surrounding tissue with knife and scissors, and even partly with blunt instruments. When this has been done to the extent deemed necessary, sometimes even above the internal os, the cervix is divided with Küchenmeister's scissors (p. 409) into an anterior and posterior half, and each half cut off separately, so as to preserve a small flap of cervical mucous membrane on each half. These flaps are stitched to the vaginal wall with three or four deep sutures, which are made to emerge in the middle of the large supravaginal wound.

Next, a triangular piece is cut out of the inverted vagina on either side, and a couple of deep sutures passed through the edges and around the vessels running on the side of the cervix. This excision allows us to exercise tighter pressure on the ligated blood-vessels, and diminishes the size of the fornix.

This is the best of all the cutting operations, in so far as it exposes less to hemorrhage.

Still safer is, however, the amputation of a conical piece of the cervix, as in Hegar's operation, by means of the galvano-caustic knife and wire (p. 227). But even this does not prevent secondary hemorrhage, and is liable to cause stenosis of the cervical canal (p. 408). The patient should, therefore, be carefully watched during the healing process.

Besides primary and secondary hemorrhage, the supravaginal amputation with its large, deep-seated, more or less anfractuous wound predisposes to sepsis.

4. *Vaginal Hysterectomy.*—These drawbacks are avoided by removing the whole uterus, which may be done from the vagina or from the abdomen. The vaginal operation will be described below under *Prolapse of the Uterus.*

5. *Abdominal Hysterectomy.*—If the supravaginal hypertrophy of the cervix is combined with such an hypertrophy of the body that the removal of the uterus through the vagina would be difficult, it may be undertaken through the abdominal wall, exactly as for a myomatous uterus. (See below, under *Fibroid.*)

CHAPTER IX.

Acquired Atrophy; Superinvolution.

Atrophy of the uterus may be congenital or acquired. We have described the congenital form above (pp. 379–380) as the *fetal*, the *infantile*, and the *pubescent* uterus.

Acquired atrophy is a normal condition after the climacteric (p. 121),—*senile atrophy*,—but in consequence of the atrophy closure of the cervical canal, especially at the external or internal os, may occur and give rise to hydro- or pyometra (p. 408).

Pathological Anatomy.—In the non-puerperal form the uterus is small, the vaginal portion disappears sometimes entirely, so that the vagina ends in a narrow funnel, at the bottom of which is situated the os. The tissue is hard, its arteries often calcareous, and it sometimes contains foci of extravasated blood. The cavity of the uterus is less deep than normal.

The *puerperal atrophy* differs in some respects from the non-puer-

peral form. The walls are thin and often very soft, and the uterine cavity may preserve its normal depth.

Etiology.—Puerperal atrophy, or superinvolution, is a rare disease. It is, perhaps, oftener connected with abortion than with childbirth. It is caused by loss of blood, protracted lactation, debilitating diseases, such as scarlet fever, tuberculosis, chlorosis, syphilis, diabetes, Bright's disease, and exophthalmic goiter.

Atrophy can also be caused mechanically by pressure of a uterine fibroid or an ovarian cyst.

It may be brought about by trachelorrhaphy, amputation of cervix, or oöphorectomy.

Sometimes salpingo-oöphoritis seems to be the cause of it, and it has been found together with paraplegia.

Symptoms.—Senile atrophy does not give rise to symptoms unless it is combined with atresia.

Before the climacteric atrophy is characterized by amenorrhea and sterility. Some patients complain of sacral pain, headache, insomnia, mental depression, anorexia, indigestion, and general weakness. Sometimes the uterine cavity measures only an inch or an inch and a half, but in the puerperal form the sound often enters to the normal depth (pp. 49 and 150). Its knob is felt with unusual distinctness through the abdominal wall.

Prognosis.—Puerperal superinvolution is sometimes only transitory, whereas the other forms are permanent.

Treatment.—The treatment is the same as for congenital atrophy (p. 38).

CHAPTER X.

Gangrene.

Gangrene of the uterus may occur as a result of puerperal infection. An inverted uterus, a fibroid, or a cancerous tumor, may slough, and in this way a spontaneous cure may take place.

Treatment.—The patient's strength should be kept up by means of quinine, strong alcoholic drinks, and nourishing food. Locally, frequent antiseptic injections should be used in the vagina (p. 168), and even in the interior of the uterus.

CHAPTER XI.

Hysteralgia.

Hysteralgia, or *neuralgia of the uterus*, may be *idiopathic* or *symptomatic*.

Idiopathic hysteralgia is a rare disease.

Etiology.—It is most common at the menopause, but may be found in young girls, especially before menstruation is well established. It is also found in anemic, nervous, and hysterical women. Sometimes it is of malarial origin or due to rheumatism.

Symptomatic hysteralgia may accompany any of the organic diseases of the womb, especially metritis and cancer.

Symptoms.—Hysteralgia is characterized by sudden attacks of severe pain in the uterus, often radiating to the sacral region, the iliac fossa, and down the leg, which recur with regular or irregular intervals.

Diagnosis.—The chief point is to discover whether the affection is purely nervous or the neuralgic attacks accompany organic disease.

Prognosis.—The prognosis is favorable if the neuralgia is not grafted on malignant disease.

Treatment.—During the neuralgic attack nothing equals in certainty and swiftness of action the hypodermic injection of morphine. In the intervals the underlying disease, if any, should be treated, and the idiopathic form treated, according to the etiology, with tonics (p. 217), antiperiodics, or antirheumatic medicines. The galvanic current, with the positive pole in the vagina or uterus (pp. 223–224), is very effective.

CHAPTER XII.

DISPLACEMENTS.

THE normal shape and position of the uterus have been discussed above (p. 51), and we have seen how it changes position according to the degree of fullness or emptiness obtaining in the bladder and the rectum (p. 53). Every breath makes it perform a see-saw movement. During inspiration the fundus is pushed forward and downward, while the cervix moves upward and backward. During expiration the opposite movement takes place. During urination and defecation it is pushed down; during copulation it is lifted up. It is therefore clear that the uterus is an unusually mobile organ. But certain permanent changes and deviations from the normal take place under certain conditions, and constitute the so-called displacements. These are *anteversion*, *anteflexion*, *retroversion*, *retroflexion*, *lateroversion*, *lateroflexion*, *anteposition*, *retroposition*, *lateroposition*, *prolapsus*, *elevation*, *inversion*, and *hernia*.

Anteposition, retroposition, and lateroposition, if they are not due to pressure from a neighboring tumor, are developmental abnormalities of merely anatomical interest (p. 381).

A. *Anteversion.*

Anteversion (Fig. 226) is that position of the uterus in which the fundus points forward, and sometimes downward, to the symphysis pubis, the os backward, and sometimes upward, toward the sacrum.

FIG. 226.

Anteverted Uterus (Fritsch).

The uterine canal preserves its normal direction in a line that is straight or slightly curved forward (p. 52).

Pathological Anatomy.—The uterus is more or less enlarged and in a condition of chronic metritis. Sometimes adhesions are found between the fundus and the peritoneum or signs of cellulitis round the cervix; or the ovary or tube may be found adherent to the anterior wall of the pelvis. Often the vaginal portion is unusually short.

Etiology.—Anteversion is due to inflammation of the parenchyma of the womb, in consequence of which the organ becomes larger and heavier and tips down in the erect and sitting posture; or to inflammation of the pelvic peritoneum or the appendages, in consequence of which the fundus uteri is dragged forward and downward.

Anteversion is sometimes due to subinvolution after childbirth or abortion, but is not rare in virgins.

Symptoms.—These are the same as in chronic endometritis and parenchymatous metritis (pp. 396 and 403), especially frequent mic-

turition, dysmenorrhea, menorrhagia, leucorrhea, and sterility. The frequency of micturition is probably due to pressure of the enlarged uterus, just as we commonly find it in pregnancy. The dysmenorrhea may be mechanical, the exit for the blood being less free when the uterine canal is horizontal or even lies higher with its open than with its closed end; or it may be explained by the increased sensitiveness due to the inflammation of the uterus or its surroundings. The menorrhagia and leucorrhea are likewise probably due partly to mechanical interference with free circulation and partly to the structural changes in the uterus.

If there are no adhesions, a peculiar, uncomfortable feeling is produced by the movements of the enlarged and stiff uterus.

Diagnosis.—By bimanual examination the fundus of the uterus is found tipped forward, the anterior surface forms a straight line or nearly so, and the os is not situated centrally in the pelvis, within easy reach, but points backward and is only reached with difficulty.

Prognosis.—Anteversion does not threaten life, but is hard to cure, mechanical disadvantages increasing the troubles inherent in the subjacent inflammatory conditions.

Treatment.—The treatment is directed against the inflammation, and is intended to overcome the mechanical disadvantage. In regard to the first, the reader is referred to what has been said above (pp. 399–402 and 404–405). The remedies especially useful are the hot

FIG. 227.

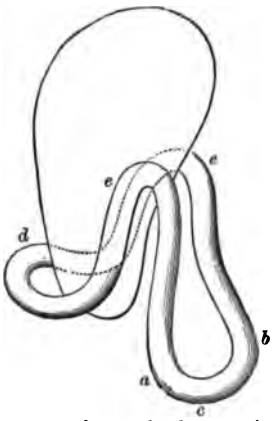

Graily Hewitt's Anteversion Pessary: *a b*, anterior bow resting on the anterior wall of the vagina; *c e*, upper end pressing on the anterior surface of the uterus; *d*, posterior bow going behind cervix.

douche, glycerin or ichthyol tampon, scarification, electrolysis, gold, corrosive sublimate, massage, and hemostatic measures (pp. 177 and 218).

The uterus may be lifted up by means of vaginal *pessaries*—that

is, supporters. Those most used for this purpose are Graily Hewitt's cradle pessary (Fig. 227) and Thomas's (Figs. 228 and 229) two

FIG. 228.

Thomas's Anteversion Pessary: *A*, lower end resting just inside the vaginal entrance; *B*, upper end to be introduced in the posterior pouch of the fornix; *C*, anterior, movable bow, which is to lift the uterus through the anterior pouch of the fornix.

FIG. 229.

Thomas's Horseshoe-shaped Anteversion Pessary.

kinds of anteversion pessaries, Gehrung's pessary, (Fig. 230) and Thomas's modification of Cutter's (Fig. 231). If the uterus bends

FIG. 230.

Gehrung's Pessary.

FIG. 231.

Thomas's Modification of Cutter's Anteversion Pessary.

over these instruments and an anteflexion is formed, they do, however, more harm than good. There is a soft-rubber Vienna pessary consisting of a thick elastic ring which surrounds the cervix, and a straight piece lying in the canal of the vagina, which I occasionally have found useful.

General Remarks about Pessaries.—Some pessaries, such as elastic rings, work by pressing excentrically on the vaginal walls; others, a class to which the above-mentioned Thomas pessary (Fig. 228) belongs, rest against the muscles and fasciæ forming the vaginal entrance;

Gehrung's pessary and Thomas's horseshoe pessary find support on the anterior and the posterior vaginal walls.

In the choice of a pessary great care should be taken never to choose a larger one than necessary. If it is made of some hard material, it is liable to erode, and even to burrow deep into the flesh and perforate the rectum or the bladder. The vagina ought, therefore, to be inspected three or four days after the introduction of a pessary, in order to make sure that there is no erosion, and later the examination ought to be repeated at least once every two months. If at any time it is found that the vagina becomes excoriated, the pessary ought to be left out for a week, during which the patient should use injections with carbolized water.

In order to avoid erosion the ring forming the pessary should be rather thick and perfectly smooth.

Soft rubber, and in some women even hard rubber, emits an unpleasant odor when in contact with vaginal discharges. This may be obviated by using block-tin for the construction of the pessary, but that has the fault of being heavy. An excellent material is aluminium.

Pessaries are introduced while the patient occupies the dorsal or left lateral position. In antedeviations the former is preferable, in retrodeviations the latter. The uterus ought, as a rule, to be replaced in the right position with the fingers or sound before introducing the pessary, just as fractures are set before the splint is applied. The pessary, except the part seized by the physician, should be smeared with a lubricant (p. 138).

Graily Hewitt's cradle pessary is inserted with the patient on her back. First, one ring is introduced inside of the vaginal entrance along the posterior wall of the vagina, then the middle part is pushed up in front, and finally the second ring. The first ring is placed round the cervix; the middle part presses against the anterior fornix of the vagina; and the second ring rests on the anterior vaginal wall. In removing it the index-finger is hooked into the lower ring and pulled back. Thus this ring will come out first, rolling over the perineum, then the middle piece, and finally the upper ring.

Thomas's anteversion pessary with movable front bow is introduced closed behind the cervix, and then withdrawn a little, so as to allow one to separate the anterior bow from the rest of the instrument and push it in front of the cervix; finally, the whole is pushed up until both bows rest on the vaginal vault, one in front and the other behind the cervix. (Compare rules for introducing Hodge's pessary under Retroflexion.)

Thomas's horseshoe-shaped pessary is introduced open; the horseshoe is placed against the anterior surface of the uterus, and the lower bow turned forward against the anterior vaginal wall. In withdraw-

ing it this bow is seized, when the remainder of the instrument follows easily.

Gehrung's pessary is placed with the upper horseshoe turned down on a table, the two bows uniting the horseshoes pointing toward the doctor. Next he seizes the nearest bow with the right thumb and index, pushes the opposite bow into the right side of the pelvis, then the bow he holds, into the left side, and finally he turns the whole pessary in the vagina, until the two uniting bows rest on the posterior wall and the two horseshoes embrace the cervix anteriorly. In withdrawing the same movements are gone through in opposite order.

Cutter's pessary can be removed and replaced by the patient herself. The bulb is placed in front of the cervix; the lower end arches over the perineum, and is attached to an abdominal belt. It is only worn in day-time.

The best-fitting pessary irritates the vagina somewhat. Whenever one is worn the woman must therefore at least once a day use an injection of lukewarm water, to which may be added a teaspoonful of borax or carbolic acid in order to keep the pessary clean. She should also be instructed to remove it immediately if it causes pain, as neglect in this respect may cause serious pelvic inflammation.

An elastic *abdominal belt* may give comfort by taking off pressure from above and steadying a large mobile uterus. The latter object is attained still better by an abdominal supporter with a solid hypogastric pad, such as Fitch's (Fig. 160, p. 187).

Certain *operations* have proved useful in different ways. If the cervix is thick, Simon's cone-mantle-shaped excision (p. 406) may be performed, and result in a considerable reduction in the size of the body of the uterus (p. 405).

Sims folded the anterior wall of the vagina transversely, denuded the edges of the fold just in front of the cervix and an inch and a half lower down, and united the two somewhat crescent-shaped surfaces with silver-wire sutures (p. 210).

B. *Anteflexion.*

We know from the anatomical part (p. 52) that the canal of the uterus is normally straight or slightly curved, with the concavity forward, or slightly S-shaped. When it forms a more decided curve or an angle, the condition is abnormal, and is called anteflexion (Fig. 232).

Classification.—A time-honored division of anteflexion is that according to the size of the angle between the cervix and body, an obtuse angle constituting the *first degree*, a right angle the *second*, and an acute angle the *third*. A better classification, because of greater practical value in regard to treatment, is that into *corporeal*, in which the body of the womb dips too far forward and downward,

while the cervix has the normal direction; *cervical*, in which the cervix is turned forward; and *cervico-corporeal*, in which both the body and the neck are turned forward; each of which varieties may again be *reducible*—that is, the flexion can be overcome with pressure of the fingers or by the introduction of a sound; or *irreducible*, when the uterus cannot be straightened.[1]

Still another classification is that which distinguishes a *congenital*, or rather *developmental*, form from an *acquired*.

Pathological Anatomy.—The bend in the uterus is, as a rule, situ-

FIG. 232.

Anteflexion (Graily Hewitt).

ated at the internal os, but may exceptionally be situated higher up in the body or lower down in the neck. At the angle is often found fatty degeneration, atrophy, or cicatricial tissue. The uterus is often in a condition of chronic metritis (p. 403), with enlargement of the cavity. Frequently the supravaginal portion is elongated (p. 413). In the developmental form the anterior vaginal wall is short, the cervical portion elongated and coniform, with a small os, which sometimes is situated on the anterior surface instead of the end of the cervix. Sometimes the sacro-uterine ligaments are swollen or shortened. The fundus may be bound with adhesions to the anterior wall of the pelvis, or similar adhesions implicate the ovaries and tubes.

[1] T. G. Thomas, *Gynecol. Trans.*, 1888, vol. xiii. p. 142—a paper of the greatest value to anybody who undertakes to treat anteflexion.

Sometimes the anteflected uterus is at the same time anteverted or retroverted.

Etiology.—The uterus undergoes a great development from the time of approaching puberty until the woman is full grown, say between the ages of twelve and twenty years (p. 33). During this time it is more liable to become anteflexed than after it is fully formed. The pressure of corsets (p. 127) and the weight of heavy skirts are apt to force the body down. An accumulation of hard scybala in the rectum presses the cervix forward and impairs the general health (p. 126), which again weakens the tissue of the womb. The latter condition is also a consequence of lack of substantial food (p. 126). Masturbation (p. 289) causes hyperemia, and thus furthers anteflexion. Exposure during menstruation (p. 127) may have a similar effect.

The acquired form is mostly due to inflammation of the uterus or its surroundings: metritis, which makes the uterus heavier; cellulitis around the utero-sacral ligaments, which pulls the angle between corpus and cervix upward and backward; and perimetritis or inflammation of the appendages, resulting in adhesions pulling the fundus forward and downward. These inflammations are again caused by gonorrheal or puerperal infection, or are simply due to colds; that of the sacro-uterine ligaments may also originate in irritation caused by the passage of hard scybala.

Anteflexion may also be due to subinvolution following childbirth or abortion; pressure from an abdominal tumor; the presence of a growth, especially a fibroid, in the wall of the corpus; and softening of the uterine parenchyma in consequence of wasting diseases or insufficient nutrition.

Symptoms.—Sometimes women with pronounced anteflexion enjoy perfect health, and the only thing that brings them to the physician is sterility. The symptom next in frequency is dysmenorrhea (p. 233), which may be due to obstruction at the angle with formation of clots, and which, perhaps, in other cases is rather attributable to the concomitant inflammation, the menstrual congestion pressing on the tender inflamed tissue of the womb or the surrounding parts. Young girls affected with the developmental form may also suffer from amenorrhea. The patient often complains of pelvic pain or diverse reflex disorders, especially pain in the epigastrium, with dyspepsia, intercostal neuralgia, headache, backache, asthenopia (p. 396), etc. She has often leucorrhea. She is often inconvenienced by frequent micturition, as in anteversion. Anteflexion predisposes to abortion and to hyperemesis during pregnancy.

Diagnosis.—When the cervix is turned forward the observer might think of *retroversion*, but by bimanual examination the whole shape of the womb, and especially the presence of the fundus at the anterior vaginal fornix, is distinctly felt. If in stout women there is any

doubt, the flexion is felt still better by placing the patient in Sims's position, when the fundus tips forward on the examining finger. The direction of the canal can be made out with the sound or probe (p. 151).

In *anteversion* the os points backward and the uterus is straight.

The presence of a *fibroid* in the anterior wall can be made out by introducing a sound, which will enter with the normal curvature turned forward, and feeling the tumor between the sound and the vaginal vault.

Inflammation and shortening of the sacro-uterine ligaments are characterized by the high position of the vaginal portion, its approximation to the posterior wall of the pelvis, its forward direction, and the diminished or suspended mobility of the uterus. By direct palpation through the anus one or both folds are felt swollen, tender, or hardened.

Prognosis.—Less pronounced cases are much benefited by treatment, and often cured, especially if pregnancy occurs, which is often the case. Otherwise there is tendency to relapse. I have never seen an anteflexed womb become straight, but the symptoms may disappear and the patient feel well. Irreducible cases have to be treated with operations which are neither free from danger nor sure to cure.

Treatment.—The treatment is partly directed against the inflammation and partly it is orthopedic. The patient should avoid violent exercise and tight lacing. Her skirts should be suspended by means of braces from the shoulders. Her bowels should be kept open, and a tonic treatment followed in regard to food, regimen, and medicines (p. 217).

Congestion and inflammation are combated with hot vaginal douches (p. 166), glycerin or ichthyol tampons (p. 173), painting with iodine (p. 165), and scarification (p. 182). When there is a tendency to hemorrhage, curetting (p. 171), with or without intra-uterine packing with iodoform gauze (p. 175), does much good.

The sound is introduced with a curvature nearly as strong as that of the uterine canal, withdrawn, straightened, and reintroduced. Soon, if not in the first sitting, it is turned with the concavity backward, establishing a transient retroflexion. The uterus may also be stretched bimanually by pushing the cervix back with a finger in the vagina, and pressing, with the other hand, on the fundus through the abdominal wall. If the patient is treated at home, she should continue in the dorsal posture for an hour, keeping up pressure on the replaced fundus by means of a hard-rolled towel applied over the symphysis.

Mild or complete dilatation with Hanks's and my dilators (p. 153) not only overcomes the obstruction in the canal at the angle, but straightens the whole uterus. By the insertion of a glass stem while it

recontracts, a better shape may be obtained. Permanent dilatation is secured by Outerbridge's instrument (p. 181).

Some praise electrolysis (p. 410).

Fig. 233.

Intra-uterine Stem and Retroflexion-Pessary with Cup (T. G. Thomas).

An abdominal belt or supporter (pp. 186, 187) may serve to take off pressure from above.

The same pessaries as for anteversion may be used for anteflexion. Personally, I have almost abandoned them, and find that I obtain better results without them.

If a vaginal pessary may irritate and cause inflammation, the *intra-uterine stem* (Fig. 233) is still more dangerous.[1] It should be of glass, and half an inch shorter than the cavity of the uterus. It may be solid or hollow, straight or slightly bent. In order to hold it in place, it is sometimes combined with a vaginal pessary having a little cup into which the plate of the stem fits. It should have a string attached to it. It is introduced with the fingers or a dressing forceps (p. 148) through a Sims speculum.

Irreducible cases may be treated by one of the following operations:

1. *Sims's Discission of the Posterior Lip.*—The patient is in Sims's position; the cervix is exposed with his speculum; the posterior lip is cut in the median line up to the vaginal junction with Küchenmeister's scissors; and a second incision carried in a straight line from the internal os to the upper end of the first incision. The wound is packed with iodoform gauze, and the vagina tamponed as long as there is any danger of hemorrhage. The dressing is changed daily. The patient should stay in bed until the wound is healed; that is, from two to four weeks. When granulation is established an intra-uterine stem may be introduced. The granulating wound is often slow to heal, and may give rise to a troublesome discharge resisting astringent applications.

2. *Amputation of the Cervix.*—If there is considerable flexion of the cervix with elongation, the cervical portion is removed by Hegar's method (p. 405).

3. *Dudley's Operation.*—Recently[2] a plastic operation has been proposed with a view to straighten the anteflexed uterus. The patient

[1] Garrigues, "Case Illustrating the Danger of Stem Pessaries," *Amer. Jour. Obst.*, 1879, vol. xii. p. 756.

[2] E. C. Dudley of Chicago, *Amer. Jour. Obst.*, 1891, vol. xxiv., p. 142.

occupies the left lateral position. The cervical canal having been exposed with Sims's speculum, a little dilated, and the uterus curetted and disinfected, the cervix is divided with scissors considerably past the utero-vaginal junction. The cut surfaces are separated with tenacula, and the incision somewhat deepened, especially on the side of the cervical canal. On each side the surface thus incised is now folded upon itself from before backward, and secured by silkworm-gut sutures. Thereby the os externum is carried directly back to the angle of the incision. Then the anterior lip of the cervix is caught with a tenaculum and partially removed, the section extending to the external os, but not into the canal. This cut surface is folded upon itself from side to side and secured with deep sutures.

4. *Salpingo-oöphorectomy.*—If the flexion is caused by, or at least combined with, inflammation of the uterine appendages, and milder means do not lead to a satisfactory result, much benefit may be obtained by removal of these organs.

C. *Retroversion.*

The retrodeviations or displacements backward of the uterus are twofold—*retroversion*, corresponding to anteversion; and *retroflexion*, corresponding to anteflexion.

In *retroversion* the uterus as a whole is tipped backward over a transverse axis. According to the degree to which the tilting is carried the os points downward or forward against the symphysis pubis, and the fundus, just opposite it, turns upward or backward toward the sacrum. The longitudinal axis is straight. In most cases retroversion is only a transition to retroflexion; the pathology, the symptoms, and the treatment are identical, and, since the flexion is so much more common than the version, we prefer to describe them under that heading.

Diagnosis.—We have seen above (p. 406) that the direction of the cervix might lead one to think of *anteflexion*, but by bimanual examination and the sound the direction of the fundus backward is easily made out. An anteflexed uterus may at the same time be retroverted. Then it is curved or bent forward, os and fundus being approximated in front of the anterior surface, and this curved uterus is tilted backward as a whole. In these cases the os is turned forward and upward, the fundus or the posterior surface is felt lying against the rectum, the anterior surface is felt concave, and the posterior convex. The difference between retroversion and *retroflexion* is that in version the uterus forms a straight line, while in flexion it is bent with the concavity backward.

D. *Retroflexion.*

Retroflexion is that displacement in which the body of the uterus is bent backward, the cervix remaining in its normal position (Fig.

234). It is often combined with retroversion, when the os points downward and forward.

Pathological Anatomy.—Besides the peculiar shape of the uterus, we find, as a rule, signs of chronic metritis, and often of pelvic peri-

FIG. 234.

Retroflexion of the Uterus (Fritsch).

tonitis, salpingitis, oöphoritis, or cellulitis. In many cases adhesions are found between the posterior surface and the rectum or between the appendages and broad ligaments and the posterior wall of the pelvis. Most of these adhesions are thread-like and friable; others are spread over a large surface and very tough.

The uterus is commonly enlarged, situated lower down than normal, and has a large os and a thick cervix.

Retroflexion may by twisting the broad ligaments interfere with the free circulation in the pelvic veins.

Etiology.—Retroflexion may be congenital, but that is much rarer than congenital anteflexion. As a rule, it is acquired. It may be due to subinvolution after childbirth. Parts of the placenta may remain attached to the anterior wall and cause incomplete involution, by which the anterior wall becomes larger than the posterior, and a retroflexion is the result. A frequently over-filled bladder may predispose to it. In the normal condition the abdominal pressure from above

in the erect posture keeps the uterus in an anteverted and often slightly anteflexed position; but when the fundus is lifted up, so that the direction of the pressure comes to lie in front of it, the uterus is more and more tipped and bent backward. This will be favored by weakness of the round and broad ligaments, which again, in most cases, is a sequel of childbirth.

This tilting may also be due to elongation of the cervical portion, or to shallowness of the cul-de-sac at the posterior vaginal fornix. The most common cause is some form of perimetric inflammation. Endometritis, very often gonorrheal in origin, leads to salpingitis, the inflammation spreads to the peritoneum, and adhesions are formed between the broad ligaments, the appendages, and the uterus on one side, and the posterior wall and the floor of the pelvis with the rectum on the other; which adhesions drag these organs with them backward and downward. In other cases the inflammation may spread directly through the wall of the uterus, and cause parenchymatous metritis and perimetritis with adhesions between the fundus and posterior surface of the uterus in front and the rectum behind.

Symptoms.—In rare cases retroflexion does not give rise to any symptoms. In most they are those usually found in uterine disease, and especially in chronic metritis (p. 403): pain, dysmenorrhea, menorrhagia, metrorrhagia, leucorrhea, dyspareunia, and dysuria. Sterility is not so common as in anteflexion, the direction of the uterine canal being more favorable for the entrance of the semen. Constipation is very common, and is easily explained by the mechanical obstruction offered by the fundus pressing against the rectum. Nervous reflexes and general malnutrition are, as a rule, prominent features.

Diagnosis.—By bimanual examination the peculiar shape and position of the uterus are easily made out. It is not enough to feel a mass in the posterior cul-de-sac of the vagina. That may as well be a *fibroid* in the posterior wall of the uterus or an *exudation in Douglas's pouch.* If the uterus cannot be mapped out, the direction of the uterine cavity may be ascertained with the sound or probe.

There are cases of flabby uterus without adhesions in which the corpus moves at the level of the internal os, as if there were a hinge, and the uterus is soon found anteflexed and afterward retroflexed.

A chief point in the diagnosis is to discover whether the uterus is movable or bound by adhesions. For this purpose examination in the dorsal decubitus is insufficient. Sometimes a uterus can be replaced with the sound in this position in such a way that the anterior wall of the rectum follows the uterus. This is not the case in the genu-pectoral position. By introducing a finger into the rectum in this position the adhesions are felt as tense bands.

Sometimes it is possible, under ether, to lift a retroflexed uterus

which seems immovable, out of the pelvis, and to retain it there by a pessary.

Prognosis.—In the great majority of cases we may expect to cure the patient, or at least make her comfortable, with a pessary. Retro-displacements predispose to prolapse. If pregnancy occurs, a serious condition may be brought about in case the uterus does not rise spontaneously out of the pelvis. In a minority of cases more or less dangerous operations are necessary in order to procure relief.

Treatment.—If the uterus and its surroundings are tender, the inflammation should be combated with hot vaginal douches (p. 177), painting with iodine (p. 165), and ichthyol or glycerin tampons (p. 173) before any attempt is made to replace and retain the uterus in a better position. If there are signs of chronic metritis, curetting (p. 171) and packing with iodoform gauze (p. 175) may reduce the bulk of the uterus and form a useful introduction to other measures.

Replacement.—The retroflexed uterus may be replaced in different ways.

Air-pressure.—One way is to place the patient in the genu-pectoral position (p. 136) and introduce Sims's speculum. In rare cases this may suffice to make the fundus uteri spontaneously sink forward. The pressure may be increased by means of a sponge on a sponge-holder or a cotton tampon held in a dressing-forceps applied against the posterior vaginal vault.

Bimanual Manipulation.—Another way is to place the patient in the dorsal decubitus, introduce one or two fingers into the vagina, and press their tips, with the volar surface turned up, into the posterior vault. The four fingers of the other hand are inserted above the symphysis pubis and press the abdominal wall down until the fundus of the uterus is reached and can be pulled forward, while the vaginal fingers push in the same direction. This method can only be used on rather lean patients.

Digital Pressure.—A good way is to place the patient in Sims's position and introduce the middle and index-fingers into the vagina with the dorsal surface turned against the back of the uterus, and press upward and forward. If the uterus is enlarged, some advantage is obtained by directing the pressure toward the sacro-iliac synchondrosis.

Repositors.—Special instruments have been invented for replacing the uterus, but the simplest way is to do it with the uterine sound. It is introduced as described on p. 150, but with the concavity turned backward, and when the knob has passed the internal os the handle is pushed forward until the knob touches the fundus. Then the handle is made to circumscribe one-half of a large circle, so as to keep the knob on the same point in the interior of the uterus. When the concavity turns forward, the handle is brought gently back, the index-finger of the left hand helping to tilt the uterus forward by pressing

on its posterior surface. As soon as a resistance is felt or the reposition causes pain, the operation should be discontinued.

Pessaries.—When the uterus is replaced, it is kept in the normal position by means of a pessary. The best is Emmet's modification of Hodge's (Fig. 235). It is made of hard rubber, and is introduced

Fig. 235.

Hodge-Emmet Pessary.

in the following way: The patient being in Sims's position, and the doctor standing behind her back, the pessary is seized by the lower, narrow end with the right thumb and index-finger, lubricated, and held in the sagittal plane in front of the vulva. With the left thumb and index-finger the labia are separated, and the pessary is pushed through the vaginal entrance pressing upward toward the promontory and backward against the perineum. When the broadest part has passed the vaginal entrance, the pessary is turned into the coronal plane. Next I seize the lower end with the left thumb and index-finger, and apply the right index-finger to the inside of the upper arch, and bring it by a combined movement with both hands behind the cervix, as high up as possible. Finally, I insert my right index-finger in front of the lower arch and push it back, the effect of which is to push the upper arch well forward against the posterior surface of the uterus. Beginners are apt to insert the pessary in front of the cervix, but by following the above directions they will soon succeed in placing it behind the same.

In a spacious vagina the pessary may be introduced while pulling the perineum back with Sims's speculum, a method which offers the advantage that the hand is guided by the eye.

Most pessaries on the market have too strong a curvature. This may be remedied by dipping them in oil and heating them in the flame of an alcohol lamp, when the hard rubber becomes soft and can be shaped at will. A well-fitting pessary extends from the depth of the posterior cul-de-sac to the vaginal entrance, and takes its support there. It follows the normal curvature of the vagina. The lower end is bent back a little, so as to avoid pressure on the urethra.

If there is much tenderness of the womb or a displaced ovary, the

pressure of the hard-rubber pessary sometimes becomes intolerable. In such cases one of a similar shape, but made of whalebone covered with soft rubber, may yet prove useful. Practitioners will find a great variety of pessaries in the stores and catalogues which we cannot enumerate in a work of this kind.

If the posterior cul-de-sac is too shallow to allow the Hodge pessary to penetrate far enough along the posterior uterine surface to keep the corpus bent forward, it is apt to bend backward over the pessary, which then does more harm than good. To obviate this a Thomas-Cutter pessary, with attachment to a band round the waist (Fig. 236),

FIG. 236.

Thomas-Cutter Retroflexion-Pessary.

FIG. 237.

Fowler's Pessary.

may be used, or, preferably, the vagina may be deepened by methodical packing (p. 173). In exceptional cases I have succeeded with Fowler's pessary (Fig. 237) when others failed.

Some use the intra-uterine stem with or without vaginal support (p. 428).

Postural Treatment.—Some help may be derived in the treatment of retroflexion by directing the patient to spend the night on her abdomen, or at least on the sides in a semi-prone position, and to avoid lying on her back. Besides, it is recommended to let her, on retiring, take the knee-chest position, and pull back the perineum with a finger, or, better, introduce a glass tube that will admit the air right up to the vault.[1]

In many women it is only necessary to use the Hodge pessary for some time, say from three to six months. Others need it all their lives.

General remarks about pessaries are found on p. 422. An elastic abdominal belt (p. 186) may be useful, especially in stout patients.

If these milder means do not succeed in curing or relieving the patient, recourse may be had to different operations—viz. perineorrhaphy, trachelorrhaphy, excision of cervix, extraperitoneal shortening of the round ligaments, forcible tearing of adhesions, massage, hysteropexy, and intraperitoneal shortening of ligaments.

1. *Perineorrhaphy.*—If the vaginal entrance is torn, and the pessary

[1] Henry F. Campbell, *Gyn. Trans.*, 1885, vol. x. p. 305.

does not find the necessary support, the perineum must be repaired (p. 299).

2. *Trachelorrhaphy* and *Wedge-shaped Excision of Cervix.*—If the cervix is torn, it should be brought together (p. 386), and even if it is not torn, but bulky and presenting a large canal, Gordon's operation (p. 405) should be performed. The involution caused in the body of the uterus by operations on the cervix (p. 389) is in many cases, together with postural and astringent treatment, sufficient to ensure the reposition of the displaced womb.[1]

3. *Extraperitoneal Shortening of the Round Ligaments* (*Alexander's Operation*).—This operation is only indicated in cases where there are no adhesions. Its object is to keep the fundus forward by removing a part of the round ligaments without opening the abdominal cavity. It is counterindicated in women who have passed the menopause, as this event entails fatty degeneration and atrophy of the ligaments.

Modus Operandi.—The patient lies stretched out at full length on her back. The operator stands on the side of the table opposite to the ligament to be operated on. The pubic hairs are shaved off. The operator feels for the spine of the pubis, and makes a little dent in the skin by pressing down the flesh over it. An incision is made parallel to Poupart's ligament from 1½ to 3 inches in length, according to the amount of subcutaneous adipose tissue, having the dent right in the middle and going down to the tendon of the obliquus externus abdominis muscle. The left index-finger is placed on the pubic spine and the pillars of the ring, and the intercolumnar fascia, with its transverse fibers, laid bare by scraping with the handle of the scalpel. The ring is situated immediately above and a little outside of the spine. Bleeding vessels are tied or compressed. From the ring emerges a bunch of adipose tissue that contains the ends of the round ligament, which spread out in fine filaments often hard to distinguish. This *whole mass* is seized with a pressure-forceps, and an aneurism-needle inserted under it *close to the bone.* Next we pull on the mass, and see the white genital branch of the genito-crural nerve, which lies just in front or to one side of the ligament. It is severed with knife or scissors, and so are some fine tendinous fibers running from the ligament to the wall of the canal. Sometimes the peritoneum is invaginated and accompanies the ligament, from which it must be stripped with the fingers and pushed back. When the ligament begins to peel out easily, this side is covered with an antiseptic compress.

The operator steps now over on the other side of the table, and repeats the operation on the other ligament.

When both ligaments are free, an assistant pushes the uterus for-

[1] Gordon and Engelmann, *International Medical Congress*, 1884, *Compte-rendu des travaux de la Section d'Obstétrique et de Gynécologie*, pp. 157–160.

ward with the sound or a repositor, and the ligaments are pulled out from 2 to 4 inches until we meet with a decided resistance.

Next, the ligaments are secured in their new position by passing two or three sutures of silk or chromicized catgut (p. 199) through the pillars and the ligament, whereby we should keep outside of the center of the ligament in order not to tie the artery running there (p. 60), which might lead to sloughing.

Finally, the redundant part of the ligament is cut off and the external wound closed with interrupted sutures. In very fat women, or if the tissues have been much bruised, a drainage-tube is left in the whole length of the wound. An antiseptic dressing is put on and left for a week. Then the outer sutures are removed. The patient is kept in bed for a month, and should wear a Hodge's pessary for six months or longer. If Alexander's operation is combined with perineorrhaphy, the pessary is introduced at the end of four weeks.

If the ligament cannot be found or breaks, it is necessary to split the anterior wall of the inguinal canal.

Nobody should undertake this operation without having tried it several times on the cadaver,[1] since even experienced surgeons have found it difficult or impossible to find the ligaments.

Alexander himself has made an important improvement in his operation, by which it becomes easy to find the ligament. Instead of searching for it at the external inguinal ring, a small incision is made in the intercolumnar fascia an inch below the internal ring; that is, about half an inch above the external ring. Only a slight puncture is made with the end of the scalpel. The wound is made to gape with a strabismus hook, and the ligament drawn out with another hook. The slit in the intercolumnar fascia is closed with two or three silk sutures. The edges of the superficial fascia are brought together with a continuous catgut suture, and the skin is closed in the same manner.

This method has the advantages that at the point indicated the ligament is easily found; that it is strong enough to be pulled out without tearing; that there is so little bruising that it is unnecessary to cut off the end of the ligament or use a drainage-tube; and that there is no danger of hernia, an event that is likely to follow when the inguinal canal is opened more extensively.

If there are signs of endometritis, it is a good plan to curette the uterus before performing Alexander's operation.

Several cases of childbirth after this operation are on record.

4. *Forcible Tearing of Adhesions* (*Schultze's Method*).—When the

[1] It is also advisable to study the papers, full of practical details, published by Polk in *N. Y. Med. Record*, July, 1886, p. 1; Mundé, in *Amer. Jour. Obstet.*, Nov., 1888, vol. xxi. p. 1121; and J. H. Kellogg, *Trans. Amer. Assoc. of Obstetricians and Gynecologists*, 1888, vol. i. p. 223.

uterus is bound down with adhesions Schultze dilates the cervical canal with aseptic laminaria (p. 152). He introduces the index- and middle fingers into the vagina, and the latter up to the fundus. Next he uses this finger to replace the uterus, while the other hand grasps it through the abdominal wall. When the uterus is replaced, it is kept *in situ* with a pessary. Most adhesions are easily separated, and the operator will, of course, use a good deal of judgment in deciding which resistance he will try to overcome, and when to desist, but on account of the uncertainty as to the conditions found in the pelvis, this method is fraught with dangers, which are still enhanced by substituting a thick sound for the finger.[1]

5. *Massage* (*Brandt's Method*).—Not less efficacious and much safer is Brandt's method, that obtains similar results by means of manipulations directed through the abdominal wall and the vagina (p. 187). By this method the adhesions are stretched gradually, and made to be absorbed by increase in vital processes.[2]

6. *Hysteropexy, or Womb-fastening.*[3]—There are different operations by which the uterus is stitched to other parts in order to make it adhere in a position that prevents it from falling back again. They may be divided into two classes, according to the point chosen for the adhesion—viz. *vaginal hysteropexy* and *abdominal hysteropexy*.

A. *Vaginal Hysteropexy* (*Schücking's Operation*).—The uterus is dilated by means of disinfected laminaria tents (p. 152), which softens its tissue. The patient is placed in the breech-back position (pp. 193 and 359). The uterus is pulled down with a volsella. A special covered needle (Fig. 238) is introduced through the os up to the fundus. An

FIG. 238.

Schücking's Needle, improved by Vorwinkel: *a*, long curved needle with eye near point; *b*, canula protecting needle; *c*, screw fastening needle; *d*, thumb-rest, moving in slot and pushing needle out and in; *e*, handle to be screwed on canula; *f*, plate with two holes through which the ends of the suture are passed before tying.

assistant pushes the bladder well over to the left side with a catheter, and holds the volsella while the operator presses the anterior fornix up

[1] Erich of Baltimore, *Amer. Jour. Obst.*, Oct., 1880, vol. xiii. p. 836; Van de Warker of Syracuse, *Gyn. Trans.*, 1881, vol. vi. p. 185.

[2] For details the reader is referred to Dr. Vineberg's paper, quoted on p. 188.

[3] *Hystera*, womb; *pegnymi*, I fasten. This name is more correct than *hysterorrhaphy*, which only means womb-sewing.

and pushes the needle through the uterine wall, the utero-vesical pouch, and the vaginal wall just behind the ramus of the right pubic bone. Now a silkworm-gut or waxed silk ligature is inserted into the notch near the end of the needle, and the instrument is pulled back into the cervical canal. Here the needle is pushed through the anterior lip of the vaginal portion, so as to emerge at the utero-vaginal junction. Finally, the needle is removed, the ligature tied, and a Hodge's pessary introduced to take off the strain. The ligature is left *in situ* for two weeks, but the patient may move about after ten days.

If the urine becomes bloody, the bladder should be washed out with a solution of thymol (1 : 1000) or boracic acid (1 : 100). If the uterus is adherent, the adhesions may first be torn by Schultze's method.

Schücking's method has been successfully performed many times by different operators. It has the great advantage of simplicity and expeditiousness, but the drawbacks are that the intestine might be caught by the needle while it traverses the peritoneal cavity, or the bladder seriously wounded, or the ureter compressed or wounded.

B. *Abdominal Hysteropexy*, or *Ventro-fixation of the Uterus.*—In this operation the uterus is attached to the abdominal wall. There are many varieties, the most important being the following—viz.:

a. Olshausen's Method.—One suture is carried through the round ligament near the edge of the uterus and the anterior layer of the broad ligament behind, and the parietal peritoneum and part of the the rectus abdominis muscle in front, three-quarters of an inch from the middle line. Two more sutures are inserted below the first, only through the anterior layer of the broad ligament and the abdominal wall as just stated. All six sutures are inserted before any of them is tied. The uterus should be lifted sufficiently to leave only a narrow slit between it and the bladder. Before tying, the operator makes sure that neither the intestine nor the omentum is in the way.

b. Kelly's Method.[1]—The ovarian ligaments are stitched with three sutures on either side to the abdominal wall. Thus the uterus is fastened in an anteflexed or anteverted position. Adhesions form at once, but stretch, so that within two weeks the corpus uteri sinks to the level of the anterior vaginal wall, where it stays.

c. Leopold's Method.—Leopold fastens the uterus itself to the abdominal wall. A suture is carried through the whole abdominal wall and transversely under the peritoneum and the most superficial part of the muscular tissue on the anterior surface of the uterus, between the two starting-points of the round ligaments, on a line half an inch long, and then out through the abdominal wall on the

[1] Howard Kelly, *Johns Hopkins Hospital Bulletin*, vol. i. No. 2, January, 1890.

other side. Two more such sutures are placed above the first and parallel to it.

In order to insure adhesion the perimetrium is scraped with the back of a bistoury in the space comprised between these sutures.

Other sutures are carried through the abdominal wall alone, below and above those going through the uterus, and finally all are tied. Those going through the uterus are left in place from twelve to fifteen days.

d. Czerny's Method is like Leopold's, with this difference that he uses only two uterine sutures of catgut treated with corrosive sublimate, and carries them only through the peritoneum, muscle, and fascia, but not through the integument.

e. Pozzi's Method.—Beginning at the lower end of the incision, a continuous suture of fine silk is brought through the abdominal wall, except the skin and sucutaneous adipose tissue (as in Czerny's method), and through the perimetrium, which is comprised three times in the suture. The remainder of the abdominal wall is closed with a continuous tier-suture of catgut, in two layers (p. 213).

f. Kaltenbach's Method.—The abdominal wall is only incised to, but not through, the peritoneum. The uterus is stitched to the peritoneum (probably with silk) and subsequently with silver wire to the periosteum of the symphysis pubis,[1] the wire sutures being left in "for a long time."

Lee[2] warns against those methods in which the needle is carried through the fundus uteri, because it is often excessively vascular and bleeds profusely.

The transperitoneal method offers the advantage of not opening the peritoneal cavity, but is inferior to the other methods in exposing the intestine and omentum to the risk of injury, and precluding a thorough and safe severance of adhesions and an examination of the uterine appendages, which might lead to their removal.

Severance of Adhesions.—In all cases in which the abdominal cavity is opened, adhesions that hold the uterus in its faulty position should be severed, beginning at the distal end of the broad ligaments As a rule, this can be done with the finger alone, but sometimes the adhesions are so tough that they have to be tied with a double ligature and cut with scissors. If there is much bleeding from torn adhesions, it may become necessary to use a provisional intra-abdominal tampon of iodoform gauze (p. 176).

Examination of Appendages.—When the abdomen is opened, the appendages should be brought into view, and, if seriously affected, removed. In the latter case either the stumps or the fundus uteri may be fastened to the abdominal wall.

[1] Kaltenbach, *Centralbl. für Gynäk.*, 1889, vol. xiii. p. 731.
[2] C. C. Lee, *Amer. Jour. Obst.*, Dec., 1888, vol. xxi. p. 1256.

Pessary.—In all cases of abdominal hysteropexy a Hodge's pessary should be introduced and worn for several months.

The bladder soon accommodates itself to its new relations with the uterus. Pregnancy and childbirth at term have been observed after hysteropexy, but in some cases abortion has occurred. Strangulation of the intestine or the omentum in the slits might take place, but this danger does not seem to be great. It is, however, serious enough to be a point in favor of other operations by which the uterus is not fastened to the abdominal wall.

7. *Intraperitoneal Shortening of Ligaments—a. Wylie's Method.*[1]—The round ligaments are pulled up into the abdominal wound, scraped on their inner surface so as to make them raw, folded upon themselves, and the loop tied with three silk sutures, so as to hold the uterus over the bladder near the pubic bone. Then the abdominal wound is closed.

b. Polk's Method.[2]—The round ligaments are caught up about three-quarters of an inch from the cornua, are approximated in front of the uterus, and are tied together by one suture. Should further shortening be needed, one or two more sutures may be passed in front of the first at a distance of a quarter or half an inch each.

c. Tait's Method produces a shortening of the round ligaments by passing the ligature for removal of the appendages (see Diseases of the Tubes) under the ligament, so as to comprise a loop of it in the part that is cut away.

Others have attacked the sacro-uterine ligaments and the infundibulo-pelvic ligament.

In regard to the *laparotomy* forming part of most of the above-mentioned methods the reader is referred to the description of Ovariotomy.

E. *Lateroversion and Lateroflexion.*

Lateral deviations of the uterus, unaccompanied by other pathological conditions, are rare. They may be congenital (p. 381) or due to inflammation later in life. The displacement is often produced by inflammatory exudations in the pelvis or tumors in the broad ligaments. The diagnosis is made by bimanual palpation or the sound. These displacements are apt to cause sterility. No direct treatment is applicable.

F. *Prolapse.*

Prolapse, Prolapsus, Descent, Procidentia, popularly called *Falling of the Womb,* is that displacement of the uterus in which it sinks down to a lower position than normal. Some authors reserve the term "prolapse" for the lesser degrees of descent, in which the uterus

[1] Gill Wylie, *Amer. Jour. Obst.*, May, 1889, vol. xxii. p. 484.
[2] W. M. Polk, *Gyn. Trans.*, 1889, vol. xiv. p. 262.

is inside of the vagina, and designate by "procidentia" only the highest degree, in which the uterus sinks more or less completely out of the body and hangs between the thighs. Others call the first degree *incomplete*, and the second *complete* prolapse.

Prolapse is sometimes *acute;* that is to say, it may occur suddenly in an otherwise healthy person, even a virgin, while making a muscular effort, but this is rare. It has also been observed in a child, in consequence of diarrhea, a few days after birth. Commonly it is *chronic;* that is to say, it is developed slowly and gradually. In the latter case it is combined with more or less hypertrophy and metritis.

Pathological Anatomy.—The vagina becomes inverted, as in supravaginal hypertrophy (p. 413), but in prolapse the peritoneal pouches in front and behind the uterus are dragged down with it (Fig. 239).

FIG. 239.

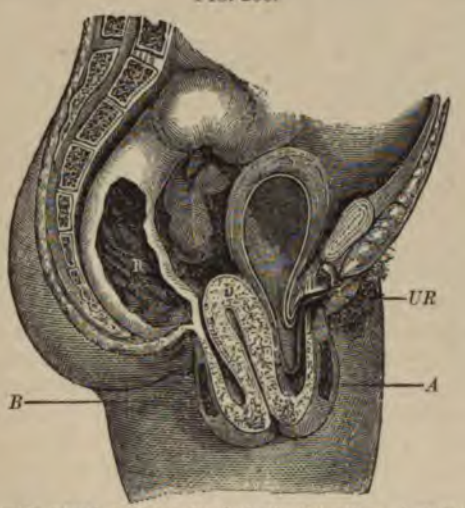

Procidentia Uteri, with pared surfaces for Lefort's operation: *A*, anterior denudation; *B*, posterior denudation; *U*, fundus uteri; *UR*, meatus urinarius; *R*, rectum.

Etiology.—As just stated, the acute prolapse is due to a muscular effort in carrying a heavy weight, such as a tub with water, in front of the body. The chronic is mostly referable to childbirth. The vaginal entrance being ruptured (pp. 294 and 297), the uterus does not find its usual support from below. It becomes retroverted and then retroflexed (p. 429). Intra-abdominal pressure drives it like a wedge down through the vagina. The sacro-uterine ligaments (p. 55) become weakened and elongated, the pelvic connective tissue loses its tonus, and the weight of the subinvoluted vagina drags

the uterus down (p. 327). Finally, the uterus sinks by its own weight. Thus lack of support from above and below combines with weight, pressure, and dragging to displace the uterus.

The descent may also be due to tumors in the uterus, which increase its weight, or in the abdomen, which press on it. The increase in weight and succulence of all pelvic structures caused by pregnancy may also result in prolapse.

Symptoms.—The symptoms of chronic prolapse are identical with those of hypertrophy of the cervix (p. 413). The acute form is accompanied by sudden severe pain, faintness, and peritonitis.

Diagnosis.—A *polypus* and an *inverted uterus* form tumors without the opening at the lower end leading into the interior of the tumor. Prolapse differs from *supravaginal hypertrophy* by the low position of the uterine body and the normal or only slightly increased depth of the cavity.

The lesser degrees of prolapse become more apparent in the erect posture (p. 136).

Treatment.—As a rule, common *pessaries* cannot be retained, on account of lack of support from the perineum. A large soft-rubber ring, an inch thick (Mayer's pessary), will sometimes retain the uterus in the pelvis by distending the upper part of the vagina. Breisky recommends large ovoid bodies of hard rubber. Gariel's air-pessary consists of a soft-rubber bag, which the patient can introduce herself into the vagina and fill with air. In most cases of complete prolapse it is necessary to use *supporters* composed of a cup and stem pressing against the vaginal portion and fastened to an abdominal belt (Fig. 240). This apparatus is removed during the night, and the cup cleansed with some disinfectant.

Brandt's method of combined massage and gymnastic movements (p. 188) claims great triumphs in the cure of prolapsus.[1]

Operations.—As a rule, combined operations are required, and even they may not always prevent a return of the evil.[2]

Emmet's or other operations are used for reducing the bulk of the uterus (p. 405); Alexander's operation (p. 435) is combined with perineorrhaphy (p. 299); vaginal or abdominal hysteropexy (pp. 437–439) is also used to hold the uterus up, in order to fasten the uterus above and support it from below.

Lefort's Operation.—For complete prolapsus Lefort's operation of *partitioning the vagina* is valuable by providing a solid column of tissue right in the middle of the vagina for the uterus to rest on.

[1] The details of the complicated manipulations may be found in Boldt's paper in *Amer. Jour. Obst.*, 1889, vol. xxii. p. 590.

[2] I combined in one case removal of the appendages, ventrofixation of the uterus, Tait's perineal flap operation, and Stolz's cystocele operation. For a time the success was complete, but a year had not elapsed before the uterus was prolapsed again.

shape of an acute angle, the top of which is situated in the median line and points backward toward the posterior commissure. This incision opens Douglas's pouch. The next step is to stitch the peritoneum to the posterior vaginal wall. The fundus uteri is easily

FIG. 242.

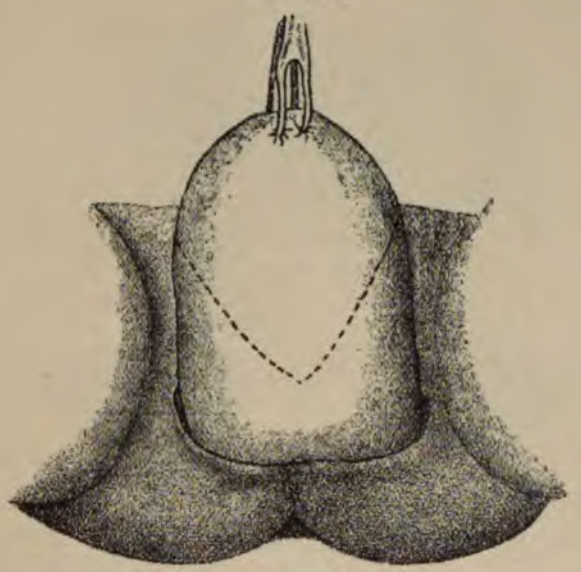

Fritsch's Hysterectomy for Prolapsed Uterus.

pulled out, and a sponge with attached thread placed so as to retain the intestines. Now the broad ligaments are gradually tied in sections, proceeding from their upper end to their base, with a half-sharp aneurism-needle bent to the side (Fig. 258) and threaded with stout silk. If possible the tubes and ovaries are comprised in the parts to be removed. As soon as a section is tied, it is cut between the ligature and the uterus. Next, the vaginal portion is carried far down, and an incision similar to that on the posterior wall is made on the anterior wall of the vagina (Fig. 243), but only through the vaginal wall, without entering the bladder. This triangle is separated from the bladder, partly with blunt instruments and partly with the knife, and the edges of the wound united by means of transverse sutures. By pulling the fundus uteri again forward and upward, the line where the peritoneum passes from the bladder to the anterior surface of the uterus is brought into view and incised; and then the posterior wall of the bladder is dissected from the uterus from above and from below.

has resorted to the high amputation of the cervix by making a circular incision around the margin of the external os, pushing up the vaginal walls with finger and scalpel-handle, and removing the blad-

Fig. 241.

Lefort's Prolapsus Operation: *A*, anterior denudation; *B*, posterior denudation; *C C'*, upper right lateral sutures; *D D'*, upper left lateral suture.

der and the peritoneum of Douglas's pouch from the seat of operation. Having thus exposed an inch to an inch and a half of the raw cervix, he amputated it with the galvano-caustic wire. Passing a tent of iodoform gauze into the cervix to prevent the closure of that canal, he returned the uterus into the pelvic cavity and packed the vagina with iodoform gauze. The cicatricial contraction of the vaginal vault resulted in forming so firm an attachment that the uterus was retained in its normal position.

Vaginal Hysterectomy.—In those very rare cases of prolapse that have resisted all other methods, the extirpation of the prolapsed uterus is justifiable. In performing it a considerable part of the vagina must also be removed. The modus operandi by Fritsch's method[1] is the following: The patient is in the breech-back position (p. 359). The base of the tumor is constricted with a rubber tube in order to prevent hemorrhage. The vaginal portion is seized with a volsella, and pulled well upward (Fig. 242). Now an incision is made on the posterior vaginal wall, between the middle and upper third, in the

[1] Asch, *Archiv für Gynäkologie*, 1889, vol. xxxv. p. 206.

shape of an acute angle, the top of which is situated in the median line and points backward toward the posterior commissure. This incision opens Douglas's pouch. The next step is to stitch the peritoneum to the posterior vaginal wall. The fundus uteri is easily

FIG. 242.

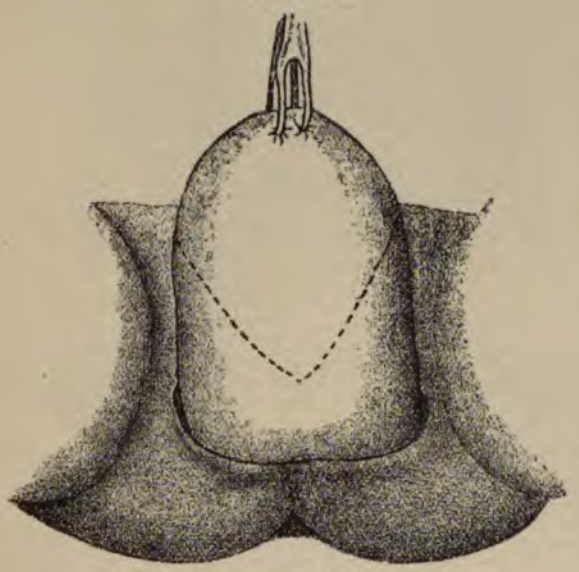

Fritsch's Hysterectomy for Prolapsed Uterus.

pulled out, and a sponge with attached thread placed so as to retain the intestines. Now the broad ligaments are gradually tied in sections, proceeding from their upper end to their base, with a half-sharp aneurism-needle bent to the side (Fig. 258) and threaded with stout silk. If possible the tubes and ovaries are comprised in the parts to be removed. As soon as a section is tied, it is cut between the ligature and the uterus. Next, the vaginal portion is carried far down, and an incision similar to that on the posterior wall is made on the anterior wall of the vagina (Fig. 243), but only through the vaginal wall, without entering the bladder. This triangle is separated from the bladder, partly with blunt instruments and partly with the knife, and the edges of the wound united by means of transverse sutures. By pulling the fundus uteri again forward and upward, the line where the peritoneum passes from the bladder to the anterior surface of the uterus is brought into view and incised; and then the posterior wall of the bladder is dissected from the uterus from above and from below.

Spurting vessels are caught and later tied. Finally, the peritoneum of the bladder is stitched to the rest of the anterior vaginal wall, or rather the lateral walls, which have been stitched together in the

FIG. 243.

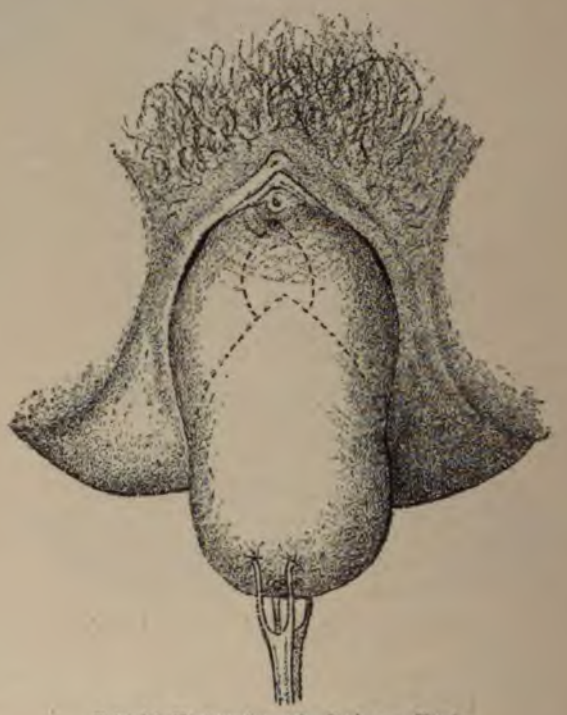

Fritsch's Hysterectomy for Prolapsus Uteri.

median line, and the stumps of the broad ligaments are also fastened to the vagina.

G. *Elevation.*

The uterus may be raised by tumors in the pelvis, or ascend by its own size, as in pregnancy, or be pulled up by contracting inflammatory adhesions. Sometimes the whole vaginal portion disappears.

H. *Inversion.*

Inversion consists in a turning inside out of the uterus (Fig. 244). It may be *total* or *partial.* As a rule, the inversion begins as an indentation at the fundus, but it may also begin in the cervix, subsequently dragging down the body. We distinguish three degrees. In

the first degree the inverted part is found inside of the uterus; in the second, it has descended into the vagina; and in the third it is combined with prolapse and hangs outside of the vulva.

Inversion comes under observation at three different periods:

FIG. 244.

Section of the Second Degree of Inversion of Uterus (Crosse): *a*, vagina; *b*, fundus uteri; *c,c*, angles of inflection; *c,c, d,d*, extent of uninverted cervix; *e*, vaginal wall; *f*, the peritoneal cul-de-sac of the inverted uterus; *g,g*, Fallopian tubes passing down into the inverted uterus; *h,h*, ovaries; *i,i*, broad ligaments; *k,k*, round ligaments.

immediately after the occurrence of the accident, especially during or immediately after childbirth, in regard to which the reader is referred to works on obstetrics; about six weeks after labor, when hemorrhage or other symptoms induce the patient to seek advice; and, finally, a long time, often many years, after its formation.

Etiology.—Inversion is a very rare accident, only one case having occurred in about 150,000 cases of delivery. The most common cause is childbirth, especially if it takes place in the erect posture, if the cord is too short, if the accoucheur or the midwife pulls on it in order to remove the placenta, and if it is inserted on the fundus. But the inversion may also take place some time after the birth of the child, especially at the time of getting up, although the lying-in period has been normal in every respect. Laceration of the cervix may predispose to it. After abortion it is still rarer than after childbirth. It has also been observed in connection with a vesicular mole.

Secondly, a tumor of the fundus uteri, especially a fibroid, being expelled, drags the uterus along.

Thirdly, inversion may occur when the uterus is enlarged and its tissue softened, independently of pregnancy and the presence of a tumor.

Where there is no tumor, the mechanism is the following: A part of the uterine wall, most frequently the placental site, becomes paralyzed and sinks down, while the surrounding parts contract above it.

Thus a kind of peristaltic movement is set up, proceeding from above downward. But if the inversion begins at the cervix, the movement takes place in the opposite direction, from below upward.

Pathological Anatomy.—The inverted part of the uterus may only be a cup-shaped depression near the fundus, or it may form a pear-shaped body, the lower end of which does not pass the internal os, or it may hang in the vagina, the pedicle being surrounded by a ring formed by the cervix; or the whole cervix and part of the vagina may have become inverted in their turn. If the tumor is yet retained in the body of the uterus, it is covered with a dark-red, swollen mucous membrane that easily bleeds. On the lower end may be seen two minute openings, admitting a bristle, which are the uterine apertures of the Fallopian tubes.

When the inverted part lies in the vagina, its mucous membrane sometimes loses its glands and becomes like that of the vagina. If it is expelled outside of the patient's body, it often ulcerates and cicatrizes, which gives it a cutaneous appearance.

Seen from the peritoneal cavity, the inverted uterus forms a funnel-shaped depression, into which descend the Fallopian tubes, the round ligaments, and sometimes the ovaries. In old cases this funnel may be impervious, the contiguous sides of the peritoneum having grown together.

Symptoms.—In most cases the inversion of the uterus, taking place suddenly in connection with childbirth, is accompanied by marked symptoms—hemorrhage, pain, collapse, and the formation of the characteristic tumor in the vagina and the funnel above the symphysis. But in exceptional cases all alarming symptoms may be absent.[1]

In the subacute and chronic forms the chief symptom is again hemorrhage, which may undermine the constitution by its frequent recurrence or profuseness, to which are added leucorrhea, dragging pain, difficulty in walking, and different nervous reflexes. Physical examination reveals the peculiar shape of the fundus and the presence of a tumor in the vagina.

Diagnosis.—The diagnosis of inversion, apart from obstetric cases, may be very difficult, and is of the utmost importance in regard to treatment. Only great carelessness could fail to distinguish common *prolapse* and *hypertrophy of the cervix* from inversion, the distinctive feature being the presence of the os uteri at the lower end, through which the sound can be brought in more or less deeply. The tumor in prolapse is broader at the upper end than at the lower, whereas the opposite is the case with an inverted uterus. A catheter goes downward into the cystocele accompanying prolapse, but upward in case of inverted uterus. A *polypus* may offer entirely similar symp-

[1] John C. Reeve has contributed a paper full of instruction on Inversion in *Gyn. Trans.*, 1884, vol. ix. p. 69.

toms, and a tumor of the same shape and appearance may be found in the same place; but if it is a polypus the sound can be introduced to the depth of a normal uterus or deeper between the tumor and the cervix, while in inversion it is soon arrested at the place where the uterus is inflected. Bimanual examination shows, when we have to do with a polypus, that the uterus is in its place. If, especially in stout women, the uterus cannot be felt through the abdominal wall, recourse may be had to rectal examination (p. 139). A catheter held in the bladder may help to settle the diagnosis, and if there is any doubt the urethra should be dilated (p. 140), and the index-finger introduced into the bladder, from which it can palpate the uterus. If it is a case of inversion, these same manipulations will show that the uterine body is not in its place, and that instead there is a funnel-shaped depression. It is also claimed that if a needle is thrust into the tumor, it will cause pain in an inverted uterus, but not in a polypus.

If we have a fibroid as cause of the inversion, and it is yet in the uterus, the differential diagnosis may be particularly difficult. Under such circumstances the sound enters to its usual depth, but the depression of the fundus can be made out by the above-named means.

If the fibroid has dragged the uterus down with it, the sound does not enter, but it becomes necessary to distinguish which part of the tumor is the uterus proper and which the fibroid. In this respect the fact that the fibroid is harder, nodulated, and painless on acupuncture is an aid to diagnosis.

If *adhesion* takes place between the pedicle of a polypus and the cervix, the sound cannot enter, but then the uterus is found in its normal place and of normal shape.

A similar condition obtains when it is a so-called *hollow polypus*,[1] an exceedingly rare disease, the pathology of which is not quite settled. There is found a tumor in the vagina as in common polypus and inversion, but the sound cannot be made to enter anywhere between the pedicle and the cervix without violence. This tumor is soft and contains fluid, which distinguishes it from a fibroid polypus adherent to the cervix. One theory is that a plastic deposit is produced on the endometrium, and that blood or other fluid accumulates between it and the uterine wall, lifts it up, and forms the polypoid tumor that is expelled through the os. Another theory is that it is the endometrium itself that becomes detached and peeled off down to the cervix. A third possibility—and, in my opinion, more likely than either of the others—would be that a common fibroid polypus contracts adhesions with the cervix; that its interior becomes myxomatous and melts, forming a cyst in the way we shall see in studying the formation of fibro-cysts, which cyst later communicates with the uterine cavity by absorption of the partition. However this may be, the fact is that

[1] Sussdorff, *Jour. Obst.*, 1877, vol. x. p. 553.

we have a sac filled with fluid protruding through and attached to the cervix. The sound does not enter, but the tumor is softer than an inverted uterus. By pulling on it, the relations between it and the cervix remain unchanged, whereas in inversion the cervix becomes more inverted or disappears altogether. Examination through the rectum practised while this traction is made will show that the uterus is in its place and has its normal shape. If the sound is made forcibly to penetrate the obstacle round the pedicle, it enters a cavity of the normal depth of the uterus.

Prognosis.—Inversion of the uterus is a very dangerous condition, accompanied by great mortality. The total mortality is 20 per cent., but it is far less in chronic cases than in obstetric practice. Spontaneous replacement is possible, but rare. Another spontaneous cure, accompanied by the dangers of septicemia, is occasionally brought about by gangrene of the inverted mass. Most of the measures adopted for the cure of inversion are more or less dangerous.

Treatment.—The measures to be taken for the inversion occurring during labor are taught in works on obstetrics. Here we treat only of more or less old cases. Experience has shown that the best treatment is that with *elastic pressure.* The vagina is disinfected and *Aveling's repositor* applied. It is made of hard rubber, and consists of a little cup which presses on the inverted fundus, and an S-shaped rod, which protrudes from the vulva and carries pressure made at its lower end upward in the direction of the pelvic axis. To the lower end are attached four elastic tapes, which are drawn through rings fastened to a belly-binder. Two of the tapes are brought forward and two backward, and they enable us to give the rod the desired direction. A pressure of two and a half pounds is sufficient. This method is safe, hardly ever fails, and leads to replacement in a short time—from nine to fifty-four hours—by starting an antiperistaltic movement, so that the part forming the pedicle is first replaced, and the fundus last.

The same principle of elastic pressure may be applied in different ways. A soft-rubber cup is attached to a curved hard-rubber stem, from the end of which tapes go to rings in a belt round the abdomen (Barnes). The uterus is surrounded with cotton pledgets soaked in glycerin; then a soft-rubber bag is introduced into the vagina, upon which pressure is obtained by passing a strap of adhesive plaster from the lumbar region over the genitals to the umbilicus (Thomas). The common German way is to use the colpeurynter, a large rubber bag distended with air or water; by its great side pressure it causes considerable pain, and can hardly be borne for more than five or six hours a day, wherefore the treatment may take a month or more. Between the applications, the vagina is treated with warm disinfectant injections. Another way that dispenses with the use of any particular

instrument, is to pack the vagina firmly with iodoform gauze, which is renewed every two or three days.

During all these treatments the patient is kept in bed, and if necessary the pain relieved by hypodermic injections of morphine.

If the elastic pressure does not succeed, recourse is had to one of the following methods of *manual replacement*, which are used on the anesthetized patient.

Emmet surrounded the tumor with the fingers of the left hand and pressed at the base, making counter-pressure through the abdominal wall on the ring in the peritoneum.

Noeggerath applied the thumb and middle finger to the horns of the uterus, replaced first one of them, then the other, and finally the fundus; counter-pressure was made as in Emmet's method.

Courty introduced two fingers of the left hand into the rectum, which allows pressure on the cervical ring with greater effect, while the fingers of the right hand press at the base of the tumor in the vagina.

Tate of Cincinnati dilated the urethra, introduced the right index-finger into the bladder, and pressed on the ring from this side, at the same time using the left index- and middle finger in the rectum, as Courty did, and applying both thumbs to the horns as in Noeggerath's method.

Instruments for replacing the inverted uterus have been devised by White of Buffalo and Byrne of Brooklyn.

If a partial reinversion is obtained in any way, Emmet's device, of pulling the lips of the cervix together over the still inverted fundus, and uniting them with deep *silver-wire sutures*, may be followed. Thus an elastic pressure is obtained that may lead to complete replacement.

The efforts to reduce the inversion must be continued as long as possible, say for half an hour, different operators relieving one another. If one method does not succeed, and her condition warrants delay, the patient should be given a few days rest, and another method tried. In the mean time, the tumor may be softened with warm vaginal injections and sitz-baths.

Conservative Cutting Operations. Thomas performed laparatomy and dilated the cervical ring with an instrument like a glove-stretcher. This method would probably be the best in old cases in which adhesions have formed between the walls of the internal ring.

Barnes pulled the tumor well down with a tape, and made three longitudinal incisions in the cervix. After that he could easily replace the tumor by manipulation.

Amputation.—When all conservative measures fail, the tumor must be removed. The chief danger of this method is the possibility of the presence of the intestine in the inverted part. An *elastic ligature* may be applied round the base, and tightened every day. The stran-

gled tumor falls off in twelve to eighteen days. Before applying the ligature a bed is made for it by burning a groove with the thermo-cautery (p. 177).

Some prefer to remove the mass by means of the *galvano-caustic wire*, or *Paquelin's thermo-cautery* which does away with the dangers of septic infection from the putrefying tumor; and if reinversion of the stump should take place, the cut surface forms a hollow cone from which discharge can escape into the vagina.

The tumor may also be cut away with *knife and scissors*, but then silver sutures should be drawn through the base before the ablation, so as to be able to close the peritoneal cavity. On each side one suture should be brought out transversely, so as to encircle the lateral blood-vessels, while three middle sutures bring the cut surfaces together.

Destruction of the Mucous Membrane.—In irreducible cases in women near the climacteric, the dangers of amputation may sometimes be avoided by destroying the mucous membrane and producing cicatrization by means of potassa cum calce or the thermo-cautery.

If inversion is produced by a *fibroid*, this must be removed before an attempt is made to reduce the inversion. It is sometimes difficult to find the line of demarkation. The safest is to make an incision over the end of the tumor and enucleate it with Thomas's serrated scoop (Fig. 248), which will be described in treating of fibroids. When once the tumor is removed, perhaps parts of the tissue in which it was imbedded have to be cut away. Next, the uterus is to be reinverted and packed with iodoform gauze.

If the tumor is *malignant*, the inverted part should be amputated or the whole uterus extirpated by vaginal hysterectomy, as detailed under Cancer of the Uterus.

If we have to deal with a *hollow polypus*, it should be pulled down, which is best done by surrounding it with a noose. If there is any difficulty in applying it, a sling-carrier in the shape of a uterine sound with a small crescent at the end will easily bring it up. A small incision is made in the pedicle, through which the sound is passed, and only enters to a depth corresponding to the size of the uterus. The diagnosis thus having been completed, the protruding tissue is removed by ligature, thermo-cautery, or galvano-caustic wire.

I. *Hernia Uteri.*

Hernia uteri, or *hysterocele*, is that displacement of the uterus in which it is found lying outside of the pelvis in a sac formed by the peritoneum. The uterus has been found in an *inguinal* and in a *crural* hernia. Such cases are extremely rare. They are nearly always congenital malformations. (See p. 381.)

CHAPTER XIII.

NEOPLASMS.

A. *Cysts of the Cervix; Adenoma Uteri; Mucous Polypi; Myxoma.*

In regard to cysts of the cervix and ovula of Naboth we refer to what has been said above under Lacerated Cervix (pp. 383 and 386) and Chronic Endometritis (pp. 394 and 400–401). These cysts, being formed by occluded glands, are a kind of *adenoma.*

In speaking of hyperplastic endometritis (p. 395) we have mentioned another kind of adenomas, small benign tumors formed by a conglomeration of hyperplastic uterine glands. They may be sessile and do hardly ever become larger than a walnut, but have a tendency to become pedunculated and form so-called *glandular polypi.* Such polypi start very frequently from the mucous membrane of the cervix, and hang out from the os, where sometimes they may acquire so considerable a size as to fill the vagina; but that is rare. Most of them come under treatment when they are not larger than a cherry, a pigeon's egg, or a small oyster. They are soft, covered with a dark red mucous membrane. They are full of cavities, the contents of which are thin or thick, clear or dark.

Sometimes the polypi are formed of *myxomatous* tissue consisting of a delicate fibrous network, with slight thickening at the points of intersection, and a hyaline or finely granular mucoid basis substance in the meshes, in which we find imbedded single or multiple granular corpuscles. Glandular formations are rare or absent.[1]

The name "adenoma" is also taken in a narrower sense, and used to designate a tumor formed by so exuberant a growth of utricular glands that the epithelial formations are connected with each other and form an almost continuous plexus. Many of these tracts seem to be solid or have a narrow caliber only. The connective tissue between the epithelial tracts is extremely scanty and fibrous, only a small number of medullary corpuscles being present.

Unfortunately, some authors speak of a *malignant adenoma,* which only is the first stage of carcinoma.

Symptoms.—These mucous polypi cause hemorrhage, leucorrhea, and sometimes pelvic pain, backache, or dyspareunia. When situated above the internal os, they may work like a ball-valve and cause great dysmenorrhea.

The *treatment* must begin with removal of the growths. In the interior of the uterus this is done with the curette (p. 171). From the cervix they may be torn off by seizing them with a forceps and

[1] Louis Heitzmann, "The Differential Diagnosis between Fungous Endometritis and Tumors of the Mucosa of the Uterus," *Amer. Jour. Obst.*, Sept., 1887, vol. xx. p. 897.

turning the instrument until the pedicle is severed (*torsion*). Or they may be cut off with scissors, but then it is well to have a thermo-cautery in readiness, as there may be some hemorrhage. They may also be removed with the galvano-caustic wire or a simple cold wire écraseur.[1]

After removal of the growth the accompanying chronic endometritis should be treated as described above (pp. 399–401).

B. *Uterine Fibroids; Fibroid Polypi; Fibro-cysts of the Uterus.*

Fibroid tumors, or *fibroids of the uterus*, *fibromata*, are more exactly called *myomata*—*i. e.* muscular tumors—or *myofibromata*, or *fibromyomata*—names denoting a mixture of muscular and fibrous connective tissue in their composition.

Pathological Anatomy.—Fibroids are so common that they are found in the body of one out of every five women over thirty-five years of age. They are globular tumors composed of several nodules, and may attain enormous dimensions, weighing up to 140 pounds. They are mostly harder than normal uterine tissue, but may be so soft that they impart a sensation which cannot be distinguished from fluctuation. On the cut surface they appear white or pinkish, show an irregular concentric arrangement of the fibers around different centres, and bulge out beyond the surrounding parts. In most cases the tumor is separated from the uterine tissue by a layer of loose connective tissue, the so-called *capsule*, so that it is easily shelled out, but often this capsule is incomplete, and the tumor is a direct continuation of the surrounding muscular wall. As a rule, the substance is compact and contains less fluid than the surrounding tissue, but sometimes it is full of dilated arteries, veins, or lymph-spaces (*cavernous myoma*, *myoma teleangiectodes* and *lymphangiectodes*). Nerves can be followed into the interior. The uterus grows with the tumor, so that its cavity becomes larger; as a rule, the muscular tissue becomes hyperplastic, and numerous blood-vessels are developed in it. But in exceptional cases, on the contrary, the normal muscular tissue nearly disappears, and the uterus forms only a bag filled with calcified tumors.

Fibroids may be developed in the body or in the neck of the womb, but the *cervical* are much rarer than the *corporeal*. In non-pregnant women only 5 per cent. are situated in the cervix; in pregnant women 20 per cent. have this situation, the relative frequency in the state of gravidity being due to the fact that cervical fibroids are likely to cause serious complications of pregnancy and childbirth, which bring the patients under medical observation.

[1] *Fibrinous polypi* are pedunculated growths formed by layers of fibrin deposited over a remnant of the after-birth left in the interior of the womb after childbirth or abortion. The symptoms and treatment are like those of intra-uterine glandular polypi.

They are either *sessile* or *pedunculated*, and the latter may again either hang from the cervix and develop into the vagina, or spring from the interior of the corpus or fundus; or they may spring from the outer surface of the corpus and fundus and develop into the peri-

FIG. 245.

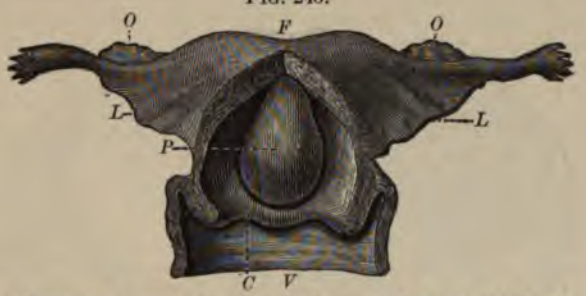

Pedunculated Submucous Fibrous Tumor (fibroid polypus) enclosed in Uterus (Cruveilhier): *F*, fundus of uterus: *O,O*, ovaries; *L,L*, round ligaments: *C*, cervix; *V*, vagina; *P*, polypus.

toneal cavity. Those which spring from the cervix and the uterus proper and are covered with mucous membrane are called *fibroid polypi* (compare glandular and fibrinous polypi, pp. 395 and 453–454,) the

FIG. 246.

Pedunculated Subperitoneal Fibroid (Hofmeyer).

word "polypus" being used as a general term for any pedunculated tumor attached to the mucous membrane of the uterus.

Fibroids are called *submucous* (Fig. 245) when a part of them is only covered with mucous membrane; *subperitoneal* (Fig. 246), if they are partly situated immediately under the peritoneum; and

interstitial or *intramural* (Fig. 247) if they are surrounded by a layer of muscular tissue. This latter variety has a tendency to work its way outward or inward, so as to pass into one of the two other varieties, and may even become pediculate.

Sometimes there is only a *single* tumor, but quite frequently fibroids are *multiple*. In the latter case the uterus with its tumors may form

Fig. 247.

Intramural Fibroid (Gusserow).

a mass of fantastic shape, often reminding one of certain forms of cactus.

If the fibroid is developed in the infravaginal part of the cervix, it may form a polypus attached to one of the lips, but from the upper part it may develop upward into the wall of the body or into its cavity or into the connective tissue of the parametrium, the broad ligaments, and the pelvis in general, separating the layers of the mesorectum.

Microscopical examination shows that fibroids originate from round cells surrounding capillaries which are undergoing obliteration. The well-developed tumor consists of unstriped muscle-fibers, mixed with more or less fibrous connective tissue and fusiform cells.

Fibroids are not so apt to be bound to the peritoneum of the abdominal wall or other organs as ovarian cysts, but if they do form such adhesions, these are often broad and contain very large blood-

vessels; so much so that the tumor to a great extent derives its nourishment from the adhesions; nay, in course of time may it be severed altogether from the uterus, and be found attached exclusively to another part of the abdomen. Such pediculate tumors may even be torn off from the uterus and lie loose in the abdomen as necrobiotic masses, without forming new adhesions. Fibroids are very frequently accompanied by local peritonitis, and may also cause cellulitis. They are often the cause of ascites, usually serous, sometimes chylous, and rarely bloody.

Fibroids are apt to undergo *changes* in their constituent elements. Some of them soften and swell at each menstruation, and if they are pedunculated the tumor at that time may be driven out through the cervical canal and appear in the vagina. After the menstrual period the swelling subsides, and the tumor recedes again into the interior of the womb, forming what is called an *intermittent polypus.*

A similar softening and swelling take place on a larger scale during pregnancy, but, on the other hand, the tumor partakes of the general involution after the birth of the child, and may disappear entirely.

After the menopause fibroids, as a rule, become smaller and harder, but they may continue growing. Even apart from menstruation and pregnancy fibroids are apt to become *edematous.* Sometimes *myxomatous* tissue is found in their interior.

Cysts may be developed either by simple accumulation of serum in the meshes of the tumor, or by resorption of myxoid tissue, or by dilatation of lymph-spaces. The latter kind has an endothelial lining.[1] Often these cysts first appear spread as small hollows, so-called *geodes,* throughout a fibroid, but subsequently the intervening tissue is absorbed, and finally one large cyst is formed. Such cysts increase rapidly in size, and may become very large, twenty quarts having been evacuated from one.

The *fluid* contained in fibro-cysts, as might be expected from their different nature, differs very much. Sometimes it coagulates by exposure to the air, and more frequently it is a serous, non-coagulating fluid. In small cysts it is citrine, viscid, or serous, but in larger cysts it contains more or less blood and becomes yellow, bloody, dark brown, or chocolate-colored. Sometimes the contents are purulent. The fluid is alkaline, and coagulates entirely on boiling and with acids. It contains always much albumin, and sometimes fibrin. The microscope reveals sometimes detached unstriped muscle-cells from the surrounding tissue.

When a considerable bloody extravasation takes place into the cyst, it may rupture, and the contents be poured into the peritoneal cavity.

[1] A specimen of this kind is described in detail in Garrigues's *Diagnosis of Ovarian Cysts by Means of the Examination of their Contents,* Wm. Wood & Co., New York, 1882, pp. 60–63.

The fibroid may *slough*, either spontaneously or after operations or after the use of ergot. In this way a cure may be effected, but the patient may also succumb to septicemia.

By deposit of calcareous matter in their interior fibroids may become *calcified* and form a stone-hard mass. They may also undergo *sarcomatous* or *carcinomatous* degeneration.

Etiology.—The causes of fibroids are unknown. The tumors are developed during the fruitful age of the woman. They are found more frequently in sterile women than in those who have borne children. Celibacy may perhaps predispose to their formation, but in most cases the sterility is probably the effect and not the cause of the fibroid. It is stated nearly everywhere that the negro race is more liable to fibroids than white people, but of late this has been denied by an American physician, who has had exceptional opportunities for personal observation of the fact.[1]

Symptoms.—Fibroids, especially polypi and the submucous variety, cause menorrhagia (p. 236) and metrorrhagia (p. 238), leucorrhea (p. 241), hydrorrhea (p. 397), and pain. The pain may be located in the abdomen, and be due to accompanying peritonitis, to the distension of the abdominal wall, or to the weight of the tumor. By pressure on the sacral plexus severe neuralgia may be caused in the pelvis, and shoot down through the legs. A polypus that is being expelled through the cervix gives rise to "cramps" or labor-like pain. The circumference of the abdomen may increase enormously. A tumor is felt entering the vagina, from the uterus, or imbedded in the uterine wall, or extending from it into the peritoneal cavity or into the broad ligaments or the pelvic floor. If it is a solid fibroid, it is generally more or less hard, globular, nodular, but may be quite soft, as we have seen in the anatomical description. If it is a fibro-cystic tumor with large cysts, it is fluctuating.

The presence of the tumor may oppose an obstacle to micturition or make it frequent. If it presses on the ureters, it may cause pyelitis and hydronephrosis. By pressing on the rectum it may be the cause of constipation and hemorrhoids. The presence of the tumor may interfere with the free circulation of the blood, causing edema, ascites, dilatation of the heart, or myocarditis. It may push the uterus down and cause prolapse (p. 440). If attached to the fundus, a fibroid polypus in descending may drag the uterus along and cause inversion (p. 446). In rare cases it produces diastasis of the linea alba, and lies partly in a ventral hernia. By pressure on the uterine vessels, fibroids may cause a sound like the uterine souffle of pregnancy, and in very rare cases a thrill like an aneurism.

The intraligamentous variety forms a tumor in the iliac fossa; that in the pelvic floor may be traced to the cervix.

[1] Dr. Middleton Michel of Charleston, S. C., *Med. News*, Oct. 8, 1892.

Diagnosis.—In most cases the diagnosis is easy, but it may be very difficult or impossible. From *hemorrhagic metritis* sessile fibroids differ by the presence of a tumor, which can be felt imbedded in the wall. A polypus in the vagina is felt with the finger; in the interior of the womb with the sound or, after dilatation (p. 152), with the finger. One examination, at least, ought to be made at the time of menstruation, since we have seen that the so-called intermittent polypus at that time becomes accessible to touch, and may be seen in a speculum.

In *cancer* of the cervix soft masses can be scraped off with the nail. There soon appears a hard ring around it; it ulcerates at an early date; and the discharge has an offensive odor. Cancer of the body gives rise to greater pain than a fibroid; the constitution suffers much more and sooner; the patient becomes emaciated, the skin has an ashy-yellowish color, while those affected with fibroids preserve for many years a florid hue and are in fairly good health. The lymphatic glands corresponding to the part affected with cancer become swollen. Ascites is more common with cancer, and a bloody ascitic fluid is nearly always associated with malignant disease. A sloughing fibroid polypus may resemble an epitheliomatous growth of the cervix, but the microscopical examination shows an entirely different structure.

A fibroid polypus is distinguished from a *glandular* by its hardness. It may not be possible to differentiate it from a *fibrinous polypus* until it has been removed and examined microscopically, but the fact that the trouble has begun after childbirth or abortion would make it likely to be the latter.

A fibroid in the posterior wall may from the vagina feel like a *retroflexion*, but by bimanual examination the fundus may be felt turned forward, or the direction of the uterine canal may be ascertained with the sound, and the greater thickness of the same between the sound and the posterior fornix of the vagina may be felt. A fibroid in the anterior wall may be taken for an *anteflexion*, but the diagnosis is made by judging of the thickness of the wall between the sound and the anterior fornix of the vagina.

A *uterus bicornis* may be taken for a single uterus with a fibroid, but the contour is more regular, the consistency normal, and the sound can be introduced into both horns.

In regard to the often difficult and very important differential diagnosis between polypus and *inversion* of the uterus the reader is referred to what has been said above (p. 449).

Another diagnostic feature of the utmost importance is the distinction between a sessile fibroid and *pregnancy*. As a rule, menstruation stops in the latter, while in the former it goes on, or is even increased in regard to the amount of the secreted blood and the duration of the

discharge. The development of the swelling is regular and more rapid in pregnancy. Softening of the cervix and lower uterine segment, fluctuation, ballottement, and recognizable parts of the fetus are felt. The fetal heart may be heard, and fetal movements both felt and heard. The mammary and stomachal signs of pregnancy are not found in connection with fibroids. In *hydramnion* we have besides the history of pregnancy an open cervical canal, through which the ovum can be touched.

Fibroid tumors may be combined with pregnancy, and the detection of such a condition may be of great practical importance in regard to treatment. A suspicion of such a condition should always be awakened by hemorrhages during pregnancy. The sound is, of course, not available. The physician must rely on the history, the stethoscope, and a careful palpation.

A small subperitoneal fibroid may form a tumor somewhat like that formed by swollen *appendages* adherent to the uterus, but, as a rule, the latter swelling will be softer and much more tender, and the uterine cavity is not enlarged. Accompanying peritonitis may, however, make a fibroid quite tender, and, on the other hand, old inflammatory masses around the appendages may form a very hard tumor.

Before making any diagnosis of abdominal tumors the physician should be sure to have the bowels well emptied with aperients and enemata, and the urine drawn with a catheter. Otherwise he might be deceived by *scybala* or a *full bladder*.

A pedunculated subperitoneal fibroid may be so like a solid *ovarian tumor* that the distinction becomes impossible, and the same holds good in regard to the diagnosis between a fibro-cyst and a multilocular ovarian cyst. In trying to differentiate them the following points should be considered. Fibro-cysts are rather rare; ovarian cysts very common. Fibro-cysts are hardly found in women below thirty-five years of age; ovarian cysts are frequent in young persons. Fibro-cysts develop more slowly. Patients with fibro-cysts preserve long a good general health and have a florid face, while in those with a multilocular ovarian cyst the constitution soon suffers. With a fibro-cyst the abdominal veins rarely become dilated; with an ovarian cyst it is quite common. Hard masses are felt above the fibro-cyst; in ovarian cysts they are found nearer the base if at all. A fibro-cyst draws the uterus up; an ovarian cyst pushes it down and backward or forward. With a fibro-cyst the uterine cavity becomes often considerably elongated; with an ovarian cyst it remains of normal length or is only slightly deepened. By means of the sound it may be possible to move the uterus independently of an ovarian tumor, while a fibro-cyst follows the movements of the uterus. Ascites is more commonly found with fibro-cysts than with ovarian cysts. Now-a-days we avoid aspiration and tapping, but if for some reason one of these

operations has been resorted to, coagulability of the fluid and the presence of muscle-cells in it militate strongly in favor of a fibro-cyst, while the presence of numerous small round bodies with several shining granules speaks as strongly in favor of an ovarian cyst.[1]

Fibro-cysts of the uterus can only be distinguished from *fibro-cysts of the ovary* by the circumstance that the former move with the uterus, while the latter may be movable independently. The fluid is identical.

In plain *ascites* there is a swollen, fluctuating abdomen, but no tumor. In ascites combined with a fibroid the tumor is felt on displacing the fluid. *Hematocele* and *exudative peritonitis* are acute diseases with a sudden start.

Prognosis.—The majority of fibroids give rise to no symptoms and are harmless. They are in themselves benign, but may endanger life in different ways. After the menopause their development is, as a rule, arrested; they begin to shrink and the patient suffers less; but, on the other hand, the change of life is often postponed in women affected with fibroids, and some fibroids continue growing, pursue a more disastrous course than before, and frequently become cystic, calcareous, or have abscesses develop in them.[2] A spontaneous cure may occasionally be effected by involution after pregnancy or expulsion of a polypus.

Hemorrhage rarely becomes directly fatal, but through the repeated losses of blood and the drain caused by leucorrhea the constitution finally suffers. Pain, worry, and disturbed sleep have a similar effect. Mechanically, the tumor may cause death by closing the ureters or the intestine. The heart suffers in consequence of the increased work thrown upon it. Large tumors press on lungs and liver, interfering with respiration and digestion.

The tumor itself has some tendency to sarcomatous or carcinomatous degeneration. The peritoneum becomes the seat of chronic inflammation, and sometimes palpillomatous degeneration.

In rare cases a fibroid becomes the cause of embolism and paralysis.

For the treatment of these tumors sometimes operations are required that belong to the most difficult and most hazardous.

Treatment.—In treating a case of fibroid tumor of the uterus the therapeutical resources at our command should, in the opinion of the writer, be considered in the following order:

Cut off polypi;
Tie and cut pedunculated subperitoneal tumors;
Lift tumor;
Hemostatic and anticatarrhal remedies;

[1] Exceptions are treated of in my above-named work on *Ovarian Cysts*, pp. 63–67.
[2] Joseph Taber Johnson of Washington, D. C., "Growth of Fibroids after the Menopause," *Amer. Jour. Obst.*, Dec., 1891, vol. xxiv., p. 1420.

Galvano-chemical cauterization;
Curetting;
Vaginal enucleation;
Oöphorectomy;
Ligation of ovarian vessels;
Total extirpation of uterus;
Supravaginal amputation—
(*a*) with extraperitoneal fixation of the stump;
(*b*) with intraperitoneal treatment of pedicle;
(*c*) with retroperitoneal treatment of pedicle;
Abdominal enucleation—
(*a*) from broad ligament;
(*b*) from pelvic floor;
(*c*) from uterine wall.

For a *polypus* there is no other treatment than to remove it as soon as possible. If it lies in the vagina, this is a very simple matter. The anesthetized patient is placed in the dorsal position, the legs fastened with Robb's leg-holder (p. 193), the vagina disinfected, the tumor brought into view with speculum and retractors, the cervix dilated with a steel dilator, the tumor seized with a volsella and pulled down, while an assistant presses on the fundus uteri. If the tumor is not very small, a better hold of it is secured by passing the noose of a linen tape around it above the volsella. If necessary, the tape may be pushed up by means of a crutch, an instrument exactly like a uterine sound ending in a little fork. This loop allows us to pull the polypus considerably down, and its pedicle is cut off with a few rotary movements of Thomas's spoon-saw (Fig. 248), a shallow spoon with

Fig. 248.

Thomas's Spoon-saw.

dull serrated margin.[1] The pedicle may be cut near the tumor, and it is safer to do so. Subsequently the stump is drawn into the substance of the uterus and disappears.

If the polypus is situated in the interior of the yet closed uterus, the cervix must first be dilated with aseptic laminaria (p. 152) or iodoformed cotton balls (p. 154).

An intermittent polypus should be removed during menstruation, when it can be seized in the vagina.

[1] Many instrument-makers make it too hollow and with too sharp teeth, which changes it from a safe and valuable instrument into a dangerous one.

Very large polypi may be brought out, after the pedicle is severed, by means of the obstetric forceps. Wedge-shaped pieces may be cut out of the lower part of the tumor in order to make it smaller, a procedure called *morcellement* by French surgeons; or a spiral incision may be carried around it, right into its substance, while it is being pulled down, which is called *allongement*.

As there often are other fibroids imbedded in the uterine wall, which in course of time become pedunculate, the operation may have to be repeated, although it is radical in regard to the tumor it is applied to.

Subperitoneal tumors can only be reached by laparotomy (see Ovariotomy). If they have a well-developed pedicle, it should be transfixed, and a double silk ligature of proportionate strength drawn through and cut into two halves, which are made to cross one another so as to form two interlocked loops, each of which is tied on opposite sides (Fig. 243). The object in dealing with the pedicle in this way is to prevent the ligature from slipping, which may cause fatal hemorrhage.

Great relief from pressure on rectum, bladder, or nerves, or from pulling on ligaments, may be afforded by *lifting* the tumor up, and sometimes it may be prevented from falling down again by a *pessary*, such as a large-sized Gehrung's (Fig. 230, p. 422) or Thomas's (Fig. 228, p. 422), or an abdominal belt with vaginal cup (Fig. 240, p. 443).

Medical Treatment.—Alone or as an adjuvant to other measures medicinal treatment is of considerable value in combating symptoms, and may even occasionally effect a radical cure. The chief symptoms that call for medicinal treatment are hemorrhage and leucorrhea, and we refer to what has been said on this subject in the general part under *Hemostatics* (p. 218), *Menorrhagia* (p. 237), and *Leucorrhea* (p. 242). The writer would particularly call attention to the value of gossypium for combating hemorrhage and pain. Ergot may be given by the mouth, in suppositories (extr. ergotæ, gr. ij–v in each, one, two, or three times a day), or hypodermically. For the latter purpose ergotin (gr. ij or iij) or sclerotinic acid (gr. ⅔) is preferred.

Some years ago, before the Apostoli treatment was introduced, I used such injections and saw good effect from them. The formula was

℞. Acidi sclerotinici, gr. x;
Glycerini, ʒss;
Aq. dest. q. s. ad ʒij.
M. Sig. Eight minims hypodermically.

The injections are made in the abdominal wall in front of the tumor, and they should be very deep. The syringe must be clean and the skin made aseptic. By so doing I have never seen an abscess form, but each injection is accompanied by considerable pain, redness, and

swelling, and leaves a knob slow to disappear. The injections were repeated three times a week. This treatment has afforded so good results in the hands of many observers besides myself, leading even in some cases to the total disappearance of the tumor, that under circumstances it is well worth trying. As a rule, the method is safe. Too large doses of ergot have, however, caused symptoms of poisoning; and a case has been reported in which the tumor became gangrenous, and the patient died of septicemia.[1]

Instead of sclerotinic acid, ergotin (gr. iij pro dosi) may be used dissolved in five parts of water:

℞. Ergotini (Squibb), ʒss;
Aq. dest., ʒijss;
Acid. carbol., ♏ij.
M. Sig. Eighteen minims for each injection.

To inject ergot preparations into the substance of the uterus is dangerous and offers no advantage.

Among mineral waters, Kreutznach, used both internally and in fomentations and baths, has the best reputation for its effect on fibroids.

With the exception of polypi, pedunculate subperitoneal fibroids and fibro-cysts, all others should, if possible, be treated with *galvano-chemical cauterization* after Apostoli's method (p. 225). In cases of hemorrhage and leucorrhea the positive pole is used in the uterus; in more dry cases the negative. If the electrode can be introduced into the canal, there is hardly any danger. I allow even the patient to go home by street-car and elevated railroads immediately after the application, which I prefer to make in the office, where more perfect apparatus is available. The first effect is to assuage pain, which gains the patient's confidence. In the vast majority of cases the tumor will become smaller, and in some it disappears. Hemorrhage will nearly always cease. The softer the tumor is—that is to say, the less connective tissue and the more serum are contained in the muscular bundles—the better are the prospects. In some cases I have seen parts of the tumor gradually pushed out, so as to form prominences in the peritoneal cavity. The method is so safe and promises so much, and, on the other hand, the cutting operations are so dangerous, that, as a rule, electricity should be given a fair trial before resorting to the latter.[2]

[1] W. T. Lusk, *N. Y. Med. Jour.*, July, 1882, vol. xxxvi. p. 30.

[2] Thomas Keith, who, at a time, was by far more successful than all contemporaneous operators, who had a mortality of only 8 per cent. in hysterectomy, and only lost 1 patient in almost 100 cases of oöphorectomy for uterine fibroma, rejects even the minor operation in favor of Apostoli's method ("Contributions to the Surgical Treatment of Tumors of the abdomen, Part II.," *Electricity in the Treatment of Uterine Tumors*, Edinburgh, 1889, p. viii.). Only when the galvanic treatment fails does he perform hysterectomy (*Gyn. Trans.*, 1890, vol. xv. p. 143).

Many patients, however, cannot get the tedious galvanic treatment, and, moreover, the experience of later years has shown that by operating early the prognosis for the operation—like that for ovariotomy—has become much better.

Hemorrhage may be checked by *curetting* (p. 171). Perhaps, it only gives relief for some months, but may then be repeated. By thus scraping off the hypertrophied endometrium the patient may sometimes be kept alive until the menopause arrives and brings permanent relief.[1] Properly performed, the operation is, as a rule, harmless; the writer has, however, had a case in which it was followed by gangrene.[2]

Vaginal Enucleation by Means of the Spoon-saw.—Large sessile myomas, weighing up to three pounds,[3] have been successfully removed through the vagina. The method is applicable to both cervical and corporeal fibroids. The patient is placed in Sims's position, and his largest speculum is introduced. If the cervix is partially open, and the tumor offers a free end near it, the cervix is seized with a tenaculum-forceps and severed bilaterally up to the vaginal vault. A volsella is fixed in the lower end of the growth, and the uterine attachments severed with the spoon-saw. The cavity should next be washed out with disinfectant fluid and packed with iodoform gauze (p. 175).

If the cervix is open and the tumor entirely imbedded in the wall of the body or situated in the cervix, a strong tenaculum is plunged into it, and a hole is cut with scissors in the lowest part of the presenting mucous membrane covering the tumor. This is extended on a director, the mucous membrane detached with the finger, a volsella fastened in the white tissue of the myoma, and the spoon-saw introduced and swept all around, detaching the tumor from its uterine bed for about an inch and a half or two inches, while traction is kept up. If the tumor is too large to be dragged down as a whole, it is removed piecemeal. For this purpose pieces large as hen's eggs are cut out, one after the other, from the detached part of the tumor. Then the tumor is again seized with the volsella, a new zone detached and removed piecemeal in the same way, and so forth until the remainder can be removed with the spoon-saw in one piece. It is only the first incision that is accompanied by serious hemorrhage; the tumor itself has few vessels, and the spoon-saw with its blunt serrated edge peels it out from its bed without much bleeding.

[1] An instructive paper on this subject was published by Henry C. Coe in *The Medical Record*, Jan. 28, 1888.

[2] The patient recovered, and was radically cured, but another time the result might be less favorable. I scraped away what I could with the finger, tore dead shreds off with forceps, and used carbolized intrauterine and vaginal injections.

[3] Thomas, *Amer. Jour. Med. Sc.*, April, 1880, vol. lxxix. p. 405; Mundé, *Amer. Jour. Obst.*, 1885, vol. xviii. p. 189.

If the cervix is closed, it must be thoroughly dilated before enucleation is begun. For this purpose it is split up to the vaginal junction with Küchenmeister's scissors, and the internal os incised bilaterally with Simpson's metrotome (p. 409), until all resistance is overcome, and finally full dilatation is obtained by using tents or cotton balls impregnated with iodoform, procedures which take days and weeks, and during which I more than once have seen the patients succumb to septicemia.

Greater than the danger from hemorrhage is that of perforating the uterus. It is impossible to know if the tumor has more than a peritoneal covering. At all events, the spoon-saw must be kept close up to the tumor. In pulling the uterus down it may become inverted (p. 452), and the inverted part must be replaced as soon as the fibroid is enucleated. The danger from septicemia after the operation is also considerable.

In exceptional cases, the fibroid starting from the posterior surface of the uterus presses against the vagina, and may be enucleated through an incision there.

Emmet's Traction Method is, in some respects, like the preceding method of enucleation, but the capsule is never opened, and all is done in the vagina, not in the interior of the uterus. The tumor is seized with a volsella, pulled down, and removed piecemeal as it emerges from the os. In this way muscular contraction is induced, and the surrounding tissue gradually closes upon the removed tumor, so that it becomes pedunculate and leaves only a small raw surface.

Oöphorectomy.—With the hope of bringing about the menopause prematurely, and diminishing the size of the tumor, the ovaries and tubes may be removed. The first part of this operation consists in laparotomy, which will be described under Ovariotomy. In regard to the next part, the removal of the ovaries, the reader is referred to Diseases of the Tubes. If the tumor is a large one, it may be very difficult to reach the ovaries. The uterus must not be tilted out of the abdominal cavity, as it may suddenly become so congested that it cannot be replaced. It may, however, be advantageously turned on its longitudinal axis. But the ovaries may be so imbedded in adhesions and inflammatory masses that it proves impossible to remove them. Gangrene of the myoma has followed the removal of the ovaries. If the cavity of the uterus measures over six inches, there is little hope that the operation will be of avail. On account of hemorrhage it is not safe to tear adhesions which cannot be brought into view.

If it is impossible to remove the ovaries, the menopause may yet be brought about by tying the ovarian blood-vessels.

Of the operations in which more or less of the uterus is removed, the *complete extirpation*, although seemingly the boldest, is perhaps the safest.

Modus Operandi.—1. *Bardenheuer's Method.*[1]—A circular incision is made around the cervical portion, and the vaginal wall separated from the cervix. A tampon of iodoform gauze is left in the vagina. Next, laparotomy is performed with the patient in Trendelenburg's position (p. 136). The incision will extend from the symphysis pubis to the umbilicus or still farther. In so doing most operators go to the left of the umbilicus, but Keith goes right through it. A corkscrew is bored into the uterus, by which it is more easy tilted out through the wound and manipulated later. If the tumor is not very large the fundus may be seized with a strong volsella instead of using a corkscrew. After turning out the uterus the edges of the abdominal incision above it are held together and covered by a flat sponge or a cloth. The upper part of the broad ligaments, including the ovarian arteries, is tied, a long pressure-forceps (Fig. 249) placed inside of the

FIG. 249.

Long Pressure-Forceps.

ligature nearer the uterus, and the intervening tissue cut. Then the remaining part of the broad ligaments is tied, section after section,

FIG. 250.

Polk's Needle: *A*, movable needle; *B, B*, the needle brought backward and forward; *C*, button for stopping movement.

and cut loose, the ligatures being passed with Polk's needle (Fig. 250), a curved blunt needle with the eye near the point and a movable

[1] I call it so for brevity's sake. The chief features are Bardenheuer's, but minor improvements by others are included in the description.

joint, which is fixed by a button on the side of the handle.[1] Next, a transverse incision is made at the bottom of the vesico-uterine pouch and the bladder separated from the cervix. A similar incision behind, in Douglas's pouch, separates the rectum from the uterus, which now hangs only by a band on either side of the cervix, containing the uterine arteries. Finally, these bands are tied and cut.

If the tissue containing the uterine arteries can be reached and tied before opening the pouches in front of and behind the uterus, the uterus may be cut off at the level of the internal os, which sometimes facilitates the removal of the cervix.

A piece of iodoform gauze left in the opening serves to prevent prolapse of the intestines and provides for free drainage. The last act of the operation is to close the abdominal wound and dress it in the usual way (see Ovariotomy). A similar antiseptic pad is laid over the vulva and anus, and fastened with safety-pins to the bandage surrounding the body.

After-treatment.—The abdominal dressing is left undisturbed for a week, and later changed as after all other laparotomies. The gauze tampon in the vagina is changed after two days, and a new one put in once a day. After the first four days the vagina is washed out, at the time of dressing, with antiseptic fluid. The wound in the vagina closes in the third week after the operation.

2. *Martin's Method.*—The whole uterus with the cervix is removed through the abdominal incision. The peritoneum is stitched to the vagina. The stumps of the broad ligaments are turned into the vagina by means of the ligatures, which are left long, and finally the peritoneum is brought together with another continuous suture above the first, so that the pelvic cavity is closed and covered all over with peritoneum.

3. *Polk's Method.*—Polk ties the infundibulo-pelvic ligament, then the round ligament, and places a third ligature just outside of the corner of the uterus comprising the tube, the anastomosis between the uterine and the ovarian artery and the round ligament. After cutting the upper part of the broad ligament, he introduces his thumb between the two layers until he feels the uterine artery, and ties this. He makes an anterior and posterior peritoneal flap on the uterus. After enucleation of the cervix he stitches these flaps to the vagina with five or six sutures left long, tied together with one knot, and pulled into the vagina with forceps, thus inverting the vagina, which then is packed with iodoform gauze. This remains undisturbed for a week.

Special Difficulties.—The *bladder* may be spread out and adhere to the front of the tumor. This condition may sometimes be diagnosticated before the operation by means of a male urethral sound. If so, the incision through the abdominal wall should be made above the

[1] W. M. Polk, *Amer. Jour. Obst.*, 1887, vol. xx. p. 294.

upper limit of the bladder, the contour of the organ made out by means of the sound, an incision made corresponding to it, and the bladder dissected off from the tumor, using as much as possible blunt instruments and the fingers.

In order to avoid wounding the bladder, it is advisable not to empty it entirely before the operation, but even to inject water into it.

If the bladder has been wounded, it may be disposed of in two ways: either the wound is closed separately with a catgut tier-suture (p. 213), or in closing the abdominal wall the whole wall of the bladder is included in the stitches. In the first case, the mucous membrane is first closed by one row of sutures, and the remaining tissue is brought together by one or two rows. For the peritoneum it is well to use Lembert's intestinal suture.

If in the second case a urinary fistula forms, it closes spontaneously. A permanent catheter should be left in the bladder or the urine drawn frequently.

If there is a persistent *urachus*, it may be avoided by making the incision through the abdominal wall at the side of it. If it has been wounded, the wound may be closed by comprising it in one of the abdominal sutures.

On the side of the cervix great care must be taken not to comprise the *ureter* in a ligature.

The *omentum* is often attached to the tumor. If the adhesion is slight, the separation is best made by brushing the omentum away from the tumor with a sponge squeezed dry. If it is tough, it must be cut between one or more sets of double ligatures.

Sometimes the *intestine* is found intimately adherent to the tumor. If it cannot be peeled off, an incision is made on the tumor, through the peritoneum around the adhesion, and the peritoneum dissected off from the tumor and left in connection with the intestine. Next,

FIG. 251.

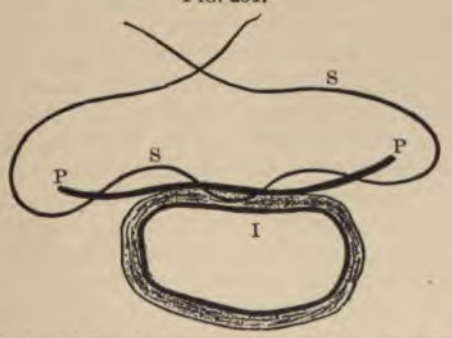

Method of Closing Peritoneal Flap left on intestine, after separating it from uterine fibroid (Schroeder): I, intestine; P, peritoneal coat of fibroid; S, catgut suture.

the raw surface is folded together by means of one or more catgut sutures (Fig. 251).

In order to overcome the difficulties presented by the mere weight of large solid abdominal tumors of any kind, and by the assistant who lifts it being in the way of the operator, Reverdin has invented a particular lifting apparatus. A pulley is fastened to a beam in the ceiling of the operating-room above the table. Over it moves a thick cord, to the lower end of which is attached a metal chain dividing into two smaller chains, each ending in a hook. These hooks are inserted into the rings of a strong volsella, with which the tumor is seized. An assistant, standing at a distance, out of the way of the operator, raises the tumor on command by pulling on the cord. To the chain is fastened a ring or hook, through which the free end of the cord is drawn, so that the assistant is enabled also to pull the tumor to the side.

Supravaginal Amputation of the Uterus.—In this operation the cervix is left and forms a stump. There are two chief varieties, with *extraperitoneal* and with *intraperitoneal* treatment of the pedicle.

A. *Extraperitoneal Treatment of the Pedicle* (Hegar's Method).—When the uterus is turned out, an elastic ligature is thrown around the cervix, including the broad ligaments. Only in exceptional cases, if the tension is too great or the mass too voluminous, are the ligaments tied first and cut between two rows of ligatures. An elastic ligature—a piece of rubber tubing as thick as the little finger, or a solid rubber string a quarter of an inch thick—is turned twice around the cervix, drawn very tight, and crossed once. Then the ends are seized in front of the crossing between the blades of a pressure-forceps, and tied together with a silk ligature behind the forceps. When this is tied, the ends of the elastic ligatures are pulled out a little more and a second silk ligature is placed at some little distance behind the first, and all ends of rubber and silk ligatures are cut short.

Next, the uterus is cut off one and a half to two inches above the elastic ligature, and the peritoneal covering of the stump stitched with a fine curved needle and a continuous catgut suture to the peritoneum near the lower end of the abdominal incision, under the ligature, so as to close the peritoneal cavity. The remaining peritoneal edges are stitched together, and the abdominal wound closed as in other laparotomies, leaving a circular furrow formed of the receding muscular, fascial, adipose, and cutaneous layers of the abdominal wall.

The stump of the uterus is transfixed with a pair of steel pins crossing one another at right angles above the ligature. Small caps are pushed over the points in order to protect the skin. The cut surface and the cervical canal are seared with Paquelin's cautery, and covered, as well as the surrounding furrow, with a mixture of 3 parts of tannin with 1 part of salicylic acid. Finally, the whole is dressed

as after a common laparotomy, and the dressing need not be changed for eight or ten days, when the sutures are removed.

It is not rare that a bloody discharge from the vagina appears three or four days after the operation. It is without importance.

The stump falls off after fifteen to twenty days, leaving a deep funnel-shaped depression, the necrosis extending beyond the elastic ligature. This funnel is dressed with iodoform gauze, which is changed daily until the surface is healed.

In leaving the above-described furrow free between the pedicle and the abdominal wall, except the peritoneum, a great source of infection and death has been eliminated, but, on the other hand, a weak point is left in the abdominal wall, and it is necessary for the patient to wear an abdominal belt.

If the ovaries are left behind, it happens occasionally that the menstrual flow continues through the pedicle.

B. *Intra-peritoneal Treatment of the Pedicle.*—The unquestioned victory won in ovariotomy by the intra-peritoneal treatment over its rival constantly has impelled surgeons to apply the same principle to the amputation of the uterus; but special difficulties are met with in the contractility of the pedicle, and the danger of infection taking place through the cervical canal, unfavorable circumstances which, however, to a great extent, have been obviated in different ways.

1. *Treub's Method.*—Among the various methods with intra-peritoneal pedicle-treatment that of Treub recommends itself by its great simplicity and consequent expeditiousness, which, in this operation, in which so many have died from shock, is of paramount importance. The abdominal incision is made so large that the uterus can be turned out easily. One, or in exceptional cases two, single ligatures are tied around the upper part of the broad ligament, outside of the ovary. Inside of this a pressure-forceps is applied, and the ligament cut between it and the ligature. An elastic ligature—a Nélaton's catheter, Jaques's patent, No. 14 or 15—made aseptic by lying for two days in a 5 per cent. solution of carbolic acid, is carried twice round the cervix, tightened with great force, tied in a single knot, the ends of which are tied together with silk, and then the ends of the rubber and the silk ligatures are cut short. The uterus is cut off horizontally, half an inch above the ligature, the stump being held up with a volsella. The cervical canal is disinfected by wiping it with a strong solution of bichloride of mercury (1 : 500). The three stumps of the uterus and the broad ligaments are dusted with iodoform, the intestines are lifted up from the true pelvis, the pedicles dropped below them, the abdomen closed, and a tampon of iodoform gauze left in the vagina, from which it is removed in the third week, unless it has been expelled before. During the first five days the patient should lie on her back, so that the stump may stay in the

same place. With this simple treatment Treub has obtained excellent results.

2. *Schroeder-Hofmeier's Method* (Fig. 252).—When the uterus is

Fig. 252.

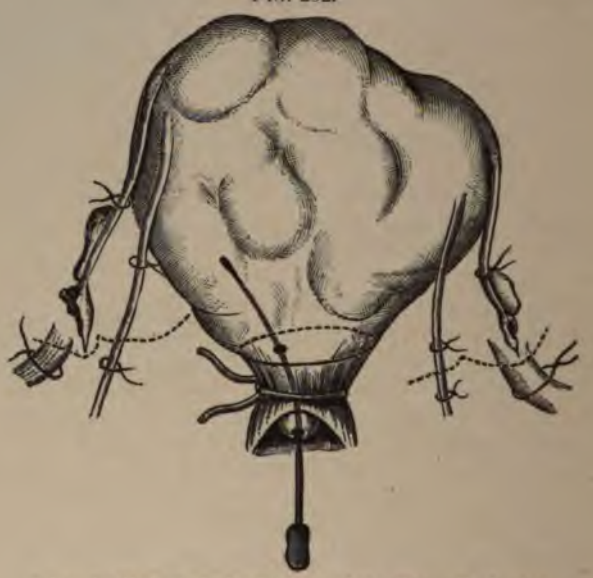

Schroeder-Hofmeier's Amputation of the Uterus (Hofmeier).

turned out, a ligature is tied around the infundibulo-pelvic ligament and a second around the tube, just inside of the ovary. In so doing as much as possible of the broad ligament is comprised in the ligature. The ligament is next cut outside of the ovary. For safety's sake it is best to tie the ovarian artery separately on the cut surface. Next, two ligatures are tied around the round ligament, and the incision continued between the two down toward the edge of the uterus, but not so near as to wound the uterine artery. An elastic ligature is placed temporarily around the cervix. If feasible, the elastic ligature is thrown around the cervix and the broad ligaments together, and the silk ligatures are inserted later, which saves one row of ligatures. Next, the uterine artery with the surrounding tissue is caught in a mass ligature and severed. In order to avoid pulling on the ligatures, they are immediately cut short. A transverse incision is now made through the peritoneal covering of the uterus one and a half to two inches above the elastic ligature. The peritoneum recedes, and the muscular tissue is cut about an inch over the elastic ligature in such a way as to form a hollow cone. The mucous membrane is rubbed

with disinfecting fluid or burned with Paquelin's cautery in order to avoid infection, and then cut out so as to remove the diseased tissue and allow a better adaptation of the flaps. When this is done, the

FIG. 253.

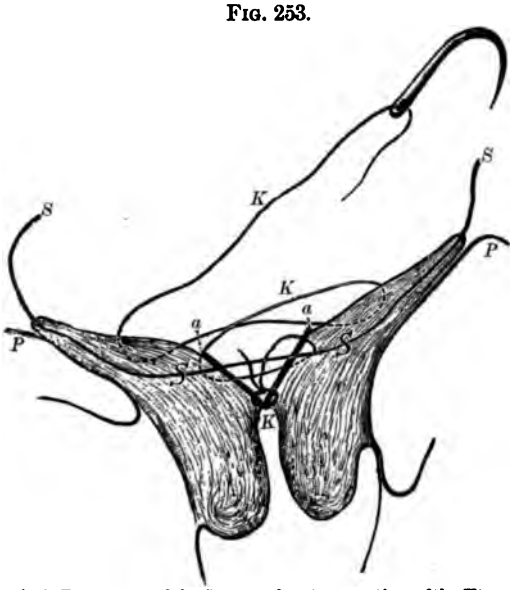

Schroeder-Hofmeier's Treatment of the Stump after Amputation of the Uterus: *P*, peritoneum; *a,K,a*, excision of mucous membrane of upper part of cervix; *K,K*, catgut tier-suture; *S*, silk suture.

lower part of the funnel is first closed with one or two rows of catgut sutures, so as to shut off communication with the cervical canal. Next, from four to six silk sutures are inserted under the whole wound, entering just at the edge of the peritoneum, and left loose until the two opposite surfaces have been stitched tightly together with a continuous catgut suture. Then the silk sutures are tied and the elastic ligature loosened. If there is any bleeding, it is checked with additional deep silk sutures. Finally, the peritoneum is stitched together with a continuous catgut suture over the whole stump. This is dropped, the abdominal cavity cleaned and closed as after common laparotomies.

In some cases every stitch-hole bleeds. Then the elastic ligature, preferably a thinner one than that used temporarily, should be re-applied and dropped with the pedicle.

3. *Continuous Sectional Ligature* (*Zweifel's Method*).[1]—With a

[1] This "fortlaufende Partien-ligatur" is a modification of the old ligature used for flat and elongated nævi (Erichsen, *Science and Art of Surgery*, 4th ed., London, 1864, p. 685).

handled needle a silk thread is carried through the part to be tied, half an inch from the edge; the thread is freed from the eye, and a second thread inserted, which is pulled back with the needle, and again carried through the part to be tied at a distance of half an inch. The two ends of the same thread are provisionally tied together or grasped in pressure-forceps. The needle is again threaded, and thus one thread is placed parallel to the other, until the whole part to be tied is embraced by loops. Then the threads are pulled taut, tied, and cut short, except the one nearest to the uterus, which is left long. Each broad ligament is tied in this way with a double row of ligatures and cut between the two rows. A soft-rubber ligature is placed at the bottom of the gap, and tightened round the cervix and below the two ligatures left long (Fig. 254). Next, an anterior and

FIG. 254.

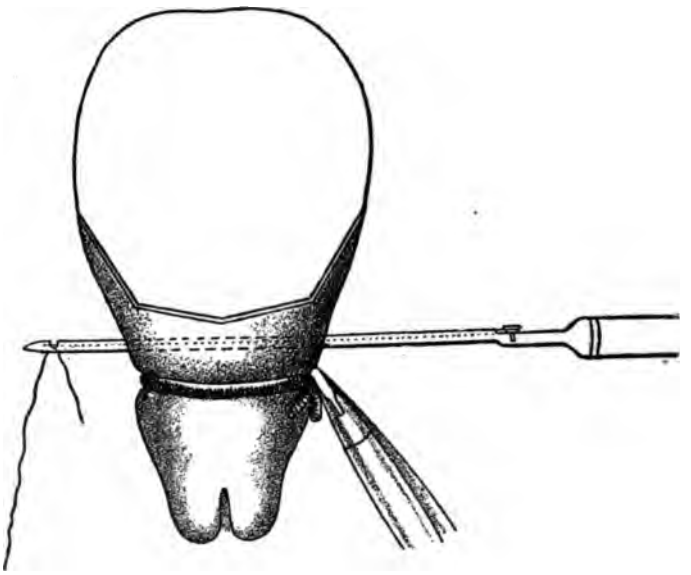

Treatment of the Stump by Zweifel's Method: The flaps are cut, the rubber tube tightened around the cervix. A needle is seen carrying a silk thread back through the stump.

posterior flap of peritoneum and as little as possible of the underlying muscular tissue are dissected off from the uterus, and the cervix cut at the bottom of the flaps horizontally and parallel to the constricting rubber ligature (Fig. 254). The cervical canal is seared with Paquelin's cautery. The stump is again sectioned from before backward with the threaded handled needle as described above, at a small distance from the cut surface; and when the threads have been tied, the

rubber ligature is taken off. Finally, the peritoneal flaps are stitched together over the stump with catgut, taking care to tuck in the edges

FIG. 255.

Treatment of the Stump by Zweifel's Method: All sutures are closed. The lower row represents the continuous sectional ligature of the cervix with silk; the upper, interrupted, sero-serous catgut sutures uniting the peritoneum.

so as to apply serous surfaces against one another, and the stump is dropped (Fig. 255).

FIG. 256.

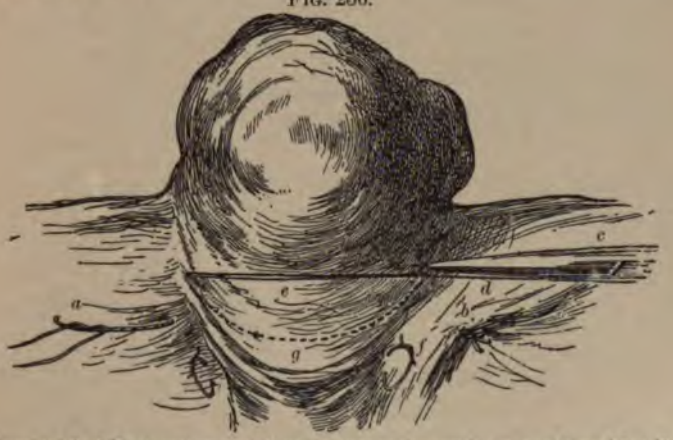

Baer's Supravaginal Hysterectomy without ligature of the cervix: *a*, position of first ligature, transfixing broad ligament and including ovarian artery and veins; *b*, same tied; *c*, rectangular forceps grasping broad ligament under Fallopian tube and ovary to prevent reflux from uterus when *d*, broad ligament, is severed just below the forceps; *e*, incision of peritoneum above reflexion of bladder, and the peritoneum stripped down below *g*; *f*, ligature transfixing broad ligament at side of cervix, including uterine artery; *g*, dotted line excision of tumor and amputation of cervix.

While this mode of ligature is well adapted for the tough tissue of the cervix, it would probably be better, in order to avoid tears, to

cross the threads before tying them on the broad ligaments. (See *Chain-ligature* under Ovariotomy.)

4. *Baer's Method*[1] (Fig. 256).—A *single* silk ligature is passed with Schroeder's needle—*i. e.* a large strong aneurysm-needle bent to the

FIG. 257.

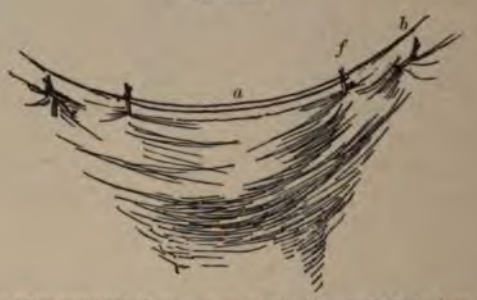

Baer's Hysterectomy after removal of uterus; *a*, center line, infolded edges of broad ligament lying closely in contact, having been rendered taut by ligatures *f* and *b*, which have included both layers of the broad ligaments and ovarian and uterine arteries and veins.

side (Fig. 258)—through the broad ligament, entering near the cervix and coming out near the upper edge of the ligament so as to prevent the

FIG. 258.

Schroeder's Needle.

ligature from slipping. This is now tied, and compresses the ovarian artery and veins. A stout, but narrow, clamp-forceps bent at right angles, with jaws two and a half inches long, is next placed outside of and under the ovary and tube, and made to grasp the broad ligament for the purpose of preventing reflux from the uterus. The ligament is now severed just below the forceps, the incision being carried as close as possible to the uterus without severing the uterine artery. If deemed necessary, another ligature is now passed through the broad ligament, farther down, along the side of the cervix. This ligation and cutting is repeated on the opposite side. The knife is then run lightly around the uterus, in a straight horizontal line a fingerbreadth above the peritoneal reflection of the bladder, the limit of which is ascertained by having an assistant introduce a sound into it, and the severed edge of the peritoneum is stripped down with the handle of the scalpel for the purpose of making two peritoneal flaps, the anterior

[1] B. F. Baer of Philadelphia, Pa., *Amer. Jour. Obst.*, Oct., 1892, vol. xxvi. p. 489.

of which contains the bladder. Next, the uterine arteries are ligated. This is done in the broad ligament, outside of, but close to, the cervix, with a medium-sized Hagedorn needle. The ligature may either be placed within the folds of the broad ligaments, or, which is preferable, made to encircle both layers of the ligament and the artery in one sweep. The constant traction made upon the pedicle by the assistant who is holding the tumor serves to draw out and elongate the cervix, and permits its amputation at a deeper level, leaving a cupped surface. The stump is now seized with a small volsella, and further trimmed down, if necessary, so that the entire supravaginal portion is removed before it is dropped back. The cervix being released, immediately recedes, and is drawn deeply down into the pelvis by the retractive property of the vagina, where it is buried out of sight by the peritoneal flaps covering it. These flaps have been rendered so taut by the ligatures in the broad ligaments that usually they close over the receding cervix like elastic bands. The edges of the flaps are folded in, and may be stitched together by Lembert's suture if necessary. This, however, is not needful, if the ligatures that secured the uterine arteries have also grasped the folds of the broad ligaments, for this so tightens them that the edges are brought forcibly together when the cervix is drawn under. *Nothing is done to the cervical canal*, and the abdomen is closed.

Drainage through the Cervical Canal.—A particular subdivision of the intraperitoneal treatment is constituted by operations which provide for a discharge from the seat of the operation through the cervical canal.

1. *Chroback's Method.*[1]—Double ligature of the appendages and broad ligaments; incision between the ligatures; curved incision through the peritoneal coat of the uterus, circumscribing two flaps, of which one shall be much longer than the other; dull separation of the peritoneum down to the fornix of the vagina; constriction of cervix with an elastic ligature, or, if the tumor is not in the way, ligature of both uterine arteries; amputation of cervix half an inch above the vesico-uterine fold of the peritoneum; searing of the cervical canal with the thermo-cautery; transfixion of cervix with silk in handled needle; and separate ligation of the anterior and the posterior lip with silk, avoiding the peritoneum. A strip of iodoform gauze one inch wide is pushed with a uterine sound through the cervical canal down into the vagina, where the end is covered with a pledget of similar material. The peritoneum is closed all along the incision in the broad ligaments, and the uterine stump with one continuous catgut or silk suture. On account of the different lengths of the flaps the line of suture does not correspond to the cervical canal, and the raw

[1] Besselmann, *Centralbl. für Gynäk.*, 1891, vol. xv. No. 47, p. 939.

surface of the stump is all covered with one of the flaps. Finally, closure of the abdominal wound.

The gauze is removed from the cervix on the third day. A thick yellow non-purulent fluid comes off, and there is no fever.

2. *Goffe's Method.*[1]—Dr. Goff makes first the peritoneal flaps, and ties an elastic ligature round the cervix and ligaments. The main mass, including the ovaries and tubes, is then cut away, care being taken to catch the ends of the broad ligaments before they are severed, in the grasp of a strong forceps, in order to prevent their slipping out of the ligature. The ovarian artery is picked up on the cut edge and tied. The uterine stump is next transfixed with silk inside of the flaps, below the elastic ligature, and securely tied in two lateral halves, like the pedicle of an ovarian tumor. The elastic ligature is now removed, the stump trimmed down, and the cervical canal touched with pure carbolic acid. The peritoneal flaps are then brought up and securely stitched together with a continuous catgut suture, extending from the upper border of one broad ligament, over the stump, to the upper border of the other broad ligament, uniting the cut edges of the anterior and posterior layers of the ligaments and the flaps, thus shutting out the silk ligature and all raw surfaces. Finally the forceps are removed. About the fourth day, when there is a rise in temperature, the cervix is dilated with an expanding dilator, which gives exit to pus and broken-down tissue. The cervix is washed out, and a metal drainage-tube two inches in length, with attached rubber tube leading out of the vulva, inserted. The dilatation is repeated every three days till the temperature becomes normal, and the discharge insignificant.

Instead of the drainage-tubes, a long Outerbridge's cervical expander (p. 181) may be used. After a shorter or longer interval the ligature comes out through the cervix.[2]

If the tension is too great to embrace the broad ligaments in the ligature, they are grasped between two pairs of clamp-forceps and cut two-thirds of their depth. Next, the lower ends of these two incisions are united by one through the peritoneum in front and behind, the peritoneal flaps stripped down, and the elastic ligature tied round the pedicle before cutting off the main mass of the uterus with the tubes and ovaries. The ovarian arteries are tied with catgut, and the peritoneum closed as above.

With the exception of Treub's method all these methods cover the stump more or less perfectly with peritoneum, and are, therefore, *retroperitoneal*, although intra-abdominal.

[1] James R. Goffe, *Amer. Jour. Obst.*, 1890, vol. xxiii. No. 4, p. 372.

[2] If strict antisepsis is observed, there will be neither fever nor formation of pus and débris, and the ligature will be retained; but if an abscess forms in the stump, the dilatation of the cervix may save the patient's life.

There are numerous modifications of these myoma-operations upon which the scope of this work does not allow us to enter.

Abdominal Enucleation.—A fibroid may be enucleated, that is to say, separated from the surrounding tissue and removed, from the broad ligaments, from the pelvic floor, or from the substance of the uterus.

A. *Enucleation from the Broad Ligaments.*—If possible, it is a precaution against bleeding to tie the ovarian and uterine arteries. But even without this a transverse incision is made through the peritoneum over the whole tumor. The peritoneum is stripped back with the finger, and a volsella inserted into the tumor, which is pulled upward. As a rule, the tumor is enucleated without a pedicle; in other cases the tube or the substance of the uterus forms one, which is tied and cut.

A large cavity is left, that may be dealt with in different ways.

1. A. Martin's method is to perforate the bottom so as to enter the vagina with a forceps which is pushed through to the vulva. Here a soft-rubber T-shaped drainage-tube is seized, and pulled up till the transverse bar lies in the bed of the tumor. Then the peritoneum is stitched together.

2. Fritsch's method is to cut off redundant tissue, stitch the edge of the pouch to the edges of the abdominal wound, and fill the pouch with iodoform gauze disposed like a fan, which serves both to check hemorrhage and to secure drainage.

Another way of packing the iodoform gauze is that of Mikulicz: a large piece of gauze with a strong silk thread attached to the middle is introduced into the cavity to be compressed, and is filled with strips of gauze like a bag. After a day the interior strips are withdrawn, and finally the outer piece is removed by pulling on the silk thread.

If it is not possible to stitch the sac to the abdominal wall, it is stuffed with iodoform gauze, the peritoneum closed over it with a tobacco-pouch suture, an incision made in the vagina, and the end of the gauze, which has been marked beforehand by attaching a silk thread to it, pulled a little down into the vagina. In both cases the vagina is solidly tamponed with iodoform gauze.

3. A third method (Hofmeier's) is to stop hemorrhage by stitching the bleeding places with a continuous catgut suture, and let the walls of the wound fall together. Sometimes it suffices to touch the bleeding spots with Monsel's solution.

It is also advisable to throw an elastic ligature around the cervix as soon as feasible, or around the lower part of the tumor, so that a part of it may be cut off, which facilitates the removal of the remainder (so-called *morcellement*).

B. *Enucleation from the pelvic floor*, under the broad ligament, is

still more difficult and dangerous. It is carried out according to the same principles as for intraligamentous tumors.

C. *Enucleation from the Uterus.*—When a fibroid is shelled out of the uterine substance, a capsule is left, the walls of which are hard to bring together with sutures. The results have been so little satisfactory that other operations are preferred.

Complication with Pregnancy.—Fortunately, most women with fibroids are sterile, and if they conceive, their pregnancy quite frequently ends in abortion or in premature labor. Labor at term may be easy, but oftener the fibroid proves a dangerous complication. If we are consulted as to the advisability for a woman afflicted with a fibroid of the uterus to contract marriage, it is, as a rule, best to dissuade her from it. Pregnancy having occurred, it is in harmony with nature's own method to induce abortion or premature labor, if the tumor is situated in such a place or has such proportions that great trouble may be anticipated by allowing gravidity to go on till full term.

To perform operations during pregnancy will be likely to lead to abortion. Unless there be urgent symptoms, such as hemorrhage or pressure, it is better to delay operative interference till labor sets in. A pedunculated subserous tumor may sometimes be pushed up out of the way of the child. A cervical tumor may be enucleated, and on account of the succulence of the womb and the uterine contractions present, the enucleation is both easier and safer than under ordinary circumstances. But if the tumor extends high up, it may be necessary to perform Cesarean section or Porro's operation or to sacrifice the child.

If the child has been born, it is better to postpone the consideration of operation, so much more so as we have seen that the tumor may disappear during involution.

Sloughing.—For some gynecologists the appearance of sloughing in a sessile fibroid is an indication for hysterectomy. Taking into consideration the unfavorable condition in which that grave operation would have to be performed, and the case referred to above (p. 465), I am inclined to think a more palliative treatment is preferable, especially if septicemia has already developed.

Mortality.—In deciding the question of the advisability of performing cutting operations for the removal of fibroids we should bear in mind that the disease for which they are to be performed rarely leads to death; that, as a rule, improvement takes place after the menopause; and that, on the other hand, the operation is followed by a large mortality. Until the last decade enucleation from the cervix had a mortality of from 15 to 20 per cent.; hysterectomy, with extraperitoneal treatment of the pedicle, 25 per cent.; with intraperitoneal treatment of the pedicle, 33 per cent.; and in cases of extensive enu-

cleation from the broad ligaments and the pelvic floor the death-rate was even 57 per cent.[1] But constant progress is being made, and several operators have of late reported runs of a score of hysterectomies without a death.

Causes of Death.—Death after fibroma-operations is due to shock, hemorrhage, septicemia, embolism, intestinal obstruction, or tetanus.

Shock plays a very great rôle in operations that often are very protracted,[2] and in which the abdominal organs are exposed to much handling. The danger is so much greater as sometimes, in consequence of the presence of the fibroid or its treatment by ergot, the patient has a weak heart. In order to avoid shock, the patient should be kept warm during the operation, in which respect the above-mentioned woollen leggings (p. 193) may be of use. The operation should be simplified, and performed as rapidly, as possible. The intestines should not be exposed or handled more than absolutely necessary, which is much facilitated by the Trendelenburg posture. Ether should be used for anesthesia. When the heart flags, hypodermic injections of tincture of digitalis should be given.

Hemorrhage is now controlled much better than formerly by means of pressure-forceps and the elastic ligature. If the intraperitoneal treatment of the pedicle is used, internal hemorrhage may take place after the operation is finished. This dangerous condition makes itself known by the restlessness of the patient, a weak, frequent pulse, pallor, a cold, clammy skin, a swelling of the abdomen, and sometimes a distinct feeling of the warm fluid being poured out into the abdominal cavity. Under such circumstances the only means of rescue is speedily to reopen the abdomen, clean out the cavity, find the source of hemorrhage, tie the bleeding vessel or put in additional sutures, inject a pint of hot water into the rectum or inject a warm saline solution (common salt a little over ½ per cent. will do) into a vein, into the peritoneal cavity, or under the skin. The best place for this subcutaneous injection is under the clavicle: ℥iij–vj are injected every ten or fifteen minutes, until at least ℥xxiv have been injected. For any of these injections an apparatus which I described in 1878, and have used several times with success, will be found convenient. It is essentially a fine Davidson syringe.[3] Bottles with hot water are

[1] Complete statistical tables are found in "A Review of the Operation of Gastrotomy for Myofibroma," by H. R. Bigelow of Washington, D. C., in *Amer. Jour. Obst.*, 1883-84. Geo. W. Johnston of Washington, D. C., has collected a large number of cases of fibromata of the cervix, *Amer. Jour. Obst.*, 1885, vol. xviii. p. 1280. (See also "Analysis of Some Statistics on Supravaginal Hysterectomy," by Marie B. Werner, *Annals of Gynecology*, Oct., 1892, vol. vi. p. 56.)

[2] Péan's operations have often taken three hours. (Péan et Urdy, "Hystérotomie," Paris, 1873.)

[3] Garrigues, "Apparatus for Transfusion," *Amer. Jour. Obst.*, October, 1878, vol. xi. No. 4, p. 754.

applied all around the patient, the extremities are rubbed, and stimulants are used freely.

Septicemia may be due to the entrance of pathogenic germs during the operation, to the use of insufficiently disinfected materials, and

FIG. 259.

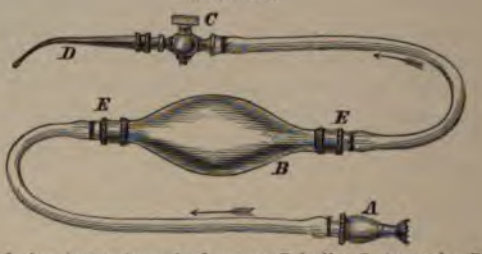

Garrigues's Transfusion Apparatus: *A*, plunger; *B*, bulb; *C*, stopcock; *D*, flexible probe-pointed canula; *E*, *E*, valves.

to infection from the pedicle, or perhaps even from the intestine.[1] The more bacteriology progresses, the more difficult it seems to guard against infection.

Thrombosis beginning in the pelvic veins may extend to those of the thigh, and from the thrombus a piece may be detached and form an embolus.

Intestinal Obstruction may be brought about by exudation and adhesions. The means to avoid it are in supravaginal hysterectomy to lift the intestines up before dropping the pedicle, to avoid as far as possible leaving raw surfaces in the abdominal cavity, and to move the bowels early. (See Ovariotomy.) If obstruction sets in, it should be combated with large injections of lukewarm water from a fountain syringe. The enema with ox-gall, described p. 169, may also be tried. If the obstruction remains, the abdomen must be reopened and the obstacle removed manually.

Tetanus is an exceedingly rare complication, and its treatment is probably hopeless. An attempt should, however, be made with bromide of potassium, chloral hydrate, and curare.

Indications for Operative Interference.—Polypi should always be removed, at least when they become easily accessible. Subperitoneal fibroids with a thin pedicle should be removed, if they annoy the patient or grow much. Fibro-cystic and suppurating tumors must be removed. In all other cases Apostoli's treatment should be employed, and operations only resorted to in those in which it fails or when it cannot be obtained.

In regard to fibro-cysts, it may be safer to desist from a total extirpation, and only to make a large incision, evacuate the fluid, stitch the

[1] Welch, "Wound Infection," *Amer. Jour. Med. Sci.*, Nov., 1891, p. 443.

sac to the abdominal wound, and pack it with iodoform gauze. It will then shrink, and be filled by granulation.

C. *Sarcoma.*

Under the vague name of *cancer* are united neoplasms of different anatomical structure, having this in common, that they undermine the constitution and sooner or later, in most cases rapidly, lead to death.

To this group belong *sarcoma*, *carcinoma*, *malignant adenoma*,—the last being only the first stage of some cases of carcinoma,—and certain *papillomas*.

Sarcoma.—Pathological Anatomy.—Sarcoma preferably affects the body of the uterus. In the neck it is very rare. It appears in three forms—the *circumscribed*, the *diffuse*, and the *papillary* sarcoma. The circumscribed forms globular tumors like fibroids, and used to be called *recurrent fibroid*, because it developed again after extirpation, which a genuine fibroid never does. Like a fibroid, it may be submucous, intramural, or subperitoneal, and it may form a polypus. It has very rarely a capsule. Its consistency is generally soft and brain-like, but it may be as dense as a fibroid. It may start from the mucous membrane, the muscular tissue, or the peritoneum. Often it has its origin in a myoma.

The diffuse sarcoma starts, as a rule, from the submucous connective tissue, invades the mucous membrane, and may spread more or less deeply into the muscular tissue of the uterus or perforate the whole wall, so as to form a tumor in the abdominal cavity. It is composed of a whitish or grayish extremely vascular mass.

Most sarcomas have a fasciculated arrangement, bands of fibrous connective tissue separating groups of cells—a disposition which may even be seen macroscopically by breaking hardened specimens. The less fibrous tissue they contain, and the more the cells predominate, the more malignant they are. In younger portions of the growth a jelly-like amorphous mass is found between the fibrillæ which later disappears. The cells may be spindle-shaped or round. Sometimes also so-called giant-cells with many nuclei are interspersed among the others. The sarcomatous tissue is full of enormously dilated capillaries with very thin walls, which explains the hemorrhages that form so prominent a feature among the symptoms.

The diffuse sarcoma, as a rule, contains epithelial cells, so that a transition is made to carcinoma.

In *myxo-sarcoma*, also called *colloid cancer*, there is a preponderance of the intercellular amorphous substance containing mucin, to which is due its gelatinous consistency.

Papillary Sarcoma starts from the vaginal portion of the uterus.

It arises from an hypertrophy of the papillæ of the mucous membrane, consists of fusiform or round cells, and has a hydropic intercellular substance.

Sarcomas may spread to the neighboring organs—the vagina, the bladder, and the abdominal cavity. They may also give rise to metastatic deposits at distant places, such as the vagina, lymphatic glands, the connective tissue of the pelvis, the peritoneum, the liver, the lungs, the pleura, the vertebræ, and the skin.

A sarcoma may become cystic, and is then called *cysto-sarcoma*.[1]

Etiology.—The cause of sarcoma is unknown. It is most common at the climacteric age, between forty and fifty years, but differs from carcinoma by being found in persons under twenty years of age, so that it may be called the cancer of youth. It may even be congenital. It differs likewise from carcinoma in this respect, that among those affected with it many are sterile, while carcinoma is rarely found in women who have never borne children. It sometimes follows endometritis or develops in a fibroid.

Symptoms.—In the beginning the symptoms hardly differ from those of fibroid tumors—namely, menorrhagia, metrorrhagia, leucorrhea, hydrorrhea, and pain. The uterus may be enlarged and nodular, and may become inverted. But the growth is a rapid one. There is soon established a continuous sero-sanguinolent discharge with offensive smell. The patient becomes emaciated, exsanguinated, and weak, and has an ashy color—a complex of symptoms called cachexia. The cervix often becomes dilated. Pieces of a soft brain-like mass may be expelled from the interior of the womb. The pain may be due to pressure or to the nature of the disease. Sometimes it is expulsive in character. The finger introduced after dilatation of the cervix feels the soft mass in the wall of the uterus.

Diagnosis.—The diagnosis of sarcoma is by no means always an easy matter. An intramural sarcoma offers the same symptoms as a *fibroid* similarly situated. The sarcomatous degeneration of the mucous membrane is somewhat more characteristic by the rapid disintegration that takes place and the speedy development of cachexia. The appearance of a tumor like a fibroid at the time of the menopause, and its growth after the same, and hemorrhage recurring after the menopause, must awaken a suspicion of its sarcomatous nature. A sero-sanguinolent discharge, the softness of the tumor,—which often allows the finger to penetrate it or break pieces off from it,—a more agonizing pain, and the rapid emaciation and cachexia, are all characteristic of sarcoma. In regard to softness, we must, however, remember that it is likewise found in a gangrenous fibroid.

[1] I have described and represented in the *New York Medical Journal*, August, 1882, such a case in which the mucous membrane of the uterus was intact, but a large tumor composed of cysts and solid masses had been developed in the abdomen.

From *hyperplastic endometritis* it is differentiated by greater tenderness of the body, by the often open cervical canal, by sometimes forming a polypus that hangs out through the cervix, by the appearance of cachexia, and by the spontaneous expulsion of torn-off pieces of the tumor, which never takes place in endometritis. Particles obtained by curetting, on the other hand, are deceptive: a sarcoma may furnish a specimen exclusively composed of healthy mucous membrane, while in endometritis the curette may bring away granulation tissue that looks entirely like small round-cell sarcoma. The clinical diagnosis is, therefore, more reliable, than the microscopical, but one may corroborate the other, and sometimes the presence of large cells separated by intercellular basis substance is conclusive.

As long as the epithelial cells of the utricular glands—either original or of new formation—are unchanged, the diagnosis of chronic endometritis is admissible, whatever the nature of the interstitial tissue be. As soon, on the contrary, as the regular arrangement of the epithelial cells is broken up, and they give way to sarcomatous tissue, the diagnosis of sarcoma can be made.[1]

When a whole tumor is removed, its nature may be settled by the microscope; and if it is reproduced in the same place or forms metastases, its sarcomatous nature is proved.

In this connection it must, however, be remembered that endometritis may produce new fungoid growths after curetting, and that another myoma may develop in another place after one has been removed.

The differentiation from *carcinoma* of the body may be impossible, and, as we have seen above, the two are frequently mixed in the diffuse form. The discharge in sarcoma is less fetid; ulceration does not appear so soon; extension to the neighborhood is slower, and sarcoma may form a polypus emerging from the os, which carcinoma never does.

Prognosis.—The prognosis is bad. The disease ends in death, on an average, in about three years, sometimes as rapidly as four months, and very exceptionally as late as ten years.

Treatment.—On account of the immense danger to health and life, the best treatment, when once the diagnosis is certain, is to perform the *total extirpation* of the uterus, either by the abdominal method (pp. 466–470) or by the vaginal method, which latter will be described under Carcinoma. Since the development of sarcoma is slower and does not implicate the surrounding parts so soon as carcinoma, the operation is oftener indicated than in the latter disease, and the prognosis as to complete recovery is considerably better.

When the cervix is healthy, the operation may be limited to *supravaginal amputation* (pp. 470–478).

[1] L. Heitzmann, *l. c.*, p. 906.

A polypoid sarcoma may be cut off and the base cauterized. If a radical operation is impossible, a palliative treatment, similar to that for carcinoma, especially curetting followed by cauterization with the thermo- or galvano-cautery or nitric acid, and the application of diluted liquor ferri chloridi (1 to 10 parts of water), should be instituted.

In handling sarcomas great care should be taken to avoid mechanical infection of yet healthy parts.

Decidual Sarcoma.—Of late several cases have been described of sarcoma of the uterus which appeared shortly after abortion or childbirth. The tumors were composed of large decidual cells imbedded in a meshwork of connective tissue, forming pseudo-alveoli and containing nuclei and giant-cells. The affection caused increase in size of the uterus, hemorrhage, putrid discharge, metastatic deposits in the iliac fossæ, the lungs, and other organs; and ended in death in the course of from six to seven months.

If the diagnosis is made early enough, complete ablation of the uterus is the only rational treatment, and has been performed successfully.

D. *Carcinoma.*

Carcinoma (Fig. 260) is a neoplasm composed of epithelial cells often grouped in alveoli formed of connective tissue, with a tendency to invade neighboring organs and undermine the constitution.

Pathological Anatomy.—Carcinoma is most common in the vaginal portion of the uterus. Next in frequency is that of the cervix, while that of the body is comparatively rare. Upon the whole, the uterus is very frequently affected in this way, perhaps oftener than any other organ, the only question being if carcinoma of the breast occurs as often or oftener.

Carcinoma of the Vaginal Portion begins in that part which is covered with flat vaginal epithelium. It does not, however, start directly from the epithelium, but from new-formed glands, and may dip deep into the muscular tissue of the cervix without attacking the cervical mucous membrane or the outer circumference. It may also form a papillary growth which develops in the direction of the vagina, and may become so large as to fill it down to the vaginal entrance. From its shape this form has derived the name of *cauliflower excrescence.* A third form is that of a flat ulceration, which has been described under the name of *rodent ulcer.*

Cervical carcinoma begins as nodules in or under the mucous membrane of the cervical canal, which coalesce and form an ulcer on the mucous membrane, whence it may spread outward, forming a deep cavity in the cervix without showing at the os or invading the corpus.

The carcinomatous degeneration may begin in the glands of the mucous membrane or in the connective tissue.

Carcinoma of the Body may be *primary* or *secondary*. The *primary* starts from the epithelium of the surface or from the glands. It

FIG. 260.

Cervical Carcinoma of Uterus extending into Body:[1] *a*, body of uterus; *b*, cervix; *c*, tube; *d*, ovary; *e*, hydatid; *f*, piece of wood inserted in order to expose the cavity of the uterus.

appears in a *diffuse* and a *circumscribed* form, the latter forming a tumor, which may become pedunculated so as to form a polypus. Often the mucous membrane of the body is affected at an early date in cases of carcinoma of the cervix.

In regard to differences in structure, several varieties of uterine carcinoma are distinguished: 1, *epithelioma*, where flat or cuboidal epithelial cells are arranged concentrically, so as to form so-called cancer *nests* or *pearls*—a form probably only occurring in the cervix; 2, *adenoid carcinoma*, composed of columnar epithelial cells, and characterized by the presence of tubular formations, with manifold convolutions, arranged in groups or alveoli or exhibiting a plexiform arrangement, the epithelial cells often breaking up into medullary corpuscles; 3, *medullary carcinoma*, where the cellular element pre-

[1] Specimen from my vaginal hysterectomy on Mrs. C. C. ——, St. Mark's Hospital, March 25, 1891.

dominates, forming a soft mass; and 4, *scirrhous* or *fibrous carcinoma*, in which there are larger trabeculæ of fibrous connective tissue, imparting greater hardness to the growth. Of these varieties the medullary is the one that grows fastest and soonest leads to a fatal issue.

Carcinoma of the uterus extends to neighboring parts, especially the vagina, the bladder, the pelvic connective tissue, the tubes and ovaries, the peritoneum, the rectum, and very rarely the bones of the pelvis. When ulceration takes place, a vesico-uterine fistula may be formed, or, more rarely, a recto-vaginal fistula. The internal iliac, lumbar, or inguinal glands become infiltrated according to the part of the uterus that is affected (p. 62). Of the above-named varieties, the epithelioma is least apt to spread to the glands. If the bones are affected, the growth may enter the hip-joint and dislocate the femur. The tumor may also compress the ureters and cause hydronephrosis.

Compression of an artery may be followed by the formation of an arterial thrombus, but thrombi are much more commonly found in the veins of the pelvis and the thighs. They may be due to direct pressure or be caused by the general marasmus and weak heart-action.

Secondary carcinoma of the body may attack the uterus by extension of a primary carcinoma from the bladder, the rectum, the ovary, or the peritoneum of Douglas's pouch.

Metastases from uterine carcinoma are rare, but have been found in the liver, the stomach, the lungs, pleuræ, kidneys, the peritoneum, the brain, and other parts.

Etiology.—Carcinoma of the uterus is a disease of advanced age. It is very rarely found below the age of twenty, in which respect it differs from a sarcoma. It is most common during the first five years following the menopause. It is much more frequent in the lower classes than in the higher walks of society, probably because poor women, as a rule, have more frequent childbirths, because they are much less cleanly, and because worry and want favor the malignant degeneration.

It is to some extent hereditary, and is frequently found in families other members of which are tuberculous. Perhaps also syphilis in ancestors, by giving rise to a deteriorated constitution, may predispose to it.

Carcinoma of the neck is usually found in women who have borne a large number of children or had difficult labors. Lacerations of the cervix (p. 283), with the concomitant eversion, glandular development, and erosions, are apt to become the starting-point of it. Carcinoma of the body, on the other hand, is comparatively common in nulliparous women. Benign tumors may in the course of time become carcinomatous.

It has been very generally repeated that while the negro race was much more liable to fibroma of the uterus than white people, it was free from carcinoma. The first is denied by a competent judge, and the latter disproved by the public statistics for fourteen consecutive years of the city of Charleston, S. C., which shows that there is hardly any difference between the two races.[1]

Symptoms.—The first symptom that brings the patient to seek advice is loss of blood. Often it is only a slight bleeding following coition. In other cases it is a return of bloody discharge after the menopause. In others, again, the menstrual flow becomes too abundant or protracted, or there is loss of blood in the intermenstrual period.

Another early symptom is a common leucorrheal discharge streaked with blood. Sometimes a shooting pain or a dull ache occurs at intervals in the sacral or hypogastric region, or the patient may have sciatica.

If the carcinoma is developing in the collum, we will in most cases find a laceration with eversion. The mucous membrane is swollen, bleeds easily, and contains hard nodules. The cervix is indurated in its totality, and not only at the angle of the tear, where a cicatricial plug (p. 384) is so common an occurrence. At the same time, the tissue is friable, so that a part may be scraped off with the nail. Sometimes the uterus is tender on pressure.

In carcinoma of the body there are no other early symptoms than hemorrhage and leucorrhea.

As the disease progresses these symptoms may become more marked and new ones are added. The hemorrhage often becomes profuse. After ulceration has taken place there is at times a profuse watery discharge with a penetrating, most disagreeable odor, and in the interval a fetid muco-purulent discharge. The pain becomes more constant and intense. In carcinoma of the body paroxysms of expulsive pain are caused by detached pieces of the neoplasm which cannot pass out through the closed cervix. Finally, the whole body aches. In other cases the pain may be due to peritonitis or to the direct affection of the nerves in the uterus. The acrid discharge is apt to cause pruritus vulvæ and excoriations of the skin on the inside of the thighs.

In some cases different forms of dysuria are present. Cystitis, causing frequent and painful micturition, is common. If one of the ureters is compressed or invaded by the new growth, hydronephrosis is developed on the corresponding side. The amount of urine that is excreted is diminished. The patient complains of pain in the lumbar region, nausea, and headache. If both ureters become obstructed, complete anuria sets in, followed by uremic convulsions and death. In other cases the uremic symptoms become less toward

[1] Middleton Michel, *Med. News*, Oct. 8, 1892.

the end, the obstruction being removed by the extension of the ulceration.

In regard to the alimentary canal, the patient frequently complains of a bad taste, thirst, loss of appetite, eructations, nausea, vomiting, and constipation. The hemorrhoidal veins surrounding the anus often swell. She loses flesh and strength, and her skin has a peculiar ashy yellowish hue.

If venous thrombi form in the pelvis and thigh, the corresponding extremity becomes swollen and unwieldy.

Sometimes the abdomen is swollen, some ascitic fluid may collect, and the cutaneous veins in the abdominal wall become distended. Peritonitis is of frequent occurrence. Inflammation of the lungs, pleuræ, and kidneys is less frequent. Sometimes dysentery sets in. A detached embolus may be driven into the pulmonary artery and put a sudden stop to the sufferings of the patient. Septicemia is rare, the inflammatory exudations serving as a barrier against the entrance of the products of decay into the circulation. The glands in the groins and in the depth of the pelvis are felt to be enlarged.

By vaginal examination we find the uterus to be immovable. The vaginal vault is as hard as a board. From the cervix we may find hanging a soft polypoid tumor, which may fill the whole vagina. It is friable and bleeds easily. Or the finger enters a crater-shaped ulceration surrounded by hard walls. Often the infiltration with carcinomatous tissue can be felt as hard nodules in the broad ligaments or as a hard string following the course of the uterine vessels out to the pelvic wall.

Although cancer undoubtedly is transmissible from one part of the body to another with the current of the vital juices, there is no evidence that it can be inoculated into another individual, and the great rarity of carcinoma of the penis compared with the very common occurrence of the disease in the cervix uteri goes far to show that the disease is not transmissible by coition.

Diagnosis.—A *sponge* left in the vagina and forgotten has given rise to such hemorrhage and offensive discharge that it has been taken for a cancerous growth. An examination with the finger and the eye and the removal of the foreign body will soon settle that error.

The distinction from *erosions* may be difficult. A papillary ulcer surrounded by follicles is likely to be benign. On the other hand, we find in carcinoma of the cervix a sharp line of demarkation between the sick and the healthy tissue: the former is elevated, has a yellowish tint, and contains glistening yellowish-white nodules. The carcinomatous tissue is more friable than the healthy or simply inflamed, so that a piece may be broken off with the nail of the examining finger. The result of treatment as a diagnostic measure is valuable: erosions heal in a short time if they are treated with sulphate of

copper or some other astringent (p. 401), whereas carcinoma spreads in spite of the treatment. Microscopical examination may be entirely negative, but in many cases it gives positive information in regard to the malignancy of the tissue. For this purpose a wedge-shaped piece must be cut out of the cervix, choosing the most affected spot and going deep enough to include in the excision part of the muscular tissue. The wound is united by a suture. The operation is so little painful that general anesthesia is superfluous. A strong solution of cocaine may, however, be applied to advantage. The excised part should be hardened, cut, and stained. The diagnosis of carcinoma is only warranted if atypical epithelial pegs dip into the muscular tissue.

A carcinomatous ulceration must be, and in most cases is easily, distinguished from the other kinds of ulcers found on the cervix (p. 410).

Chancroid is an acute affection characterized by sharp edges, a yellow bottom, a red halo, and an abundant secretion of pus of a different odor. *Chancre* may give rise to doubt, but the history, the presence of other syphilitic symptoms, the result of an antisyphilitic treatment, and microscopical examination furnish abundant means of dispelling it.

Tuberculous ulcers are surrounded by tuberculous nodules; are, as a rule, combined with tuberculosis of other parts, especially the lungs; and show the characteristic bacillus.

The simple *friction ulcer* found where the cervix protrudes in front of the vulva is surrounded by bluish tissue, and heals easily under proper care. The glands are not affected.

Corroding ulcer[1] has not so hard surroundings, and can be diagnosticated by means of the microscope, which shows absence of epithelial proliferation.

Papillary hypertrophy may give rise to small benign growths, but they have a narrow base; when seated on a broad base a papillary growth is carcinomatous.

Carcinoma of the body has to be differentiated from hyperplastic endometritis, fibroma, and products of conception. In regard to *hyperplastic endometritis* the reader is referred to what has been said above (p. 398). Here we will only add a few words about the microscopical examination. The diagnosis of scrapings removed by the curette as being carcinomatous is only warranted if we meet with encephaloid masses which show, not a glandular structure, but atypic epithelial pegs. Fungous endometritis is characterized by the presence of a

[1] *Corroding ulcer* is the term used by Dr. Williams for the one he ascribes to senile gangrene caused by calcification of the internal iliac arteries, while *rodent ulcer* is the old classical name that may yet be retained for very flat ulcerations of the vaginal portion, which extend very slowly to the sides, and very late dip into the depth of the cervix, but are microscopically proved to be carcinomatous.

varying number of tubular glands, the epithelium of which is unbroken. The interglandular tissue may be crowded with lymph-corpuscles, or it may be myxomatous or fibrous in character.[1]

A *fibroid* follows a benign course. It develops very slowly, no particles are expelled, there is no bad odor, the uterus is freely movable, the patient has no fever, and her constitution does not suffer except from loss of blood. She may be pale, but she has not the yellowish color of carcinoma. It is true, a fibroid may slough, and then there may be high temperature and fetid discharge, but this is a condition that comes on suddenly, and ends in a short time in death or recovery.

Pieces of *secundines* may be retained in the uterus for years and cause considerable hemorrhage, pain, and leucorrhea. When they are removed with the curette the microscope clears the diagnosis, and the patient recovers.

The diagnosis from *sarcoma* can only be made by a microscopical examination of expelled, scraped-off, or excised parts. It is in so far of importance as the prospects for success in a radical operation are greater in sarcoma than in carcinoma.

If the early recognition of carcinoma may be difficult, in its advanced stage the disease presents so uniform a picture that it is easily recognized, the most striking features being the hemorrhage, the offensive watery discharge, the immobility of the uterus, the implication of neighboring organs, the crater-like ulcer, the large, friable, soft mass springing from it, the pains, and the cachectic condition.

The ascitic fluid accompanying carcinoma of the body and obtained by aspiration contains sometimes large round or pear-shaped endothelial cells with large nuclei, either isolated or in groups. This sign is of some positive value, but not of negative—*i. e.* if these malignant cells and cell-groups are found, it is very likely that the disease is malignant (carcinoma, sarcoma, or papilloma), but their absence does not prove anything.[2]

Prognosis.—The disease is fatal. Even the most radical treatment effects only quite exceptionally a permanent cure, and it is even doubtful if, upon the whole, it prolongs life. Under palliative treatment patients affected with carcinoma of the cervix may live three or four years. When the disease is in the corpus they live rarely more than one or two.

Treatment.—Prophylaxis.—Cervix lacerations, if they give rise to eversion and consequent irritation of the mucous membrane, should be operated on (p. 386), and endometritis treated as stated above (pp. 400–401).

Palliative Treatment.—By far the greater number of patients do

[1] Louis Heitzmann, *Amer. Jour. Obst.*, September, 1887, p. 919.
[2] For details see Garrigues's *Diagnosis of Ovarian Cyst*, pp. 94–97.

not come under observation before the disease has spread so much that a radical treatment, aiming at the complete removal of the affected part, cannot be instituted with any hope of benefiting the patient. But very much may be done to relieve her, prolong her life, and make her a less objectionable companion for others. The chief indications are to relieve pain, combat hemorrhage and bad odor, and keep up the patient's strength.

The disease being fatal, and having only a duration of a few years, we need not be afraid of making opium-eaters of our patients (p. 218). There are no other drugs that will relieve the pain of cancer as opiates do, and the patient should simply have as much of them as is needed to make her comfortable. In cancer of the cervix small doses will suffice for a long time, and need only be increased very gradually. In the beginning four drops of Magendie's solution, two or three times a day, are enough, and I have not found it necessary to go beyond ten or twelve drops three or four times a day in the later stages. The hypodermic injection is most efficacious, but for obvious reasons most patients take their morphine by the mouth. In cancer of the body larger doses are required to dull the pain.

Moderate hemorrhage may be kept in check by means of injections with chloride of iron (p. 168). In more profuse hemorrhage, or if the seat is in the body, curetting (p. 171) is of great value. In removing large sprouting masses from the cervix I have found Thomas's spoon-saw (p. 462) a very useful instrument. The patient is placed in the dorsal or left-side position, a Sims speculum is introduced, the tumor is seized with a volsella, and as much of the friable tissue as possible is removed with the spoon-saw, followed by Simon's sharp spoon. Jagged edges may be cut off with curved scissors. Most operators use the thermo- or galvano-cautery as supplemental to curetting in order to arrest hemorrhage and destroy infiltrated tissue. Others object to the cautery, because it destroys tissue that is not yet affected, and thus hastens the process of destruction. Whether the cautery be used or not, the cervix is packed with pledgets wrung out of a solution of chloride of iron (p. 175), and the vagina with an antiseptic plug (p. 174).

After having removed this tampon the next day, some apply pledgets wrung out of a solution of chloride of zinc (ʒv to distilled water ℥j, or, if there is a wall more than a quarter of an inch thick around the cancerous tissue, even equal parts). The vagina is protected by a tampon of cotton balls wrung out of a solution of bicarbonate of soda (1 part to 2 of water), which is left in for two or three days. If the zinc pledgets do not come off easily, they are left for a day or two longer. This treatment produces a thick slough, leaving a velvety surface, and is followed by considerable contraction. It may

even effect a permanent cure, but is not quite safe, since the action of the caustic may involve healthy tissue or the cancerous degeneration go deeper than anticipated.

Some substitute excision with knife and scissors for curetting as the first step in the chloride-of-zinc treatment, cutting out a cone from the vaginal junction to the internal os. During the separation of the slough and cicatrization disinfectant injections are used.

Nobody should undertake curetting for a large cancerous mass without being prepared to ligate the uterine artery from the vagina (p. 171), or even to extirpate the uterus if necessary.[1]

It is also recommended to scrape off all diseased tissue and dress the wound with a saturated solution of soda.

Hemostatic drugs are not of much avail. Gossypium (p. 219), however, is useful as an adjuvant.

Injections with creolin (p. 169) are very valuable, both as a hemostatic and an antiseptic. The odor of the drug itself is by no means disagreeable. Still more astringent is liqu. ferr. chloridi (p. 175). Permanganate of potassium (enough to give the water a dark purple color) has no odor at all, but stains the linen. Peroxide of hydrogen has neither odor nor color, and has a high disinfecting power. Small tampons dipped in terebene and olive oil, equal parts, may be left in place for two or three days. Equal parts of iodoform and charcoal applied as a powder on the ulcer relieves pain, cleanses the ulcer, and combats the odor, but has a smell of its own that to many persons is objectionable. All these benefits may also be derived from the daily application of the odorless aristol. Suppositories with chloral and tannin (āā gr. xv–ʒss) combat hemorrhage, pain, and odor.

Occasionally the use of a styptic tampon (p. 175) may become necessary.

For carcinoma of the body Vulliet's dilatation (p. 154), followed by curetting and chloride of zinc, may be used. Simple curetting, although less exact and powerful, is also very useful; repeated every three to six months, it prolongs life considerably.

In using tonics the reader should remember the warning (p. 220) against giving iron when there is any hemorrhage.

So far, no drug has been found that will cure cancer, although from time to time some new specific is praised even by good observers. Some years ago it was condurango-bark; then came Chian turpentine; next methyl blue enjoyed a short-lived celebrity. I have not seen any effect from the use of these substances; but since others have

[1] I did so in a case in which I had refused to perform the radical operation on account of infiltration of the broad ligament on one side. The curetting entailed a large opening in Douglas's pouch. I then performed vaginal hysterectomy. The patient made an excellent primary recovery, but the cancer, of course, continued developing.

claimed success, and since we must sometimes prescribe something, I add the following formulæ:

℞. Extr. condurango, fl. ℥ss;
Aqu., ad ℥viij.—M.
Sig. A tablespoonful four times a day.

℞. Extr. condurango, ℥ss;
Vaselini, ℥iss.—M.
Sig. To be applied daily on tampons to the ulcerated surface.

℞. Terebinthinæ Chiensis, ℥ss;
Sulphuris sublimati, ʒiiss;
Rad. glycyrrhizæ, q. s.
Ft. pil. No. c.
Sig. Three pills every four hours.

To those who cannot swallow pills it may be given as an emulsion with mucilage, a yolk of an egg, syrup, and sherry wine.

Methyl blue is given in doses of 3 to 4 grains, once or twice a day, in capsules, by the mouth, or by the rectum. It is also injected into the tumor (♏xx to ʒj of a solution of 1 part to 300 parts of water), or the ulcer is covered with it in substance. As it stains everything, it is a disagreeable stuff to handle and to take.

Radical Treatment.—Although some of the heretofore-mentioned methods have been claimed to have effected a complete and permanent cure of cancer, we restrict the term "radical" to methods in which a cure is sought by surgical operations in the healthy tissue surrounding the diseased part. In this connection we have to consider the thermal galvanocauterization, the high amputation of the cervix, Baker's operation, and vaginal, sacral, perineal, and abdominal hysterectomy.

Thermal galvanocauterization seems to have given better results, both in regard to mortality and length of time before relapse occurred, than any other known method. It is performed with the snare, the knife, and the dome-shaped burner (p. 227). At least the whole cervix should be removed.

The need of a costly instrumentarium and its liability to get out of order have undoubtedly prevented this method from becoming more popular.[1]

The high cervix amputation (Schroeder's method) has been described on p. 415. It is not an easy operation, exposes to the danger of considerable hemorrhage, and is less rational than the total extirpation

[1] Statistics of a large personal experience have been published by Pawlik of Vienna and John Byrne of Brooklyn, N. Y., *Gynecol. Trans.*, 1889, vol. xiv. p. 90. Dr. Byrne's battery and instruments may be obtained from Messrs. Kerston & Kayson of Brooklyn.

of the uterus, since we have seen that cervical carcinoma often is combined with a beginning of the same disease in the body of the womb.

The whole cervix has also been cut out with the thermocautery, by which means hemorrhage is avoided, but neighboring organs may be implicated.

Baker's Operation consists in first removing the cervix, as in Schroeder's operation, then cutting a cone-shaped piece out of the body up to the fundus, and finally searing the whole surface with Paquelin's cautery. In this way most of the uterus can be removed without opening the peritoneum. Baker operates in Sims's position. He uses sutures of twisted silver wire to arrest hemorrhages, which has the double advantage that the ligatures may be tightened when in the progress of the operation they become loose, and that we do not risk cutting them with the cautery. This is a very thorough method, and has so far given excellent results, both immediately and remotely, but it is hardly feasible to calculate the thickness of the cancerous tissue and the depth to which the cautery extends its destruction, and hysterectomy is, therefore, to be preferred.[1]

Coe[2] recommends the excision of the cervix in cases of extensive erosion with general induration, whether cancer has actually developed or not. He cuts out a cone, the apex of which may be as high as the os internum, the mucous membrane of the entire canal being removed with the cone, but leaves the vaginal mucous membrane. He then introduces a plug of glass or iodoform gauze, and closes the cervix with deep silver-wire sutures.

Vaginal hysterectomy is a German operation that has met with much opposition in this country.[3]

The very bad results are, however, probably due, in a great measure, to the fact that it has been undertaken when the disease had progressed too far. It is counterindicated if the carcinoma is not strictly confined to the uterus proper. The uterus should be freely movable, and an examination under anesthesia should not reveal any infiltration of the broad ligaments or of the pelvic glands. But even with these restrictions relapses, as a rule, come sooner or later, the probable explanation being that there is at the time of the operation already a microscopical invasion of the surrounding parts which cannot be felt. A. Martin has, however, tried to prove by statistics that the permanent—or rather final—results are as good after extirpation of the cancerous uterus as in operation for cancer in any other part of the body.

[1] W. H. Baker, *Gynecol. Trans.*, 1891, vol. xvi. p. 170.
[2] H. C. Coe, *Med. News*, Feb. 16, 1889.
[3] J. Byrne, *l. c.*; Baker, *l. c.*; Reamy, *Gyn. Trans.*, 1888, vol. xiii. p. 183; Jackson, *Med. News*, Jan. 18, 1890; Coe, *Amer. Jour. Obst.*, June, 1890, vol. xxiii. p. 587.

Modus Operandi.—There are many modifications of this operation. I shall limit myself to describing the two I have used myself—the clamp method and the ligature method.

The patient lies on her back, the legs held up with Robb's leg-holder. If possible, four assistants should be secured. A large Sims speculum, or preferably Schroeder's modification with a short, broad blade, depresses the posterior wall of the vulva and vagina. The lateral walls are at times held aside with large retractors, those especially constructed for the purpose by Schroeder (Fig. 169, p. 205) being the most useful. Bernay's utero-tractor (Fig. 261) is introduced closed

FIG. 261.



Bernay's Utero-tractor.

into the cavity of the body of the uterus, opened, and traction made with it, in order to make the hooks penetrate the flesh. Then the uterus is again replaced *in situ*, and a circular incision made at the vaginal junction, just outside of the cervix, through the mucous membrane, the lowest point of the bladder being marked with a catheter held by an assistant. Next, the uterus is again pulled as low down as possible. Small cuts are made with a pair of blunt curved scissors, the concavity of which is turned against the uterus and kept close to it. As soon as feasible the closed scissors are used alternately with one or both forefingers to separate the bladder from the uterus up to the peritoneum, which is left intact. Next, the same is done behind the cervix, and when the peritoneum is reached, it is torn with the closed scissors, and the opening dilated from side to side with the two forefingers. A sponge with a double thread attached is introduced into Douglas's pouch. After that the peritoneum in front is opened in the same way. Next, the base of the left broad ligament is severed with small cautious cuts until it becomes thin enough to be easily compressed by a long and strong pressure-forceps, which is placed over the lower half of the broad ligament, including the uterine artery. Then the ligament is cut inside of this forceps to a point near the end of the latter. A second forceps is placed over the upper half of the ligament with the ovarian artery, and the ligament is cut off from the uterus. The application of the forceps is very much facilitated by throwing a strong silk ligature over it with *Hunter's needle*,

which is constructed like Bellocque's tube for plugging the posterior nares. If possible, the tube and ovary should be drawn inside of the upper forceps, or they may be tied separately with silk and removed.

When the left side is free the same procedure is gone through on the other side.

It may be necessary to use more than these four pairs of forceps. Some surgeons use only one, especially made for the purpose, on each ligament.

The vagina is packed loosely around and between the instruments with creolin gauze, and the handles are surrounded with a mass of cotton, and so supported that they cannot drag on the stumps or press against the vulva. Great care should be taken in this respect, as there easily forms quite a considerable slough. Small forceps may be removed after twenty-four hours; the large should be left from thirty-six to forty-eight hours, as hemorrhage has occurred at the end of twenty-four hours. After the removal the vagina is packed lightly with gauze to be changed every day. After the first four days a vaginal injection is given at the time of dressing. The patient may sit up in bed at the end of the second week, and get out of bed at the end of the third week.

The other method secures the ligaments by means of a row of strong silk ligatures. These are put in with a pair of strong aneurism-needles bent to the side (Fig. 258, p. 476) or with Polk's hinged needle (Fig. 247 p. 467). After each ligature the ligament is cut inside of it, whereby the uterus becomes more movable and space is obtained for the next ligature, which is placed above the first, and so on until the whole ligament is severed. The uterus now being free, it is much easier to place a similar row on the right side.

The ligatures are left long, and are pulled out when they become loose.

The use of forceps is more expeditious, which in weak patients may be of great importance, but the ligature is safer. Forceps can hardly be used unless the vagina is spacious.[1]

Some prefer to stitch the peritoneum to the vagina, draw the stumps of the broad ligaments down into it, fasten them there, and then close the opening remaining in the vagina.[2]

The *pregnant cancerous uterus* has repeatedly been successfully re-

[1] I do not know if it is more than an accident that I lost a patient by tetanus, who had been doing excellently until the ninth day after the extirpation by the clamp method. Still, it has been surmised that similar occurrences after ovariotomy and the extraperitoneal treatment of the pedicle after abdominal hysterectomy for fibroids stood in some relation to the use of clamps and pins. The forceps has also caused the formation of a fecal fistula.

[2] Such a procedure is described in detail by H. J. Boldt in *Trans. Amer. Gyn. Soc.*, 1892, vol. xvii. p. 177.

moved in the second and third month by vaginal hysterectomy, which is particularly indicated under these circumstances.

An accident that is not very rare in separating the bladder from the uterus is the formation of a *vesicovaginal fistula.* If such a thing happens, the opening in the bladder should be closed at the end of the operation, and all precautions taken to insure healing (pp. 357–359). If the attempt fails, and spontaneous closure does not occur, and there is no relapse, the fistula should be closed later.

In order to gain room for the extirpation of the uterus, the *perineum and the whole rectovaginal septum has been cut through* in the median line, and healing by first intention has been obtained by means of silkworm sutures.

Sacral Hysterectomy.—1. *Kraske's Method.*—Kraske's operation for cancer of the rectum has been adapted to the removal of the cancerous uterus. The patient is placed in Sims's position. A curved incision is made from the iliosacral synchondrosis on the right side to the tip of the coccyx. Then the gluteus maximus muscle and the great and lesser sacrosciatic ligaments are detached from the sacrum. The coccyx is freed all around, and removed, together with the lower end of the sacrum, by sawing the latter bone through from between the third and fourth posterior sacral foramina on the right side to the left cornu. The rectum is loosened and pushed over to the left side. The peritoneum is incised close to the margin of the rectum, exposing the posterior surface of the uterus. The ligaments may now be tied and severed, and the uterus separated from the bladder.

This operation is recommended in cases in which the uterus is large and the body of the organ fills up the pelvis, or in which the ovaries and tubes are the seat of prior disease and are adherent.[1] The mortality is very great, and the wound heals very slowly, and is apt to leave fistulæ.

2. *Hegar's Method.*—Hegar makes on the posterior surface of the sacrum a V-shaped incision with the base turned upward, cuts muscles and ligaments on the edges of the bone, detaches the rectum, and cuts the sacrum with a chain-saw between the third and fourth sacral foramina in a slanting line, preserving the periosteum on the posterior side. The end of the sacrum is not detached, but only thrown upward, and later replaced.

In regard to the whole procedure of sacral hysterectomy it may be said that a cancerous uterus that cannot be removed by the vagina is not fit for extirpation.

Perineal Hysterectomy (*Zuckerkandl's Method*) opens the way to the uterus by a transverse perineal incision from one tuberosity of the ischium to the other, and by separating the vagina from the rectum.

[1] Details may be found in a paper by E. E. Montgomery of Philadelphia in *The Trans. of the Amer. Assoc. of Obstetricians and Gynecylogists,* 1891.

Abdominal Hysterectomy (*Freund's Method*) for carcinoma has been attended with such extreme mortality that the operation is now universally abandoned, and is only used as a necessary addition to vaginal hysterectomy (*laparovaginal hysterectomy*) when difficulties are encountered which cannot be overcome in any other way. Still, by the easy access it gives to all the pelvic organs it is preferable to the sacral and the perineal methods.

E. *Papilloma.*

Under the name of papilloma many different tumors have been described which have in common a dendritic, digitate, or villous shape. Most of them are simply a form of *carcinoma* of the cervical portion—Clarke's cauliflower excrescence (see p. 486). Others are *fibroid polypi* (p. 455), formed by increase in size of the papillæ of the cervix, and are generally covered with stratified flat epithelium. They have a pedicle composed of connective tissue and muscular fibers. Others, again, contain glands, and belong, therefore, to the *mucous polypi* (p. 395). Others, again, are *sarcomas* that have taken the papillomatous form (p. 483).

Some, finally, are *true papillomas.* In these the tumor is formed by hypertrophy of the papillæ of the vaginal portion. It contains highly dilated capillaries and larger vessels with very thin walls, but no epithelial elements. It gives rise to a profuse watery discharge and hemorrhage, but the general health does not suffer much, and if the growth is removed by an operation in the healthy tissue, no relapse follows. But when these tumors become old, epithelial elements appear in them, and they take on the structure of epithelioma.

This true papilloma is likewise found springing from the mucous membrane of the body of the uterus, but is exceedingly rare in that locality.

Treatment.—True papilloma is to be treated as carcinoma, especially by amputation of the cervix, or, if situated in the cavity, by curetting and cauterization.

F. *Enchondroma.*

Enchondroma has been found in the cervix, but is very rare. It should be removed by amputating the cervix.

G. *Tuberculosis.*

Next to the tubes, the uterus is the part of the genital tract which is most commonly the seat of tuberculosis. It may be *primary* or *secondary*, and the latter may again spread from neighboring organs or be due to infection through the blood. The disease is usually limited to the mucous membrane. It occurs in three forms—the

acute miliary, *chronic diffuse*, and *chronic fibroid* form. Of these, the chronic diffuse is by far the most common, and is characterized by the formation of cheesy masses. Tuberculosis is nearly always limited to the body of the uterus; and, on the other hand, in a considerable portion of the few cases of cervical tuberculosis on record the disease did not invade the body.[1]

Diagnosis.—Besides offering the symptoms of endometritis, the uterus is considerably enlarged, which is partly due to tuberculous infiltration, partly to hyperplasia of the normal elements. Knobs may be felt near the cornua. If the os is closed, pus may accumulate, so as to form a fluctuating tumor (*pyometra*, p. 317). If it is open, caseous masses may be expelled from it. Shreds removed with the curette and examined microscopically may show bacilli and cells, as described on p. 280. As a rule, a tubercular affection is at the same time found in the tubes and the lungs.

Tuberculous ulceration of the cervical portion may be mistaken for *carcinoma*. Microscopical examination of a piece cut out from the neighboring tissue shows, however, an entirely different structure in the two diseases.

Treatment.—As to general treatment, the reader is referred to what has been said in speaking of tuberculosis of the vulva (p. 280). The local treatment consists in curetting and the application of iodoform. If the disease relapses, the uterus should be removed by vaginal hysterectomy, if the general condition of the patient is not too bad.

[1] J. Withridge Williams, "Tuberculosis of the Female Generative Organs," *Johns Hopkins Hospital Report in Pathology*, ii. Baltimore, 1892, p. 126.

[illegible]TER I.

[illegible]RMATIONS.

[illegible] usually large. In most cases t[illegible] [illegible]esence of some abdominal tumor, w[illegible] [illegible] grows in length and width. I[illegible] [illegible]plication it has been found to meas[illegible] [illegible]gin. One tube may be longer than [illegible]

[illegible] or be abnormally contorted, con[illegible] [illegible] of fluid, inflammation, and ext[illegible]

[illegible] *abdominal* [illegible]. Th[illegible] [illegible] situated near the abdominal end [illegible] the wall.

[illegible] both sides, which is [illegible] [illegible] part of the Müllerian [illegible]

[illegible]

CHAPTER II.

SALPINGITIS.

SALPINGITIS is the inflammation of the Fallopian tubes.

Different Forms.—It may be *acute catarrhal* or *acute purulent*, both of which are seated in the mucous membrane, and are, therefore, called *endosalpingitis;* or it may be *chronic interstitial*, which is also called *pachysalpingitis*, *mural salpingitis*, or *parenchymatous salpingitis*, and is located in the muscular coat. Salpingitis may be *cystic*, and according to the character of the fluid contained in the dilated tube it is called *pyosalpinx*, which is filled with pus, *hydrosalpinx*, which contains a watery fluid, and *hematosalpinx*, the contents of which are bloody.

Perisalpingitis is the inflammation of the peritoneal covering of the tube, a condition which only occurs as part of a more extended pelvic peritonitis.

Profluent salpingitis is only a variety characterized by the discharge of a watery fluid, pus, or blood from the tube through the uterus and vagina. When the fluid is watery the disease is also called *hydrops tubæ profluens* or *intermittent hydrocele of the ovary* (Bland Sutton. See Tubo-ovarian Cysts in the pathology of the Ovaries.)

Under the name of *Salpingitis isthmica nodosa* has been described a form of chronic salpingitis in which nodules can be felt at the corners of the uterus. In their interior is found the tubal canal, hyperplasia and hypertrophy of the muscular elements of the wall, and sometimes cysts.

Pyosalpinx saccata is a variety of pyosalpinx in which the lumen of the tube is partitioned off into a series of pus-filled sacs, which partitions may subsequently become absorbed, so as to form one cavity.

Taking the etiology as base for a classification, salpingitis may be divided into *infectious* and *non-infectious*. The non-infectious is always catarrhal; the infectious is nearly always purulent, but may in the beginning or toward the end of the disease be catarrhal.

Pathological Anatomy.—One or both tubes may be diseased. The infectious form is usually bilateral. The tube is swollen to a thickness varying from that of a little finger to that of a thumb. In *catarrhal* salpingitis the affection is chiefly limited to the mucous membrane. The folds are edematous and hyperemic or slightly infiltrated with small round cells.

The epithelial cells are swollen, show slight increase in size of their nuclei, and vacuoles form in their protoplasm. Side-branches grow out from the folds, and these, as well as the original folds, may grow together, forming closed cavities. The muscular coat does not

participate much in the inflammatory process. The secretion is increased, and contains mucus, albuminoids, and thrown-off epithelial cells.

In *purulent* salpingitis the process is more destructive. The tubes are swollen, often distorted, adherent to neighboring organs, and sometimes divided by internal partitions or external bands into a series of compartments, which give them a beaded appearance. The epithelial cells lose their cilia. The epithelium is thrown off over large areas, and the underlying tissue is crowded with small round cells, which are thrown off as pus-corpuscles. The mucous membrane is the primary seat, but by extension the inflammation invades the muscular coat, and the connective tissue between the muscle-bundles becomes infiltrated with pus-corpuscles. The fimbriæ become agglutinated to one another or to the ovary. In the beginning the ostium uterinum may remain open, constituting a profluent purulent salpingitis. If purulent salpingitis is cured, it leads to a temporary or permanent hypertrophy of the wall by formation of new connective tissue. The vegetations springing from the folds grow together, forming a whole layer of new formation lining the original tube.

Interstitial salpingitis is a chronic disease which has its seat in the muscular coat.[1] It may follow either catarrhal or purulent salpingitis. The extension from the mucous membrane to the muscular layer takes place through the connective tissue. In the first stage the connective tissue between the muscle-bundles is edematous. Next, a large number of inflammatory corpuscles (small round cells) form in it, and even the smooth muscle-fibers themselves break down and are transformed into such cells. Later, the interstitial inflammation may lead to the formation of new connective tissue. It is doubtful if muscular tissue is also formed. In this way the wall is thickened, and the process may end in a permanent *hypertrophy* (Fig. 262). On the other hand, interstitial salpingitis may lead to *atrophy* of the tube. Here the wall is thin, the caliber small, and the epithelium partially lost. The muscle-tissue is to some extent replaced by connective tissue.

The different forms of salpingitis, especially the purulent, are often accompanied by pelvic peritonitis, due to an extension of the inflammation through the wall of the tube to its peritoneal covering, or to the entrance of irritating fluid into the peritoneal cavity through the ostium abdominale. In most cases the ovary becomes implicated in the inflammation. It is full of small cysts or may form an abscess. An exudation is formed in Douglas's pouch or around the tube and ovary, which are then matted together into one globular mass. Ad-

[1] H. J. Boldt has made a special study, illustrated by instructive drawings, of the microscopical changes characteristic of this form in *Amer. Jour. Obst.*, Feb., 1888, vol. xxi. p. 122.

hesions are formed to the intestines, the omentum, the bladder, the uterus, the broad ligament, or the wall of the pelvis.

The loss of epithelium and growth of new folds springing from those normally formed by the mucous membrane may lead to closure of the

FIG. 262.

Hypertrophy of Fallopian Tube due to Interstitial Salpingitis. The tube is cut open, showing the lumen, *a*, in the middle of the thick hard wall, *b*.[1]

ends of the tube or coalescence between the walls in one or more places in their course. As a rule, the abdominal opening is first closed by agglutination between the fimbriæ or between them and the ovary. Later, agglutination may also take place at the uterine end. If both ends are closed, the fluid accumulates, forming a cyst, filled with a serous, mucous, pultaceous, purulent, or bloody fluid. The wall is in most places thickened, but through distention or ulceration in the interior it has thin places liable to rupture. Most frequently this thinning is found in the upper and posterior part of the tube, so that the fluid, in case of rupture of the wall, flows into the peritoneal cavity. In rarer instances the rupture takes place downward between the folds of the broad ligament and produces pelvic cellulitis and abscess.

These tubal cysts are mostly club-shaped, with a thinner inner end and a thicker outer. Sometimes they are more pear-shaped or round, or form a string of alternating wide and narrow parts, like a string of sausages (Fig. 263).

[1] Specimen from my salpingo-oöphorectomy on Mrs. S., in St. Mark's Hospital, on July 24, 1890.

Frequency.—Salpingitis is a rather common disease. Some go so far as to state that it forms twenty per cent. of all diseases of the female genitals, which, however, according to my experience, is a gross misrepresentation. Even if I include cases in which I have found oöphoritis, which, as a rule, is accompanied by salpingitis, only

FIG. 263.

Salpingitis: *a*, tube finger thick at lower end, narrowed in many places; *b*, cyst as large as a chestnut situated in the wall of the tube; *c*, ovary containing a recently ruptured Graafian follicle, the size of a large hazelnut; *d*, torn adhesions.[1]

about 12 per cent. of my cases have had inflamed tubes, and if I limit myself to cases in which I had direct evidence that the tubes were affected, I find only about six per cent. So much is sure, that uterine diseases are without comparison more common than tubal affections.[2]

Etiology.—Salpingitis is hardly ever a primary disease. As a rule, it is secondary to inflammation of the uterus or the peritoneum. The inflammation may follow the mucous membrane or be propagated from the uterus through the lymphatics of the broad ligament.

The disease is nearly always limited to the period of genital activity. It is quite frequent in prostitutes, causing *colica scortorum;* and unfortunately, it appears often in newly-married pure women.

[1] Specimen from my salpingo-oöphorectomy on Mrs. L. S., in St. Mark's Hospital, on August 29, 1890.

[2] Based on a large pathological experience, H. C. Coe comes to the conclusion that "actual disease of the tubes is far less frequent than is generally believed," *Amer. Jour. Obst.*, June, 1886, vol. xix. p. 575. According to him chronic catarrhal salpingitis does not exist, atrophy and hypertrophy are rare, pyosalpinx is found in only one-fifth of the cases in which the appendages have been removed, hydrosalpinx is still less frequent, and hematosalpinx exceedingly rare.

Malformations, such as atrophy, a spiral twist, and angles in the course of the tubes, predispose to their inflammation.

Salpingitis may be due to infectious and exanthematous diseases, such as cholera, typhoid fever, scarlet fever, and smallpox. It may be brought on by flexion, myoma or carcinoma of the uterus, and perhaps stenosis of the os, with retention of mucus in the cavity, or by ovarian disease. It may be caused by exposure to cold, violent exercise immediately before menstruation, or too frequent coition. But in the large majority of cases salpingitis, and that in its worst form, the purulent salpingitis, is either gonorrheal or puerperal. If gonorrhea once invades the uterus, it has a great tendency to spread to the tubes. Puerperal salpingitis is found as part of the affections characteristic of puerperal infection or of incomplete abortions, in which the ovum or the spongy decidua is allowed to remain in the uterus.

Purulent salpingitis may also be due to gynecological treatment, not only operations, such as incision of the cervix; but the mere introduction of a sound or the administration of an intra-uterine douche may, in rare cases, lead to salpingitis or change a comparatively harmless catarrhal into a purulent inflammation.

Symptoms.—There is no pathognomonic symptom. Even a dangerous puerperal salpingitis, calling for removal of the pus-filled tubes, need not cause any other symptom than emaciation and recurrent fever. A symptom, however, that must awaken great suspicion is an *intermittent outflow* of mucous or purulent fluid from the genitals, but the same may sometimes be due to endometritis. The patient is, as a rule, *sterile*, or has had one child, so-called secondary sterility. The disease is, in most cases *bilateral* or, if only found on one side, the *left* is more likely to be affected, a peculiarity which may have its cause in the preponderance of cervical tears on this side (p. 383) or the absence of a valve in the left ovarian vein (p. 74).

Pain may be insignificant or excruciating. It is felt in one or both iliac fossa and in the sacral region. It often has a colicky character, and may be due to contraction of the inflamed muscular coat or to pressure on the ends of nerve-filaments. In other cases the pain is burning. If only one side is affected, the pain is sometimes felt in the opposite side. It is increased by any kind of exertion, so that the woman becomes unable to do any kind of work; and it is much enhanced by coition. It is worst at the menstrual period.

Leucorrhea is common. Often the patient suffers from *menorrhagia* or *metrorrhagia*, the hemorrhage taking place in the sick tubes themselves or in the uterus, the endometrium of which may be inflamed. Periods of menorrhagia may alternate with others of *amenorrhea*. The general health suffers, the patient loses flesh, and strength, becomes nervous, and often has fever.

By vaginal examination the tubes are found tender, thickened,

Frequency.—Salpingitis is a [illegible] adherent to neighboring organs. far as to state that it forms [illegible] and tender, or there may be an female genitals, which, however, [illegible] knuckle of intestine and a part gross misrepresentation. Even [illegible] into one shapeless mass. found oöphoritis, which, as a [illegible] fill the pelvis as to push the [illegible] same time canting it forward. [illegible] large, they push the uterus with [illegible] forward up against the anterior wall [illegible] above, tipping it forward into [illegible] again the uterus is found retro- [illegible] posterior wall of the pelvis.

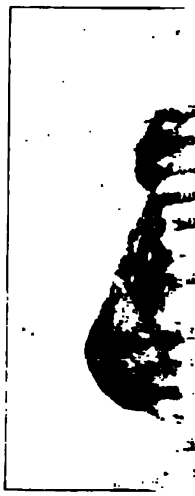

Salpingitis: *a*, tube finger thick at [illegible] a chestnut situated in the wa[illegible] Graafian follicle, the size of a [illegible]

[illegible] salpingitis may be very difficult, the [illegible] ovaritis, peritonitis, and cellulitis. [illegible] allow of mucus or pus preceded by [illegible] the presence of salpingitis very [illegible] still more weight if the examiner by [illegible] region can make the fluid appear [illegible]

[illegible] of general hysteria; *lumbo-abdomi-* [illegible] on the skin over the iliac region, [illegible] vagina, and in none of these purely [illegible] swelling.

[illegible] tube is distinguished by its shape, [illegible] felt beside the swollen tube, in a [illegible] enlarged and tender compared with [illegible]

[illegible] situated lower down than the swollen

about 12 per cent. of my [illegible] larger exudation of more globular myself to cases in which [illegible] pouch to one of the iliac fossæ. affected, I find only about [illegible] swollen tube from an *intestinal knuckle* diseases are without comp[illegible] the latter is not particularly tender, is

Etiology.—Salpingitis [illegible] sometimes empty, while at other times it is secondary to inflamm[illegible] inflammation may follow [illegible] the uterus through the l[illegible]

[illegible] ledge of the condition of the tubes it

The disease is nearly a[illegible] common examination in the dorsal and It is quite frequent in p[illegible] touch (p. 139), to anesthetize the patient, tunately, it appears ofte[illegible] let the legs fall out, so as to put the [illegible] introduce the fore- and middle fingers of [illegible] of the vagina, and depress the ab- [illegible] The vaginal examination is performed [illegible] side of the pelvis, and the right hand

[illegible] be surmised if the history reveals gon- [illegible] and the purulent nature of the fluid in

[1] Specimen from my salpi[illegible] on August 29, 1890.

[2] Based on a large patho[illegible] actual disease of the tub[illegible] *Obst.*, June, 1886, w[illegible] pingitis does not exist, a[illegible] only one-fifth of the case[illegible] pinx is still less frequent

the tube, together with the permeability of the ostium uterinum, is proved if pus can be made to appear at the os uteri by the above-mentioned manipulation.

Prognosis.—Salpingitis is a serious disease. Its course is usually a tedious one. It may end fatally from exhaustion; it may cause sudden death or make the patient an invalid for life, and it very often entails sterility. It is especially the purulent form the prognosis of which is so doubtful; the catarrhal is more amenable to treatment, less protracted, and less dangerous.

Treatment.—Prophylaxis.—Women should be sufficiently clad (see p. 126) and avoid sudden refrigeration when heated, especially during the menstrual period.

As far as possible they should avoid marriage with a man who has or has had a gonorrhea which is not perfectly cured; or to put it the other way, a man with gonorrheal threads, designated with the German name "tripper faden," in the urine, or at whose meatus urinarius appears a little secretion in the morning, should not marry unless the discharge is free from pus, and when even a purulent discharge, artificially produced by injection with nitrate of silver or corrosive sublimate, does not contain gonococci (see latent gonorrhea, p. 129).

Childbirth should be surrounded by all antiseptic precautions.[1] In cases of incomplete abortion the uterus should be emptied immediately.

If salpingitis is present the doctor should abstain from making an incision in the cervix, introducing an intra-uterine pessary, using intra-uterine injections, nay, even from carrying a sound into the uterine cavity, as all these interferences may give new impetus to the disease or change a catarrhal salpingitis into a purulent, and lead to death.

Curative Treatment.—In acute salpingitis we prescribe absolute rest in bed, fluid diet, an ice-bag on the lower part of the abdomen, opium suppositories (p. 218), hot vaginal douches (p. 167), and, if necessary, a saline aperient (p. 217). Hot rectal injections serve both to move the bowels and combat the inflammation. If the inflammation is unmistakably purulent and gives rise to serious symptoms, it is safer to remove the appendages immediately without losing any time in palliative treatment.

In the chronic form much may be accomplished by mild treatment, if the patient can take care of herself. It is often good even in this form to begin with confining the patient to her bed for three or four weeks. Painting internally and externally with tincture of iodine

[1] Full information in this respect is found in Garrigues' *Practical Guide in Antiseptic Midwifery in Hospitals and Private Practice*, Detroit, Mich., 1886, and in my article on "Puerperal Infection" in *Amer. System of Obstetrics*, Phila., 1889, vol. ii. pp. 327–361.

(pp. 165 and 184), pledgets soaked in ichthyol-glycerin (p. 173), galvanism with one pole against the vaginal vault (p. 224) or in the uterine cavity (p. 223), preferably the former, scarification of the cervix (p. 182), intra-uterine applications of chloride of zinc (p. 166), blisters applied over the inguinal fossa, superficial cauterization of the same region with Paquelin's cautery, poultices, hot-water bags, Priessnitz compresses (p. 183), and warm entire baths—are all very effective remedies, which, combined with substantial food, mild stimulants (p. 204), and tonics (p. 217), may effect a cure. Some recommend *curetting* (p. 171) followed by antiseptic applications, on the principle that by making the endometrium healthy we indirectly act beneficially on the mucous membrane of the tube. I have not performed this operation for that purpose, and think it might occasionally render the tubal inflammation worse.

Others think they can evacuate the fluid from the tube by dilating the uterus, curetting, especially around the openings of the tubes, and packing with iodoform gauze, to be removed every day or two.

Massage (p. 187) has also been praised, but seems to me to be surrounded by too great dangers. The only indication I see for it is the cases in which the abdominal opening of the tube is closed, and the uterus remains open. Under such circumstances a very gentle pressure following the course of the tube from without inward toward the uterus may press out the fluid which has accumulated in the tube. But the diagnosis is not easy to make on the living, and if the abdominal ostium was just a little agglutinated, the pressure might reopen it and drive the contents of the tube into the peritoneal cavity.

Intra-uterine injections should be avoided, as they are apt to increase the inflammation of the tubes.

If these milder measures do not succeed, the tube may be attacked surgically from the vagina or through the abdominal wall.

Catheterization of the tube is in normal cases, and in most pathological ones, impossible. It has only been performed when the uterus was lateroflexed, and the ostium internum much dilated. In other cases of supposed catheterization the sound has perforated the uterine wall, which is easily done, and, as a rule, has no bad consequences (compare p. 172).

Aspiration through the vaginal vault is not devoid of dangers, not only on account of the organs that may be wounded with the needle, but still more on account of the nature of the fluid that after its withdrawal may drip into the peritoneal cavity. It should, therefore, only be used if the swelling is situated in the posterior half of the pelvis, so low down that it is within easy reach, and when it seems so firmly adherent in Douglas's pouch that we have reason to hope that no fluid will escape into the peritoneal cavity. Besides, as a rule, aspiration will have greater value from a diagnostic standpoint than

from a curative. It is most likely that the diseased mucous membrane of the tube will reproduce a similar fluid.

A great improvement on simple aspiration is, therefore, the combination of galvano-puncture, aspiration, injection, and drainage (Gehrung's method, p. 227).

An *incision* may be made from the vagina, and a drainage tube of glass, hard rubber, or silver introduced and fastened to the vaginal vault with silver wire drawn through holes in the vaginal end of the tube.[1] We may also use a soft rubber tube with cross-bar, and long enough to protrude from the vagina. A safety pin is inserted at the lower end, and iodoform gauze wound round tube and pin, so as to close the tube without preventing drainage. This method should, however, only be used if the conditions mentioned in speaking of aspiration are present.

In all cases that have withstood the palliative treatment for four months or longer, an *exploratory laparotomy* is indicated, which may lead to the removal of the uterine appendages or to their preservation by different means.

Conservative Treatment.—In some cases it suffices to separate adhesions, run a probe through the whole length of the tube, wash it out from the fimbriated end with a weak solution of bichloride of mercury (1 : 5000), and stitch the fimbriæ to the peritoneum near the ovary so as to prevent them from curling in and closing the abdominal opening again. If the fimbriæ cannot be separated, the end of the tube may be cut off, and the mucous membrane stitched to the peritoneal coat with a few catgut sutures. At the same time it may be necessary, in order to prevent reformation of torn adhesions, to perform abdominal hysteropexy (p. 438) or shortening of the round ligaments (p. 435). Such conservative measures have even been successful when the tube contained from a half to a whole fluidrachm of pus. Where there is a large collection of fluid, the tubes should be removed.[2]

Salpingo-oöphorectomy.—Indications.—In acute salpingitis the removal is counterindicated except when a purulent salpingitis extends to the peritoneum and threatens to become generalized. Under such circumstances the extirpation should be performed immediately, without losing time with palliative measures. If there is a purulent discharge from the uterus, this organ ought to be curetted as soon as the patient has recovered from her laparotomy.

The removal is also indicated for interstitial salpingitis, if the patient suffers much pain, and has repeated attacks of pelvic peri-

[1] T. G. Thomas, *Diseases of Women*, 6th ed. 1891, p. 763.

[2] Polk has done much in this line, and described his procedures in *Medical Record*, Sept. 18, 1886; *Amer. Jour. Obst.*, 1887, vol. xx., p. 630; *Trans. Amer. Gyn. Soc*, 1887, vol. xii., p. 128; *Jour. Obst.*, Dec., 1890; *ibidem*, Sept., 1891.

tonitis; and for most cases of cystic salpingitis, especially pyo- and hematosalpinx.

It is true, numerous autopsies have proved that pus can become inspissated in the tubes to a puttylike mass, and, on the other hand, it can probably, by a process of clarification, be changed into a serous or mucous fluid, but such favorable events are too uncertain, and it is, therefore, safer to remove the tube if it contains more than a very small amount of pus.

If the endometrium shows signs of infection, it is advisable first to curet and drain (p. 175) before performing laparotomy, and in this way the latter operation may sometimes be avoided.

On the other hand, in general, the removal should not be undertaken as long as the uterine ostium remains open.

Under all circumstances the consent not only of the patient, but of her husband, must be obtained. The off-hand way in which some operators spay a woman without her knowing it, is not only unjustifiable on moral grounds, but exposes the operator to a suit for mayhem and heavy damages.

Modus Operandi.—The appendages may be removed through the abdominal wall or through the vagina: most operators prefer the former, which gives more space and enables us, if necessary, to inspect the whole pelvis. It is called *Tait's operation*, the latter *Battey's operation.*[1] The reader is referred to the general description of laparotomy given under Ovariotomy. Here we shall only add a few points with special regard to salpingo-oöphorectomy.

A. *Abdominal salpingo-oöphorectomy.*—The incision is made in the median line, so low down that the lower end is half an inch above the symphysis. The upper end varies according to circumstances. In easy cases only room for two fingers is needed; in difficult it may become necessary to introduce the whole hand, push the intestines up, and expose the whole pelvic cavity to view.

When the small incision is made in the abdominal wall, the left fore- and middle fingers are introduced into the abdominal cavity. Pushing omentum and intestines up, the fingers are placed on the fundus uteri, and moved out along one of the tubes to the ovary. If there are no adhesions, the tube and ovary are lifted between these two fingers up through the abdominal wound. If necessary this procedure may be facilitated by having the uterus lifted from the vagina by means of a dilator introduced into the cervix or simply with the fingers of an assistant.

In this and other operations in the depth of the pelvis the manipulations may also be much facilitated, especially on the left side, by

[1] Battey's operation was originally devised for the "extirpation of the functionally active ovaries for the remedy of otherwise incurable diseases" (*Trans. Amer. Gyn. Soc.*, 1876, vol. i. p. 101), but has been much extended both as to object and method.

introducing a colpeurynter, *i. e.* a rubber bag, into the rectum, and distending it with water. If oozing points are left in the pelvis after the operation, this same bag filled with ice-water and combined with abdominal compression may serve as a hemostatic plug working both by pressure and refrigeration.

If the broad ligament does not yield, Tait gains room by making small tears in it with his nails near the pelvic wall. The peritoneum and connective tissue are torn, but the stronger vessels resist. The parts to be removed may also be seized beneath the surface of the body with suitably curved forceps, and ligated there, without being brought out through the incision.

If there are adhesions they are cautiously torn, the surgeon, if possible, relying on his sense of touch alone. Otherwise, they are lifted up into the wound and separated there. Sometimes it is necessary to enlarge the incision so as to make the whole pelvis accessible to the eyes and hands. The intestines are pressed up under the abdominal wall, and held there with a flat sponge or a gauze compress. In very exceptional cases they are even pulled out through the opening, laid on the upper abdomen, and covered with a cloth wrung out of hot water. Trendelenburg's position helps much to avoid this handling of the intestines, which is apt to cause shock and predisposes to adhesions after the operation.

If the tube and ovary are imbedded in a whole mass of resistant new-formed tissue it may be necessary to desist from their removal, but with increasing experience and skill a man will be able to remove organs which, at an earlier stage of his career, it was wise to leave undisturbed.

Tait does not give up the operation even if it is necessary to wound bladder and intestine in order to finish it. The ensuing fistula heals spontaneously.[1]

Sometimes serous fluid accumulates in the interior of adhesions by which they become tubular, and look much like a Fallopian tube or the appendix vermiformis.

Vascular bands are often cut between two ligatures.

When the tube and ovary are lifted up, a dull handled needle (Fig. 175, p. 207), threaded with a loop of medium strength silk (braided, No. 4) which is closed with a knot at the end farthest away from the eye, and has about the same length as the needle, is pushed from behind forward, through the broad ligament under the ovary. When it emerges in front, an assistant pulls the silk out a little and inserts a strong silk ligature (braided, No. 12), 20 inches long between the needle and its silk loop, and pulls it through to its middle. By withdrawing the needle with its silk loop held against it the pedicle-silk is carried back under the ovary, when the operator liberates it

[1] Lawson Tait, *Centralblatt. für Gynäk.*, Feb. 4, 1893, vol. xvii. p. 93.

from the carrier.[1] Next, the loop of the pedicle-silk is brought forward over the ovary and tube, comprising as much of the latter as feasible. One of the free ends is carried through this loop, the other remains above it. The operator seizes both ends with the fingers of his right hand and pulls on them, and presses with his left thumb and index-finger against the tissue to be ligated. He may also pull on one end alone, and have his assistant pull on the other, or, preferably, he may combine both these manipulations. The ligature is pulled very tight, but slowly, so as not to break it, and then tied with a reef knot. This way of tying the ligature is called the *Staffordshire knot* (Fig. 264), because it is the badge of the county of Stafford in England. From each side a pressure-forceps is put on the pedicle just above the ligature, and tube and ovary are cut off with small cuts made with a pair of scissors curved on the flat. Next, one of the pairs of forceps is removed, and a strong tenaculum or tenaculum-forceps inserted in its stead. Then the second forceps is taken off. If there is no bleeding from the stump, the ends of the ligature are cut short. If there is bleeding, the ligature is carried round the pedicle and tied on the other side. The cut surface is powdered with iodoform or aristol. Finally, the tenaculum is removed, and the pedicle dropped into the pelvic cavity. If there is too much tissue, it may be cut off under the tenaculum.

Fig. 264.

Staffordshire Knot (Tait).

It should be remembered that the ovarian vessels at the brim of the pelvis cross in front of the ureter, and care should be taken not to embrace this tube in the ligature.

If the tumor is situated in the broad ligament, leaving the lower part of the same free, this may be tied in small bundles, between two ligatures, gaining access to the deeper portion by gradually cutting what has been tied. If there is no pedicle at all, the peritoneal covering of the tumor must be split, and the tumor enucleated. This leaves a sac which is treated as described above (p. 479) under Fibroids of the Uterus.

As to the treatment of *the appendages of the other side* there is much difference of opinions. Tait recommends to remove them even if they are healthy, because they will be affected later, and the second operation has a mortality altogether disproportionate to the first proceeding, while many die for want of a second operation. Other operators, on the contrary, have even tried to save the second set of adnexa when they were found diseased. This has the advantage of preserv-

[1] Some insert the strong silk immediately into the eye of the needle, but the procedure described above has the advantage that the pedicle-silk cannot be cut by the eye of the needle.

ing menstruation, and of avoiding the mental depression sometimes following the removal of the appendages on both sides, and has even, in rare cases, led to pregnancy and childbirth. When offspring is particularly desirable this method should, therefore, be considered.[1]

The ovary may be cut open, cysts enucleated or part of the ovary cut out, and the edges united by a continuous catgut suture. A piece of the tube may be cut off, and hemorrhage arrested by ligating the ala vespertilionis without interfering with the vessels nourishing the ovary. An opening may be cut in the tube, and the mucous membrane stitched to the peritoneum around it (p. 511).

While the removal of non-adherent appendages is a comparatively easy operation, it becomes one of the most difficult when there are many extensive and unyielding adhesions.

The *mortality* after salpingo-oöphorectomy has, in Tait's hands, only been 2.5 per cent. The objection that the operation deprives the patient of the possibility of becoming a mother has not much weight, since in the large majority of cases she has proved to be or would be sterile on account of the condition of the ovaries and tubes. Her sufferings may be intolerable, and render it impossible for her to earn a living or perform any useful work. Often they make an opium-eater of her. Now, in most cases, but, it must be admitted, not in all, the operation restores her to health and makes her again a useful member of her household and the community at large.

Immediate and Remote Results.—In 86 per cent. the operation brings on the menopause at once or after a few months (compare p. 118). When menstruation continues it may be due to incomplete removal of the appendages, irritation of the stumps, or disease of the uterus. As a rule, there is a discharge of blood for several days following the operation, which is accounted for by the unusual congestion caused by the ligature cutting off the normal roads of circulation. In some cases a hematoma is developed in the broad ligament. Sometimes, during convalescence, or later, an encysted collection of serous fluid takes place in pseudomembranes. Many complain of vertigo and fulness in the head, which may be relieved by bromides or cauterization with Paquelin's thermo-cautery on the nape of the neck, or which may even necessitate repeated venesection.

Purpura hemorrhagica has been observed at the time when menstruation was due, but the operation does not give rise to vicarious menstruation.

During the first week after the operation most patients complain of pain in the pelvis, which probably is due to the constriction of the pedicle. In some this pain disappears soon, and they feel relieved from their sufferings and bless the day they submitted to the opera-

[1] Details are found in papers by A. Martin, *Centralblatt. für Gynäk.*, June 20, 1891, vol. xv. No. 25, p. 515, and Polk, *Amer. Jour. Obst.*, Dec., 1890, vol. xxiii. p. 1375.

from the carrier.[1] Next, the loop of the pedicle-silk is br[illegible] of over the ovary and tube, comprising as much of the la[illegible] This One of the free ends is carried through this loop, [illegible] above it. The operator seizes both ends with the [illegible] hand and pulls on them, and presses with his left [illegible] finger against the tissue to be ligated. He may [illegible] alone, and have his assistant pull on the other, or [illegible] combine both these manipulations. The ligatur[illegible] but slowly, so as not to break it, and then tied [illegible] way of tying the ligature is called the *Staff*[illegible] because it is the badge of the county of Staff[illegible]

Fig. 264.



Staffordshire Knot (Tait).

each side a pressur[illegible] icle just above t[illegible] ovary are cut off [illegible] a pair of scisso[illegible] one of the pair[illegible] strong tenaculu[illegible] in its stead. [illegible] off. If there [illegible] the ends of [illegible] there is bleeding, the ligature is [illegible] on the other side. The cut surf[illegible] aristol. Finally, the tenaculum [illegible] into the pelvic cavity. If there [illegible] under the tenaculum.

It should be remembered [illegible] the pelvis cross in front of th[illegible] to embrace this tube in the li[illegible]

If the tumor is situated [illegible] part of the same free, this [illegible] ligatures, gaining access [illegible] what has been tied. If [illegible] ering of the tumor must [illegible] leaves a sac which is t[illegible] roids of the Uterus.

As to the treatm[illegible] much difference of [illegible] if they are healthy, [illegible] operation has a mor[illegible] ceeding, while man[illegible] rators, on the cont[illegible] when they were [illegible]

[1] Some insert th[illegible] cedure described a[illegible] eye of the needle.

of a long tube. Without speculum and retractors we do not see any thing at all, and if we use them, they block the passage for our fingers. This method was excellent for the removal of healthy ovaries and at a time when lack of antiseptic surgery made the opening through the abdominal wall much more dangerous than that through the vagina, but for the needs of the present day, when we especially wish to remove sick tubes, and with our present resources in regard to hemostasis and drainage, the abdominal method is preferable. If, however, the uterus is retroverted, or the cervix can be pulled forward and the fundus easily forced down into Douglas's pouch, the appendages may be safely removed in this way. Under these circumstances there will seldom be trouble from intestinal adhesions.[1]

The vagina is opened in the median line by an incision extending backward from the utero-vaginal junction, or by a transverse incision just behind the cervix, after which the operator works mostly with his forefinger until he can plunge it into the peritoneal cavity. Adhesions are torn and the appendages brought down and ligated. Hemorrhage is stopped by the same means as when laparotomy is performed.

Cystic Salpingitis.

When a considerable amount of fluid distends the tube, it forms a cyst. The abdominal ostium is closed, the uterine may yet remain open. The cyst forms a tumor situated to the side of and above the uterus, whence it may extend up into the abdominal cavity or down between the layers of the broad ligaments. The swelling may be club-shaped, with a narrower inner and a wider outer end; or it may be more globular and be bound to the uterus with a narrow pedicle, corresponding to the inner undilated part of the tube; or it may be divided by external bands or inner partitions into a series of compartments, which gives it the appearance of a string of sausages.

The contents vary much, but may be divided into three chief classes according to the preponderating element—namely, pus, blood or serum. Often different kinds are found in the same individual.

Symptoms.—When salpingitis leads to the formation of a cyst, pressure-symptoms are added to those due to inflammation. The patient complains of heaviness and a bearing-down sensation, meteorism, constipation, often combined with a frequent desire for defecation and micturition, which is an inconvenience in daytime and disturbs her rest at night. Sometimes there is a constant slight discharge of blood from the uterus. She has pain in the inguinal and sacral regions, and repeated attacks of peritonitis.

By bimanual examination a tumor of the description just given is felt which may be movable or immovable, more frequently the latter.

[1] Henry T. Byford of Chicago, *Amer. Jour. Obst.*, March, 1892, p. 337.

Diagnosis.—The diagnosis between cystic salpingitis and certain other diseases may be difficult or impossible. *Tubal pregnancy* forms a similar globular tumor fastened to the cornu of the uterus. The history, the presence of signs of pregnancy, the expulsion of shreds of a decidua, and attacks of sudden pain so violent as to make the patient scream and sink down on the floor may, however, enable us to make the diagnosis of tubal pregnancy.

An *ovarian cyst*, be it pedunculated or intraligamentous, may be entirely like cystic salpingitis; but sometimes the ovary may be felt beside the cystic tube, and the history of the case may give useful information.

Cysts of the broad ligament are less painful, hardly tender, immovable, and tip the uterus to the opposite side. A *peritonitic exudation* causes a constant pain, is immovable, and pushes the uterus forward and downward, but all this may also be found in cystic salpingitis. A *uterine fibroid* may form a similar tumor either in the abdominal cavity or between the layers of the broad ligament, but it is harder, never fluctuating, and the depth of the uterine cavity is increased. A uterine *fibro-cyst* is in closer connection with the uterus, and the sound reveals an increased depth of the uterine canal. *Swollen pelvic glands* may give a similar history and form a similar tumor. Aspiration may give information about the presence and nature of fluid, but ought not to be used unless the tumor is adherent to the abdominal wall or the vaginal vault.

The differential diagnosis between the three kinds of cyst may also be very obscure, although certain circumstances may point more distinctly to one rather than to the others. Thus pyosalpinx is by far more common, follows gonorrheal or puerperal infection, is very adherent and tender, often causes fever, and is apt to form fistulæ. Like hydrosalpinx it is usually bilateral.

Hydrosalpinx may form a tumor of much larger size. As a rule, it is less adherent and less tender, and causes less constitutional disturbance.

Hematosalpinx is exceedingly rare, is often unilateral, and may be accompanied by a constant bloody discharge from the uterus. Sometimes it is combined with hematocolpos and hematometra.

Treatment.—As a rule, the cystic tube with the ovary should be removed. An exploratory laparotomy should be performed. If the cyst is large, it is well to empty it with trocar or aspirator, and close the opening with pressure-forceps before extirpating the tumor. If it is small, it may be removed *in toto*.

The arrest of *hemorrhage* may be very troublesome. It has become necessary to leave pressure-forceps in the abdominal cavity till the next day, and even to perform hysterectomy, but as a rule the operator will be able to control bleeding by the usual means: tying of

arteries, temporary compression with forceps, sponges, or compresses, flushing the abdominal cavity with hot water (p. 177), uniting peritoneal edges with a continuous suture of catgut, stitching other bleeding places in a similar way (p. 479), and permanent compression with iodoform gauze with or without counterpressure in the vagina (p. 176).

Broad *adhesions* are often better separated with a sponge than with the fingers. Band-like adhesions should be tied near both ends and cut away, as their presence later might give rise to intestinal obstruction. If there are many adhesions, the removal of the cyst is sometimes facilitated by cutting the tube between two ligatures near the inner end, and proceeding outward instead of going from the infundibulopelvic ligament and the pelvic wall toward the uterus. In order to guard against infection it is best to cut the tube with Paquelin's thermo-cautery or sear the ends after having cut with knife or scissors.

The prognosis for the operation is better in hydro- and hematosalpinx than in pyosalpinx.

Besides these considerations applying to cystic salpingitis in general, each of the three varieties offers some peculiarities.

Pyosalpinx.

Pyosalpinx is that form of cystic salpingitis in which the contents are purulent. The name is only used if an appreciable cyst has been formed, while a small amount of pus in the tube simply constitutes purulent salpingitis. The cyst has in most cases the size of a Bartlett pear, but may be as large as a fetal head at term or even a cocoanut. The wall is in general thickened, but has thin places, especially upward and backward, where the cyst is apt to burst during the operation for its removal. The abdominal ostium is closed by agglutination of the fimbriæ among themselves or to the ovary. The uterine ostium may yet be open. As a rule, the cyst is adherent 'way down in Douglas's pouch. The uterus is often retroflexed.

The fluid is thick pus, sometimes of a dirty color and offensive odor, due to the neighborhood of the intestines. In the course of time it may change, blood being admixed with it by hemorrhages from the wall, or it may become inspissated to a putty-like mass, or the cellular elements may be absorbed, leaving a more serous or mucoid fluid.

If left alone, the cyst may rupture and discharge its contents into the peritoneal cavity, causing sudden death, or in between the layers of the broad ligament, whence it may find an outlet through the rectum, the vagina, the bladder, or the skin, either above or below

Poupart's ligament, or in the gluteal region. Such rupture often leaves a fistulous tract with no tendency to heal, the continued discharge exhausting the patient.

Treatment.—Some puncture with the aspirating needle from the vagina, the rectum, or the skin, according to the situation of the cyst, and when pus appears they follow the puncture up with an *incision*. This method only deserves consideration if the cyst is situated in the bottom of Douglas's pouch, and is firmly adherent, and the other set of appendages seems to be healthy. It may be drained, as stated above (p. 511), irrigated with antiseptic fluids, injected with tincture of iodine, touched with a stick of nitrate of silver, or painted with iodized phenol (a mixture of iodine 1 part and crystallized carbolic acid 4 parts), but the abscess may continue to discharge for many months.

Most operators prefer *laparotomy*, either in one sitting or in two acts. By the latter method the sac is made to adhere to the abdominal wall before it is opened. The common way is to operate in one sitting, guard the peritoneal cavity against the entrance of pus by means of large sponges or gauze compresses, and, if it has entered, wash it out with plenty of warm water and extirpate the sac.

Some prefer the *vaginal extirpation*.

Hydrosalpinx.

In hydrosalpinx the fluid is serous, mucous, or pultaceous. Sometimes it contains cholesterine. The wall is, as a rule, thin and translucent. This variety of cystic salpingitis is less apt to become adherent and is, therefore, often movable. Like pyosalpinx it is in general bilateral, but it develops more slowly, gives rise to less pain, and may become larger. In most cases it is not larger than a pear, but it sometimes reaches the size of a fetal head at term, and may even form a very large cyst (Fig. 265). Even if only one side is affected the patient is, as a rule, sterile. Often hydrosalpinx is accompanied by a cystic degeneration of the ovary, and through inflammation it may become adherent to an ovarian cyst, which may make an impression as if the hydrosalpinx itself were of unusual size. Rupture of the sac is an exceedingly rare event, and the general condition is much better than in pyosalpinx. It is probably the remnant of an old catarrhal or, perhaps, even a purulent salpingitis. The diagnosis might, perhaps, be made surer by aspirating the fluid, but, being less adherent, hydrosalpinx is less fit for this operation. We might find ciliated columnar epithelium in the fluid, but that may also be found in certain ovarian cysts.

Treatment.—A small cyst of this kind may give so little trouble that it may be left alone. Sometimes *aspiration* through the vagina

may effect a cure. The tumor may be emptied by means of an *incision* made in the vagina and drained, but this process may prove a tedious one. In most cases *laparotomy* is performed and the tumor is

FIG. 265.

Hydrosalpinx.[1]

removed. If the tumor is not very large, and the ovaries are in a fair condition, an attempt may be made to save one or both sets of appendages (p. 511).

Hematosalpinx.

Hematosalpinx is the name for a cyst formed by the tube and filled with blood. There are two forms: in one the blood is not coagulated, but kept fluid by admixture with alkaline secretion from the inside of the tube; in the other is found a laminated fibrinous clot due to successive hemorrhages. In the former the wall need not undergo much change, and the blood may be reabsorbed; in the latter the

[1] Specimen from my operation on Mrs. A. N—— in St. Mark's Hospital, on April 30, 1892. In this case a unilateral hydrosalpinx formed a tumor filling the pelvis and reaching to the level of the umbilicus.

wall is much thickened. The effused blood may be inspissated to a syrupy mass or changed to pus, and the wall may ulcerate and finally rupture, an accident which is much more common with hematosalpinx than with hydrosalpinx, and has to be guarded against in operating for atresia of the genital canal (p. 318).

Etiology.—Exanthematous and infectious diseases, phosphorus-poisoning, extensive burns, and diseases of the heart, lungs, and kidneys, may cause ecchymosis or slight hemorrhage into the tubes.

In pyosalpinx hemorrhage may take place from the wall, and blood mix with the pus.

When there is an occlusion of the genital canal, the menstrual blood which normally is secreted in the tubes (p. 117) is retained and forms hematosalpinx combined with hematocolpos and hematometra, although the communication between the tube and the uterus may be interrupted (p. 317).

Hematosalpinx may also be due to a uterine fibroid or an inflamed ovary, causing salpingitis by extension of the inflammation of the endometrium or the ovary and closing the tube, or it may be a reflex effect of an extra-uterine pregnancy in the other tube.

Treatment.—Small tumors need no treatment. In that form which contains fluid blood laparotomy may be performed, the tube cleaned out, made perviable, and allowed to remain (p. 511). If the cystic tube has developed down between the layers of the broad ligament, which may be supposed when it is low down and immovable, an incision may be made in the vaginal vault, and the cyst drained. Large tumors filled with clots or blood mixed with pus should be removed by laparotomy. The same procedure becomes necessary after the operation for atresia of the genital canal, if it has not preceded it (p. 318).

CHAPTER III.

Displacements.

The tube may be found in a crural or inguinal hernia, and is then generally accompanied by the ovary.

In the higher degrees of inversion of the uterus the tubes are always drawn into the sac formed by the inverted uterus (p. 448).

CHAPTER IV.

Neoplasms.

The neoplasms of the tubes are not of much practical interest, as they often cannot be diagnosticated, are so small that they do no harm,

or appear together with affections of greater importance in the neighboring organs.

A. *Cysts.*—Real cysts, which are something entirely different from cystic salpingitis (p. 517), may be found in all three layers composing the wall of the tube. They range in size from a millet-seed to a walnut, and contain a citrine, serous fluid. They are seen very frequently in laparotomies and autopsies. One of them situated at the abdominal end of the tube is so common that it is described in works on normal anatomy under the name of the *hydatid of Morgagni* (p. 30). Some of these cysts are doubtless remnants of the Wolffian body (p. 20), and others are the result of extravasations of blood.[1]

The fluid contained in them is so bland that, even if through a rupture in the wall it should find its way into the peritoneum, it could hardly do any harm.

B. *Fibroma.*—Myomatous and fibrous tumors like those of the uterus (p. 454) are formed in the muscular coat, but do not, as a rule, acquire surgical dimensions. In one case, however, the growth had reached the size of a fetal head at term.

C. *Lipoma.*—Fatty tumors of the size of a bean to that of a walnut have been found at the lower side.

D. *Papilloma*, a real neoplasm, must not be confounded with the growth of the mucous membrane due to simple hyperplasia and hypertrophy accompanying salpingitis (p. 503). Papillomatous tumors may close, dilate, and even rupture the tube, in which latter case a papillomatous infection would be likely to take place in the peritoneum. They are commonly small, but may reach the size of an orange.

E. *Cancer*, either carcinoma or sarcoma, may occur primarily in the tubes, but is nearly always secondary to cancer of the uterus or the ovary.

The disease makes its appearance about the time of the menopause, and develops slowly. It gives rise to a sanious discharge from the vagina, which, in connection with the presence of a tumor and the absence of signs of uterine or vaginal cancer, may lead to a diagnosis. As a rule, it is not recognized before an autopsy is made.

If it can be diagnosticated in life, the tube and ovary should be removed by laparotomy.

F. *Tuberculosis.*—The Fallopian tube is more apt than any other part of the genital apparatus to be the seat of tuberculosis. In fact the tubes are affected in nearly all cases of tuberculosis of the genital tract, and genital tuberculosis is much more common than was formerly surmised.

It may be primary in this locality, and is then probably due to

[1] This was so in a case of chronic oöphoritis and salpingitis operated on by me and examined miscroscopically by Charles Heitzmann.

infection through the semen of a tuberculous man. Much more frequently, however, it is secondary, following tubercular peritonitis or being the effect of infection through the blood in persons suffering from phthisis. As a rule, both tubes are affected.

The wall is swollen, its epithelium is thrown off, the ostia are generally closed, the caliber is enlarged, and the tube is filled with a caseous mass. The microscope reveals the characteristic formation of tubercles in the wall—nuclei centering around giant cells—and the presence of Koch's bacillus in the tissue and in the secretion. Often the peritoneum in the vicinity is studded with miliary tubercles. In advanced cases the whole mucous membrane is destroyed. The tubes are in general out of place, often drawn down along the edges of the uterus, and bound to neighboring parts by adhesions. They may form tumors as large as a goose-egg, the shape of which is that of a sausage, a club, or most frequently a string of 3 to 5 beads, the single knobs of which are round or oval and hard, while in pyosalpinx they are soft. Another point of difference between the two is that in pyosalpinx the inner part of the tube is nearly always free, while in tuberculosis the disease affects this part and even the intramural portion as well.

Sometimes tubes, ovaries, and uterus are all matted together by exudation into one large mass.

The disease is very rarely *acute*, in general it has a *chronic* course.

The *symptoms* are like those of salpingitis.

The *diagnosis* is often obscure, but occasionally it may be made by reference to hereditary predisposition, by finding signs of tuberculosis in other parts, especially the lungs, by finding caseous masses and bacilli in the vaginal secretion, and by the peculiarities of the tumor just mentioned.

Treatment.—As a prophylaxis connection with a man affected with tuberculosis should be avoided. The *hygienic* and *medical* treatment is the same as for tuberculosis in general. If the general condition of the patient is not too bad, *salpingo-oöphorectomy* may perhaps effect a cure; but on account of the adhesions the operation is often difficult and sometimes impossible. If the uterus participates in the degeneration, this may be removed together with the tubes and ovaries. But as it is uncertain if all affected tissue has been removed, and as the operation itself by rupture of the tube and entrance of its contents into the peritoneal cavity may spread the infection, the treatment, upon the whole, is unsatisfactory. The presence of tubercular peritonitis or a mild degree of phthisis is no contraindication for the operation.[1]

[1] An exhaustive monograph by J. W. Williams on "Tuberculosis of the Female Generative Organs" is published in *Johns Hopkins Hospital Report in Pathology*, ii., Baltimore, 1892, pp. 85–144.

PART VI.

DISEASES OF THE OVARIES.

CHAPTER I.

MALFORMATIONS.

Excessive Growth.—The ovaries of new-born children may have twice the normal size, which may either be due to a uniform hyperplasia of all the constituent parts, or, more frequently, to fetal inflammation, resulting in a preponderance of connective tissue and a partial or total disappearance of the Graafian follicles.

Supernumerary Ovaries.—Small globular, pedunculated bodies of the same structure as the normal ovaries, and varying in size from that of a pea to that of a hazelnut, are found in 5 per cent. of all bodies of women. These small ovaries are situated near the peritoneal border of the normal ovaries.

An ovary may be more or less completely divided into two parts by fissures. In a unique case there were even found three large ovaries, each bound to the uterus with a separate ligament.

The possibility of supernumerary ovaries must be kept in mind in order to explain the persistence of menstruation after the extirpation of both ovaries (pp. 118 and 515), the presence of two normal ovaries besides an ovarian cyst, and the occurrence of pregnancy after double ovariotomy — phenomena which have actually been observed.[1]

Absence or Rudimentary Development.—Both ovaries may be absent, a condition which usually is combined with absence of the uterus. One ovary may be absent in cases of uterus unicornis.

More common than the total absence is a rudimentary development of the ovary. Such rudimentary ovaries may or may not contain Graafian follicles. In the latter case they consist only of connective tissue and smooth muscle-fibers.

As a rule, the rudimentary condition is found in connection with an arrest of development of the uterus, but it may also be found when

[1] For details see my article on "Malformations of the Female Genitals," in *Amer. System of Gynecology*, edited by Mann, vol. i. p. 236.

the uterus is normal. Women without Graafian follicles do not menstruate, and are sterile, but may have sexual desire and a perfect female type.

Rudimentary ovaries are often found together with an imperfect development of the large blood-vessels, especially the aorta, or of the central nervous system, especially in idiots and cretins.

CHAPTER II.

Displacements.

One or both ovaries may occupy an abnormal position. In its unusual place the ovary may have preserved its normal connections, or it may have been cut off altogether from the broad ligament by an inflammatory process in fetal life. It may then either float about as a small hard body in the abdominal cavity or it may become fastened to the lower border of the omentum.

If the displaced ovary retains its normal connections with the ala vespertilionis and the tube, it may be found outside the pelvis or remain in it.

Extrapelvic Displacements.—It may be found in the *lumbar region*, or, passing through the same openings as other herniæ, it may occupy the inguinal canal or the labium majus (*inguinal hernia*); the anterior side of the thigh below Poupart's ligament (*crural hernia*); the gluteal region (*gluteal hernia*); the depth of the anterior wall of the pelvis (*obturator hernia*), or the anterior surface of the abdomen (*ventral hernia*).

The position of the ovary in the lumbar region is very rare. It is due to a lack of descent (p. 23), and is only found together with a considerable arrest of development in other respects.

Inguinal hernia of the ovary may be congenital or acquired. The congenital may be due to a deficient development of the round ligament, by which the ovary, tube, and sometimes one horn of a uterus bicornis and part of the omentum are pulled through the canal of Nuck.

More rarely the ovary alone is found in a congenital inguinal hernia, into which it easily drops during intra-uterine life on account of being much smaller than the caliber of the canal of Nuck.

The acquired form can only occur if the tube and the infundibulopelvic ligament are unusually elongated and lax, and may then be produced by a fall or similar violence.

In its abnormal place the ovary may become inflamed or undergo cystic or cancerous degeneration.

Congenital inguinal hernia cannot be replaced. It may be pro-

tected by a hollow pad or, if it gives trouble, it may be extirpated. The acquired form may be brought back through the canal and kept back by means of a truss. If it cannot pass the canal, herniotomy should be performed. If the ovary is seriously diseased, it should be extirpated.

Crural ovarian hernia is always acquired. If the ovary cannot be replaced by taxis, herniotomy should be performed, after which a truss should be applied. It should only be removed, if it is so seriously affected that medical and palliative treatment must be without avail.

The other herniæ through natural openings are exceedingly rare. The ovary may be found in a ventral hernia after laparotomy, and would offer a special indication for operating on the hernia.

The ovaries may also be drawn with the tubes into the funnel of an inverted uterus (p. 448).

While the preceding displacements are anatomical or surgical curiosities, the *intrapelvic displacement* or *prolapse of the ovary*, is a common disease of considerable practical importance.[1]

The normal ovaries may frequently be palpated in their normal situation by bimanual vagino-abdominal examination. They may likewise be felt by recto-abdominal examination, but the latter offers no advantage except in intact virgins or women with atresia of the vagina.

When the ovary becomes displaced it sinks backward, downward, and inward, describing an arc with the ligament of the ovary as a radius and its insertion on the uterus as a center. Thus it sinks first down on the retro-ovarian shelf (p. 91), and next into Douglas's pouch, and may sink as low down as the level of the os uteri.

Etiology.—The left ovary is much more frequently prolapsed than the right, the cause of which is probably to be sought chiefly in the absence of a valve in the ovarian vein on this side, and its opening into the renal vein under a right angle—circumstances that favor passive hyperemia in the gland and predispose to disease (p. 74). The presence of the rectum on the left side and the motion of hard fecal lumps downward help also to dislodge the ovary.

The mere increase in weight of the ovary is sufficient to cause it to prolapse, as is proved by cases in which, after the subsidence of swelling, the organ returns to its normal place. It may be pushed out of place by tumors or drawn down by a retroverted or retroflexed uterus or by adhesions remaining after pelvic peritonitis. It may also sink on account of insufficient support from below, especially rupture of the vaginal entrance (p. 297).

[1] This disease has been treated of in an exhaustive way by P. F. Mundé, *Trans. Amer. Gyn. Soc.*, 1879, vol. iv. p. 164 *et seq.*

Prolonged sexual irritation may cause the prolapse by producing hyperemia.

Pregnancy offers particularly favorable circumstances for the production of prolapse, since the ovaries are enlarged and ascend into the abdomen, and their attachments become softened and elongated. Inflammation and beginning cystic degeneration increase the weight, and are often the cause of adhesions.

Whether a normal ovary can become prolapsed by a fall or similar injury, as is the case with the uterus (p. 441), is doubtful, but if it is enlarged beforehand, such a traumatic impulse is enough to cause the displacement.

Prolapse of the ovary is frequently associated with acquired anteflexion of the uterus, the cause of both troubles being probably subinvolution after pregnancy and the concomitant lack of tonus in the tissues.

It is also often combined with tubal disease.

Symptoms.—The symptoms are those of chronic oöphoritis combined with those due to the abnormal position of the ovary. Hyperemia, edema, and inflammation may be both the cause and the effect of the displacement. The patient complains of pain in the sides of the pelvis, the sacral region, or the rectum, often shooting down to the knee and up into the hip. It gets worse when she walks, prevents her from standing for any length of time, and is sometimes aggravated by sitting down. It is also increased very much by palpation, and may continue through the whole day upon which the examination has been made. This great tenderness also renders coition painful or impossible, causes great pain during the passage of hard fecal masses, and often painful tenesmus after they have been expelled.

Menstruation is, as a rule, painful and often too profuse.

Nausea and vomiting are not rare. The whole nervous system suffers much. The patient is tired, despondent, and irritable. Sometimes she may even have attacks of epilepsy.

Diagnosis.—The diagnosis is, as a rule, easily made by bimanual examination, when the ovary is recognized by its shape, its connection with the uterus, its great sensitiveness if it is inflamed, or at least a sickening feeling on pressure if it is normal. If the ovary is situated on the retro-ovarian shelf, it is felt best by examining the patient in the left-side position and pressing the perineum well back.

The *swollen tube* has a more sausage-like shape. A small pedunculated *fibroid of the uterus* is harder and not sensitive. Remnants of *pelvic inflammation* are more diffuse and less tender. *Scybala* are less tender, may often be indented or crushed, and may be removed by enemas and aperient medicines.

Prognosis.—The displaced ovary is liable to become inflamed or

cystic. If it is movable, the prognosis is comparatively good; but if it is bound in its new position by adhesions, the treatment will at best be a very protracted one, and a cure is doubtful.

Treatment.—The two chief indications are to combat hyperemia and inflammation and to replace and retain the ovary in its normal place. The first is aimed at by rest, keeping the bowels open (p. 217), prohibiting sexual connection, prescribing hot vaginal douches (p. 166), using scarification of the cervical portion (p. 182), making applications of iodine (p. 165), or inserting pledgets with ichthyol-glycerin (p. 173) into the vagina, or by means of galvanism with the positive pole in the vagina (p. 224).

The displaced organ should be replaced as soon as feasible, but sometimes the above-mentioned measures must be taken first before the ovary recovers sufficiently to be able to bear the pressure of a pessary.

The ovary is best replaced in the genu-pectoral posture (p. 136), and if it cannot be replaced or retained at once, the daily use of this posture and a glass tube admitting the air into the vagina (p. 434) may prepare the way for its final replacement.

If the ovary is adherent, it is necessary first to try to bring about the stretching and absorption of the adhesions. This is done by packing the vagina (p. 173). If the ovary is very tender at first, perhaps only a single cotton ball will be tolerated, but gradually more are put in, so as to lift the ovary up in the pelvis.

Massage (p. 187) is also a powerful means of stretching and breaking up adhesions.

The galvanic current has, in consequence of its electrolytic property (p. 224), a similar effect.

Schultze's method is somewhat similar to that used by the same author for uterine adhesions (p. 436). The forefinger is introduced into the rectum of the anesthetized patient in the lithotomy position, and bored in between the ovary and its surroundings, while the uterus is grasped with the other hand through the abdominal wall and pulled upward.

The retention of the ovary in its normal position is often more difficult than its replacement. Sometimes Thomas's hard-rubber *bulb-pessary*, essentially a Hodge pessary (Fig. 235, p. 433) with a thickened upper arch, answers a good purpose. Special pessaries of hard rubber with a crossbar of unusual width, or with a notch in the middle or a corner cut off, have been constructed for this condition.[1]

In cases in which no hard pessary can be tolerated, one of whalebone and soft rubber (p. 434) may be tried.

If these measures fail, we may have recourse to cutting operations. If the uterus is retroverted or retroflexed, it may be brought forward

[1] See the above-mentioned article by Mundé.

by shortening the round ligaments (p. 435) or fastening the fundus uteri to the abdominal wall (p. 438).

If the uterus is not displaced, but the ovarian displacement is due to an elongation of the infundibulopelvic ligament, that may be shortened by taking a reef in it (p. 440).

But if the ovary, besides being prolapsed, is diseased, the proper thing to do is to perform salpingo-oöphorectomy (p. 439).

CHAPTER III.

Hyperemia and Hematoma.

A normal hyperemia doubtless takes place in the ovary during coition in consequence of contraction of the unstriped muscle-fibers of the broad ligament (p. 57), and contributes to the expulsion of the ovum (p. 74). A similar normal hyperemia probably returns at regular intervals, corresponding to menstruation. At least the general blood-pressure of the whole system is increased before menstruation sets in (p. 116), and in some women a very considerable increase in size may be found alternately in one ovary or the other at the menstrual periods (p. 119). An effusion of blood also takes place normally into the ruptured follicle after the expulsion of the ovum (p. 71).

Pathological Anatomy.—Abnormal hemorrhage may take place into the Graafian follicles or into the stroma of the ovary, the follicular being much more common than the stromal. Follicular hemorrhage forms a tumor that is rarely larger than a hazelnut (Fig. 266), but may reach the size of a walnut.

The ovary is only moderately enlarged and a little more resistant. If many follicles are filled with blood at the same time, it is dark and studded all over the surface with small protuberances. The sac is thinned on the side nearest the surface. The contents are dark, thin blood mixed with clots. In the course of time it may change into a thick chocolate-colored fluid, which may be of the consistency of honey. The fluid part may be absorbed altogether, leaving a granular pigment; or the solid parts may be absorbed, so that only a cyst filled with serous fluid remains; or suppuration may set in. As a rule, the follicle does not burst, but the ovum is destroyed.

Stromal hemorrhage may cause so small an extravasation of blood that it can only be seen with the microscope, but it may impart a reddish color to the ovary, and even show as minute red points on the cut surface. On the other hand, it may gradually, by repeated new escapes of blood, destroy the whole tissue of the ovary, and form a hematoma as large as a man's fist or a child's head. In other cases the tissue is

preserved, but so infiltrated with blood that the whole ovary is like a sponge soaked in blood. Such enlarged ovaries are bound by adhesions to the neighboring organs. The stromal hemorrhage may be primary or follow as a secondary event after follicular apoplexy.

FIG. 266.

Hematoma of Ovary (a little less than natural size): *a*, follicular hematoma, 12 millimeters in diameter, inner measure; fresh blood-clot easily separated from the surrounding wall, situated in the outer end of the ovary, one-half of it touching the stroma, the other half covered with a layer varying from 2 to 3 millimeters in thickness, without any opening; *bb*, dilated follicles with serous contents; *c*, Fallopian tube.[1]

Any extensive hemorrhage may cause rupture of the ovary, the blood pouring into the peritoneal cavity or penetrating between the two layers of the broad ligament. The extravasated blood undergoes changes similar to those just described for the follicular form.

Etiology.—Hyperemia and hematoma of the ovary may be due to any thing that causes *venous stasis*, such as masturbation or venereal excesses, heart disease, pulmonary phthisis, cerebral apoplexy, tumors, adhesions compressing the veins, or torsion of the ala vespertilionis.

Secondly, they may be referable to *dissolution of the blood*, such as occurs in severe burns, phosphorus-poisoning, typhoid fever, puerperal septicemia, scurvy, etc.

[1] Left ovary from my salpingo-oöphorectomy on Mrs. P—— in St. Mark's Hospital, Nov. 29, 1892. The right ovary contained a serous cyst measuring 2 cm. in diameter.

Thirdly, hematoma may be developed from *gyroma*,[1] which is the same as corpus albicans (p. 74), and may be the terminal stage of a corpus luteum, or under influence of chronic oöphoritis may represent the first stage of an *endothelioma*, an abnormal formation, which will be described under Oöphoritis. Gyroma may occasionally lead to the formation of a hematoma, and endothelioma does so quite frequently.

Symptoms.—A patient affected with hyperemia of the ovary is liable to suffer from menorrhagia. At the time of menstruation she is seized with sudden pain in the region of the ovaries, extending down the thighs, and sometimes accompanied by neuralgia of the breasts. She has no fever.

Hemorrhage in the ovary may take place without giving rise to symptoms. If the collection is large, it causes pain, nausea, vomiting, and the ovary is felt to be enlarged. If rupture occurs, the usual symptoms of internal hemorrhage are present, such as shock, pallor, abdominal pain, a cold clammy skin, and a weak, rapid pulse. If a large hematocele is formed, a fluctuating swelling can be felt through the abdominal wall and the vagina.

Diagnosis.—Hyperemia or apoplexy may be diagnosticated, if in a healthy person one or both ovaries suddenly become enlarged and tender without fever. In a patient affected with blood-dissolution the apoplexy may be inferred, if she suddenly is seized with ovarian pain, and a movable tumor can be felt in the pelvis.

A periodical increase of suffering at the time of menstruation in a person with diseased ovaries is a sign of congestion.

The sudden appearance of the signs of internal hemorrhage in such a person denotes that rupture of the ovary has taken place.

An extravasation of blood into the broad ligament does not extend so high up as the tumor formed by intraperitoneal hemorrhage; indeed, it often forms a tumor at the base of the broad ligament.

A swollen Fallopian tube often is more sausage-shaped, whereas the ovary is more round.

Sometimes an aspirating needle may be thrust in through the vaginal roof, and the bloody fluid will then help to establish a diagnosis.

Prognosis.—Hyperemia can, as a rule, be cured. Hematoma may also be absorbed, but occasionally a rupture occurs, which may end fatally. If due to endothelioma, the whole constitution suffers, and grave nervous symptoms are developed. The normal ovarian tissue disappears gradually, and the ova are destroyed.

Treatment.—In hyperemia, rest, inclusive of physiological rest—

[1] This subject was first treated by Dr. Mary Dixon Jones, and has been corroborated by Dr. Francis Foerster and Dr. H. J. Boldt, all working under the egis of Dr. C. Heitzmann: Jones, *N. Y. Med. Jour.*, Sept. 28, 1889; May 10–17, 1890; *Times and Register*, Apr. 30, 1892; Foerster, *Amer. Jour. Obst.*, May, 1892, vol. xxv., p. 577; Boldt, *International Med. Congress*, Berlin, 1890, and *Deutsche Med. Wochenschr.*, 1890.

that is to say, abstinence from sexual excitement—is of great importance.

The general health should be improved by means of hygienic measures and tonics (p. 217). The nervous system may be quieted by the use of bromides. A derivation to the skin by means of blisters may be useful. The bowels should be kept open. In girls of ardent temperament or with bad habits marriage may answer a good purpose. The usual treatment for pelvic inflammation, such as the use of hot douches, painting with tincture of iodine, tampons with ichthyol-glycerin or plain glycerin, or the galvanic current, should be instituted. If there is an acute attack, the patient should stay in bed, have an ice-bag on the hypogastric region, and be given morphine enough to combat pain. If the ovaries have suffered much in their structure, it may even become necessary to remove them. When symptoms of rupture are present, laparotomy should be performed at once, and the ovary from which the hemorrhage comes should be extirpated together with its tube. The other ovary should be left, if it is not seriously diseased.

CHAPTER IV.

OÖPHORITIS.

OÖPHORITIS, the inflammation of the ovary, may be acute or chronic.

A. *Acute Oöphoritis and Ovarian Abscess.*

The inflammation may begin on the surface,—*perioöphoritis*,—which is identical with local peritonitis (although the ovary has no peritoneal covering, p. 65), in the follicles,—*follicular oöphoritis*,—or in the stroma,—*interfollicular oöphoritis*,—just as we have seen in regard to hemorrhage, with which it is in many cases connected in such a way that it is difficult to say which has preceded the other. The distinctive anatomical feature is here, as in the inflammation of other parts of the body, the infiltration of the tissue with small round cells, and, if suppuration supervenes, the presence of pus-corpuscles. To the naked eye the condition is in the beginning much like hyperemia; the ovary is enlarged and impregnated with a reddish fluid; later yellow points and streaks appear; and finally these melt together, and an abscess is formed. Of these there may be one or more. In puerperal and gonorrheal cases usually both sides are affected; in others, as a rule, only one ovary is inflamed.

Before pus is formed the inflammation may end in resolution, but the ovary rarely returns completely to its pristine condition. As a

rule, it remains enlarged by formation of new connective tissue or becomes smaller by subsequent cicatricial retraction—*cirrhosis*.

The ovum and the epithelium of the follicles undergo fatty degeneration. Sometimes they are transformed into small cysts with thickened walls, or they are destroyed, leaving a cicatrix. An abscess may destroy the whole ovary. As a rule, plastic lymph is thrown out as a superficial covering over the abscess in the depth of the ovary, and thus the organism is protected, but rupture may take place into the peritoneal cavity and cause general peritonitis. The pus in an ovarian abscess may be "laudable" or have an offensive odor due to absorption of gas from the rectum. It may become inspissated, and finally form an innocuous calcareous mass.

Etiology.—Extensive oöphoritis is a rare disease outside of the puerperal state. It may be *primary* or *secondary*. The primary may be caused by hyperemia and hematoma of the ovary (p. 539), by sexual excesses, or by sudden suppression of the menstrual flow (pp. 127, 229). It may also appear as part of a constitutional disease, such as the eruptive fevers, cholera, septicemia, whether puerperal or not, and poisoning with phosphorus or arsenic. It may follow minor operations, such as the use of the sound, the incision of the cervix, trachelorrhaphy, etc. The common course is that the inflammation first attacks the endometrium, then the tubes, and finally extends to the ovary; but it may also reach the ovaries directly through the lymphatics.

An ovarian abscess may even be due to a needle finding its way from the intestine into the ovary.[1]

Secondary oöphoritis may also follow after peritonitis, and most frequently it is due to gonorrheal infection, which latter works its way up from the vagina through the uterus and tubes.

Symptoms.—In most cases the symptoms are obscured by those of the accompanying disease, especially salpingitis or peritonitis. But sometimes it is possible to feel the ovary to be enlarged. It is the seat of a burning pain, radiating down to the knee, to the bladder, and the rectum, and it is exceedingly tender to the touch. The knee on the affected side is sometimes drawn up; occasionally there is a reflex pain in the breast, and nearly always nausea. Like orchitis in the male, oöphoritis may alternate with mumps.

An ovarian abscess gives rise to recurrent attacks of chills and fever. Sometimes the swollen ovary can be felt, and perhaps even fluctuation can be made out. The abscess may open into the peritoneal cavity, the intestine, especially the sigmoid flexure, the bladder, less frequently into the vagina, and rarely even through the abdominal wall.

Diagnosis.—It is seldom possible to make an entirely sure diagnosis. This can only be done if we feel the enlarged and tender

[1] Frank W. Haviland, *New York Med. Record*, Oct. 2, 1892, vol. xlii. p. 398.

ovary. In a *suppurating ovarian cyst* the symptoms are less acute. *Salpingitis* and *pyosalpinx* are sausage-shaped, the inflamed ovary and ovarian abscess globular. *Pelvic abscess* is situated lower down and absolutely immovable, while the ovarian abscess may be more or less movable.

Prognosis.—The prognosis in the common non-septic, acute oöphoritis is, upon the whole, favorable as to life, even if the disease rarely ends in complete resolution. The inflammation may subside in four or five days. The septic form is apt to form an abscess, and it is not rare that the abscess bursts into the abdominal cavity and causes death from septic peritonitis. If the abscess opens into the gut, the opening may close speedily, but sometimes a fistulous communication remains, which may give rise to exhausting fever. Since we have seen that the ova are liable to degenerate, we can understand that oöphoritis often leads to sterility. One attack is frequently followed by others, so-called chronic oöphoritis.

Treatment.—The patient must be kept quiet in bed. An ice-bag is applied over the affected part (p. 183). The bowels should be kept open with saline aperients (p. 217). Pain is to be combated with opiates, preferably hypodermic injections of morphine.

If the symptoms indicate the presence of an abscess, laparotomy should be performed and the ovary removed. Even if the ovary is adherent, the adhesions are fresh and can in all likelihood be separated. Some prefer, however, under these circumstances, if the ovary is within easy reach, to aspirate, make an incision, and drain from the vagina. Gehrung's treatment (p. 227) is also applicable to such cases. This vaginal treatment is less dangerous, but also less satisfactory in regard to complete recovery.

B. *Chronic Oöphoritis.*

By chronic oöphoritis is understood a chronic condition characterized by the remains of acute inflammation of and in contact with the ovary, congestion, and repeated attacks of acute inflammation.

Pathological Anatomy.—In most cases the ovary is enlarged to two or three times its normal size, and has an oval or globular shape. In others it is smaller than normal, forming an irregular shriveled mass. Very frequently it is more or less cystic (Fig. 267). The capillaries increase in size from the periphery toward the center, forming a structure like that of erectile bodies. The anastomosis between the ovarian and the uterine artery is dilated, which may explain the endometritis so often found combined with chronic oöphoritis. The ovisacs and the ova are often diseased or disappear. First medullary corpuscles are developed, and the yolk and the germinative vesicle

break down, leaving a granular mass; later fibrous connective tissue replaces the whole structure.

Sometimes the ovum undergoes colloid or waxy degeneration. The

FIG. 267.

Chronic Oöphoritis: *a*, cut surface of ovary studded with cysts; *b*, tube; *c*, pedunculated cyst hanging from the mesosalpinx.[1]

follicles may be transformed into cysts with a thickened wall and surrounded by indurated tissue. The albuginea is thickened, and often covered with an adhesive layer of peritonic origin. A single cyst may reach the size of an English walnut, and cause the absorption of the rest of the organ, so that the ovary is changed to an ovarian cyst. The fluid is serous and yellowish, or may by admixture of blood become thick and brown. The stroma of the ovary is harder, of a white color, and shows hyperplasia of fibrous connective tissue. The hyperplastic ovary is generally free; the atrophic, on the contrary, imbedded in adhesions, to the pressure of which its dwindling probably is due.

FIG. 268.

Chronic Oöphoritis (natural size): *a*, corpus luteum changed into cyst; *b*,*b*, yellow masses with remnant of central cavity; *c*,*c*, corpora nigra; *d*, albuginea.

[1] Specimen from my salpingo-oöphorectomy on Mrs. C. C——, in St. Mark's Hospital, on June 9, 1891.

The formation of cysts is probably caused by congestion at the menstrual period, if the blood-pressure is insufficient to rupture the follicle or the rupture is prevented by the thickening of the albuginea, perioöphoritic adhesions, or the too deep situation of the follicle in the stroma. Sometimes it can be seen that the cyst has formed in a corpus luteum (Fig. 268).[1]

Etiology.—Chronic oöphoritis is by far more common than acute. Often the acute inflammation forms the starting-point, and the reader is, therefore, referred to what has been said above (p. 534) in regard to the causes of that affection.

The disease is found most commonly in young women between twenty and thirty years of age. The left side is oftener affected than the right for the same reasons that we have given for the greater frequency of prolapse on this side (p. 527). A misplaced ovary is indeed more liable to the development of chronic oöphoritis than one in its normal situation. For the same reason retroflexion of the womb predisposes to it. It is often found together with an ovarian cyst on the other side.

Ordinarily, chronic oöphoritis is due to puerperal or gonorrheal infection. Other factors are venereal excesses, masturbation, and perhaps, unsatisfied desire. The abuse of alcoholic beverages seems also to produce the disease. Working on sewing-machines causes pelvic congestion, and may, therefore, become a cause of chronic oöphoritis. Syphilis has also been thought to be a cause of the disease—a supposition that has much to recommend it when we think of the frequency with which that disease localizes in other glands, and especially of the analogy with syphilitic orchitis.

Nothing is more common than to find extravasated blood by microscopical examination of even apparently healthy ovaries, and larger collections of this kind can hardly fail to elicit an inflammatory reaction in the surrounding tissue. Thus hyperemia and hematoma may lead to chronic inflammation of the ovarian tissue, and to the formation of cysts (p. 535).

Symptoms.—The symptoms are, as a rule, more or less masked by inflammation in the surroundings, especially salpingitis and local peritonitis, as well as retroflexion of the uterus.

[1] Besides the large corpus luteum which has been transformed into a cyst are found numerous small, generally oblong, yellow masses, in the centre of which traces of a cavity are still discernible, and two corpora nigra (p. 74).

For want of a more suitable place, I wish here to refer to the *calcification of corpora lutea.* Concretions of the bright yellow color characteristic of the recent corpus luteum have been found imbedded either directly in the stroma of the ovary or surrounded by a cyst-wall. They consist of a dense tissue impregnated with lime-salts. Occasionally these hard bodies may even be felt through the vaginal wall, and give rise to the impression that one has to deal with the sac of extra-uterine gestation, containing fragments of bone (Bland Sutton, *Amer. Jour. Obst.*, Dec. 1892, vol. xxxvi. p. 908, and H. C. Coe, *ibidem*, Feb., 1892, vol. xxv. p. 246).

Very frequently both ovaries are affected.

The patient complains of pain in one or both iliac fossæ, to which often sacral pain is added. At times it extends with a neuralgic character to the rectum, the bladder, the hip, and down to the knee. The whole leg may feel heavy. The pain is always increased at the approach of the menstrual period, and often during intercourse—especially if the uterus is retroflexed and the ovaries prolapsed—or during defecation and micturition. Any kind of exertion is badly borne. Some patients can hardly stand or walk for any length of time. In rare cases the pain appears regularly in the middle of the intermenstrual period. (Compare p. 404.)

Menstruation is often irregular and too profuse. When the follicles and ova are destroyed, there follows, on the contrary, a stage of amenorrhea.

Very often these patients are sterile or become so secondarily after the confinement or the abortion that gave rise to the disease.

Leucorrhea is quite common. The digestion suffers, the patient loses flesh, and the nervous system is much upset—disorders which may end in hysteria or hystero-epilepsy.

A woman of the laboring class affected with this disease undergoes an enormous amount of suffering, and her wealthy sister may by invalidism be confined to her bed or her room for months or years.

Diagnosis.—Often it is very difficult or impossible to tell if a mass we feel through the roof of the vagina is an ovary or a tube, or both matted together in one mass by peritonitic exudation. Sometimes we can, however, distinctly feel the enlarged or prolapsed ovary. It lies more laterally and backward, and is of oval shape, while the swollen tube is sausage-shaped and lies nearer the edge of the uterus. The ovaries, or at least one of them (p. 119), swell regularly before each menstrual period, and decrease after menstruation. The tenderness of the inflamed ovary is greater than that of any other part of the pelvis. The pain usually gets worse at the approach of the menses. How the examination should be made in difficult cases is described on p. 501.

Prognosis.—Chronic oöphoritis rarely leads to death, although it may do so when an abscess forms and ruptures. On the other hand, it rarely ends in perfect recovery. It is at best a very tedious disease, causing much pain for months or years, and it may even affect the mental condition, making the patient irritable, despondent, hysterical, epileptic, and weak-minded. It often entails sterility.

Treatment.—The treatment coincides in most respects with that for chronic salpingitis (pp. 509–510). The patient should abstain as much as possible from sexual intercourse, and stay in bed during menstruation. A depletion and much relief from pain are obtained by giving hot vaginal douches (p. 166), painting the vaginal vault with iodine

(p. 165), and applying cotton tampons with ichthyol glycerin (p. 173). If this does not effect a cure, the galvanic current should be tried. I use it, as a rule, in the vagina (p. 224), and make the current as strong as the patient can stand, which in most cases is up to 50 milliampères. Often scarification of the cervix (p. 182), or the application of a fly-blister, 2 to 4 square inches in size, every evening, to the iliac region, has a good effect. Massage (p. 187) has been much praised, and may undoubtedly do good by causing absorption of perioöphoritic adhesions that compress or pull on the ovary.

The medicinal treatment should above all consist in the administration of tonics (p. 217). The nervous troubles are often greatly benefited by the use of bromides. Chloride of gold has frequently seemed to me to reduce the size of the swollen ovary (p. 218). Rubbing with chloroform oil (p. 218) affords temporary relief from pain. A warm entire bath should be taken twice a week. For those who can travel a treatment with the strong iodine brine of Kreuznach or the iron moor of Franzensbad, Marienbad, or Schwalbach, combined with the change of air, new impressions, and the interruption of marital relations, is often followed by decided improvement.

This palliative treatment, carried out methodically and patiently, is of great value, but in some few cases nothing short of an operation will cure the patient. Even when laparotomy is performed, the ovaries need not always be removed. If the tubes are in a fair condition the ovaries may be incised, diseased parts cut away, cysts enucleated, and the wound closed again with a continuous suture of catgut. If the ovaries are prolapsed, they may be lifted up and fastened in a better position by stitching the round ligaments to the anterior abdominal wall.[1]

But if the ovaries are much diseased, and if the tubes are in a bad condition, the appendages should be removed on one or both sides (p. 512).

Appendix.—Gyroma and Endothelioma.—It is a peculiarity of the ovary that, examined microscopically, it shows so many variations that hardly two ovaries are alike, and it is, therefore, difficult to decide what is a normal structure and what represents an abnormal process. (See p. 72, foot-note.)

Two conditions have been described as diseases under the names of *gyroma* and *endothelioma*,[2] which are intimately connected with

[1] Polk, *Amer. Jour. Obst.*, Sept., 1891.

[2] M. A. Dixon Jones, "A Hitherto Undescribed Disease of the Ovary, Endothelioma changing to Angioma and Hematoma," *N. Y. Med. Jour.*, Sept. 28, 1889, and "Another Hitherto Undescribed Disease of the Ovaries, Anomalous Menstrual Bodies" (Gyroma), *ibid.*, May 10 and 17, 1890. Compare foot-note on p. 72. Gyroma is, however, doubtless the same that has been described by Patenko under the name of *corpus fibrosum* in *Virchow's Archiv*, vol. lxxxiv. p. 193.

each other, and one of which, endothelioma, under some circumstances, is a normal development.

Gyromas (Fig. 269) are convoluted, highly refracting masses, which in many instances replace most of the ovarian tissue. They are found both in the cortex and in the medulla (p. 67). In the former locality they are transformed corpora lutea—abnormal menstrual bodies—or corpora lutea of pregnancy (p. 71); in the latter they arise from

FIG. 269.

Ovary containing Corpus Luteum changed into Gyroma: *a*, cut surface of ovary; *b*, tube; *c*, gyroma.[1]

arteries which become obliterated by endartheritis. The convolutions of gyromas are in the former case due to the convoluted figure of the structureless membrane of the follicular wall after it has ruptured; in the latter they arise from the tortuous course of the arteries (Fig. 270).

Those that are developed from the corpora lutea are due to a transformation of the medullary corpuscles which are found outside and inside of the ruptured Graafian follicle (p. 72, foot-note). Instead of being absorbed or transformed into connective tissue, these medullary corpuscles become infiltrated with an elastic or colloid substance.

In the vicinity of a gyroma the blood-vessels are in an abnormal condition: the capillaries are large and straight, the veins dilated, and the arteries not infrequently suffering from obliterating endarteritis

[1] Specimen from my salpingo-oöphorectomy on Mrs. M———, in St. Mark's Hospital, on Dec. 14, 1889.

and waxy degeneration. Gyromas are not found in the cow, pig, or sheep, and are probably always a pathological production.[1]

Gyroma is found in all cases of endothelioma, but may also be found independently of the latter. Clinically gyroma is character-

FIG. 270.

Gyroma × 100 (Fr. Foerster): GG, gyroma traversed by delicate tracts of fibrous connective tissue: CC, newly-formed inflamed fibrous connective tissue; AA, arteries with slight sclerosis and hyaline degeneration; V. vein in transverse section; B, capillaries.

ized by pain in the ovarian region, exhaustion, and marked nervous disturbances, which may go so far as hysteria and mental aberration.

Endothelioma (Fig. 271) is always an outcome of ovulation, a growth of the structureless membrane of the follicular wall (p. 69). Similar formations are found in the pregnant cow, pig, and sheep. Some endotheliomas are, indeed, nothing but corpora lutea of pregnancy, but others are transformed gyromas, which, as we have seen, are always a pathological product. While gyromas may be found in an ovary in varying numbers, endothelioma is invariably single.

It is composed of large alveoli, or closed spaces, filled with endo-

[1] Dr. Dixon Jones thinks that what has been described as corpora lutea vera or corpora lutea of pregnancy (p. 71) is nothing else but anomalous menstrual bodies, gyromas and endotheliomas changing into angiomas and hematomas ("Another Hitherto Undescribed Disease," reprint, p. 24)—a rather startling supposition (see p. 72).

thelial cells. The wall of the alveoli consists of coarse fibrous connective tissue, richly supplied with blood-vessels. The endothelial cells are globular, fusiform, or polyhedral corpuscles, mainly arranged

FIG. 271.

Endothelioma of Ovary (Jones); *C*, coarse connective tissue containing *V*, large blood-vessels, mainly venous in character; *S*, septum or prolongation of connective tissue into a closed space filled with globular and angular corpuscles in rows; between the rows there are fat-globules and empty slits; *A*, cellular elements.

in rows and intermixed with dark brown fat-globules and pigment-granules.

The rows are in many places interrupted by light gaps, probably caused by liquefaction of some of these cells.

In the vicinity of an endothelioma there are large varicose veins and often aneurismatic arteries, which occasionally rupture, and cause hemorrhage under the albuginea or into adjacent cysts.

Sometimes some of the cells are transformed into red blood-corpuscles, while others fuse together, forming vessels around the new-formed blood. (See Hematoma, p. 532.) The endothelial growth replaces gradually the normal ovarian tissue, and may occupy the whole

ovary, which, however, is not much increased in size, and sometimes even smaller than normal. The ova are diseased or destroyed.

The clinical features of endothelioma are lancinating pain in the region of the ovary, progressive emaciation, pronounced pallor, and great weakness.

By destroying the patient's health and rendering her sterile the affection is of great importance.

Both gyroma and endothelioma originate in chronic oöphoritis, and, again, they cause inflammation in the surrounding tissue. Some pathologists take endothelioma to be a variety of carcinoma, which fits well with the clinical aspect.

As the presence of these conditions can only be proved by microscopical examination, they cannot be a guide in regard to treatment, but when, after oöphorectomy, they are found in the removed ovaries, they bear witness to the justifiableness of performing the operation.

CHAPTER V.

NEOPLASMS.

THE ovaries are very frequently the seat of neoplasms. Some are *cystic*, others are *solid*.

A. *Cysts.*

Pathological Anatomy.—Ovarian cysts offer a great variety in their anatomical structure, but they may, nevertheless, be reduced to a few types:

I. *Dropsy of the Graafian follicle* (*hydrops folliculi*), assuming one of three forms: 1, a conglomeration of many small cysts in the interior of the ovary; 2, a similar formation, but with pedunculated cysts, by which the whole ovary may become like a bunch of grapes (*Rokitanski's tumor*); and 3, the development of a few or one large cyst; II. *Proliferating* cysts, occurring in three varieties: 1, *glandular*, 2, *papillary*, and 3, *mixed:* III. *dermoid* cysts; and, IV. *tubo-ovarian* cysts.[1]

[1] While the author was collecting materials for his work on *Diagnosis of Ovarian Cysts by means of the Examination of their Contents*, he had the advantages of witnessing all the ovariotomies performed in the Woman's Hospital in the State of New York during eighteen months, and of obtaining a part of the fluid and the sac and the ovary of the opposite side when it was diseased. Not only was the fluid examined chemically and microscopically in every case, but many hundreds of specimens were cut from the hardened sacs or small ovaries. In that work he refers also in many places to the solid part of ovarian cysts, and if other occupations have prevented him from increasing the material and utilizing it for a special essay, his personal acquaintance with all stages of cystic degeneration of ovaries has enabled him to better understand and value the work of other investigators in this domain.

I. *Dropsical Graafian Follicles.*

In studying chronic oöphoritis we have seen (p. 535) that often in that disease many small follicles may be transformed into cysts, and

FIG. 272.

Ovary with many Dropsical Follicles (Leopold).

that a single follicular cyst may cause the absorption of the rest of the ovary. Thus there is a gradual transition from oöphoritis, an

FIG. 273.

Bilateral Oligocystic Ovarian Tumors (Hooper).

inflammatory disease, to cystic degeneration, a neoplasm, and it is in reality, in some cases, only the size of the specimen which decides us in calling the disease by one or the other name. The proof that a cyst is of follicular origin is the presence of the ovum; and by the conformity of the structure and the fluid we are led to regard larger cysts,

even when the ovum has disappeared, as being developed from follicles.

If many follicles are affected simultaneously (Fig. 272), the ovary does not obtain very large dimensions, indeed hardly more than the size of an hen's egg. The stroma may be unchanged or infiltrated with medullary elements. Gradually it is absorbed.

FIG. 274.

Rokitanski's Tumor, one-third actual size (Tait); on the right is seen the adherent omentum.

Sometimes a few follicles become cystic, forming what is called an *oligocystic tumor* (Fig. 273). Very rarely the partition between two

such cysts ruptures, so that they communicate. As a rule, only one is developed; or, predominating in its development, causes the atrophy and disappearance of the others.

If only one follicle undergoes cystic degeneration, it may form a tumor of the size of a man's head or even a uterus at term.[1]

Such a large cyst is strictly monocystic. Nowhere are found remnants of partitions. The *wall* is white, and consists of two layers of dense fibrous connective tissue held together with a layer of loose connective tissue, in which run blood-vessels. The arteries are thickened in consequence of endarteritis. These two layers correspond probably to the tunica propria and the combined tunica fibrosa and albuginea (p. 68). The outside is covered with a short columnar epithelium; the inside has a similar epithelium with somewhat longer cells.

The *fluid* is serous, alkaline, and almost colorless. It does not coagulate spontaneously nor by heat. It contains paralbumin, the presence

FIG. 275.

Ovaries with Pedunculated cysts (Winkel): *a*, anterior wall of uterus cut open, showing a primary sarcoma of the body; *b*, *c*, ovaries with multiple pedunculate cysts; *d*, *e*, tubes; *f*, posterior wall of bladder.

of which is characterized by its precipitation when the fluid is boiled with a small amount of acetic acid, the precipitate being redissolved by adding an excess of the same reagent. It contains only a few granules and no cellular elements.

These monocystic and oligocystic tumors are much rarer than the proliferating and dermoid cysts.

Rokitanski's Tumor (Fig. 274).—Much rarer still is that species

[1] I have seen it contain a pailful of fluid (*Diagnosis*, p. 9).

of ovarian cystic tumor which from the name of the man who first described it is called Rokitanski's tumor. In fact, only a few cases are known. This seems always to be a bilateral affection. The tumors grow slowly. They are of moderate size, between that of the fist of a man and that of the head of a four-year old child. They are composed of innumerable cysts varying from the minutest size to that of an orange. The wall is thin and lined with columnar epithelium; the contents are limpid; and the ovum is nearly always found in every cyst.

The cysts may become more or less pedunculated, so as to impart to the whole tumor the appearance of a bunch of grapes.

FIG. 276. *A.*

FIG. 276. *B.*

A. Inner Surface of Glandular Ovarian Cystoma (partly diagrammatic) x 120; *a*, connective tissue; *b*, epithelium; *c*, bowl-shaped depression with small opening; *d*, a similar one, the opening closing up; *e*, *f*, buds of epithelium, growing from the bottom of the bowl; *gg*. depressions in the connective tissue, from which the epithelium has been removed.
B. Same as *c* in Fig. 276 *A*, enlarged 360 times. It is composed of two pouches uniting at the top. The centre of each is undergoing liquefaction. A kind of thready material is seen extending from the periphery into the interior of the pouch between the epithelial cells (cement substance).

Fig. 275 shows the ovaries with a few pedunculated cysts on the surface.

II. *Proliferating Cysts.*—Proliferating cysts are also called *myxoid cystomas*, in opposition to the dermoid cystomas, because their inner surface resembles a mucous membrane. The epithet "proliferating"

has been given them because they, differing entirely from the above-described large cysts due to dropsy of the follicle, which are strictly monocystic with a smooth inner surface, produce new cysts or papillary growths from their inner surface. With regard to these two different kinds of proliferations the myxoid cystomas are again subdivided into two groups—*glandular* myxoid cystoma and *papillary* myxoid cystoma.

a. Glandular ovarian cysts have a wall composed of the same two layers we found in the case of follicular dropsy, and a similar external epithelium, but the internal epithelium undergoes a remarkable proliferation, which results in the development of gland-like growths. This epithelium is polymorphous; that is to say, different forms of cells—columnar, goblet-shaped, and flat—are found in it, but the long columnar is the predominating variety. It is stratified and forms pouches, which at first are placed regularly side by side, and are of about the same size (Fig. 276); but in consequence of the continued proliferation of the epithelial cells some of these pouches become closed, thus forming a *secondary cyst* in the wall of the primary cyst. At first, it is a nearly solid mass of epithelial cells, but soon the cell-body begins to melt, setting the nucleus free (Fig. 277), and forming a fluid in the secondary cyst. This

Fig. 277.

Melting of Epithelial Cells in Secondary Cyst in the Wall of an Ovarian Cyst.

process can be followed under the microscope, and, by analogy, we may infer that the same takes place in the primary cyst. When the secondary cyst is formed, the same process of proliferation is repeated, so that continually one generation of cysts is formed in the wall of another.

Simultaneously with this production of new cavities a reduction in their number takes place by the absorption of the partition which separates two cysts from one another. At first there is only a small hole of communication between the two sacs, but gradually the open-

FIG. 278.

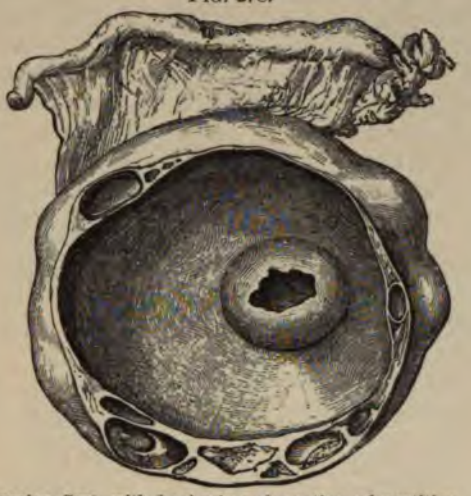

Small Glandular Ovarian Cyst, with beginning absorption of partition. Slightly reduced from natural size (Doran).

FIG. 279.

Large Glandular Ovarian Cyst, showing numerous secondary cysts and ridges as remnants of absorbed partitions: *a*, primary cyst turned inside out and stuffed with cotton; *bb*, secondary cysts; *cc*, remnants of absorbed partitions.[1]

[1] Specimen from my ovariotomy on Mrs. M. S———, at St. Mark's Hospital, Aug. 14, 1890. It contained sixteen quarts of fluid.

ing increases in size until, finally, only a low ridge remains as a remnant of the former partition (Figs. 278 and 279).

By this continual proliferation of epithelial cells, formation of new cysts, and absorption of partitions very large tumors are formed, in which, as a rule, one cyst predominates, but there are invariably found a greater or smaller number of secondary cysts in its wall. These cysts are, therefore, always *multilocular* from a pathological standpoint, even if from a surgical they may be regarded as unilocular.

The healthy ovarian tissue disappears entirely as soon as the tumor reaches a few inches in diameter.

The glandular variety is by far the most common, and forms the largest tumors of all. Their growth may, indeed, become so enormous that they weigh more than the rest of the body (Fig. 280).[1]

FIG. 280.

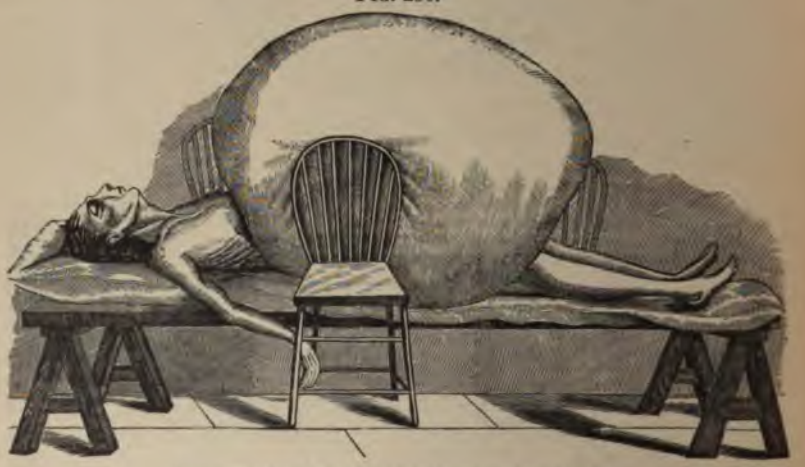

Enormous Glandular Ovarian Cystoma (Rodenstein).

Fig. 281, on the other hand, represents such a glandular cystoma found in a new-born child, and enlarged thirty times.

The outer layer of the wall corresponds to the albuginea, is smooth, of dense texture, a pearl-gray or white color, and takes no part in the formation of secondary cysts, which exclusively takes place in the inner layer.

The inner layer furnishes the connective tissue which, together with the inner epithelium, enters into the composition of the secondary cysts. It is of a reddish color, slightly uneven, and velvety like the inside

[1] The figure represents the patient after death at the age of forty-five years. The tumor stood three feet high, covered the breasts, went down to the knees, and weighed 146 pounds (Dr. L. A. Rodenstein, *Amer. Jour. Obst.*, 1879, vol. xii. p. 315).

of the stomach. Often it is brown from impregnation with extravasated blood, or yellow in consequence of fatty degeneration. Sometimes it has hard spots, due to calcareous infiltration.

FIG. 281.

Congenital Multilocular Cystoma, × 30 (Winckel).

From the outer layer may grow small excrescences, covered with the common short columnar epithelium (Fig. 282).

FIG. 282.

Papillomatous Excrescence on Outer Surface of Myxoid Proliferating Glandular Cystoma of Ovary (natural size): A, seen from above; B, sagittal section of the same, with part of cyst-wall, showing that the papilloma was only connected with the outer part of the wall, and did not spring from the interior of the cyst: *a*, papilloma, sagittal section through pedicle; *b*, main cyst; *c*, secondary cyst, partially filled with cheesy contents, partially empty; *d*, secondary cyst with cheesy contents.

In the loose connective tissue between the two layers of the wall are found plain muscular fibers, especially near the ligament of the ovary. Sometimes cysts have been found there, and even a corpus luteum.

The glandular cystoma has, as a rule, a pedicle.

Relation to Cancer.—Being a neoplasm chiefly composed of epi-

...nnett's
...thelial

...ity

...to the

thelial cells and a stroma of connective tissue, the glandular cystoma approaches the structure of carcinoma. The difference is that glandular cystoma does not affect the lymphatic system, does not give rise to relapse after extirpation, and has the tendency to produce more or less fluid in its compartments. If, however, the epithelial proliferation predominates much, and the formation of cysts stops, the condition is passing into that of carcinoma. The appearance in the wall of epithelial cells of much larger size than those commonly found in the wall of ovarian cysts is likewise characteristic of beginning carcinoma.

Contents of Glandular Cysts.—In microscopical new-formed cysts nearly the whole body is one solid mass of epithelial cells. As a rule, the contents become more fluid as the cyst grows, but there are tumors called *parvilocular*, in which each compartment never reaches any considerable size. The whole tumor is like a honeycomb, and the contents never become more fluid than a thick gelatinous mass, in which even the microscope fails to find any structure.

The fluid in common ovarian cysts is of a gray, yellow, or brown color. It may be limpid as spring-water, or so filled with solid bodies as not even to be translucent. Usually it is more or less viscid. The specific gravity of the specimens examined by me varied from 1013 to 1062. Its reaction is alkaline. As a rule, it does not foam much, if at all, on being withdrawn from the cyst.

Fig. 283.

Red Blood-corpuscles.

Generally ovarian fluid does not coagulate spontaneously; but by being boiled, as a rule, the contents are more or less completely turned into a solid mass. Ovarian fluid possesses a remarkable degree of resistance to decomposition: while in ascitic fluid all form-elements are destroyed within a few days, in ovarian fluid they are sometimes preserved for weeks or months. The fluid contains nearly always paralbumin.

As a rule, ovarian fluid is full of a variety of form-elements: red blood-corpuscles, epithelial cells (either intact or metamorphosed), nuclei, pigment-granules, finely granular globular bodies like lymph-corpuscles or colorless blood-corpuscles, pus-corpuscles, spindle-shaped cells, crystals of cholesterin and of indican. Figures 283–296 show most of these bodies. A few remarks about them will suffice.

Besides the well known common shape of red blood-corpuscles we find crenated, rosette-shaped, thorn-apple-shaped, and hematoblasts (Fig. 283).

Epithelial cells (Fig. 284) are almost constantly found. They are columnar seen in side view, and multangular in front view. All show signs of fatty degeneration. When this process reaches a high degree,

FIG. 284.

Epithelial Cells, single and grouped, in front and side view.

the epithelial cells appear as so-called *gorged corpuscles*, or *Bennett's large corpuscles* (Fig. 285). Often vacuoles are formed in epithelial

FIG. 285.

Bennett's Large Corpuscles, or Nunn's Gorged Corpuscles—*i. e.* epithelial cells in fatty degeneration,

cells, which probably are a kind of disintegration leading to the destruction of the cells.

FIG. 286.

Colloid Corpuscles.

Colloid corpuscles (Fig. 286), large and small, are probably either parts detached from epithelial cells or a transformation of the whole cells.

FIG. 287. FIG. 288.

Horn-cells. Proliferating Cells.

Horn-cells (Fig. 287) are epithelial cells that have lost their protoplasm, have sharp ridges, and look horny.

FIG. 289. FIG. 290.

Ameboid Bodies. A Large Bennett Corpuscle with ameboid movements.

Proliferating cells (Fig. 288) are large cells containing a brood of younger ones in their interior, from which they escape to lead an independent existence.

FIG. 291.



Bennett's Small Corpuscles, or Drysdale's Corpuscles—*i. e.* nuclei in fatty degeneration.

FIG. 292. FIG. 293.

Cells with nucleus and fine dark granules (enlarged colorless blood-corpuscles?) Flakes of epithelium, the cells melting and setting the nucleus free.

In quite fresh fluid it is not rare to find cells with ameboid movements. In Fig. 289 we see the same two cells in three different stages of separation and amalgamation.

FIG. 294.

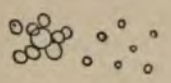

Fat-granules.

FIG. 295.

Spindle-cells from a myxofibromatous ovarian cyst.

Drysdale's corpuscles (Fig. 291) are small globular or polyhedral clear bodies with a small number of shining granules. My inves-

FIG. 296.

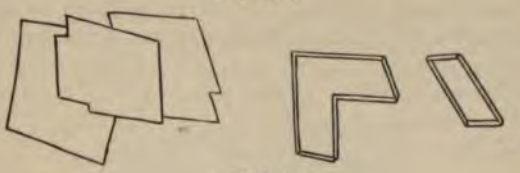

Cholesterin.

tigations have led me to believe that these bodies are nuclei of epithilial cells in fatty degeneration (Fig. 293).

Ovarian fluid contains also round cells with a nucleus and finely

FIG. 297.

Papillary Ovarian Cyst springing from the hilum of the ovary, the greater part of which is not involved in the morbid growth. The cyst has forced its way between the layers of the broad ligament as far as the Fallopian tube (Doran).

granular protoplasm (Fig. 292), the nature of which is uncertain. Perhaps they are enlarged colorless blood-corpuscles.

b. Papillary Ovarian Cysts are by far not so common as glandular, being found in only one out of ten ovariotomies, and do not acquire so large proportions. They contain a comparatively small number of secondary cysts. From their inside spring dendritic or cauliflower-shaped growths, called papillomas (Fig. 297), which may fill the secondary cyst in which they grow, and break through its wall into a neighboring cyst, or perforate the wall of the primary cyst, so as to come to lie in the peritoneal cavity, where they may cover the outside of the ovary and neighboring parts.

They may even penetrate the uterus, the bladder, the rectum or other viscera, so as to form one mass with them. The ends of papillomatous growths may also coalesce in the interior of the cyst, thus forming a separate compartment or secondary cyst.

The papillæ range in size from that of a pea to that of a small orange. They are sessile or pedunculated, white, dark red, or black.

The inside of papillary cysts is usually lined with a ciliated epithelium, and the fluid in their interior is not viscid or colloid, but more watery.

This kind of tumors is often bilateral, and develops in a consider-

FIG. 298.

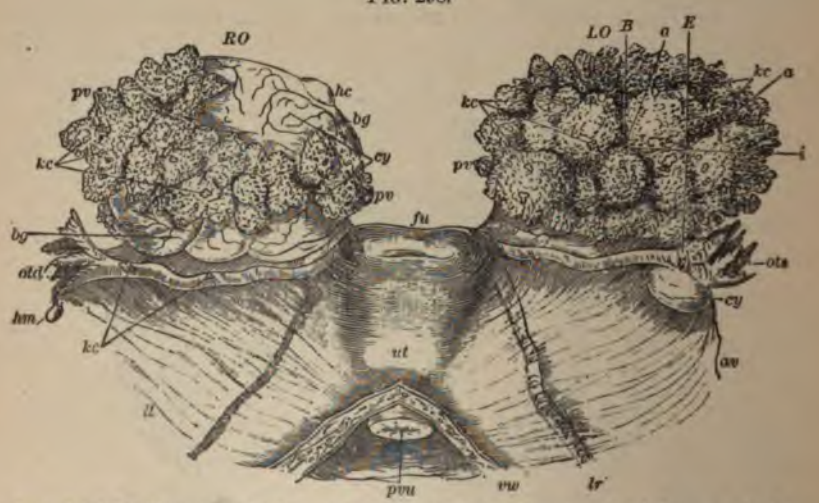

Superficial Papillomata on both ovaries (Coblenz): *RO*, right ovary; *LO*, left ovary; *fu*, fundus uteri; *hc*, hyaline cyst; *pv*, papillary vegetations; *cy*, cystic tumors; *bg*, blood-vessels; *hm*, hydatid of Morgagni; *otd*, abdominal orifice of right tube; *ots*, abdominal orifice of left tube; *kc*, calcareous deposits; *il*, broad ligament; *lr*, round ligament; *av*, infundibulo-pelvic ligament; *ut*, uterus; *pvu*, vaginal portion of uterus; *vw*, vaginal wall laid open.

able number of cases between the folds of the broad ligaments. The development is much slower than that of the glandular variety. It

is often accompanied by ascites, and, if removed by tapping, the fluid reaccumulates in a short time.

It is not rare to find grains of a sand-like substance in the papillomatous masses, so-called *corpora arenacea*, or *sand-bodies*, like those forming in the brain the tumor called a psammoma.

In this variety normal ovarian tissue is preserved longer than in the glandular.

Superficial Papillomata.—Papillomata on the outside of an ovary are not always due to rupture of a papillomatous cyst. They may also develop originally on the surface (Fig. 298).

c. Mixed Proliferating Ovarian Cysts.—In one and the same cystoma some cavities may be of the glandular type, others of the papillary. Thus there seems not to be any radical difference between the

FIG. 299.

Portion of the Wall of a Dermoid Ovarian Cyst (Ziegler): *a*, wall; *b*, elevation composed of of fatty and cutaneous tissues; *c*, hairs; *d*, teeth.

two varieties—a point to which we shall come back in speaking of the origin of ovarian cysts. From the history of the development of the ovaries (p. 26) we know that from a very early period these bodies are built up of two elements—epithelial cells and connective tissue. In the glandular cystoma the former predominates, in the papillary the latter.

III. *Dermoid Cysts.*—Dermoid cysts differ entirely from all those

hitherto described, both as to sac and contents. While in the other kinds of cysts the inner surface reminds one of the mucous membrane of the intestinal canal, in the dermoid variety it is like skin, not only in general appearance, but in regard to the elements that enter into its composition (Fig. 299). Thus the inside is covered with a thick layer of stratified epidermal cells, the most superficial flat and without nuclei, the deeper round or polyhedral. Outside of this comes a layer like derma, then one of subcutaneous adipose tissue, and finally a layer of fibrous connective tissue corresponding to the outer layer of other ovarian cysts. The derma is often raised in more or less regular papillæ. It may contain sudoriferous glands, with ducts opening on the inner surface, or sebaceous glands opening into the sheaths of hairs. Such hairs spring often from a small prominence and may form a switch several feet long, rolled up into a ball, and usually of a reddish yellow color. In other places may be seen teeth, often in large number (up to three hundred have been found in one cyst). Sometimes several teeth together are inserted in one piece of bone. Even a kind of shedding may go on, a tooth with a decaying root sitting over a young healthy one, just as in the mouth the milk-teeth are eroded and thrown off by the permanent teeth.

If there are many teeth, the bicuspid form predominates. If there are only few, they are generally like the incisors or canines.

Besides these attributes of the skin, many other tissues, or even simulacra of organs, have been found in the wall of dermoid cysts: bones (usually of the flat type), cartilage, striped and plain muscle-fibers, gray brain matter, nerves going to the teeth, mucous membrane like that of the intestine, a body like the submaxillary gland, a breast with papilla, a metacarpus with articulations, a trachea, a heart with mitral valve, columnæ carneæ and chordæ tendineæ,[1] and even an eye.

The outer surface of a dermoid cyst is, as a rule, of a dull gray or greenish color with orange or ocherous patches.

Dermoid cysts are small or of medium size, rarely exceeding that of the head of an adult.

Commonly only one ovary is affected, but the occurrence of the disease on both sides is not rare.

Two or three dermoid cysts may develop in the same ovary. In the course of time, when the separate cysts grow, the partitions between them are absorbed, and they are blended into one.

A dermoid cyst may form adhesions and rupture into another organ or on the surface of the body. If it opens into the bladder, hairs may be eliminated with the urine (*pilimiction*).

Dermoid cysts may give rise to metastasis in the shape of small yellow nodules on the peritoneum, of characteristic composition.

A dermoid cyst in one ovary may be combined with a proliferating

[1] A. W. Johnstone, *Trans. Amer. Gyn. Soc.*, 1893, vol. xviii. p. 305.

myxoid cystoma in the other. In the same ovary some compartments of a cyst may have the dermoid, and others the myxoid type. Nay, the two kinds may be represented in one and the same small secondary cyst.

Contents of Dermoid Cysts.—The fluid contained in dermoid cysts is characterized by its richness in fat-globules and cholesterin. It may be so thick that it hardly can pass through a canula, and solidifies as soon as it is exposed to the air. It contains often lumps of solid fat, and in a few cases this has been found in the shape of a large number of balls of the same size and as round as billiard-balls.

This fluid has a nauseating odor. It does not give the reaction of paralbumin. It contains cholesterin, urea, oxalic acid, leucin, tyrosin, and xanthin.

Dermoid cysts are much rarer than proliferating cysts, less than 4 per cent. of ovarian tumors having this type.

Before puberty this is, however, the predominating variety. Frequently its occurrence is combined with an imperfect development of the genitals.

Similar cysts have been found in other parts of the body, such as the head, the neck, the sacrum, the pit of the stomach, the perineum, the testicle, the uterus,[1] the organs of the chest, and other abdominal organs, etc.; but they are more frequent in the ovary than anywhere else.

IV.—*Tubo-ovarian Cysts,* or *Hydrocele of the Ovary.*—Tubo-ovarian cysts consist of a combination of a cystic salpingitis (p. 517) with a cyst of the ovary. They have the shape of a retort. The line of demarkation between the two organs is, as a rule, distinctly visible. The fimbriæ may have disappeared altogether or may be spread over the outer surface of the ovarian cyst; or we may find them inside, floating from the inner surface or attached to it from end to end.

The tubal part is covered with peritoneum, and the inner surface has in the beginning ciliated columnar epithelium, but later the cilia disappear, and the cells may become flattened.

The uterine opening commonly remains pervious, so that the contents may from time to time, when pressure increases, be evacuated through the vulva.

Bland Sutton[2] calls tubo-ovarian cysts *hydrocele of the ovary,* and says there is good reason to believe that they arise in a tunic of the peritoneum that occasionally invests the ovary, much in the same way that the tunica vaginalis clothes the testis. The ovary is replaced by

[1] W. W. Stewart of Columbus, Ga., *Med. Record,* Nov. 11, 1893, vol. xliv. No. 21, p. 648.

[2] Bland Sutton, *Diseases of the Ovaries and Tubes,* Philadelphia, 1891, p. 111.

a cyst which communicates with a distended tube, but the orifice of communication is an adventitious opening, and does not represent the abdominal ostium of the tube. What is usually called hydrops tubæ profluens this author calls *intermitting ovarian hydrocele.*

As a rule, the affection is unilateral.

All kinds of ovarian tumors may undergo this blending with cystic salpingitis. All that has been said above about the size of the tumor and the nature of the fluid of ovarian tumors applies, therefore, to tubo-ovarian cysts.

Probably a catarrhal salpingitis (p. 503) is a forerunner for the formation of this kind of cyst. A hydrosalpinx (p. 520) is formed, adhesion to the cystic ovary follows, the partition becomes atrophied, and finally the two cavities form one.

All ovarian cysts may be unilateral or bilateral. Dermoid cysts are oftener only found on one side; proliferating papillary cysts and Rokitanski's tumor, on the other hand, are nearly always bilateral. Even in unilateral cases of ovarian cysts the other ovary very frequently shows beginning cystic degeneration.

Pedicle.—Ovarian cysts in most cases rise up into the abdomen, and are connected with the uterus by means of a pedicle, which facilitates their removal. In some cases, however,—and we have seen that this applies particularly to the papillary variety,—the development takes place downward, so that the cyst is situated between the layers of the broad ligament, more or less close up to the uterus, and has no pedicle.

The pedicle of ovarian cysts varies much in size and composition. It may be long or short, thick or thin, broad or narrow. It contains always the ligament of the ovary and part of the broad ligament, and, as the tumor grows, the Fallopian tube is drawn in, so as to form part of it. The tube, as a rule, is both elongated and thickened. The arteries may become as thick as the radial, and the veins as a finger. Besides there are lymphatics, nerves, smooth muscle-fibres, and connective tissue, all forming a bundle covered by a peritoneal sheath.

Torsion of Pedicle.—The longer and thinner the pedicle is, the more easily it may become twisted, the tumor rotating around its perpendicular axis. Such rotation can only occur, if there are no adhesions, and the tumor is of moderate size. It is probably due to the peristaltic movement of the intestine, the differences in the state of emptiness and fulness of intestine and bladder, the irregular development of secondary cysts, by which the centre of gravity changes, and the movements of the patients. It is often caused by the development of the pregnant uterus. It is much more frequent with dermoid than other ovarian cysts.

Sudden twisting of the pedicle leads to gangrene and fatal peritonitis. If it develops slowly, it causes edema and hyperemia of the

wall, hemorrhage into the wall and the cystic cavity, or suppuration. The cyst-wall is dark red, nearly black. If the torsion continues, the whole pedicle may be severed, but in the mean time, as a rule, adhesions form with other organs, from which the tumor henceforth draws its nourishment. Even the uterus has been found as part of the severed mass.

The rotation of the tumor and twisting of the pedicle may involve the intestine, and cause its occlusion. On the other hand, the twisting may effect a cure of the cyst by causing atrophy, fatty degeneration, and calcification of the diminished tumor.

Adhesions.—As long as the ovarian cyst is covered by its columnar epithelium, it slides freely over the surfaces with which it comes in contact; but, when the epithelium is rubbed off or covered by inflammatory exudation, adhesions to the surroundings, such as the bladder, the uterus, the intestine, the omentum, the liver, the abdominal wall, etc., are easily formed. These adhesions may be like long strings, which are easily torn or divided between two ligatures; or extend over a large surface, when they may place considerable difficulties in the way of the removal of the tumors. By extending downward between the layers of the broad ligament and into its base, the tumor may become adherent to the ureter and the large blood-vessels of the pelvis.

Ascites.—An accumulation of ascitic fluid in the peritoneal cavity sometimes accompanies an ovarian cyst, especially the proliferating papillary variety. The fluid may be mixed with blood, which is a sign of a deteriorated constitution.

Fusion.—When an ovarian tumor develops in each ovary, the two may become adherent to each other in the abdomen; the common partition may be absorbed, and the two form one tumor with this peculiarity that it has two pedicles, one attached to each cornu of the uterus.

Intraligamentous and Extraperitoneal Development.—We have seen that while most ovarian cysts have a pedicle, some are sessile. They develop downward between the layers of the broad ligament, and may extend far away from their base outside of the peritoneum, going in between the uterus and the rectum or the uterus and the bladder, and reaching the cæcum, colon ascendens, and even the kidney.

All kinds of ovarian cysts are liable to become *retroperitoneal* in this way, but this development is found most frequently in papillary proliferating cysts.

Hemorrhage.—At times more or less considerable amounts of blood may be poured into the cystic fluid, with which it mixes, and to which it imparts a dark red or brown color. This hemorrhage may come from erosion of vessels in the partitions which are being absorbed, from ulceration of the wall, or torsion of the pedicle.

Suppuration.—The wall of a cyst may become inflamed, and the contents changed to pus. This grave accident may be due to torsion of the pedicle, but is most frequently attributable to puncturing of the cyst without sufficient antiseptic precautions. It may be caused by puerperal infection or occur spontaneously. In the latter case pyogenic bacilli are supposed to have worked their way in from the outer world through the genital canal.

Rupture.—An ovarian cyst may burst and pour part of its contents into the peritoneal cavity, where a bland fluid is absorbed and eliminated, especially by the kidneys. Even thick colloid contents of cysts, if not mixed with blood or pus, do not irritate the peritoneum, although their absorption requires more time. But bloody, purulent, or ichorus fluid, as well as the contents of dermoid cysts, causes more or less violent peritonitis or death from shock.

The rupture into the peritoneal cavity may give rise to the formation of a metastatic tumor of the peritoneum, of which more will be said presently.

Rupture may also occur into the intestine, the stomach, the vagina, the bladder, the Fallopian tube, or through the abdominal wall, especially the umbilicus.

Under favorable circumstances the rupture may effect a cure of the disease.

Evidence of rupture is found in 8 or 10 per cent. of all ovariotomies. This accident may be due to a fall, a blow, a kick, or similar violence. It may also be caused by torsion of the pedicle, by great thinness and brittleness of the wall, by the development of unusually numerous secondary cysts or perforating papillomata, fatty degeneration, or hemorrhage into the cyst.

Calcification and Ossification.—We have mentioned above (p. 551) that frequently calcareous incrustations form hard plates in the cyst-wall. This process may acquire such proportions that the whole tumor is changed into a hard shell, in which even bone-corpuscles may be found.

Cancerous Degeneration.—We have seen above (p. 552) that the proliferating glandular myxoid cystoma may become malignant. The same is the case with dermoid cysts, and when once degeneration into sarcoma or carcinoma has taken place, not only neighboring organs may be involved, but metastatic deposits may form in remote parts of the body. It has been found that 20 per cent. or more of all ovarian tumors become cancerous.

Metastasis.—Papillomatous cysts have a tendency to cause the production of small yellow nodules on the peritoneum. After removal of the tumor these may disappear or become innocuous by becoming calcified.

Glandular and dermoid cysts are much less liable to form such

metastases, except the glandular variety with gelatinous—*i. e.* semi-solid—contents. When in consequence of rupture of the cyst before or during operation part of the contents enters the peritoneal cavity, it has in some rare cases given rise to the formation of large gelatinous masses covering the peritoneum; which condition is called *pseudomyxoma of the peritoneum* (Werth) or *gelatinous disease of the peritoneum* (Péan).[1]

The gelatin is held in the meshes of fine membranes of connective tissue, which may be covered with endothelium or columnar epithelium, and carry fine blood-vessels. In some cases this formation may be explained as a transformed peritonitis, but in others it is certainly a growth of small solid particles of the tumor which go on forming a tumor in the peritoneum similar to the one in the ovary, from which they were broken loose at the time of the operation.

The Origin of Ovarian Cysts.—In speaking of the division of ovarian cysts into different classes (p. 544) we have seen that one class, the so-called dropsy of the Graafian follicles, is indisputably formed by a pathological development of one or more of such follicles. It is likewise sure that a corpus luteum may be converted into a cyst. As a rule, the cysts of this origin remain small as a hazelnut; but they may attain the size of an adult's head.

As to the second class, the proliferating cysts, there reigns yet considerable diversity of opinion in regard to their origin, and it is very likely that it differs in different cases. Microscopical examination has shown that both the glandular and the papillary variety may develop from a Graafian follicle. Another source may be the germinal epithelium, which in some ovaries, even of adults, forms pouches extending into the stroma of the ovary, much like the columns of epithelial cells giving rise to the primordial ova and primary follicles (p. 28). Even those tumors which have ciliated epithelium may have this origin, as part of the ovary, probably by extension from the tube, may have ciliated external epithelium instead of plain columnar. Some claim that the papillary cystomas are developed from remnants of the Wolffian body growing into the ovary from the hilum.[2]

The source of the glandular variety is by some thought to be a degeneration of the intima of the arteries in the ovary. Colloid deposits are often found in the stroma, the Graafian follicles, or a corpus luteum; but there is no evidence that they are the starting-point of proliferating cysts. We find, likewise, frequently small cysts without epithelium in the ovaries, but it is unlikely that formations of so epi-

[1] A case of the kind is described on p. 46 of my *Diagnosis.*

[2] In regard to the histogenesis of the papillary cystomata of the ovary a good synopsis of known facts and valuable new observations are found in articles by J. Whitridge Williams in *Johns Hopkins Hospital Bulletin*, No. 18, December, 1891, and *Report in Pathology*, II., Baltimore, 1892.

thelial a character as proliferating cystomas originate in them. It is not proved that connective tissue can be transformed into epithelium, and it is, therefore, unlikely that proliferating cystomas can develop from the stroma of the ovary.

As to the origin of dermoid cysts, the generally accepted theory is that of *invagination*. The ovary is developed from the axis-cord, in which it is impossible to distinguish the individual blastodermic layers. In the collection of mesoblastic cells destined to form the ovary may be included cells belonging to the epiblast, to the hypoblast or to other parts of the mesoblast than those required for the ovary. This happens most commonly with the epiblastic cells, which form epidermis, teeth, nails, hair, the cutaneous glands, and the central nervous system; more rarely with the mesoblastic cells, forming bone, cartilage, and muscle-tissue; and least frequently with the hypoblastic cells, whose rôle it is to form the epithelium of the intestine and the glands connected with it.

When not only extraneous tissue, but more or less perfectly formed organs are found in a dermoid cyst, it is, however, a question if this must not rather be looked upon as a case of *fœtus in fœtu;* that is, two fetuses, one of which has hardly developed and is included in the other.

Etiology.—Little or nothing is known about the circumstances that cause the development of ovarian cysts. They are met with at all ages. Simple cysts have been found in the ovaries of fetuses. In young children even multilocular cystomas have been found in a small number of cases, and Fig. 281 (p. 551) represents a congenital cystoma of this kind. Before puberty the dermoid variety predominates.

Commonly ovarian cysts appear, however, during the period of greatest sexual activity, between the ages of twenty and fifty years.

Single women are proportionately much more liable to the disease than married, the reason for which may be sought in the physiological rest which the ovaries enjoy during pregnancy and lactation.

Sometimes several members of one family are affected, which points to a hereditary disposition.

Some think chronic oöphoritis is the cause; others have taken chlorosis to be a factor in the production of ovarian cysts: the monthly congestion in these patients is insufficient to cause a menstrual discharge, but strong enough to produce hypertrophy of the walls of the follicle, and thus start the development of a cyst.

Symptoms.—If the tumor can rise freely into the abdominal cavity, it may pass unnoticed until it is large enough to give the patient the appearance of being in a state of advanced pregnancy. But, as a rule, it gives rise before that to diverse abnormalities.

Quite commonly she complains of pain in one or both sides of the pelvis or the sacral region. In some patients each menstruation is

accompanied by pain, fever, and increase in size of the tumor, which symptoms are doubtless due to congestion. Sometimes the pain occurs regularly about a week after menstruation as a kind of intermenstrual pain (p. 404).

As a rule, the patient has an abnormal sensation in walking, sitting down, or rising. Often she complains of cold feet, probably due to an imperfect circulation.

In the beginning there are no menstrual disturbances; but, when the tumor becomes large, it is often accompanied by menorrhagia, especially if it is intraligamentous; and still later, when all ovarian tissue has disappeared, menstruation often ceases altogether. On the other hand, even after the menopause new hemorrhagic discharges from the uterus may occur.

Even if menstruation takes place, and only one ovary is affected, the patients are often sterile, which may be due to the diminished number of ovules, a more difficult ovulation, inflammatory deposits, tubal disease, the displacement of the uterus, or endometritis. On the other hand, women with two large ovarian cysts may yet occasionally become impregnated, but their pregnancy is often cut short by abortion.

Like other abdominal tumors, and, on account of the enormous size they sometimes attain, in a higher degree than most others, ovarian tumors give rise to a series of symptoms, all of which are referable to pressure.

If the tumor is prevented by intraligamentous development, adhesions, or shortness of the pedicle from rising up into the abdominal cavity, symptoms of this class begin as soon as the tumor reaches the size of a fetal head. If, on the other hand, it leaves the pelvis, they come much later. Pressure on the bladder causes frequent micturition; that on the rectum, constipation. Moderate compression of the ureters leads to a scanty excretion of urine. If one of them becomes closed, the urine accumulates above the stricture and in the pelvis of the corresponding kidney, causing hydronephrosis and uremia. Pressure on the hemorrhoidal veins or on the trunks to which they carry the blood—the internal iliac and the superior mesenteric—is conducive to the formation of hemorrhoids. The pressure on the internal iliac veins and the vena cava inferior may become so great that these channels practically become impervious. Under such circumstances the blood finds an outlet through the deep and the superficial epigastric veins, the roots of which anastomose with those of the internal mammary vein; but, as a result of the increase of the blood carried, the veins on the lower part of the abdomen become much enlarged.

The uterus is pushed over to the opposite side by a lateral cyst. If both ovaries are cystic, they push the uterus forward. In the beginning the uterus lies, as a rule, in front of the ovarian cyst, but later

behind it. The pressure may become so great that it becomes prolapsed.

Pressure on the stomach is accompanied by nausea, vomiting, and anorexia. The liver may become flattened, and in rare cases jaundice appears as a sign of compression of this organ or the excretory ducts destined to convey the bile to the intestine. The apex of the heart may be pressed outward and upward, so that the whole organ occupies a more horizontal position.

Even the substance of the heart is apt to undergo fatty degeneration or brown induration, which may become a cause of sudden death. The compression of the lungs gives rise to rapid and superficial respiration. In rare cases a serous exudation takes place into the cavity of the pleura. Even the lower ribs and the ensiform process may be turned outward.

Interference with the free circulation in the femoral and external iliac veins causes varicosities and edema of the legs and labia majora, which are still more increased, when the stagnation results in the formation of a thrombus in those large venous trunks. Rarely neuralgia appears in the legs in consequence of pressure on the sacral plexus or the large trunks innervating the lower extremities. Sometimes a certain variability is observed in the pressure-symptoms. They increase during congestion of the tumor and diminish in consequence of profuse menstruation, diarrhea, and abundant diuresis.

In some cases a blowing sound may be heard with the stethoscope on the abdomen, like the uterine souffle of pregnancy. It is probably due to compression of the large blood-vessels of the pelvis. The abdominal wall becomes thin, the umbilicus protrudes, and the skin is the seat of striæ, due to rupture of the corium. This tension of the skin may be accompanied by painful burning and exasperating itching, which disturb the sleep of the patient.

A symptom that often is the first to bring the patient to the physician is the increase in size of the abdomen. Sometimes she can distinctly tell that the swelling has begun in one iliac fossa; and, perhaps, we can yet feel it there ourselves; but when the tumor grows large, it becomes central and fills the abdomen. The rapidity with which it grows varies much. The glandular variety grows fastest of all, and becomes largest; the papillary grows more slowly, and does not acquire such large proportions; the paucilocular dropsy of the Graafian follicles and a monocystic dermoid cyst develop most slowly and remain smallest of all.

The larger the tumor becomes, the more the patient leans backward in order to move the center of gravity into a more favorable position, just as a pregnant woman does. When the growth becomes too heavy and unwieldy, she cannot walk at all. She cannot even lie on her back, but only on the side, and can only turn with the assistance of others.

In the beginning the general health is good, but soon the patient begins to lose flesh and strength. Digestion, respiration, circulation, innervation, all suffer. Sleep is often disturbed. Pain, anxiety, and loss of adipose tissue give her face a peculiar expression, the so-called *facies ovariana* (Fig. 300), characterized by pinched features and deepening furrows.

FIG. 300.

Facies Ovariana (Spencer Wells).

In rare cases the breasts may undergo a development similar to that of pregnancy. Sometimes aphthous stomatitis develops toward the end.

As a rule, the disease ends fatally, and many are the ways in which death is incurred. It may be due to lack of nutrition, dyspnœa, hydrothorax, pleurisy, pneumonia, insomnia, exhaustion, heart-disease, hydronephrosis, nephritis, uremia, hemorrhage into the cyst, inflammation and suppuration of the cyst, rupture into the peritoneal cavity, twisting of the pedicle, acute or chronic peritonitis, cancerous degeneration, etc.

By physical examination the presence of a tumor is made out. If the patient is nervous and contracts her abdominal muscles, it may be necessary to anesthetize her (p. 159), and certain details in regard to the pedicle can only be ascertained in this condition.

A complete examination is to be made both of the pelvis and the abdomen (pp. 137, 155, *et seq.*).

By bimanual examination (p. 138) we may find the womb displaced, as described above in speaking of pressure, or we may find the vagina elongated by being pulled up by the tumor and ending as a funnel-shaped canal, the vaginal portion of the uterus having disappeared. If the tumor is confined to the pelvis, we will feel it as a globular elastic mass to one side of or behind the uterus. As a rule, the tension of the cyst is too great to allow fluctuation to be felt.

Even when the tumor is developed in the broad ligament, close up to the edge of the uterus, a shallow furrow between the two indicates the line of demarkation. In cases of large tumors part of the cyst may be felt in the pelvis.

The independence of the uterus is also made out by introducing a sound and moving the uterus. The cavity of the uterus is often somewhat deeper than normal. Often a larger part of the tumor may be felt through the rectum than through the vagina. Sometimes external papillomata may be felt through the rectum or the vaginal roof.

If the tumor extends into the abdomen, we notice by inspection that the abdomen is more prominent than usual. By palpation we feel the resistance offered by the tumor, judge of the mobility or immobility of the same, and in most cases feel fluctuation. We fold the abdominal wall in front of the tumor, and move it in different directions, and move the tumor from side to side and up and down. In order to feel the pedicle, one assistant pulls the uterus down with a volsella, another lifts the tumor, and the surgeon tries to feel the hard string extending from one to the other.

In palpating an ovarian tumor we sometimes hear and feel a superficial crepitation, which is explained in different ways. I believe it to originate in fresh adhesions between the tumor and the abdominal wall, as I have noticed almost identically the same sensation in peeling off the membranes from the inside of the uterus in performing Cesarean section.

Percussion elicits a dull sound over the tumor, surrounded on both sides and above by an area of tympanitic resonance due to the intestine.

Auscultation permits us sometimes to hear a blowing sound in enlarged and partially compressed blood-vessels.

The following measures should be taken with a tape measure: the circumference at the level of the umbilicus and at the most prominent point, if that measure differs from the first; the distance from the symphysis to the umbilicus and from the umbilicus to the ensiform process, and to both anterior superior spines of the ilium. In

tumors of moderate size the distance from the symphysis to the umbilicus is longer than from the latter to the ensiform process, and the distance from the umbilicus to the anterior superior spine of the ilium is greater on that side where the tumor is situated. In very large tumors these differences disappear.

In the course of the development of ovarian cysts some accidents may occur, the clinical aspects of which would require special attention—namely, hemorrhage, inflammation, suppuration, twisting of the pedicle, rupture, ascites, peritonitis, and intestinal obstruction.

Hemorrhage.—Small amounts of blood are frequently mixed with the cystic fluid without giving rise to any symptoms, but if the intracystic bleeding is considerable, it may even jeopardize the patient's life. This occurrence is marked by a sudden increase in the size of the tumor, a weak pulse, dyspnœa, fainting, pallor, and a cold, clammy skin. While a moderate bleeding may, perhaps, be arrested by means of an ice-bag placed on the abdomen, signs of serious internal hemorrhage call for immediate ovariotomy.

Inflammation and Suppuration.—The cyst may become inflamed, which is accompanied by fever, pain, and tenderness of the tumor. If the inflammation passes into suppuration, the patient is seized with more or less regularly recurring rigors, followed by profuse perspiration and high temperature. Simple inflammation is treated successfully with ice-bags, while suppuration is an indication for immediate removal of the cyst.

Torsion of the Pedicle.—If torsion takes place very slowly, it may develop without appreciable symptoms, except a gradual diminution of the tumor, but if it occurs suddenly, it is accompanied by rapid enlargement of the cyst, pain, tenderness, incessant vomiting, the vomit soon becoming green in color, and acceleration of the pulse. The torsion may be temporary. With its cessation the symptoms stop. If it continues, it may lead to ascites, internal hemorrhage, rupture of the cyst, suppuration, peritonitis, or gangrene of the tumor. But it may also follow a more chronic course, and end the patient's life by slow infection and marasmus. If the diagnosis of torsion of the pedicle can be made, ovariotomy should be performed at once.

Rupture of the Cyst.—Rupture into the peritoneal cavity of small cysts with serous contents need not produce any symptoms. If the cyst is large and the contents watery, the fluid is soon absorbed and disposed of by increased diuresis and perspiration. Colloid fluid may remain for months in the peritoneal cavity.

The rupture of a cyst with bloody contents may be followed by the development of a retro-uterine hematocele.

If pus or other irritant fluid is poured into the peritoneal cavity,

it sets up general peritonitis. Smaller amounts of fluid may, however, only cause local peritonitis and adhesions.

If a large cyst ruptures into the peritoneal cavity, the patient has a sensation of something giving way, is seized with sudden severe pain and faintness. The surgeon can feel the fluid move freely in the peritoneal cavity. In rare cases a new large tumor may form in the peritoneal cavity (p. 563).

In some cases rupture occurs repeatedly, each time accompanied by temporary diminution of the cyst and symptoms of peritonitis.

The effects of rupture being so very different, the appropriate treatment must be decided on in each case according to circumstances.

If the symptoms are at all alarming, ovariotomy should be performed at once.

The rupture into the stomach is marked by vomiting of cystic fluid. That into the intestine is evidenced by evacuation of the fluid through the anus, and diarrhoea. When rupture takes place into the bladder, cystic fluid, hairs, and teeth may be evacuated with the urine. If the cyst ruptures into the vagina, the contents are evacuated through the vulva.

The evacuation through a hollow organ or through the skin, like that into the peritoneal cavity, may be intermittent. If the communication has taken place with the intestine, no infection need take place, the opening being small and valvular, or being kept temporarily closed by the inside of the cyst-wall applying itself against it.

The rupture through a hollow organ may effect a spontaneous cure. It is, therefore, wise to await developments before undertaking any dangerous operation.

Ascites.—Serous fluid may accumulate in the peritoneal cavity, outside of the tumor, in consequence of chronic peritonitis, torsion of the pedicle, rupture of the cyst, hydronephrosis, and, perhaps, pressure on the vena porta. Papillary cystomas are particularly apt to be surrounded by ascitic fluid.

A moderate amount of such fluid may be looked upon as beneficial, as it prevents the formation of adhesions, and, therefore, facilitates the removal of the tumor. A large collection increases, of course, the gravity of all the pressure-symptoms.

Peritonitis.—Local or general peritonitis, characterized by the usual symptoms,—fever, vomiting, pain in the abdomen, great tenderness, exudation, and tympanitis,—is a very common accompaniment of ovarian cysts. It may be caused by friction, torsion of the pedicle, or rupture of the cyst. It leads to the formation of adhesions which render the removal of the cyst more difficult or impossible. As a rule, its occurrence should, therefore, be met by immediate ovariotomy.

Intestinal Obstruction.—As the result of pressure of a large tumor

on the intestine, or the formation of adhesive bands, or the torsion of the pedicle, involving the intestine in its convolutions, the latter may become impervious—an accident characterized by the usual symptoms, constipation, gaseous distention, pain, and vomiting, which finally becomes stercoraceous. This grave condition calls for immediate ovariotomy.

Explorative Puncture.—The practice of withdrawing some fluid from the tumor by thrusting the needle of an aspirator through the abdominal wall, which in most cases gave valuable information about the nature of the tumor, has practically been abandoned. The reasons of this change are that a blood-vessel might be wounded; or cystic fluid find its way into the peritoneal cavity, and cause peritonitis or metastases, especially in case of a papillary cystoma; or suppuration be brought on in the cyst, which, however, can be avoided by using an aseptic syringe and disinfecting the skin; or adhesion be caused between the cyst and the wall. I believe, however, that the chief explanation is to be found in the development of abdominal surgery: while fifteen or twenty years ago most surgeons avoided operating on other tumors than ovarian cysts, they are now prepared to attack whatever they may find after opening the abdomen.

Aspiration through the vagina is yet frequently used in different pelvic disorders, and thus familiarity with the fluid of ovarian cysts is still of importance, both for diagnostic and curative purposes.

Diagnostic Value of the Examination of the Fluid.—By studying the physical, chemical, and microscopical characters of the fluid, it is almost always possible to diagnosticate ovarian cysts from others. Myxoid ovarian fluid has in most cases a certain appearance by which it can be recognized at once simply by looking at it.

Viscidity is the most important physical character when present, but it may exceptionally be wanting in ovarian and present in non-ovarian fluid.

No chemical product peculiar to ovarian cysts has been found.

As a rule, the fluid of an ovarian cyst does not coagulate spontaneously, and, when it does, the coagulation takes place slowly. Ascitic fluid, as a rule, coagulates spontaneously and slowly, forming a small coagulum. The fluid of uterine fibrocysts sometimes coagulates, and then immediately after being evacuated and *en masse*.

Ovarian fluid, as a rule, coagulates to a great extent or entirely by heat. That of the cysts of the broad ligament does not coagulate by heat, unless an acid is added.

There is no pathognomonic morphological element in ovarian fluid. The most important element in regard to diagnosis is columnar epithelial cells seen in side view. Their presence excludes all other tumors than those of the ovary, the Fallopian tube, and the broad ligament (perhaps with the exception of the rare pancreas-cysts).

Although the small granular bodies described above, and represented in Fig. 292, may be found in very different fluids, the presence of very many of them in an abdominal cyst is a strong presumption in favor of its ovarian origin.

If a cystic fluid contains hair or epidermis-cells or is composed of fluid fat, it comes from a dermoid cyst; but we can only conclude that it is ovarian, if besides it contains the just-mentioned form-elements.

A fluid as clear as spring-water and containing very few histological elements may be found in ovarian cysts, both in true monocysts (hydrops folliculi) and in multilocular cysts with ciliated epithelium.

Both ovarian cysts and cysts of the broad ligament may have serous or colloid contents, but the latter is common in ovarian cysts, rare in extra-ovarian, while a watery fluid is common in extra-ovarian, rare in ovarian cysts.

Besides the information gained by the examination of the abstracted fluid, explorative puncture offers the advantage that many relations of a cyst, which were masked as long as it was full, may be felt after it is emptied. As to the modus operandi, see p. 157.

Explorative Incision.—If the symptoms and signs of an abdominal tumor yet leave the surgeon in doubt as to its being ovarian or as to the possibility of its removal, resort should be had to explorative laparotomy (p. 157).

Differential Diagnosis.—The diagnosis of abdominal tumors is often so difficult, and so many mistakes have been made, that an operator before coming to a final conclusion, and especially before beginning an operation, should bear in mind the mistakes that have been recorded and the means of avoiding them.

It is convenient to consider separately the diagnosis as long as the tumor is confined to the pelvis, and when it has become abdominal.

A. *Pelvic Tumor.*

An ovarian tumor in the pelvis should be differentiated from 1, cellulitis; 2, peritonitis; 3, hydro- and pyosalpinx; 4, a cyst of the broad ligament; 5, hematoma of the broad ligament; 6, a retroflexed gravid uterus; 7, extra-uterine pregnancy; 8, retro-uterine hematocele; 9, fibroid and fibrocystic tumor of uterus; and 10, solid ovarian tumors.

1. *Cellulitis* gives the history of inflammation, and as a probable cause, labor or abortion. The swelling is hard unless an abscess has formed, when it is softer than a cyst. It is immovable. The limits are less distinct.

2. *Peritonitis* gives a history of inflammation, and is generally caused by the use of the sound, some operation performed on the

uterus, or gonorrheal infection. It is often combined with endometritis and salpingitis. The swelling is immovable. The fluid is serous, never viscid or ropy, and does not contain columnar epithelial cells.

3. *Hydro- and Pyosalpinx* are usually bilateral, and form long sausage-shaped tumors.

4. *Cysts of the broad ligament* have very distinct fluctuation, are less tender, and contain, as a rule, a fluid that is thin, colorless, and does not coagulate by heat before the addition of an acid.

5. *Hematoma of the broad ligament* appears suddenly, is accompanied by pallor and fainting, and is soon reabsorbed.

6. *The retroflexed gravid uterus* is accompanied by signs of pregnancy, and often constipation and retention of urine. The mass in Douglas's pouch is continuous with the cervix, and can often be replaced.

7. *Extra-uterine pregnancy* gives the signs of pregnancy. A tumor is felt either independent of the uterus or attached to it. The patient has attacks of sudden, violent pelvic pain. Sometimes there is a bloody discharge from the uterus containing decidual shreds.

8. *Retro-uterine hematocele* gives a history of sudden abdominal pain at a menstrual period or of menorrhagia, followed by inflammation. The tumor, at first very soft, soon becomes hard.

9. *Fibroids of the uterus* are hard, situated in the uterus or intimately connected with it. The uterus has an irregular shape. Hard nodules are often felt.

Fibrocystic tumors may be fluctuating, but form one mass with the uterus, and hard nodular masses are likely to be felt.

10. *Solid ovarian tumors* are much rarer than cysts, are hard, often nodular, frequently accompanied by ascites, the fluid of which may, if the tumor is cancerous, contain large round or pear-shaped cells, isolated or in groups, and with single large nuclei.

B. *Abdominal Tumor.*

If the ovarian tumor has risen into the abdominal cavity, it should be differentiated from the following swellings: 1, pregnancy (normal, with excess of liquor amnii, with dead child, or extra-uterine); 2, hydatiform mole; 3, hematometra, hydrometra or physometra; 4, fibroid or fibrocystic tumor of the uterus; 5, ascites; 6, hematocele; 7, encysted peritonitic exudation; 8, tuberculosis of the peritoneum; 9, cancer of the peritoneum; 10, a cyst of the broad ligament; 11, an omental cyst or solid tumor; 12, hydronephrosis; 13, a renal cyst; 14, a floating kidney; 15, a hydatid; 16, a liver-cyst; 17, a floating liver; 18, a pancreas-cyst; 19, a cyst or solid tumor of the spleen; 20, a cyst

of the mesentery; 21, a cyst of the abdominal wall; 22, a solid tumor or swelling of the abdominal wall; 23, hydrosalpinx; 24, spina bifida; 25, dilatation of the stomach; 26, a distended bladder; 27, impacted feces; 28, tympanitis; and 29, a phantom tumor.

1. *Pregnancy* is characterized by numerous signs, especially the fetal heart-sound, fetal movements to be heard and felt, parts of the fetus to be felt by vaginal or abdominal examination, ballottement, purple color of the vagina, and softening of the cervix and lower uterine segment. The tumor forms one mass with the cervix and is contractile.

In *hydramnion* the fetal heart-sounds may be inaudible and the fetal parts may be difficult to feel, but we have the history and other signs of pregnancy, unusual distention of the lower uterine segment, and sometimes an open cervix, allowing the examiner to place the finger right on the ovum.

Amniotic fluid differs from all others by containing large flat cells filled with fat, and free masses of fat.

If the child is dead, we have, of course, no fetal sounds or movements; but the history and other signs of pregnancy remain, and the fetus can be felt.

Extra-uterine pregnancy rarely advances so far as to form a large abdominal tumor. We have the history and the signs, not only of pregnancy, but of ectopic gestation (p. 573), and the fetus is even felt more easily than in intra-uterine pregnancy.

2. A *hydatiform mole* may be very like an ovarian cyst, but it differs from it by the condition of the cervix during pregnancy, the contractility of the uterus, and the discharge of a bloody fluid containing débris of the vesicles of the chorion.

3. *Hematometra, hydrometra and physometra* (p. 408) are all situated in the uterus, follow atresia of the genital canal, give rise to menstrual molimina, and do not affect the constitution.

4. *Sessile fibroids* are hard, nodular, and situated in the wall of the uterus. Pediculated fibroids may be much like an ovarian cyst, but are harder.

Fibrocystic tumors of the uterus may be so like multilocular, colloid, sessile ovarian cysts that the most experienced gynecologists may be deceived in differentiating them. The points to keep in mind are that fibrocysts are rare, that they usually appear in persons over thirty years of age, that the uterine cavity commonly is considerably enlarged, that the tumor, as a rule, forms one mass with the uterus, that its consistency is harder, that hard masses are often felt in the upper part of the tumor, that the patient often suffers from profuse menorrhagia, that the development is slow, and that the constitution suffers less.

If the fluid coagulates spontaneously, rapidly, and *in toto*, it is proof that the tumor is a fibrocyst.

5. *Ascites.*—The abdomen appears flat, and no tumor is felt. The fluctuation is very marked. The percussion is tympanitic on the part of the abdomen turned upward, and dull in the dependent parts in whatever position we place the patient. In Fig. 301 the shaded

FIG. 301.

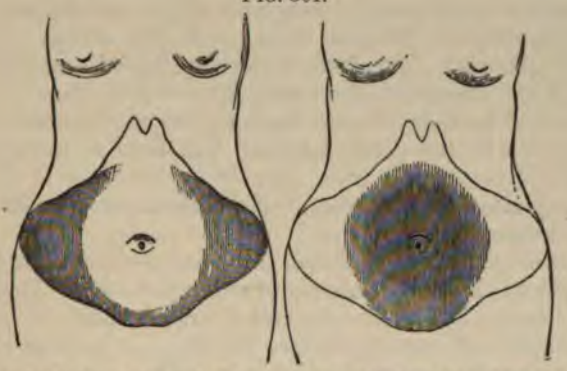

Percussion-sound in Ascites to the left and in Ovarian Cyst to the right when the patient lies on her back (Sp. Wells).

parts mark the dull percussion. The fluid is not viscid, forms a small coagulum by exposure to the air, and contains flat endothelial cells and lymph-corpuscles with ameboid movements. As a rule, the condition is found to be due to diseases of the liver, heart or kidneys.

If the ascitic collection is so enormous as to distend the whole abdomen, it may, however, be impossible to elicit the above-described signs; but then such a mass of fluid may accumulate in the course of a few months in ascites, while an ovarian cyst takes years to grow to such enormous proportions. The uterus is easily movable in ascites, immovable in cases of very large cysts.

6. *Hematocele* (see above under Pelvic Tumor).

7. *Encysted peritonitic exudation* gives a history of inflammation. The fluid is serous, like that in ascites.

8. *Tuberculosis of the peritoneum* is accompanied by free fluid, and often by a tumor formed by agglutinated intestinal knuckles and omentum, that may be hard to differentiate from an ovarian cyst. These pseudotumors, however, are much more common in young women than later in life, and grow much more rapidly than ovarian cysts. Sometimes the central part of the abdominal wall is the seat of a red blush and edema. The fluid is straw-colored, and coagulates, at least partially, by exposure to the air. The presence of tubercles in the lungs, pleurisy, great tenderness, on pressure, of the intestines, and a rise in temperature in the evening, also go far to establish the diagno-

sis of tuberculosis of the peritoneum; and as laparotomy has proved a cure for this disease, no harm is done, if a mistake should be made.[1]

9. *Cancer of the peritoneum* is accompanied by rapid cachexia. The fluid often contains characteristic cells (p. 492). Large, hard, irregular masses can be felt in the abdominal cavity.

10. *Cysts of the broad ligament* are much rarer than ovarian cysts, seldom larger than an adult's head, immovable, and dip deep into the pelvis, where they are situated close up to the uterus. As a rule, they develop slowly. The fluid is as described above under Pelvic Tumor. When evacuated, the tumor is slow to refill.

11. *Omental cysts* are situated higher up in the abdomen, and have no connection with the pelvic organs. The fluid is serous like that of ascites.

There may also be a *solid* tumor of the omentum, especially a carcinomatous tumor.

12. *Hydronephrosis* lies behind the intestine, and occupies a more lateral position. There is a history of urinary trouble. The fluid may contain columnar epithelial cells and a large amount of urea, but is very unreliable, and even deceptive. Perhaps, it may be reached by means of catheterization of the ureter (p. 161).

13. *Renal cysts* are rare. There is a tympanitic percussion-sound, because the intestine lies in front of it. There is a history of urinary trouble. These cysts develop from above downward. Sometimes the peculiar shape of the kidney can be recognized. The fluid contains much urea.

14. A *floating kidney* or one fastened in the iliac fossa has also been mistaken for an ovarian cyst. In this case the characteristic shape is still better preserved than when the organ is the seat of cystic degeneration.

15. A *hydatid of the liver* develops downward from the right hypochondrium, and can be felt to be continuous with the liver. The dull percussion-sound extends uninterruptedly to the liver region. Sometimes hydatid vibration can be felt. The fluid is clear as spring-water, does not coagulate by heat, and may contain hooklets of echinococci or shreds of cuticula, the parallel striation of which is pathognomonic. In its chemical composition enter succinic acid, leucin, grape-sugar, and inosite, but never paralbumin. (*Hydatids of the Pelvis* will be described in Part vii., Chap. ix).

16. *Liver-cysts*, other than hydatid cysts, are exceedingly rare. They develop from the right hypochondrium. The fluid may contain bile or liver-cells, and does not contain the bodies usually found in ovarian tumors.

17. A *floating liver* is recognized by its shape, the clear percussion

[1] Encysted tubercular peritonitis has been lucidly discussed by W. T. Howard of Baltimore in *Trans. Amer. Gyn. Soc.*, 1885, vol. x. pp. 41–62.

in the liver region, and the possibility of replacing it in its normal position.

18. *Pancreas-cysts* are rare and develop downward. The fluid is acid and contains small nuclei and peculiar thready bodies.[1]

19. *Cysts of the spleen* are very rare, develop from the left hypochondrium, and the fluid is rich in leucocytes.

Solid splenic tumors retain the peculiar shape of the spleen, and are harder.

All tumors coming from above leave for a time a resonant space above the symphysis. The production of gas in the stomach and injection of water into the intestine drive a tumor in the direction from which it has started (p. 156).

20. *Cysts of the mesentery* are very rare. Perhaps both ovaries can be felt. The tumor is sometimes freely movable in an upward direction. A kind of pedicle formed by the mesentery may extend to it from above. The fluid is serous, without epithelial cells.

21. *Cysts of the abdominal wall* have no connection with the uterus. The fluid is serous, and does not contain cellular elements.

Cysts of the urachus contain flat epithelial cells.

22. *A solid tumor* of the abdominal wall, especially a fibroma of the fascia transversalis with partial cystic degeneration, has been taken for an ovarian cyst.[2] The lack of menstrual disturbance and of pain may give rise to a doubt, which may be cleared by examination under ether.

A thick layer of subcutaneous *adipose tissue* has given rise to the same mistake, but it may be raised between the fingers, and on deep percussion we get a clear sound.

Edema of the anterior wall is characterized by the pitting left by pressure.

23. *Hydrosalpinx* very seldom forms a large tumor (p. 520). It is, as a rule, bilateral, always monocystic, and not very tender. The fluid is serous, and does not contain the bodies commonly found in ovarian tumors. The presence of ciliated columnar epithelial cells does not decide the question (p. 556).

24. *Spina bifida* very rarely forms a tumor in the pelvis and abdomen, but in one case it contained some three quarts of fluid.[3] This is watery, colorless, limpid, without form-elements, and contains only traces of albumin. After evacuation of the fluid the fissure in the sacrum through which the cyst entered the pelvis may be felt.

25. *Dilatation of the Stomach.*—Incredible as it may seem, even a dilated stomach has been mistaken for an ovarian cyst and operated

[1] Garrigues, *Diagnosis*, p. 86.

[2] An interesting case of the kind was reported by Rob. Weir, in the *Med. Record*, Dec. 3, 1887, xxxiii. 703.

[3] Emmet, *Gynecology*, 2d ed. p. 791.

on.[1] The chief points which are to be borne in mind in order to avoid a similar mistake are the great variations in the size of the tumor; the change in the distribution of the tympanitic and the dull percussion-sound, according to the presence of gas or food in the stomach; and the large quantities of food vomited at times, representing nearly all that has been ingested for several days. Once on the alert, the diagnosis can be made clear by the introduction of an esophageal sound or the production of gas in the stomach (p. 156).

26. *Distention of the Bladder.*—A bladder may be overdistended with urine although the patient urinates (*ischuria paradoxa*), and may form a very large tumor in the abdomen.[2] Before making his examination the doctor should, therefore, introduce the catheter, and empty the bladder.

27. *Impaction of Feces.*—A patient may likewise suffer from diarrhea, and still carry large masses of feces in her intestines, which may be mistaken for tumors. Before a diagnosis is made, the bowels should be emptied with aperient medicines and large irritating enemas (p. 169).

28. *Tympanitis* gives tympanitic percussion-sound.

29. A *phantom tumor* is a curious condition sometimes met with in hysterical patients and in those affected with caries of the vertebræ. Through a combination of adipose tissue in the wall and tetanic contraction of the abdominal muscles a protuberance is formed on the abdomen, which even may give a somewhat dull percussion-sound. The moment the patient is anesthetized the supposititious tumor subsides and disappears, leaving an area yielding the normal tympanitic sound of the intestine.

Large *extraperitoneal* ovarian cysts are particularly difficult to diagnosticate. They have no pedicle.

Other signs, that, taken conjointly and not singly, may give rise to a more or less strong suspicion of the existence of this kind of cyst, are the following: 1, close adherence to the enlarged and laterally displaced uterus; 2, elongation of the bladder, as proved by the introduction of a steel sound; 3, pressure on the rectum and bulging out of the posterior vaginal cul-de-sac; 4, embarrassed defecation and micturition; 5, spontaneous rupture of the cyst; 6, unusual pain caused by the growing cyst; 7, tympanitic percussion sound in front of the tumor, like that found in renal tumors; 8, an unsymmetrical shape and preponderating development in one side of the pelvis of a firmly fixed cyst.[3]

Complications.—Ovarian cysts may be complicated by many diseases, some of which may be directly referable to the pressure

[1] Reeves Jackson, *Detroit Lancet*, 1880; *Centralblatt. für Gynäk.*, 1880, vol. iv. p. 368.
[2] I have myself withdrawn three quarts of urine from the bladder.
[3] Wm. Goodell, *Amer. Syst. of Gynecol.*, vol. ii. p. 830.

exercised by the tumor itself, while others are mere coincidences, which, however, may have considerable influence on the prognosis and treatment. Thus we would not perform ovariotomy, if the cyst is accompanied by *cancer of the uterus*, unless the latter organs could be extirpated at the same time—an addition to the operation which, of course, would cast a deep shadow over the prognosis. In advanced *tuberculosis* or any other serious chronic disease it may also be deemed inadvisable to subject the patient to the risks of a capital operation, which at best will fail to prolong her life.

The complication with *pregnancy* is of particular interest, since it is not so very rare, and may influence the treatment very much. It may occur even when both ovaries form large tumors, and so much the more so when only one is affected. The diagnosis is made from the history and the objective find, the presence of an ovarian tumor having been known before the patient became pregnant, or being made out in connection with the gravid uterus. When the presence of one child is ascertained, the investigation must next be directed toward the second mass, with a view to decide whether the case is simply one of twins or of uterogestation combined with a tumor.

The simultaneous pressure of a growing uterus and an ovarian cyst will in most cases cause so much discomfort, or even be attended with such danger, that interference is called for. Three methods are then at our disposal: 1, artificial abortion or premature labor; 2, tapping of the cyst; or, 3, ovariotomy. If possible, we would wait till the child is viable, and then induce premature labor. Tapping has given excellent results, and there is no serious objection to it, if performed by a man prepared to let ovariotomy follow if untoward sequences should develop. Ovariotomy has been performed many times during pregnancy. The dangers of the operation are very slightly increased, but sometimes it is followed by abortion.

Prognosis.—A spontaneous cure of an ovarian cyst may take place by means of slow torsion of the pedicle, followed by atrophy, fatty degeneration, or calcification. Or it may be brought on by rupture of the cyst. The tumor may also shrivel up after one or more tappings. It may also become stationary and stop growing. But all these occurrences are so rare, that they must be left entirely out of consideration when the question of treatment is raised.

A patient may live twenty years with an ovarian cyst, but in the vast majority of cases a speedy death awaits the woman affected with such a tumor. Of those having a proliferating cystoma, 60 to 70 per cent. die within three years, and 10 per cent. additional in the fourth year.

Treatment.—Medical treatment is of no avail, and galvanopuncture is more dangerous than ovariotomy. Noeggerath[1] claims that a

[1] E. Noeggerath, *Centralbl. f. Gynäk.*, 1890, vol. xiv., "Report of Tenth International Congress," p. 86.

weak *faradic current* applied three times a week for from one-half to one hour makes a glandular proliferating ovarian tumor of small or medium size disappear in six to eight weeks, so that only small remnants of it remain. He uses the secondary current, the negative pole, covered with a sponge, in the vagina, the positive, in the shape of a sponge-covered plate of the size of a hand, on the abdomen. As the procedure is innocuous, it might be tried.

Two kinds of treatment only are generally recognized—namely, *tapping* and *ovariotomy;* and it may be stated from the beginning that ovariotomy should be performed whenever it is practicable.

Tapping.

Tapping as a therapeutic measure is objectionable for several reasons. It may cause hemorrhage, a danger which, however, is considerably reduced by using a fine needle or trocar and canula connected with an aspirator. It may cause suppuration of the cyst; but that may be entirely obviated by using a clean instrument, and disinfecting the patient's skin and the operator's hands carefully. Acrid fluid may find its way through the opening in the cyst into the peritoneal cavity, and set up peritonitis. This may also, to a great extent, be prevented by emptying the opened cavity entirely; but nobody ought to tap without being prepared to have an ovariotomy follow in case of supervening peritonitis. A malignant infection of the peritoneum may take place, if the tumor happens to be of the papillary variety, and particles of the papillomatous growths are carried out into the peritoneal cavity on withdrawing the instrument. As nearly all ovarian cysts contain secondary cysts, these will, on removal of the pressure from the emptied compartment, only develop so much the faster. The tapping has to be repeated again and again, with ever shorter intervals, thus constituting a serious drain on the strength of the patient. The sudden evacuation of a large amount of fluid may so change the shape of the tumor that a rotation is induced, accompanied by torsion of the pedicle (p. 561).

In spite of all real and imaginary dangers connected with tapping, there are, however, circumstances under which it is perfectly proper to have recourse to it:

1. If a patient absolutely refuses to have ovariotomy performed, tapping may yet offer relief, and sometimes even prolong her life.

2. We have seen above (p. 579) that during pregnancy tapping has in many cases given excellent results as a palliative measure. If the physician is first called during actual labor, and the cyst offers an obstruction to its progress, tapping is in many instances preferable to any other treatment.

3. The removal of very large tumors has been attended by sudden death on account of anemia of the brain caused by the rush of blood

to the abdominal organs at the cessation of the pressure exercised on them by the tumor. Other vital organs, such as the heart, the lungs, and the kidneys, may be so compressed by the cyst that they are not in a condition to perform their functions properly. It is, under such circumstances, a good plan to prepare the system for the radical operation by the preliminary slow evacuation of some of the fluid contained in the cyst.

Fig. 302.

Warren's Ovarian Trocar.

4. Tapping may be indicated by the presence of an acute disease, such as pneumonia, bronchitis, typhoid fever, smallpox, etc., which makes it desirable to remove pressure, but excludes the immediate performance of ovariotomy.

5. It is also indicated in advanced chronic diseases, such as tuberculosis, Bright's disease, and cancer.

6. Finally, in the rare cases in which ovariotomy is impossible.

Tapping may be performed through the abdominal wall or through the posterior vault of the vagina. It may be performed with a large trocar, such as that used for ascites, or by means of an aspirator. The former is more expeditious, and, if the fluid is thick, the only available method; the latter is considerably safer. If a large trocar is used, it is well to prevent the possible entrance of air by having a soft-rubber tube attached to it, the other end of which is kept under the surface of some fluid in the receptacle. The instrument represented in Fig. 302 offers the further advantage that, in case of obstruction of the canula, the trocar can be pushed forward again.

Modus Operandi.—The patient should lie on her back. The puncture is usually made in the median line, midway between the symphysis pubis and the umbilicus. With a hypodermic injection of cocaine (p. 203) the skin may be made insensible, and a small longitudinal incision, large enough to admit the trocar, be made through it, which leaves a better wound for healing than if the trocar is thrust through the skin. If an aspirator is used, the pain is so insignificant and the opening so small that neither cocaine nor the cutaneous incision is called for. If the canula becomes blocked up during the flow of the fluid, a disinfected stylet should be used to clear it without removing it. Sometimes the obstruction is due to contact with the inside of the cyst-wall, and is overcome by changing the direction of the canula. It is risky to open

more than one cyst at a time, as large blood-vessels may run in the deeper parts of the cyst. After the operation the wound is closed, the abdomen covered with a thick pad of cotton, and surrounded with a binder, so as to counteract the loss of pressure caused by the removal of the fluid. If there is any bleeding, which is very rare, a hare-lip pin may be passed deep in under the lips of the wound and surrounded by a figure-of-eight ligature. The patient should be kept in bed for four days. (For further particulars see p. 157.)

Tapping through the vagina is much more hazardous, and likely to give less relief, since the large compartments of a cyst are found in the abdominal part of an ovarian cyst. If the operation is followed by suppuration, ovariotomy must be performed or the opening in the vagina and cyst enlarged by incision, so as to make room for a T-shaped soft-rubber drainage-tube, through which disinfectant fluid should be injected daily, until the discharge ceases.

Ovariotomy.

Ovariotomy is the operation by which an ovarian tumor is removed from the body, while the term oöphorectomy is used to designate the removal of ovaries which do not exceed the normal size of the organ very much (p. 535).

Indications and Counter-indications.—In a general way it may be said that ovariotomy is indicated in every case of ovarian cyst, and as soon as its presence is discovered.

Small tumors may be more difficult to remove because the pedicle is less developed, but, on the other hand, there is less danger from adhesions. The patient is spared all the accidents to which such tumors are liable in the course of their development (pp. 569–71). Finally, we must take into consideration the pronounced tendency ovarian tumors have to become malignant (p. 562).

Special indications for immediate operation are serious hemorrhage into the cyst, suppuration of the cyst, torsion of the pedicle, rupture into the peritoneal cavity followed by alarming symptoms, and the occurrence of peritonitis or of intestinal obstruction.

The age of the patient need not be taken into consideration: ovariotomy has been performed with success in young children and in old women over eighty years of age.

Even hemophilia is no counter-indication, since the operation has been successfully performed under such circumstances.

On the other hand, the surgeon should abstain from so capital an operation, if the patient is in an advanced stage of tuberculosis or chronic nephritis or suffers from cancer in any other organ than the ovary, unless the cancer can be removed at the same time or by a separate operation. Cancer in the ovarian cyst itself also forms a

counter-indication, if the disease has invaded the surroundings or infected the constitution. The same applies to any other wasting disease that may be expected soon to put an end to the patient's life.

Ovariotomy may be performed through the abdominal wall or through the vagina, the former of which methods is by far the more common and important.

Vaginal ovariotomy is, indeed, little used, and should be limited to cases of small, freely movable cysts. The drawbacks in entering the abdomen from the vagina have been set forth in speaking of oöphorectomy (p. 516).

In the following we consider only *abdominal ovariotomy.*

Preparatory Treatment.—If the patient is weak, and has been living in unfavorable circumstances as to food and shelter, it is advisable to give her a chance of gaining in health and strength by proper diet and regimen. Under all circumstances the skin is cleaned, the bowels are emptied, and, if necessary, the functions of the kidneys regulated (p. 192).

Some surgeons give ten grains of quinine for several days in order to ward off fever, which, however, is hardly necessary, unless the patient is subject to malaria. Others praise bromides as a preventive of vomiting.

In regard to season, the time of the day, menstruation, lactation, the arrangement of the room and table, the presence of spectators, the administration of the anesthetic, the patient's dress, and disinfection, the reader is referred to what has been said in speaking of operations in general (pp. 188–216).

Instruments, Sponges, etc.—In a simple ovariotomy very few instruments are used; but, as it is impossible to foretell with certainty what difficulties may arise, a rather large armamentarium must be prepared to overcome them. The following paraphernalia ought to be within reach:

4 large flat sponges;
4 large round sponges;
8 small round sponges (p. 195; about the substitution of gauze, see p. 196);
4 sponge-holders (Fig. 206);
1 sharp-pointed bistoury;
1 probe-pointed bistoury;
1 pair of long straight blunt-pointed scissors;
1 pair of blunt-pointed scissors curved on the flat;
1 dissecting-forceps;
1 mouse-tooth thumb-forceps;
1 director;
12 pairs of small pressure-forceps (Fig. 151, p. 180);

3 pairs of small pressure-forceps with T-shaped jaws;
6 pairs of long pressure-forceps (Fig. 249, p. 467);
2 pairs of Nélaton's cyst-forceps (Fig. 304);
2 volsellæ (Fig. 171, p. 205);
2 pairs of Spencer Wells's pedicle-forceps (Fig. 305);
1 male metal catheter;
1 female metal catheter;
1 male urethral steel sound, No. 25, French;
2 small tenacula (p. 205);
1 Simon's sharp spoon (Fig. 128, p. 152);
1 tenaculum-forceps;
1 large curved trocar (Fig. 303);
1 small curved trocar (Fig. 158, p. 186);
1 aspirator (Fig. 134, p. 158);
2 wire retractors;
1 cautery-clamp (Fig. 306);
1 Paquelin's thermo-cautery (Fig. 149, p. 178);
1 yard rubber cord for temporary compression;
Drainage-tubes of glass and soft rubber, one of the latter T-shaped;
1 uterine sound;
1 dull handled needle (Fig. 175, p. 207);
1 Schroeder's needle, bent at right angles (Fig. 258, p. 476);
1 Polk's needle (Fig. 250, p. 467);
2 Spencer Wells needles or long straight Hagedorn needles;
2 strong curved Hagedorn needles for closing incision;
2 smaller curved needles for passing ligatures;
2 fine curved needles;
2 cambric needles for the intestine;
1 Hagedorn needle-holder;
1 common needle-holder;
Silk for ligatures and sutures, fine, medium, and strong;
Catgut;
Silkworm gut.
A movable electric lamp is sometimes very useful;

For dressing: Iodoform;
Iodoform gauze;
Gutta-percha tissue;
Salicylated or borated or plain aseptic absorbent cotton;
Rubber adhesive plaster;
Flannel binder or many-tailed muslin bandage;
6 large safety-pins.

Ovariotomy begins with laparotomy.

Laparotomy,[1] or *abdominal section*, is an operation consisting in an incision through the abdominal wall into the peritoneal cavity. In ovariotomy the chief steps are—

1, the abdominal incision;
2, the removal of the cyst;
3, the closure of the wound;
4, the dressing.

With few exceptions laparotomy is performed in the median line, between the umbilicus and the symphysis pubis. According to different circumstances the incision is made longer or shorter, more or less near the symphysis, and may be extended beyond the umbilicus all the way up to the ensiform process.

The patient is placed on her back, extended at full length on a table, with her feet toward the window. The necessary preparations have been described in the general division (pp. 190–216). The operator stands on the right side. At least one assistant besides the one who gives the anesthetic is needed, and stands on the left side of the patient, facing the operator. Many operators prefer, in order to avoid sources of infection, to have as little assistance as possible, and take the instruments from the tray themselves.

For operations in the pelvis *Trendelenburg's position* (p. 136) offers great advantages, the organs being more exposed to view and easier to reach. For this position the patient is turned with the head toward the light. The operator may stand on her right, which affords him better light, but has the drawback that he must lift his arm in a somewhat fatiguing way; or he may stand on her left.

Péan's Position.—Some surgeons prefer to operate sitting, which becomes a necessity in very protracted operations. Péan has constructed a special table for this purpose. The operator sits between the patient's legs, which rest in movable hollow supports or hang down over the operator's own thighs. For this position the operator

[1] Dr. Robert P. Harris of Philadelphia published in 1890 a pamphlet entitled "*Cœliotomy. This, and not laparotomy, is the proper Greek synonym of 'abdominal section,' laparotomy being an incision of the flank only.*" Unfortunately this name has been adopted to some extent in this country.

First, it is to be regretted that the euphonious word laparotomy, with its beautiful liquids and open vowels, should be driven out by "celiotomy"—for that is not only the pronunciation, but the modern spelling—with its sharp sibilant and thin sound of *e*. Secondly, when a word has existed for nearly a hundred years, has passed into all languages, and forms the root of numerous derivatives and part of compound words, it causes only confusion to substitute another for it. Finally, even the argument drawn from philology in favor of the new word, is to say the least, doubtful. If it must be admitted that *ἡ λαπάρα* means the soft part between the ribs and the crest of the ilium, it is only a very slight extension to apply it to the whole abdominal wall, and it has no other sense; whereas *ἡ κοιλία* means, 1, the abdominal cavity; 2, the stomach; 3, stools; 4, the pulp of the finger; 5, any cavity; and consequently the word *celiotomy* does not convey even approximately an idea of what is going to be cut.

sits on a high chair, and the patient lies on a low table, so that he can bend over the abdomen, and look into the peritoneal cavity.

Behind and to the left of the operator is the instrument table; to the right, a basin with corrosive-sublimate solution (1 : 2000), and another with plain boiled water. Behind the assistant stands a table with sponges kept in basins with 2½ per cent. carbolic-acid solution, under the care of a nurse. Used sponges should first be wrung out of plain warm water, and then replaced in the basin with carbolized water.

1. *Incision.*—In most laparotomies it suffices to make an opening large enough to admit the index- and middle fingers. The first incision is made with a medium-sized scalpel through the skin and subcutaneous tissue. Bleeding vessels are secured with pressure-forceps. The next incision severs the linea alba. If the operator misses it, and goes a little out to one of the sides, no harm is done. The only difference is that he will see and perhaps cut through the inner fibers of the pyramidalis or rectus muscle. The septum between the two recti is, however, easily found by pushing a director from the opening made in the sheath to the sides, a resistance being met with in the median line. In this part of the operation there is no danger, and it may be executed rapidly, simply cutting down on the tissues. But under the fascial and muscular tissue lies a layer of adipose tissue, the *preperitoneal fat*,[1] which forms an important landmark, for immediately behind it is found the peritoneum.

This preperitoneal fat is, therefore, best torn with pressure-forceps or the handle of the scalpel, until the peritoneum itself is exposed.

When the abdomen is distended by a tumor, its wall is on the stretch, and the tissues separate more easily than in other laparotomies, and in consequence of the pressure exercised on it the preperitoneal fat may become very much reduced. Greater care is, therefore, needed under these circumstances in making the abdominal incision than, for instance, in oöphorectomy, or the operator risks plunging his knife right into the cyst from the start, not to speak of wounding organs, such as the omentum, the intestine, or the bladder, that might be in the way.

The exposed peritoneum is seized with two pairs of pressure-forceps or with a tenaculum, and lifted up in a fold, in which a small opening is cautiously made with the knife. Before doing this all hemorrhage should be stopped by grasping bleeding vessels with pressure-forceps, which are left on during the following steps of the operation, until they are in the way, and bleeding has stopped. Now the left index-finger is introduced, and the knife held against it and made to cut the peritoneum from within outward until the hole is large enough. If after a digital exploration the operator deems it neces-

[1] It is sometimes called the *subperitoneal fat*, an expression that is apt to mislead.

sary to enlarge the opening, it is done with a pair of strong straight scissors, one blade of which is placed inside of the abdominal cavity, between the middle and index-fingers, which keep intestine and omentum out of the way and protect the bladder; and the other touches the skin. Thus the whole thickness of the abdominal wall is cut through, and bleeding vessels are caught with pressure-forceps. As to the length of the incision, we can only say that it should not be longer than required, but long enough to allow of all necessary manipulations. A pressure-forceps is put on the peritoneum on either side of the incision, so as to facilitate finding it again when the wound is to be closed.

The lower end of the incision ought, finally, to be half an inch above the symphysis; the upper varies according to the size of the mass to be removed. If the incision extends beyond the umbilicus, most operators avoid this place, as being thinner and less favorable for healing, and go to the left of it; but some of the best ovariotomists cut right through it.

2. *Removal of Cyst.*—When the peritoneal cavity is opened, the cyst appears in the wound as a pearl-gray glistening body. In order to reduce its size the patient is turned on the side facing the operator. Emmet's trocar (Fig. 303) is pushed into it near the upper end of the

FIG. 303.



Emmet's Ovariotomy Trocar.

incision, and the fluid directed down into a tub standing under the table. Many operators prefer to let the patient stay on her back and to use a trocar with a rubber tube attached, leading the fluid down into the vessel destined to receive it. Howard Kelly has devised one of glass, which is cheap and easily rendered aseptic by boiling with soda-water.[1] As soon as the cyst begins to collapse, it is seized with

[1] Kelly, *Amer. Jour. Obst.*, April, 1893, vol. xxvii. p. 581.

a Nélaton forceps (Fig. 304) and pulled out. If there is much fluid, the operation is considerably expedited by withdrawing the trocar and enlarging the opening with scissors. After a little while room will be gained for the application of a second Nélaton forceps, and sometimes even one or two volsellæ may answer a good purpose in pulling out the tumor. If there are several large compartments, they are opened one after the other with trocar, scissors, or fingers, from that first entered.

Fig. 304.

Nélaton's Cyst-forceps: *A*, circular jaws with holes and pegs; *B*, catch.

During the removal of the cyst the assistant compresses the abdomen, and is particularly careful to prevent the protrusion of the intestine. He should also, during the following steps of the operation, always keep the abdomen closed as much as possible by approximating the edges, and covering the incision with a sponge or a gauze pad.

If the mass of the cyst left after evacuation is still heavy or bulky, it is best to get rid of it by seizing the pedicle in a temporary ligature of rubber tubing or strong silk, with Spencer Wells's pedicle-forceps (Fig. 305), or a cautery-clamp (Fig. 306), and cutting it off at a distance of about two inches above the compression. If, on the other hand, the cyst is collapsed and light, the pedicle is simply seized with the fingers. A blunt handled needle armed with a silk loop, as described

Fig. 305.

Spencer Wells's Pedicle-forceps.

under salpingo-oöphorectomy (p. 513), is used to carry the pedicle ligature through, and the Staffordshire knot (p. 514) may be used;

but in ovariotomy it is more convenient to cut the pedicle-silk in two halves, cross them, and tie each half separately, thus forming two links of a chain perforating and surrounding the pedicle. As the

FIG. 306.

Smith's Cautery-Clamp.

stump of the Fallopian tube might suppurate, it ought to be tied as close up to the uterus as convenient. When the pedicle has been tied, it is cut three-quarters of an inch above the ligature, and treated just as the stump in salpingo-oöphorectomy. Finally, it is dropped, the intestine kept back, and the omentum spread over it.

Some draw the peritoneum together over the stump and close it with a continuous suture of catgut, expecting thereby to ward off infection and adhesions to the intestine; but the first may just as well take place through the peritoneal covering, and, since the peritoneal endothelium must be handled in stitching, it is just as liable, or perhaps more liable, to form adhesions than the raw surface dusted with a powder like iodoform or aristol.

Others sear the stump over the ligature, which is a good means of preventing absorption and adhesion, but which shortens the stump and invites the risk of burning the ligature, unless a cautery-clamp is used.

On the other hand, it is a double assurance against hemorrhage to seize large arteries in the stump and tie them separately.

The distal end of the stump does not slough, because new capillaries are speedily formed around the ligature, which carry nourishment enough to the part beyond.

The silk becomes encapsulated, and is slowly absorbed; but it has been found as late as two years after it had been put in. If aseptic, it is entirely innocuous.

After having dropped the pedicle, the *second ovary* should be brought into view and examined. In a young woman it ought to be saved if possible. If it is healthy, nothing is done to it. If it only shows a few small serous cysts, they should be pricked open. A larger cyst may be cut out and the edges united with a continuous catgut suture.

In women who have passed the climacteric or are near that period it is safer to remove the second set of appendages, so as to prevent the formation of a cyst on this side. The same rule applies, if the cyst is cancerous, as experience has shown that in such cases the second ovary is predisposed to become affected in the same way. It should also be removed, if the uterus is the seat of a fibroid (p. 466) or if for any other reason it is advisable to hasten the menopause.

If no blood or other fluid has escaped into the peritoneal cavity, no attempt should be made to clean it, but the wound should simply be closed when the rest of the operation is finished.

A separate nurse should have care of sponges and gauze pads, and before the operator proceeds to the closure of the wound the sponges, pads, and artery-forceps should be counted, as it has happened that such objects have been left in the abdominal cavity, from which place they often have been removed after a long time, and after much injury had been caused.

3. *Closure of the Abdominal Incision.*—In closing the wound after laparotomies great care should be taken to unite the different layers, and especially the fascial and aponeurotic structures, as otherwise a ventral hernia is very apt to form. The best practice is first to close the peritoneum with a continuous suture of thin catgut, put in either as in simple sewing or as for buttonholes, by passing the needle through each loop of the thread. The second row of sutures should unite the aponeurotic and muscular structures. This is best done with interrupted sutures of strong catgut or silk. Finally, the skin and subcutaneous adipose tissue are united by deep and superficial silk sutures. Before closing the two upper rows of sutures the wound should be irrigated with some antiseptic fluid (p. 199).

4. *Dressing.*—When all the sutures have been tied and cut off, the abdomen is washed with a solution of corrosive sublimate, the wound dusted with iodoform, a compress of iodoform gauze laid over it, and a piece of gutta-percha tissue, an inch wider than the compress in all directions, placed outside of it. Next, the whole anterior surface of the abdomen is covered with a thick layer of dry absorbent cotton impregnated with some antiseptic substance, usually boracic or salicylic acid; this is held in place by two-inch-wide straps of rubber adhesive plaster; and, finally, a flannel binder or a many-tailed muslin bandage is put around the whole abdomen, and pinned in front with safety-pins.

5. *After-treatment.*—After the operation the patient is placed in her bed, and surrounded by half a dozen bottles filled with hot water. If there is no shock, she is allowed to sleep till she awakes spontaneously. If she vomits, the measures recommended on p. 204 are taken. The urine should be drawn with a catheter three or four times a day, if she is unable to pass it herself. Opiates should be avoided as much as possible on account of the danger of their para-

lyzing the intestine. Pain may often be considerably relieved by applying an ice-bag to the abdomen; but great pain is weakening and calls, in my opinion, for a hypodermic injection of one-eighth of a grain of morphine.

If there is no special indication for doing it earlier, the bowels should be moved by a gentle aperient on the third day. I prefer for this purpose a heaping teaspoonful of sulphate of sodium, to be repeated every four hours if needed. This salt tastes much better than sulphate of magnesium and does not gripe. To allow the bowels to be at rest too long is dangerous, because it may give rise to occlusion of the intestine by adhesions. Before the bowels are moved much relief from flatulence is afforded by introducing a soft-rubber rectal tube.

During the first day no food is given. Thirst is relieved by very small quantities of hot or ice-cold water or an enema of a pint of tepid water. The following days the patient may have tea, milk, thin oatmeal gruel, and beef-tea, in small, frequently repeated portions (not over two ounces at a time). After the first week she may have common food.

If everything goes well, the dressing is not touched for a week. Then the sutures are removed as described on p. 211. The abdomen is washed with a solution of corrosive sublimate, the sutures are replaced by strips of rubber plaster, half an inch wide and cut out in the middle so as to leave free exit for any discharge from the edges of the wound. Then a similar dressing is applied as at the time of the operation. In this way the wound is dressed once a week, and the patient should stay in bed for three weeks.

As the broad straps of plaster adhere to the skin, and their removal causes some pain, it is better to cut them just outside of the cotton, leaving the ends, and fastening the new straps to them, until finally, after three weeks, all is removed. Then the abdomen is cleaned with chloroform, which dissolves gutta-percha, and, after having been up a few days, the patient may be dismissed. She should, however, wear an abdominal belt for at least three months.

Difficulties met with during the Operation.—If an ovarian cyst does not contain much solid matter, has no adhesions, and has a long and strong pedicle, ovariotomy is one of the easiest operations. But numerous and manifold are the difficulties which may arise, which often cannot be foreseen, and for which the operator must be prepared.

Bladder in Front of Tumor.—Just as we have seen that the bladder may be spread over the front of a uterine fibroid (p. 468), so this may be the case with an ovarian cyst.

Persistent Urachus.—See p. 469.

Peritoneum taken for Cyst-wall.—In consequence of the irritation caused by the tumor the peritoneum is often much thickened, and, taking it for the adherent cyst-wall, the operator has sometimes peeled

it off from the abdominal wall. If this is only done over a small space, it is immaterial; but if a large surface has been denuded, the peritoneum, in order not to lack nourishment, and to prevent suppuration, must be stitched to the abdominal wall either by a continuous catgut suture or by the so-called mattress-suture—*i. e.* interrupted sutures going through the whole thickness of the abdominal wall—and tied over a quill or a small roll of adhesive plaster.

If the operator is in doubt whether he has to do with the peritoneum or the adherent cyst-wall, it is better to continue cutting cautiously, even at the risk of extending the incision into the cyst.

Adhesions may cause great trouble or even render the extirpation impossible.

Adhesions to the abdominal wall may often be easily severed by pushing a male urethral steel sound between the abdominal wall and the cyst before tapping. If there is much resistance, the flat hand is introduced, and the ulnar edge of it used in the way a paper-cutter separates the leaves of a book. On account of bleeding it is, however, not safe to go too far out, and more resistant adhesions should be left till the cyst has been emptied.

If the adhesion is found in the line of incision, this should be extended upward above the adhesion, until a point is reached where the abdominal cavity is opened, and then the adhesions should be attacked from this point. If this cannot be done, the operator should cut into the sac and invert it.

Long and resistant adhesions are cut between two ligatures. If they are too short for that, they should simply be cut and the bleeding points caught with pressure-forceps.

Adhesions to the intestine are very serious. If an adhesion is string-shaped, it may be torn or tied between two ligatures. If it is broad, it may be severed by pulling on the sac or pushing this away from the intestine by means of a sponge on sponge-holder. If it does not yield readily, a piece of the outer layer of the sac is cut out, and left on the intestine (p. 469). If the adhesion is very extensive, it is better not to try to separate it at all, but either to desist altogether from the operation or be satisfied with an incomplete operation by marsupialization, as will presently be described.

If the intestine has been injured, it must be attended to, as even the smallest puncture may allow the contents to enter the peritoneal cavity, and as any place deprived of its peritoneal coat is apt to rupture.

A mere puncture may be seized with forceps and surrounded by a ligature. The edges of a longer tear must be brought together: if it is only peritoneal, they may be united with a continuous suture; but if the whole wall is torn through, the edges should be united by a Czerny-Lembert suture; that is, a double row, the inner comprising

the muscular layer and the peritoneum, but not the mucous membrane, the outer the peritoneum alone a quarter of an inch outside of the first. A fine cambric needle, threaded with the finest iron-dyed black silk, is used for this delicate work. The inner suture may be interrupted or continuous; the outer is always continuous.

If the intestine has suffered much, it may become necessary to excise a portion of it.

Small bleeding surfaces on the intestine may be seared by holding a Paquelin cautery at a short distance from them, or they may be touched with Monsel's solution. The injured part should be kept near the incision, so as to favor the formation of a fecal fistula in case healing fails to take place. Serious injury to the intestine is commonly fatal.

Special attention should be paid to the appendix vermiformis. If it is adherent to the cyst, and not easily detached, it should be cut off between two ligatures, and the surface remaining in the body thoroughly disinfected.

Adhesions to the mesentery are vascular. If possible, they should, therefore, be tied before cutting. If that is not feasible, they must be cut, and a suture passed under the bleeding part.

Adhesions to the omentum are common and bleed easily. They are best separated with a sponge squeezed dry. If they are extensive, a part of the omentum must be cut off, for which purpose it must be ligated in sections. A larger mass, however, can safely be tied by using the elastic ligature (p. 470). Large veins may extend all alone without being accompanied by other tissue from the omentum to the abdominal wall or down into the pelvis. They are easily torn, and must be severed between two ligatures. No rent should be left in the omentum, as the intestine may be caught in it and become strangulated. Its edges should be united with continuous catgut sutures or the whole cut off.

Adhesions to the liver and the spleen may cause severe hemorrhage. If they are not easily separated, it is better to leave part of the cyst-wall on the viscus. Bleeding from these organs may sometimes be stopped with Paquelin's cautery or Monsel's solution.

The operator should be careful not to tear the *gall-bladder*. If the accident happens, the tear must be comprised in the sutures closing the abdominal incision, temporarily establishing a biliary fistula. If this organ is badly torn, it is necessary to remove it entirely.

Adhesions to the pelvis are the worst of all, as they are broad, deep-seated, and may implicate the ureter or large vessels. If the tumor is small, it is best to sever them before emptying it. It may be necessary to do so guided by the touch alone, although a great help has been secured just for such cases in Trendelenburg's position (p. 136). It may be better to leave the outer layer of the cyst where it

is adherent or to cut off the free part of the cyst and stitch the remainder to the abdominal wound.

The *ureter* may have to be dissected out in order to free it from adhesions.

If the ureter is injured during a laparotomy, the injury is to be remedied in one of the following ways: if the wound is lateral, the edges should be united by suture and a catheter introduced by Pawlik's method (p. 161) beyond the wound; or, if that is not practicable, an iodoform tampon made according to Mikulicz (p. 176), should be left in contact with the sutured wound in order to save the peritoneal cavity, if the wound does not unite.

If the ureter is torn transversely, but the ends remain in contact with each other, the same course should be pursued.

If one of the ends has suffered much and is considerably displaced, nephrectomy should be performed at once, provided the patient appears able to stand the shock. If she is too weak, a provisional urinary fistula should be established by making an incision in the lumbar region, suturing the upper end of the ureter to it, and leaving a catheter in it. The other end is ligated and sutured to the lower end of the abdominal wound. If a fistula forms here, another catheter is introduced and left in it. A third is introduced through the urethra into the bladder. From all three catheters rubber tubes go into vessels containing a solution of boric acid. When the patient has recovered the kidney is extirpated.[1] Sometimes it is possible simply to introduce the upper end into the bladder and stitch it there.

If the *uterus* has been wounded, the bleeding may usually be stopped by passing a ligature under the bleeding point, by stitching some loose tag of peritoneum to it, or by searing it with the thermocautery. If, however, the hemorrhage cannot be checked in any other way, the uterus must be removed.

The cyst may be so *adherent everywhere* that it cannot be extirpated. In making the first incision the operator enters it, and the sac cannot be inverted. Then there is nothing to be done except to empty it, stitch it to the abdominal incision, wash it out, and pack it with iodoform gauze, which is changed every four or five days. Under this treatment the sac shrinks and fills with granulations.

If an irremovable cyst has *colloid contents* contained in numerous small compartments, the upper and lower ends of the incision should be seized with volsellæ and held up against the abdominal wall. The compartments should be broken up with one or more fingers or the whole hand.

Sometimes adhesions in the upper part may be overcome by seizing the lowest part from within and inverting it. In other cases it

[1] Pozzi, *Centralbl. f. Gynäk.*, Feb. 4, 1893, vol. xvii. p. 98.

suffices to let an assistant introduce his hand into the sac and put it on the stretch, while the operator severs it from its surroundings.

If the cyst contains much solid matter, it is best to tie the pedicle and extract the lower end first. If the solid matter is found below, while the upper part forms a large cyst, the trocar should be pushed through the lower solid part into the upper cystic part, thus giving an outlet to the fluid, and then the upper part pulled out first. If it becomes necessary to pull the intestine out of the abdominal cavity in order to sever adhesions or stanch bleeding, they should be laid on the upper part of the abdomen, and covered with cloths wrung out of warm salt water (p. 481). Trendelenburg's position has, however, rendered this evisceration superfluous in most cases.

Intraligamentous Development.—Ovarian tumors that develop in the broad ligament are usually papillary (p. 556). They are smaller, grow more slowly, and have fewer daughter-cysts. Their papillomas may rupture the cyst-wall and lie free in the peritoneal cavity or grow into neighboring organs. They are more malignant, and are very apt to cause metastatic infection of the peritoneum. They are difficult to remove, and special care must be taken to avoid infection. The uterus is at first pushed over to the other side by the tumor, later elevated and immovable. When the lower limit of the broad ligament is reached, the tumor may develop forward or backward. If it goes forward, it strips off the peritoneum from the abdominal wall, and thus it is reached in making the abdominal incision before the peritoneal cavity is opened. Such tumors may occasionally be removed without entering that cavity at all, but, as a rule, it becomes necessary to do so at a later stage of the operation. If the development takes place backward, the tumor separates the layers of the mesentery and comes to lie behind the large and small intestine.

The intraligamentous tumor may also burst through its peritoneal covering, so as to present an upper intraperitoneal and a lower extraperitoneal part. That portion which is free from the peritoneum has the usual pearl-gray color of ovarian cysts, while that which is covered with peritoneum is pink. In exceptional cases the tumor is even covered with a thick layer of unstriped muscle-fibers, which gives it the appearance of a uterine tumor.

The ovarian vessels enter the tumor at its outer border; the uterine follow the Fallopian tube and enter on the middle of the surface. The intervening part of the broad ligament may give way, so that the tumor has a double pedicle.

Smaller cysts with thin walls are often present, and the uterus usually lies in the angle between the chief cyst and the smaller ones.

Rarely the whole encapsulated cyst can be drawn out and removed entire by forming a pedicle of the broad ligament. If the outer and lower parts of the ligament are free, the surgeon may put

in a double row of sutures, beginning at the infundibulopelvic ligament, and cut the tissue that lies between each two sutures, whereby the deeper parts become more accessible. The following suture must always embrace part of the mass comprised in the preceding one, in order to avoid hemorrhage. (Compare Vaginal Hysterectomy, p. 497). Proceeding in this manner we get under the cyst and diminish its attachment, until finally the tube and the rest of the broad ligament can be enclosed in one ligature.

If the cyst extends down to the lower edge of the broad ligament, it can only be removed by enucleation (Miner's method),[1] which consists in stripping the cyst of its peritoneal covering, and leaving this or part of it as an empty sac. If the tumor does not rise much above the superior strait of the pelvis, this is done by making an incision through the peritoneum at the upper end of the tumor and pushing it down with fingers and blunt instruments. If, on the other hand, the cyst is large, it should be emptied and pulled out to the level of the abdominal wall. On account of the dangerous character of the fluid and the inner wall, the opening in the cyst should not be enlarged with the knife nor papillomata broken off, but the hole left by the trocar should be closed with forceps. Next, a small incision is made on the anterior surface in a transverse direction. The peeling is begun here, and it is gradually extended all around the circumference.

Before doing so the ovarian vessels should, however, be tied between two ligatures and cut; and if large veins are found in the involucrum, they must be disposed of in the same way. Branches of the uterine artery which are severed in cutting the peritoneum are also tied. When the ovarian ligament and the Fallopian tube come within reach, they should be tied and cut; and, finally, the uterine attachment is tied with one or more mass-ligatures. They include sometimes a part of the uterus itself, and it may even become necessary to perform supravaginal hysterectomy (pp. 472–477).

Often a large part of the uterus is left without peritoneal covering, and may bleed; which hemorrhage may be checked by passing a continuous catgut suture under the bleeding surface or inserting interrupted sutures under it or touching it with the thermocautery.

The development into the mesentery gives rise to considerable hemorrhage, which must be overcome by mass-ligatures. Pieces three or four inches wide may be ligated without causing gangrene of the intestine.

If a part of the cyst is imbedded in the pedicle, its inner layer

[1] Julius Francis Miner of Buffalo, N. Y., performed the first operation of this kind in 1869, and in the following year published the method (Atkinson, *Biographical Dictionary of Contemporary American Physicians and Surgeons*, Philadelphia, 1880, p. 45).

should be scraped out with a sharp curette or seared with Paquelin's cautery.

Sometimes, as a result of inflammatory processes, the peritoneum is so adherent to the intraligamentous ovarian cyst that in places it cannot be stripped off, but has to be dissected off from the tumor with a knife, or the separation made within the limits of the tumor itself. In these difficult cases the peritoneal covering is often torn, and severe hemorrhage may take place.

If papillomas have grown from the ovarian cyst into other organs, these parts are temporarily left, and after removal of the tumor they are, as far as possible, scraped out with nail or curette or cut out with the knife, to which treatment the uterus lends itself more readily than other organs.

At the base of the tumor a sharp lookout should be kept for the ureter, which runs in a nearly antero-posterior direction, and is recognizable by its hardness. Great care must be taken not to tear it, cut it, or comprise it in a ligature.

After the enucleation a large raw surface is left, which may be treated in different ways, as described in speaking of Fibroids (p. 479).

Pseudo-intraligamentous Ovarian Tumors.[1]—There is a kind of ovarian tumor which simulates intraligamentous tumors, but in reality is adherent to the posterior surface of the broad ligament, which it draws up in front, sometimes high up in the abdominal cavity. The upper end and the posterior surface of the tumor may be free or covered with a pseudo-membrane of peritonitic origin, which is entirely like the peritoneum. The bottom adheres to Douglas's pouch. These pseudo-intraligamentous tumors can hardly be diagnosticated clinically from the intraligamentous, except when the latter adhere with a broad surface to the vagina proper, situated laterally to and behind the uterus. The vagina is then immovably fastened to the lower pole of the tumor. A history of gonorrheal or puerperal peritonitis makes it likely that the tumor is pseudo-intraligamentous.

Even when the abdomen is opened, it may be quite difficult to recognize the true condition, and still it is of great importance, since it complicates the operation very much if the operator enters the space between the layers of the broad ligament.

Sometimes the tube may be separated from the tumor, and the separation continued along the posterior surface of the broad ligament, or one succeeds in getting behind and under the tumor and loosening it from the peritoneum in Douglas's pouch. The best way of removing the lower end of the tumor is to pull on the sac after freeing it from adhesions above, and tying the tube with a double ligature near the uterus, and severing it with the thermocautery.

Incomplete Operations.—Sometimes it is impossible to remove the

[1] K. Pawlik, *Ueber Pseudo-interligamentöse Eierstocksgeschwülste*, Wien, 1891.

[illegible] These three methods are at our com- [illegible] leave the remainder and [illegible] through the vagina. But if it is [illegible] it is better not to ope- [illegible] impossible to perform a [illegible] over subserous devel- [illegible] cancer which has spread to the sur- [illegible]

[illegible] stitching the edges of the tumor to [illegible] which has been [illegible] carry their young. [illegible] tumors. If it is [illegible] possible, the whole [illegible] should be scraped off. Some- [illegible] in other cases [illegible] to the abdomen. [illegible] the abdomen, the cyst- [illegible] incision. The [illegible] which is changed [illegible] adhesion has taken place, the cyst [illegible] The sac almost invariably [illegible] months or even a year, the patient's [illegible] may occur. [illegible] usually continues and [illegible] months. If, on the other [illegible] gradually with granula- [illegible]

[illegible] leave what cannot be re- [illegible]

[illegible] large blood-vessels that [illegible] the cyst, he may puncture [illegible] the opening with a [illegible] a drainage-tube in it [illegible] may give rise to a [illegible]

[illegible] the blood-supply of the tumo [illegible] ligament, an [illegible] with a curved needle fro [illegible] the uterus. If possible, th [illegible] opened, and drained. If th [illegible] is, however, not desirable [illegible] the danger of infection [illegible] and if it is not possible to stit

[illegible] vol. ii. p. [illegible]
[illegible] vol. xxiii. p. [illegible]

the cyst to the wall, the abdomen is closed, the dressing applied, the patient turned on her side, and the tumor tapped from the vagina. This is done by thrusting a pair of pointed scissors into the cyst and opening them widely on withdrawal. This will give us a free opening, by which we can both empty the sac and ensure free washing and

FIG. 307.

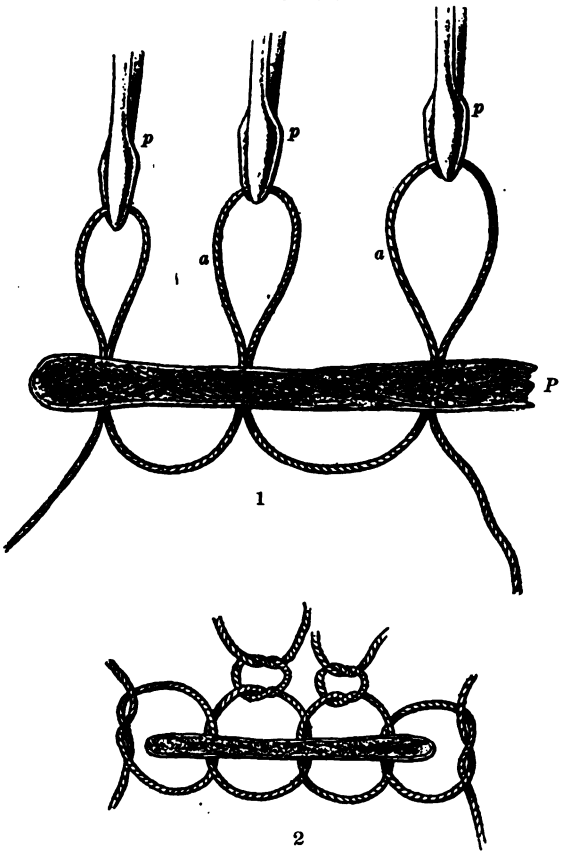

Wallich's Chain-ligature:—1. *P*, pedicle; *ppp*, pressure-forceps: *aa*, loops;—2, ligatures cut, crossed, and tied loosely.

drainage. A rubber tube should be stitched in the wound, or, better, the sac packed with iodoform gauze. Later on, from day to day, the mass may be broken down with a dull curette and the sac injected with diluted tincture of iodine of increasing strength, or peroxide of hydrogen.

The Pedicle.—If the pedicle is thick and short, there is danger of the outer part of the ligature slipping. This may be obviated by repassing it near the edge before tying it, or by first making a notch by passing a finer silk ligature around the pedicle one-third of an inch from the edge, and tying it before tying the thick pedicle-ligature.

If the pedicle is so short that the ligature encroaches on the uterus, it is a protection against hemorrhage to unite the edges of the peritoneal covering of the stump with sutures. If it is very thick, it is necessary to tie it in more than two parts by means of a *chain-ligature.* A long thread is carried with a handled needle through part of it, and seized with a pressure-forceps. Next, the long end of the same thread is carried through in one or more other places, and the loops secured in the same way. When all are in place, the loops

FIG. 308.

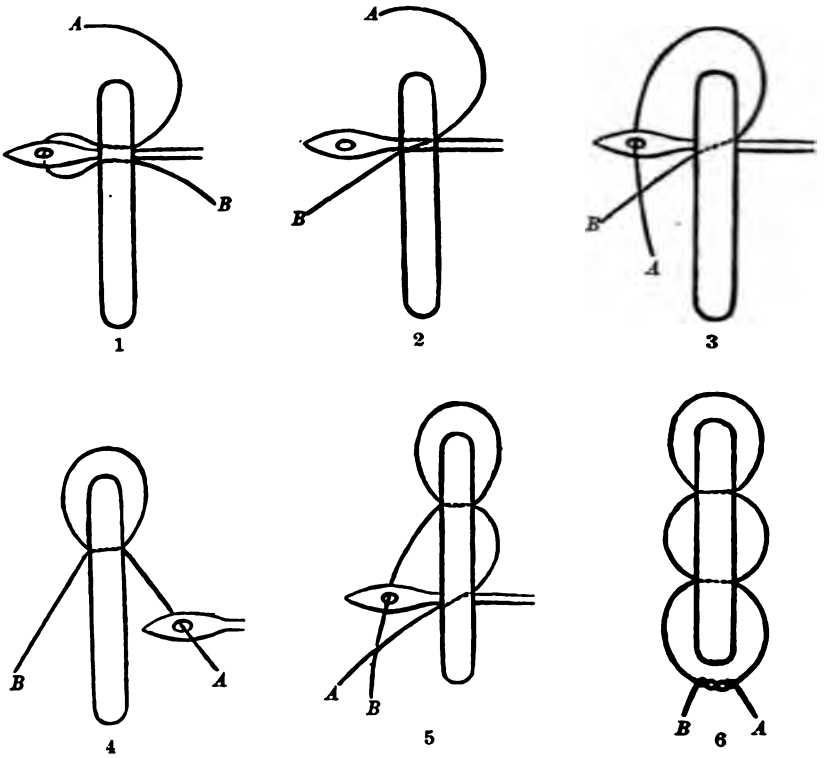

are cut, one after the other, near the forceps, and the halves crossed and tied, so that finally the whole mass to be ligated is enclosed in

threads, forming together a chain (Fig. 307). The pedicle may be cut gradually, leaving at least half an inch of tissue above the ligature, and for greater safety it is advisable to tie arteries visible on the cut surface with silk or catgut.

Robert Sanderson's Method (Fig. 308).—A handled needle, carrying a long silk thread, is inserted through the part of the pedicle farthest away from the operator (1). One end *A* is held by the assistant; the other end, *B*, is pulled out from the stitch-canal and the eye of the needle (2), the needle threaded with *A* (3), pulled back (4), and then pushed with *A* through another part of the pedicle. Now *A* is pulled out from the eye, *B* inserted (5), and the needle pulled back with *B*. Finally, the two ends are tied with a surgical knot over the last part of the pedicle (6). This does not tear the tissue, and compresses the whole pedicle tightly. It is only another way of making a *cobbler's stitch*.

In dealing with thick pedicles it is also useful to compress them with Spencer Wells's forceps, so as to form a notch before tying.

If a hematoma forms under the ligature of the pedicle, another ligature should be placed nearer the uterus. The blood between the two ligatures is left to be absorbed.

If the tube appears inflamed or if the stump contains parts of the cyst, the cut surface should be cauterized. If in combination with a pedunculated tumor we find metastatic masses behind the peritoneum, the latter must be left alone.

If the pedicle is so friable that the ligature cuts through, the single vessels must be secured with forceps left in the wound.

After the removal of a large tumor which has caused great distention of the abdominal wall, part of the skin and peritoneum inside of the recti muscles should be trimmed off before closing the wound.

Toilet of the Peritoneum.—If adhesions have been torn, and blood or other fluids, such as pus, cyst-contents, etc., have found their way into the peritoneal cavity, it must be cleaned, the technical term for which procedure is the *toilet of the peritoneum*. Sometimes it is enough to introduce a few sponges on sponge-holders into Douglas's pouch. If the bleeding is more profuse, or more objectionable fluids have found their way into the abdominal cavity, it should be flushed with hot water to which table-salt has been added in the proportion of 6 : 1000. This is poured into it from a pitcher or through a finger-thick glass tube. This saline solution comes very near the composition of serum, and attacks the epithelium less than plain water or antiseptic fluids. If there is still some oozing, the abdominal packing with iodoform gauze (p. 176) may be used. Only if there seems to be a decided hemorrhage, it is necessary to hunt for its source, and tie the bleeding vessel. Experience alone can guide the operator in this respect.

Hemostasis.—For arresting hemorrhage four methods are available—pressure, ligature, cauterization, and styptics.

A small hemorrhage may be arrested by simple pressure with a finger or sponge. A liberal use of pressure-forceps saves much time by avoiding many ligatures. Bleeding from larger surfaces in the pelvis may be arrested by packing it with sponges, pads, or cloths, which should be left in sometimes as much as fifteen minutes, while counter-pressure is being made from the vagina, and removed very cautiously, so as not to tear off newly formed coagula.

Sometimes long forceps have to be left in the wound till the next day, but this should be avoided as much as possible. It is better to pack the peritoneal cavity with iodoform gauze (p. 176). After the abdomen has been closed, pressure may yet be used to arrest oozing by means of a tightly fitting bandage or two bricks placed outside the dressing, combined with packing of the vagina and a bag filled with ice-water in the rectum (p. 450).

Bleeding from a large surface on the anterior abdominal wall may be checked by folding that part of the wall and excluding it from the abdominal cavity by passing some quilled sutures at the base of the fold, which are left in place for two days (Kimball's[1] method).

When blood may be expected to flow from both ends of a divided vessel, it is, if possible, cut between two ligatures. If this is not possible, it is cut, and both ends are seized and tied or compressed with artery-forceps. It is safest to tie the isolated vessel that bleeds, but often this cannot be done, and we must be satisfied with a mass-ligature embracing the surrounding tissue. Bleeding from a surface may be arrested by passing a continuous suture under it and drawing it together. Sometimes loose tags of peritoneum are used as a patch. Bleeding from the anterior abdominal wall may sometimes be arrested by tying the corresponding epigastric artery.

Cauterization has become quite convenient since Paquelin invented his thermocautery. It can be applied to bulky organs, such as the abdominal wall, the uterus, the spleen, and the liver; it can be used for cutting; and, held at a distance, it has even proved successful in dealing with hemorrhage from the intestine.

Tincture of iodine or Monsel's solution may be used as a styptic to smear on small surfaces of delicate organs, such as the intestine or bladder, but their use ought to be avoided whenever possible, as they form coagula which may become a source of inflammation or sepsis. Hot water is an excellent hemostatic, which operates by causing contraction of the capillaries.

In order to find the bleeding spot, it is sometimes necessary to enlarge the incision and even to draw out the intestine (p. 513). The search may be facilitated by throwing light into the abdominal

[1] Gilman Kimball of Lowell, Mass.

cavity with a concave mirror or, still better, with a portable electric lamp.

Much hemorrhage may be avoided by tying the pedicle as soon as possible, before beginning to separate adhesions.

Complications.—If a small *myoma* is seen in the uterus, it should be let alone, but its presence may be an inducement to remove the second ovary (p. 466). A large myoma may be in the way, and have to be removed according to circumstances (p. 466, *et seq.*).

If the ovarian cyst is accompanied by *ascites*, nothing should be done to remove the latter before the cyst is taken away, for the fluid serves as a diluent for cyst-fluid that may enter the peritoneal cavity.

If the patient is affected with an *umbilical* or *ventral hernia*, its sac should be dissected out, and the thinned and superfluous tissues covering it be cut away.

Complication with *pregnancy* has been considered above (p. 579). If the patient is not seen before *labor* has set in, and an ovarian tumor obstructs the parturient canal, the operator should try to push it up into the abdominal cavity in the genupectoral position—a treatment which is, however, only applicable to small tumors. A large tumor should be tapped from the vagina (p. 582). If it does not collapse sufficiently, an incision may be made in the vagina, and the tumor removed or diminished in this way. If it contains much solid matter, craniotomy or Cesarean section may be preferable. In the latter case ovariotomy should be added.

Drainage.—We have seen in the general part of this work (p. 182) that the most experienced laparotomists entertain very divergent views as to the use of drainage. While some look upon it as a fifth emunctory, of which they are very willing to avail themselves, others are loth to have recourse to it. In a general way it may be stated that it is indicated when pus or other irritant fluid has entered the peritoneal cavity during the operation; when sepsis or peritonitis is present; when there is much ascites, especially in connection with papillomata; when there are many or large raw surfaces left; when the bladder or intestine has been wounded during the operation or is found in a sloughy condition; and when the operator is in doubt about the efficacy of his hemostasis. In the last case, if a tube is used, it should be kept pumped out, as coagulation then takes place more readily than when blood accumulates in it.

If a tube is used, it should be without side holes, granulations being apt to grow into them; and even if the tube has no lateral openings, it is well to turn it on its axis once a day in order to prevent too firm adhesion. It is also well to lift the tube half an inch and let it drop back by its own weight, so as to avoid too much pressure and the formation of a fecal fistula.[1] But, as a rule, it is enough to leave the tube for one

[1] Wm. Goodell, Mann's *Amer. Syst. of Gynecol.*, vol. ii. p. 819.

or two days in the peritoneal cavity or an empty pouch. When only a teaspoonful of fluid accumulates in several hours, the tube can safely be withdrawn. If it is used in incomplete operations, it should be left in as long as there is secretion of pus. In the latter case injection with antiseptic fluid is made through it, whereas in completed operations no injections should be used, as they are apt to tear protective adhesions. A hole is cut for the tube in the dressing; a piece of gutta-percha tissue is drawn tight up to the flange of the tube and folded over some loose iodoform gauze outside the dressing, which allows us to change the gauze and empty the tube without disturbing the dressing. In order to avoid secondary infection of the sutures, it is well to use silver wire for the two that are in direct contact with the tube. One of them should be left open until the tube is removed.

The tube has to a great extent been replaced by iodoform gauze, which has the advantage of being soft and of helping to check hemorrhage. It may be left in place from three days to a week.

The objections to the use of drainage in the peritoneal cavity are that it irritates the peritoneum, may cause uncontrollable vomiting, interferes with free movements of the intestine, predisposes to intestinal obstruction, the formation of fecal fistula and ventral hernia, and maintains a danger of infection.[1]

Some prefer drainage through the vagina, a method which has already been referred to in speaking of enucleation of fibroids from the broad ligaments (p. 479), which is particularly indicated in cases in which the tumor extends far down into Douglas's pouch, and by which ventral hernia is avoided. It is established by means of iodoform gauze or a soft-rubber drainage-tube. Two fingers are passed up through the disinfected vagina to the posterior vault. An opening is made from above through the bottom of Douglas's pouch with scissors or trocar, and dilated with forceps or an expanding dilator, until a finger can easily be passed through it. A strip of iodoform gauze, four inches wide, is passed through from above into the vagina, and packed in or around the part from which one wishes to drain. After closure of the abdominal cavity the vagina is packed with iodoform gauze. If there is a rise in temperature, the vaginal packing should be removed, and the abdominal gauze pulled out a few inches, which produces free drainage. At the expiration of from eight to twelve days the last of the abdominal gauze should be withdrawn. If there yet is a purulent discharge, a soft-rubber drainage-tube with crossbar should be introduced instead.[2]

Shock.—The sudden giving out of vitality called *shock* is very

[1] A strong plea in its favor is made by E. W. Cushing of Boston, Mass., supported by Lawson Tait and Bantock, in *Annals of Gynecology*, Nov., 1890, vol. iv. p. 69.

[2] H. T. Hanks, "Counter-drainage after Cœliotomy," *The Post-Graduate*, No. 4, 1893.

dangerous, and calls for immediate attention. We have already spoken of this condition in treating of the operations for uterine fibroid (p. 481). Much may be done to prevent it, not only by proper attention to the anesthesia, but by preventing hemorrhage, by keeping the patient warm, by avoiding as much as possible handling the intestine,[1] and by abbreviating the duration of the operation as much as other considerations allow.

If it threatens, death may yet be averted by the hypodermic injection of digitalis and strychnine, the intramuscular injection of camphor (p. 204), the rectal injection of hot water, or injection into the peritoneal cavity of a hot saline solution (p. 481), and by finishing the operation in the shortest possible time.

Complications during After-treatment.

Shock.—If shock is present after the patient has been brought to bed, she should be roused (p. 216) and stimulated as just described.

Vomiting.—If the patients vomits, the medicine with hydrocyanic acid mentioned on p. 204 should be administered. Deep inspirations may be tried, by which air containing remnants of the anesthetic is expelled from the deeper part of the lungs. If vomiting continues at a time when the patient should take food, the different modifications of milk—peptonized milk, kumiss, or matzoon—can often be retained when everything else is rejected. If the patient vomits everything ingested, she must be fed by rectal alimentation, for which milk, eggs, and beef extracts are particularly useful. As a rule, an ounce of brandy should be added. The whole enema, in order to be retained, should not be more than four ounces.

If vomiting accompanies intestinal obstruction, calomel is the best remedy.

Internal Hemorrhage.—After bloody operations the patient may be very weak and restless, with a weak, rapid, and irregular pulse; but if there is no bleeding, this condition will yield to the free use of stimulants.

Real hemorrhage comes nearly always from the pedicle, rarely from large raw surfaces. If a drainage-tube has been left in the abdomen, the continuous reproduction of pure blood furnishes the diagnosis. Otherwise it must be made by the general condition of the patient—weakness; restlessness; weak, rapid pulse; cold, clammy skin; and swelling of the abdomen. Then only two sutures should be removed, which will suffice to ascertain the presence of blood in the abdominal cavity. If it is found, the whole wound must be reopened, and the source of the hemorrhage—first of all, the pedicle—looked for.

[1] Goltz has shown that a continuation of small, insignificant raps on the belly of a frog kills it.

When found, the bleeding is arrested by means of ligatures, and the cavity cleaned and closed again. If the patient has lost much blood, a subcutaneous injection of saline solution (p. 481) may prove of great value.

Tympanitis without inflammation is much relieved by the introduction of a soft-rubber rectal tube; by enemas with turpentine (ʒss to Oj), sulphate of quinine (gr. v every four hours), or mentha viridis (ʒij to aquæ Oj); by the administration of tinct. nucis vomicæ or tinct. capsici (♏v every hour), or large doses of subnitrate of bismuth (gr. xxx–xl); by standing the patient on her head; by nicking the plaster straps crossing the abdomen, drawing up her knees, using faradization, or puncturing the transverse colon.

Elevation of Temperature.—The temperature should not rise above 100° Fahr. As soon as it does, the cause should be looked for, which may be constipation, emotions, suppuration of a stitch-canal, a mural abscess, peritonitis, or sepsis. An ice-bag or rubber coil with running ice-water should be applied outside of the dressing. Antipyretic drugs should be administered. One or more sutures may be removed to give exit to pus.

If the temperature rises more than two degrees above the normal average, and swelling of the abdomen announces approaching peritonitis, the bowels should be moved at once, which may be done with sulphate of sodium, a teaspoonful every hour, and an enema with ox-gall (p. 169) given in the mean time.

Suppression of Urine.—If the secretion of urine stops, it should be promoted by giving digitalis and acetate of potassium.

If a ureter has been tied or injured, a urinary fistula may form in the vagina, which should not be interfered with until the patient has recovered. Hydronephrosis has developed, and been cured by extirpation of the corresponding kidney. In another case a cure was effected by pushing a trocar through the urethra and bladder into the abnormal reservoir, and leaving the canula till healing had taken place.

Intestinal obstruction is marked by constipation, vomiting, and tympanitis. It is often due to adhesion between the stump of the pedicle and the intestine, and is now-a-days, as a rule, avoided by moving the bowels early. If this grave complication occurs, large ox-gall enemas (p. 169) should be given. By using a fountain syringe and low pressure (p. 170) several quarts may be injected. Calomel is the best aperient, because it is least likely to be vomited. Tinct. belladonnæ or atropine may help to relax the bowel. If these milder means fail, the abdomen must be reopened, and the obstruction removed manually.

Septic Peritonitis.—In spite of all antiseptic precautions, some patients develop peritonitis, which is probably always of septic origin,

and may lead to general septicemia and death. The infection cannot always be blamed on the operator, as it would seem that pathogenic microbes can find their way through the wall of the intestine to the peritoneal cavity (p. 482), where they find an excellent soil in blood and serum. Often the drainage-tube has been the door through which infection has entered.

Peritonitis develops, as a rule, within four days. It is characterized by green vomit, tympanitis, tenderness of the abdomen, and a frequent pulse. Often there is no rise in the temperature, which, on the contrary, may be subnormal.

The bowels should be moved at once, five grains of quinine given every four hours, brandy administered freely, and an ice-bag or ice-water coil applied to the abdomen. Finally, the wound may be reopened and the peritoneal cavity washed out with peroxide of hydrogen, but the chance of recovery is then slim, indeed.

If peritonitis supervenes as late as ten to fifteen days after the operation, it is probably due to mortification of the pedicle or other large masses that have been ligated, and treatment is then nearly powerless.

A mural abscess is recognized by hardness and tenderness of the affected part. A small opening should be made and a drainage-tube inserted. If the abscess has formed around a suture, this should be removed, the pus pressed out, and the dressing changed daily.

A *deep abscess* may be made out by bimanual examination. If it lies close up to the vagina, it should be opened and drained from that point. If not, the abdomen must be reopened, cleaned, and drained either through the skin or through the vagina.

Emphysema of the abdominal wall is rare, but is of importance, in so far as it predisposes to the formation of an abscess.

Spontaneous reopening of the wound is an unfortunate occurrence that may to a great extent be prevented by keeping the bowels open, by not removing the sutures too soon (some think they ought even to be left in for ten days), and by replacing them by plaster strips, as recommended above (p. 591). If it happens, the patient should be anesthetized, and new sutures put in. It may be so difficult to replace the intestine that it becomes necessary to puncture it and let the gas escape. Before replacing it it should be washed with the solution of chloride of sodium.

Sometimes a *fistulous tract* leads into the abdominal cavity, and resists healing for a long time. Patients affected with tuberculosis, syphilis, or cancer are predisposed to this untoward accident. In most cases it is due to the mechanical irritation caused by a drainage-tube or suture- and ligature-material. Sometimes the cause is sepsis. It not only protracts convalescence, but may lead to the formation of a fecal or urinary fistula, nephritis, and exhaustion. Many such

fistulæ heal by nature's sole efforts under favorable hygienic circumstances, and the use of nourishing food. Daily irrigation with hot water or mild antiseptic fluids contributes, however, much toward a favorable result. Sometimes much time can be saved by dilating the fistulous canal sufficiently to introduce a fine pair of forceps and pulling out a ligature from the bottom. Packing with iodoform gauze or marine lint soaked in Peruvian balsam is also often useful. Strong fluids and severe manipulations must be avoided, as they may make the condition worse by wounding the intestine.[1]

Fecal fistula is a rare complication. It is due to injury of the intestine during the operation or to pressure from a drainage-tube. It may occur as late as two or three weeks after the operation.

The accident may be prevented by enlarging the abdominal incision, if there are many adhesions, and using Trendelenburg's position, so as to obtain a view of adhesions that implicate the intestine; by using iodoform gauze as a drain instead of hard tubes; and by using silk, not catgut, in repairing injury to the intestine.

To operate for fecal fistula is dangerous and unnecessary, for, as a rule, it closes spontaneously within a year. The fistula should be tamponed with marine lint soaked in Peruvian balsam, or gauze impregnated with iodoform, aristol, or dermatol, and the dressing renewed daily. When the opening in the bowel becomes very small, the intestines should be emptied by a cathartic, then kept at rest for a week, and then again moved by enemas. When the hole in the intestine is closed the same dressing should be kept up until the sinus heals up from the bottom.[2]

Tetanus is also a rare complication, and the prognosis is very bad. It should be treated with chloroform, chloral, and curare.

Phlebitis occurs sometimes. The affected leg should be raised on pillows, painted with tincture of iodine, wrapped in cotton batting and slightly compressed with a roller-bandage.

Great care should be taken not to press much on the swollen vein, as a clot may be detached, and cause sudden death by embolism of the pulmonary artery.

Parotitis is a rare occurrence. The swelling of the parotid gland may simply be due to the mysterious consensus between that organ and the genital gland, also frequently observed in man. It is then of slight importance, and soon ends in resolution. But it may also be part of a septic infection, and then it has a tendency to suppurate, and is a serious complication.

Mental Aberration.—In rare cases ovariotomy is followed by mania,

[1] A valuable paper on this subject by Andrew F. Currier of New York is found in *Annals of Gynæcology*, July, 1892, vol. v. No. 10, p. 577.

[2] An interesting paper on fecal fistulæ after laparotomy by A. Palmer Dudley is found in *Amer. Jour. Obst.*, Feb., 1892, vol. xxv. pp. 145–163.

melancholia, and temporary or permanent insanity. This complication is most apt to arise in patients with a hereditary predisposition.

If both ovaries have been removed, menstruation stops, as a rule, but may continue for a few months. (Compare pp. 118 and 515.)

If one ovary has been left behind, pregnancy may occur, and it, as well as the ensuing childbirth, offers nothing abnormal, except that the cicatrice is subjected to such a strain that it needs protection by means of an abdominal belt.

If both ovaries have been removed, the patient is, as a rule, sterile. (In regard to an exception to the rule and its explanation, see p. 525.)

Prognosis.—The technique of ovariotomy has been brought to such a degree of perfection that in the hands of the most skillful operators the mortality has been reduced to 5 per cent. Circumstances that make the prognosis good are a good constitution, a hopeful disposition, absence of disease in other organs, a unilocular or paucilocular cyst, a good pedicle, and absence or easy separability of adhesions.

Death is commonly due to shock, hemorrhage, peritonitis, or septicemia, to which are added the rarer causes, such as exhaustive suppuration, uremia, tetanus, or embolism.[1]

B. *Solid Ovarian Tumors.*

Solid ovarian tumors are much rarer than cystic tumors of the ovary and solid uterine tumors. They may be *fibroids, papillomas, sarcomas, endotheliomas, carcinomas,* or *tuberculous.*

I. *Fibroma.*

Pathological Anatomy.—Fibroids of the ovary are usually small, not larger than a hen's egg or an orange, but may reach the size of an adult's head, or even become enormous, weighing over sixty pounds. They are smooth, globular, and nodular, like uterine fibroids; but, unlike them, if they do not comprise the whole ovary, they are intimately connected with the surrounding tissue, and cannot be shelled out. They may be hard or so soft as to become fluctuating. They are most frequently found on one side only, but may be bilateral. They may be *diffuse—i. e.* comprise the whole ovary—or *circumscribed,* occupying only a part of it, and then generally the outer end, while the remainder is in a condition of chronic oöphoritis (p. 535).

The cut surface shows translucent gray or yellowish places alternating with opaque white ones. The follicles have disappeared. The tissue is composed of fine fibrillar connective tissue, peculiarly rich

[1] H. C. Coe has in a most excellent paper in *Trans. Amer. Gyn. Soc.*, 1889, vol. xiv. pp. 170–191, based on personal observation, discussed "Death from Visceral Affections after Ovariotomy."

in long spindle-cells. Sometimes it contains smooth muscle-fibers, in other cases none.

As a rule, the mesoarium is preserved, forming a pedicle to the tumor, but when this grows large it may invade the broad ligament, and become sessile. The tube is not implicated in the pedicle, unless the tumor becomes very large. The tumors are generally accompanied by ascites, which prevents the formation of inflammatory adhesions as long as they remain small. Sometimes they are found together with myoma of the uterus.

They may undergo the same *changes* as uterine fibroids. They may become cystic, a transformation which is due to the dilatation of lymph-spaces in the connective tissue, so-called *geodes*, hollows filled with a coagulable serous fluid. Such cystic fibroids are called *cystofibromas* or *fibrocysts*. Fibroids may undergo mucoid, fatty, or cancerous degeneration, or become calcified or ossified or cartilaginous. Internal hemorrhage, suppuration, and gangrene may occur in consequence of torsion of the pedicle or pressure during childbirth.

Origin.—The fibroma may originate in the albuginea or in a corpus luteum.[1]

Etiology.—The etiology of ovarian fibroids is unknown. They are more common in young women than later in life.

Symptoms.—Commonly there are menstrual disturbances, such as amenorrhea, dysmenorrhea, or irregular menstruation. The tumor causes more pain than uterine fibroids. It grows very slowly. Ascites develops frequently and early. If the tumor acquires large proportions, all the pressure-symptoms described in speaking of uterine fibroids (p. 458) may be developed. As a rule, the tumor is freely movable.

Diagnosis.—It may be difficult or impossible to distinguish an ovarian fibroid from a *pedunculated uterine fibroid*, unless both ovaries can be felt, which, of course, excludes an ovarian tumor. The ovarian tumor causes more pain. A *malignant tumor* grows more rapidly. A fibrocyst of the ovary, if not movable, closely resembles a uterine fibrocyst. In the latter the sound will, however, generally show a greater depth of the cavity. A fibro cyst of the ovary can hardly be distinguished from other ovarian cysts. It may, therefore, often be necessary to perform exploratory laparotomy before a positive diagnosis can be arrived at.

Prognosis.—The tumor may become dangerous by its size. It may oppose an insurmountable obstruction to childbearing, and necessitate Cesarean section. It may undergo dangerous changes, as mentioned

[1] Those who are more particularly interested in the pathology of ovarian fibroids will find an interesting monograph on the subject by H. C. Coe in the *Amer. Jour. Obst.*, July and Oct., 1882, vol. xv. p. 561, *et seq.*

above. Death may result from peritonitis, nephritis, uremia, intestinal obstruction, or an embolus in the pulmonary artery.

Treatment.—*Electrolysis* is said to have caused a diminution of the tumor, but it is not known if the result is permanent. It should only be used if an operation is absolutely refused. The true treatment called for is abdominal *ovariotomy*, which ought to be performed as soon as the tumor is found.

II. *Papilloma.*

We have seen above (p. 556) that a whole class of ovarian cysts is characterized by the presence of papillary growths in the interior, which may perforate the wall, and enter the peritoneal cavity. Similar papillary growths may develop on the surface of a solid ovary or the wall of a glandular cyst.

They are, as a rule, accompanied by ascites. They may be small like warts, or become as large as a fist, and extend to neighboring organs.

Etiology.—Gonorrheal salpingitis has in several cases preceded this formation.

Prognosis.—It has a tendency to become malignant.

Treatment.—The treatment consists in early ovariotomy.

III. *Sarcoma.*

Sarcoma of the ovary is a rare affection.

Pathological Anatomy.—It may be primary or develop secondarily in an ovarian cystoma. It is often bilateral. It forms pink tumors ranging in size from that of a child's fist to that of a man's head, or may even acquire enormous proportions. It is globular or oval, and has a smooth surface, with varying consistency according to the composition, the pure sarcomatous growth and cystosarcomas being much softer than fibrosarcomas. Often small cysts project slightly from the surface. Like other solid ovarian tumors, it is commonly, and at an early date, accompanied by ascites, which prevents the formation of adhesions.

It is rich in blood-vessels, and may become cavernous, forming large cysts. The follicles are destroyed. It may be combined with sarcoma of the uterus.

Spindle-celled sarcoma is the most common variety, but round-celled and mixed-celled sarcoma are also found. The variety known as alveolar sarcoma has likewise been observed. The sarcomatous tissue may be combined with myxomatous, fibrous, or carcinomatous tissue (*myxosarcoma, fibrosarcoma, sarcoma carcinomatosum*) or a new formation of glands (*adenosarcoma*).

The sarcomatous tissue may undergo changes, especially fatty degen-

ovary, but later it becomes more globular. It has a nodular surface, a whitish color, and varies in consistency from considerable firmness to brain-like softness.

At first the mesoarium forms a pedicle, but later this may become infiltrated, thickened, and hard, and finally the tumor may be entirely sessile. At an early date ascitic fluid accumulates, which is often mixed with blood; local peritonitis is of frequent occurrence; and the degeneration extends to neighboring organs, such as the peritoneum, the pelvic connective tissue, the bones, the lymphatic vessels or glands, especially those of the lumbar region, or to the uterus; or metastases appear in the liver, the lungs, the spleen, and other remote parts of the body.

It seems that the carcinomatous degeneration originates in an atypic proliferation of the epithelium of the Graafian follicles or pouches extending from the germinal epithelium into the interior of the ovary (p. 563).

Secondary carcinoma of the ovary is brought through the lymphatics, cancerous epithelial cells being carried into these vessels, in which they cause thrombosis and infection of the surrounding tissue.[1]

Like other tumors, carcinoma of the ovary may undergo secondary changes, especially fatty degeneration, which leads to the formation of cystic cavities with ragged walls of carcinomatous tissue—a condition called *cystocarcinoma*.

Etiology.—Carcinoma rarely attacks the healthy ovary, while, as we have seen, it often occurs in ovarian cystomas. Its cause is unknown. It is found in young women, and even in children, most commonly near the two ends of menstrual activity, puberty or the menopause.

Symptoms.—The disease may begin as an acute inflammation or develop gradually. It is characterized by amenorrhea, pain, rapid growth, local peritonitis, ascites, edema of the thighs, and general marasmus.

Diagnosis.—It is distinguished from fibroid and sarcomatous tumors by the unusually rapid development, greater pain, edema of the thighs, and the presence of tumors in Douglas's pouch, the lumbar region, the omentum, stomach, liver, or spleen.

The ascitic fluid accompanying malignant ovarian tumors (carcinoma, sarcoma, or papilloma), obtained by aspiration, contains sometimes large round or pear-shaped cells, with a large nucleus, either isolated or in groups.[2] Much more conclusive than aspiration is, how-

[1] This is proved by actual observation of microscopical specimens from a carcinomatous tumor of the pelvic floor and the ovaries belonging to it, by M. Dixon Jones, *Med. Record*, March 11, 1893, vol. xliii. No. 10, p. 295, *et seq.*

[2] Garrigues, *Diagnosis of Ovarian Cysts*, pp. 94–97.

exploratory incision, which enables us to feel the nodules on the ovary, and perhaps on other parts, and to judge whether an extirpation should be attempted or not.

Treatment.—If performed early, ovariotomy may effect a radical cure. If the neighboring organs are implicated, it may yet give relief from painful tension for several months. But if other tumors are felt beside the ovary, the operation is contraindicated.

VI. *Tuberculosis.*

Next to the tubes and the uterus, the ovary is the part of the genital tract most commonly affected by tuberculosis. It may be *primary* or *secondary*. It may be part of general tuberculosis, and is then brought to the ovary through the blood, but it may also reach the ovary through the genital canal.

Pathological Anatomy.—Miliary tubercles are rarely found. The affection may be limited to the surface or invade the whole organ. The ovary is then somewhat enlarged, soft, and contains cheesy deposits ranging in size from that of a millet-seed to that of a marble. These tuberculous nodules may soften and rupture into the peritoneal cavity, causing peritonitis. The surface of the ovary is commonly covered with layers of inflammatory exudation and adhesions.

Symptoms.—The symptoms are those of chronic oöphoritis.

Diagnosis.—The disease can only be diagnosticated, if swelling of the ovary is combined with pulmonary tuberculosis or local tuberculosis of the visible part of the genital canal, or if the discharge from the uterus contains cheesy masses and tubercle-bacilli.

Treatment.—If the affection is primary, salpingo-oöphorectomy may lead to a cure. If it is combined with pulmonary tuberculosis, and the disease has been checked in the lungs, the removal of the appendages is still indicated. If it is allied to a similar affection of the tube and the uterus, hysterectomy may be added (p. 466). Even miliary peritonitis may be cured by the operation. On the other hand, the operation is counterindicated as long as the disease spreads to the lungs. If no radical cure is possible, the usual medical and hygienic treatment is all we have to rely on.

CHAPTER VI.

OÖPHORALGIA.

THE ovary may be the seat of neuralgia. In most cases this forms only part of hysteria, but the disease may be found in women

Dr. G. M. Tuttle of New York has reported a case of apparently primary tuberculosis of the ovary in *Amer. Jour. Obst.*, Jan., 1890, xxiii. p. 68.

who show no other symptoms of that affection. It may be of malarial origin.

The left ovary is affected much more frequently than the right, for which circumstance we may, perhaps, find an explanation in its contact with the rectum, the contents of which are apt to press on the ovary on this side, or the different disposition and construction of the ovarian vein on this side (p. 74). Sometimes the affection is bilateral. The pain is spontaneous, or may be produced by pressure on the ovary. It is felt in the hip, shooting back to the lumbar region or down the leg, and is so severe that the patient can neither be moved nor stand. Very often it is combined with hemianæsthesia of the corresponding side and hystero-epileptic seizures. Pressure on the ovary produces, first, cardialgia and vomiting; next, palpitations, with frequent pulse and globus hystericus; and, finally, often a hissing sound in the corresponding ear, pain in the temple, darkening of the eyesight, loss of consciousness, and convulsions.

While pressure on the ovary may produce such an attack, it can also check a spontaneous one.

Diagnosis.—In *chronic oöphoritis* the ovary is enlarged, and often uneven and fastened by adhesions.

Treatment.—The treatment consists in rest, anodynes, galvanism, faradization with the secondary current of high tension (p. 221), and tonic and antihysteric remedies. If the disease is malarial, it yields to large doses of quinine.[1] Oöphorectomy has sometimes a marked beneficial effect, but is in many cases fruitless.

[1] Case of H. C. Coe, *Amer. Jour. Med. Sci.*, April, 1891, vol. ci. p. 365.

PART VII.

DISEASES OF THE PELVIS.

UNDER this title we describe the affections of the peritoneum, the connective tissue, and the blood- and lymph-vessels of the true pelvis, including the ligaments of the uterus.

CHAPTER I.

MALFORMATIONS.

IN speaking of the uterus (p. 381) we have mentioned that lateroposition is due to an uneven development of the two broad ligaments, anteposition to defective development of the parts situated in front of the uterus, and retroposition to a similar defect in those behind it.

Perhaps some cases of congenital anteflexion and anteversion originate in too great shortness of the round ligaments.

The peritoneal pouch, which in the fetus forms the canal of Nuck, and normally is transformed to a fibrous string, may remain open. It may either remain in connection with the abdominal cavity or be closed at the upper end and become the seat of hydrocele, or form a sheath around the round ligament, which must be pushed back in Alexander's operation (pp. 59, 254, and 435).

CHAPTER II.

ANEURYSM OF THE UTERINE ARTERY.

I AM not aware that more than one case of aneurysm of the uterine artery has been reported.[1] Upon vaginal examination there was found a pulsating tumor in the pelvis of the size of a hazelnut, which was diminished by pressure, but refilled again each time pressure was discontinued. It gave a subjective sensation of throbbing. It was supposed to be due to the use of leeches in the vagina, and

[1] Mars, *Excerpta Medica.* No. 2, Nov., 1891.

might, perhaps, also be due to childbirth. The treatment recommended is galvanopuncture, with the positive pole in the tumor, or forcipressure.

CHAPTER III.

Diseases of the Broad Ligament.

A. *Varicocele of the Broad Ligament, or Parovarian Varicocele.*

Varicocele in the female corresponds to the same condition in the male, but the different anatomical relations constitute rather considerable differences between the two. While in man the veins of the testis follow an almost perpendicular course, those of the ovary are nearly horizontal. The spermatic veins soon form a single trunk, whereas the pampiniform plexus in woman communicates freely with the uterine, the vaginal, and the vesical plexus. There will, therefore, be less tendency to the disease in woman than in man. As a matter of fact, it is about three times less common in female cadavers than in male, and is rarely recognized in the living subject, although we may be sure that the swelling must have been much larger during the patient's lifetime than after death.

By varicocele we do not mean the enlargement of veins in the broad ligament which accompanies tumors, especially uterine fibroids, but an isolated swelling of the ovarian veins, implicating more or less the other veins of the broad ligament. It has been divided into *superior* parovarian varicocele when it is situated between the ovary and the tube, and *inferior* parovarian varicocele, when it is found below the ovary. It may reach the size of a hen's egg, and is composed of a conglomeration of veins, the walls of which are often thickened, and which may contain phleboliths. It is much more common on the left side, but may be found on the right or on both, the preponderance on the left side being without doubt due to the lack of a valve in the left ovarian vein, and to the fact that it opens at right angles into the renal vein (p. 74).

Etiology.—The condition is probably due to subinvolution after confinement; a relaxed condition of the tissues following a low state of the general health; an original weakness of the walls of the veins; pressure from fecal accumulation in the sigmoid flexure, which lies in front of the ovarian vein; or displacements of the uterus, especially retroversion and retroflexion, which interfere with the free return of the blood through the infundibulopelvic ligament.

Symptoms.—The most prominent symptom is pain of a peculiar dull, aching character, extending up the side to the region of the kidney. The pain disappears when the patient is in the horizontal posi-

tion, and is increased by standing erect. By bimanual examination with one finger in the rectum a distinct doughy tumor or knotted swollen vessels may be felt in the broad ligament.

Prognosis.—Some patients suffer so much that they are unable to stand or walk, and are bedridden invalids for years. The dilated veins may rupture, and form a hematocele or hematoma (see below).

Diagnosis.—*Salpingitis* causes a sausage-shaped tumor; *oöphoritis* is harder and more painful; *cellulitis* and *pelvic peritonitis* have more diffuse contours, and none of them becomes smaller in the recumbent position. A swollen vein may be confounded with a swollen ureter, but in the latter condition other symptoms of a pathological state of the uropoietic organs are present.

Treatment.—If the condition is recent, hot douches, tincture of iodine, ichthyol glycerin, or faradic electricity, combined with frequent rest in a recumbent position and attention to the bowels, may effect a cure. If it is old enough to have produced permanent dilatation of the veins and thickening of their walls, nothing is likely to be of avail except an extirpation of the affected part of the broad ligament, together with the tube and ovary; which may be done by tying it with the cobbler's stitch or some other form of a chain-ligature, and cutting the parts away above the ligature.[1]

B. *Cysts of the Broad Ligament.*

Not every cyst situated *in* the broad ligament is a cyst *of* the broad ligament. We have seen above (p. 561) that ovarian tumors may develop downward into the broad ligament and even far beyond its base. A Graafian follicle or a corpus luteum may form such a cyst. By a cyst *of* the broad ligament is meant a cyst developed in the broad ligament outside of the ovary. Such cysts are sometimes called *parovarian cysts*, but this name is not quite correct, for the parovarium is a definite organ found in a definite locality, and, if it is true that such cysts may develop in it, it is no less true that they may develop in any other part of the broad ligament. The schematic figure 309 gives a good idea of the locality of such cysts.

Cysts of the broad ligament are much rarer than ovarian cysts. As a rule, they are monocystic, but exceptionally polycystic tumors of this origin have been found. Commonly, they do not exceed the size of a pregnant uterus at six months' gestation, but exceptionally they may become enormous.

As a rule, the wall is so thin as to be translucent or transparent, but in exceptional cases the cyst may look like a uterine growth on

[1] The disease has been described, with report of four cases in which laparotomy was performed successfully, by A. P. Dudley of New York in the *N. Y. Med. Jour.*, Aug. 11 and 18, 1888—a paper that has been severely, and in my opinion rather unjustly, criticized by Coe in *Amer. Jour. Obst.*, May, 1889, vol. xxii. p. 504.

account of a thick layer of smooth muscle-fibers. The wall is composed of the peritoneum with its endothelium; a layer of connective tissue containing some plain muscle-fibers; often glands, which do not open into the interior; and very few blood-vessels, which gives it a

FIG. 309.

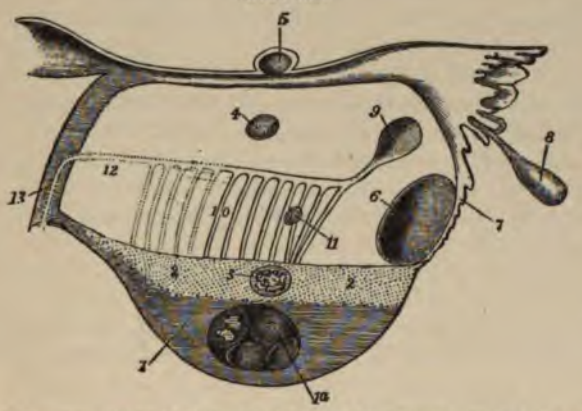

Diagram of the Structures in and adjacent to the Broad Ligament (Doran): 1, framework of the parenchyma of the ovary, seat of 1 *a*, simple or glandular multilocular cyst; 2, tissue of hilum with 3, papillary cyst[1]; 4, broad-ligament cyst independent of parovarium and Fallopian tube; 5, similar cyst in broad ligament, above the tube, but not connected with it; 6, similar cyst developed close to 7, ovarian fimbria of tube; 8, the hydatid of Morgagni; 9, cyst developed from horizontal tube of parovarium; 10, the parovarium: the dotted lines represent the inner portion, always more or less obsolete in the adult; 11, small cyst developed from a vertical tube: 12, Gartner's duct; 13, track of the same in the uterine wall.

white color. Its interior surface is smooth or wrinkled, but has no glandular formations, and is covered with a single layer of vibratile, low columnar or flat epithelium. As a rule, these cysts extend right up to the tube, that becomes imbedded in the wall without mesosalpinx. Like ovarian tumors, they may develop below the broad ligament, and come to lie below, in front of, or behind the peritoneum. They may become so large as to be much more abdominal than pelvic tumors.

The *fluid* is normally watery, nearly colorless, and alkaline or neutral. It does not coagulate spontaneously, nor to any extent by heat before adding an acid. It contains a few cells and Bennett's large and small corpuscles (Figs. 284, 285, and 291, pp. 553–554). But in exceptional cases a thick colloid fluid has been found in such cysts.

Papillary and dermoid cysts may also develop in the broad ligament.

As a rule, cysts of the broad ligament are sessile, but sometimes

[1] This theory about the origin of the two kinds of ovarian cysts is not generally admitted.

the ligament forms a pedicle, which may even become twisted, an accident that may lead to gangrene of the tumor.

These tumors are found in the period of sexual maturity. They grow very slowly.[1] They do not impair the general health, and give rise to no symptoms except by their bulk.

Diagnosis.—A small cyst of the broad ligament may be felt in the pelvis separate from the ovary and tilting the uterus over to the opposite side. It may be so like *hematoma* that it cannot be distinguished from it except by the history, the latter developing rapidly, and being reabsorbed after some time. The distinction from *ovarian*, especially intraligamentous, and other abdominal cysts may be very difficult. The leading points are the slow development, slight pain, absence of cachexia, the low seat, absence of solid masses, a very distinct fluctuation-wave, flatness in front, and greater fullness in the flanks.

It is impossible to tell for sure, by the fluid alone, whether a tumor is ovarian or a cyst of the broad ligament, although the presumption may be strongly in favor of one or the other[2]: both ovarian cysts and cysts of the broad ligament may have serous or colloid contents, but the latter is common in ovarian cysts, rare in extra-ovarian, while the watery is common in extra-ovarian, rare in ovarian cysts. Still, it may be found, not only in true monocysts, but in multilocular cystomas of the ovary.

Treatment.—Small tumors of this kind should be let alone. When by their bulk they become troublesome, the best thing to do is to remove them exactly like an ovarian tumor. Sometimes there is a pedicle, and sometimes one can be made of the peritoneal covering during the operation. Enucleation is, as a rule, easy. If it meets with difficulties, the sac should be cut open and the left hand introduced to help the right hand separate the cyst from the peritoneum. After the enucleation the empty shell may be tied as a pedicle in one or more sections, or the edges may be stitched together with catgut, or they may be brought together as a purse and fastened to the abdominal wound. The cavity is packed with iodoform gauze, and will fill by granulation, but, as a rule, only with suppuration. If the tumor cannot be enucleated, the whole sac may be fastened to the abdominal wound (*marsupialization*). Redundant tissue is, of course, cut away in all these procedures.

Another way of operating is simply to cut out a large circular piece of the wall and close the abdomen.

These cysts used to be treated by *tapping* or *aspiration*, and their

[1] I have, many years ago, assisted in aspirating one that had been tapped five years before by W. L. Atlee, and in that time had not become larger than the uterus at the end of six months' gestation.

[2] Garrigues, *Diagnosis, etc.*, pp. 49–55.

innocuous nature and the slowness to refill of most of them are indeed great inducements to use that kind of treatment; but since it has been discovered that some of them are papillomatous, and the radical operation in most cases easy and safe, extirpation is preferred by most gynecologists.

If the ovary and tube are healthy and placed so that they need not be removed, they should be left behind.

C. *Solid Tumors of the Broad Ligament.*

Besides uterine fibroids which grow in between the layers of the broad ligament, and of which enough has been said in speaking of that disease, the broad ligament is occasionally the seat of solid tumors which take their origin in the ligaments themselves. Thus, myomas, fibromas—sometimes melting to fibrocysts—lipomas, and sarcomas, have been observed. Such tumors may push the vagina before them and protrude into the vulva, or grow out through the greater sciatic foramen, simulating a hernia.

All solid tumors of the broad ligament should be removed by laparotomy as soon as discovered.

CHAPTER IV.

Diseases of the Round Ligaments.

In an earlier part of this work (p. 256) we have said that any part of the round ligament may become the seat of a *fibroma*, and that this occurs more frequently outside than inside of the pelvis. The fibrous tissue is commonly blended with muscular, myxomatous, or sarcomatous tissue, constituting a *myofibroma*, *myxofibroma*, or *fibrosarcoma*. In one case the lymphatics were much distended (*fibroma lymphangiectodes*).

The affection is much more common on the right side than on the left. The *diagnosis* may be very difficult. The *treatment* consists in early extirpation.

CHAPTER V.

Diseases of the Sacro-uterine Ligament.

We have seen above (p. 426) that *inflammation* of the sacro-uterine ligament is a chief cause of anteflexion of the uterus. One or both ligaments are swollen, tender on pressure, and become shortened through cicatricial contraction.

The usual antiphlogistic treatment, especially ichthyol, glycerin, tincture of iodine, hot douche, and the galvanic current, is indicated, and often yields good results in fresh cases; and even a chronic shortening may be overcome by means of vaginal packing (p. 173).

Since these ligaments form the chief support of the uterus (p. 55), their loss of tonus and *elongation*, usually due to childbirth, are principal factors in the production of prolapse of the uterus (p. 440). The loss of tonicity may perhaps be remedied by the use of the faradic current or massage. If not, recourse must be had to pessaries, supporters, or the operations indicated for prolapse (p. 442).

CHAPTER VI.

Pelvic Hemorrhage.

Internal hemorrhage from the genitals and the parts near them takes place in three ways, differing widely from one another as to frequency, anatomy, danger, and treatment, and which it is, therefore, appropriate to designate by three different names and to describe apart from one another. Since, however, most authors follow a different course in this respect, it is necessary to add the other names under which the described conditions are known.

The blood may be poured freely into the peritoneal cavity. We call this simply *intraperitoneal hemorrhage*, but most writers class it with the second condition, and call it non-encysted hematocele or cataclysmic hematocele. Secondly, the blood may enter the peritoneal cavity, and become limited by inflammatory exudation, so as to form a tumor. We call this *hematocele*, but it has been designated as pelvic hematocele, intraperitoneal hematocele, or true hematocele (always comprising the free intraperitoneal hemorrhage). Finally, the extravasated blood may be situated in the connective tissue of the broad ligaments, the pelvis, and the abdomen. This condition we designate as *hematoma*, but it is also called extraperitoneal hematocele, false hematocele, pseudohematocele, or thrombus. (Compare Thrombus of the Vulva, p. 268.)[1]

A. *Intraperitoneal Hemorrhage.*

If a large amount of blood is poured rapidly into the healthy peritoneal cavity, it meets with no resistance, the intestines are pushed aside, and the abdominal wall becomes distended.

Etiology.—Most cases of abdominal hemorrhage are traumatic and

[1] Rosenwasser of Cleveland, Ohio, unites the two last condition, under the name of *circumscribed* or *limited, hemorrhage*, opposed to the first, which he calls *free hemorrhage* (*Trans. Amer. Obstetricians and Gynecologists*, 1893).

due to rupture of the liver, or they may be caused by the rupture of an aneurysm of the abdominal aorta or the celiac axis. In gynecological practice they are nearly always brought about by the rupture of a fetal sac situated in the Fallopian tube, and sometimes by rupture of a dilated vein, such as those forming a varicocele or accompanying a uterine fibroid, or by hemorrhage from a badly secured pedicle, or by adhesions torn during laparotomy.

Symptoms.—The condition is characterized by sudden pain in the abdomen; a sensation of a warm internal current; faintness; nausea; vomiting; a frequent, small, or imperceptible pulse; a subnormal temperature; difficult respiration; pallor; a cold, clammy skin; and often discharge of blood from the vagina. Consciousness is preserved and the patient feels that she is dying.

Diagnosis.—We have only these rational symptoms of internal hemorrhage to go by. No tumor can be felt, and we cannot wait for a dull percussion-sound or the feel of fluctuation.

Prognosis.—The condition is absolutely fatal unless the hemorrhage is arrested by surgical means.

Treatment.—The indication is the same as for any other serious hemorrhage accessible to the surgeon's knife: laparotomy offers the only chance of rescue for the patient. Clots, fluid blood, and foreign substances, such as a fetus, must be removed from the peritoneal cavity, bleeding vessels tied, or diseased appendages removed on the affected side. It is even recommended, in cases of a ruptured fetal sac, not only to stitch up the tear in the tube, but to combine with it the ligation of both the ovarian and uterine artery in their continuity.

B. *Hematocele.*

Hematocele is an encysted effusion of blood in the peritoneal cavity of the pelvis.

Pathological Anatomy.—As a rule, the blood is found in Douglas's pouch, but if the amount is large, it rises more or less above the brim of the pelvis, and may reach as far up as the umbilicus. At first it lies behind the uterus, and is, therefore, called a *retro-uterine* hematocele. If later it surrounds that viscus, it is designated as *circumuterine.* If Douglas's pouch is closed by adhesions, the blood accumulates in front of and above the uterus, which condition is named *ante-uterine* hematocele, and is, of course, much rarer than the other varieties.

The blood is at first pure and thin, but becomes coagulated, inspissated, tarry, and, still later, sometimes mixed with pus or sanies. Through adhesive peritonitis the intestines are glued together, and plastic lymph is poured out and converted into tissue, forming a roof over the extravasated blood, which in places is finger-thick and shuts it off from the peritoneal cavity.

The blood may be derived from the ovaries, the tubes, the uterus, the broad ligaments, the peritoneum, or a fetal sac.

If it is a case of tubal pregnancy, the fetus is found only in a small minority of cases, which shows that it becomes absorbed; but on microscopical examination we always find villi chorii, which are entirely characteristic of an impregnated ovum.

Sometimes peritonitic adhesions exist before the hemorrhage takes place, or repeated hemorrhage may occur under the already formed roof.

Etiology.—Hematocele is a rather rare disease. It is found at the age of sexual maturity, most frequently in persons between twenty-five and thirty-six years of age. We may distinguish two chief forms, of which one is brought about by rupture of some organ, while the other is due to menstrual fluid entering the peritoneal cavity through the abdominal ostium of the tube. By far the most common cause is a tubal pregnancy rupturing into the peritoneal cavity. Hematosalpinx is more apt to cause fatal hemorrhage in rupturing than the formation of a tumor. Hemorrhagic salpingitis may furnish the blood. There may be closure of the uterine end of the tube or atresia of the uterus or vagina. In rare cases the hematocele is caused by bleeding from an apoplectic Graafian follicle or a hematoma in the stroma of the ovary (p. 530). A hematoma of the broad ligament may secondarily burst, and pour its contents into the peritoneal cavity. A ruptured vein is more likely to cause a speedily fatal hemorrhage. Torn peritonitic adhesions may cause hematocele—*e. g.* when an adherent retroflexed uterus is forcibly replaced (p. 436), or the adhesions may give rise to a bleeding in their interior by the same process as that which in pachymeningitis leads to the formation of a hematoma of the dura mater. This condition is called *hemorrhagic pachyperitonitis.*

The formation of a hematocele is often closely allied to menstruation. It is not only when the genital canal is closed that regurgitation takes place, but lifting of heavy weights, violent exercise, coition, and exposure to cold during the menstrual period may have the same effect.

Systemic diseases, such as scarlet fever, small-pox, purpura, and icterus gravis, may cause such changes in the composition of the blood, and weaken the walls of the pelvic blood-vessels so much, that they give way and allow the blood to escape into the peritoneal cavity.

Symptoms.—Sometimes there are premonitory symptoms. If the hematocele is due to ovarian or tubal disease, there will, as a rule, be a history of dysmenorrhea and pain in the pelvis. If the genital canal is closed, the patient has never menstruated, or at least not for a long time, and may have had monthly molimina. In extra-uterine pregnancy there may be signs of pregnancy, expulsion of decidua, and

previous attacks of pain. Metrorrhagia or menorrhagia may have been present as a sign of some abnormal condition of the internal genitals; or the patient may recently have gone through one of the above-named systemic diseases. In other cases the onset may be sudden and without warning. How severe it will be depends on the amount of blood that has extravasated, and the rapidity with which it escapes. There is always a sudden pain in the pelvis, to which may be added faintness, nausea, vomiting, a more or less rapid and weak pulse, and swelling of the abdomen, due to tympanitis. Instinctively the patient avoids all movements, and lies, as a rule, on her back. If she is menstruating, the flow may stop, or, on the other hand, outside of the menstrual period there may come a bloody discharge from the vagina.

This stage of hemorrhage is the next day followed by one of inflammatory reaction, with a chill, a pulse beating 100 to 140 in the minute, and a temperature of 102°–104° F. But this stage is likewise of short duration. As soon as the fluid is well encysted pulse and temperature return to the normal standard, and the pain abates.

The third stage is that of absorption, in which the coagulated and inspissated blood is gradually liquefied and taken up into the circulation. Only in exceptional cases suppuration or septicemia supervenes. If rupture occurs, the contents are most frequently evacuated through the rectum, more rarely through the vagina, and still more so through the bladder. They may also enter the free peritoneal cavity. During the time of resorption there is often a discharge of thick, dark blood from the vagina, which probably is some of the extravasated blood that finds its way out through the tube and uterus, while others think it is of uterine origin and due to hyperemia.

If the amount of blood in the peritoneal cavity is large, it may give rise to pressure-symptoms, such as constipation, retention of urine, tenesmus, uremia, neuralgia, edema of the legs, and rarely phlebitis. Sometimes jaundice is developed, and the urine contains urobilin, causing green fluorescence when chloride of zinc in ammoniacal solution is added.

By vaginal examination at first a soft mass, and later a tumor, is felt filling Douglas's pouch and extending more or less upward toward the umbilicus. The examination is best made with one finger in the rectum, one in the vagina, and the other hand on the abdomen. Parts of the tumor may be hard and others fluctuating. It bulges with a round end into the vagina, which, as well as the vaginal portion, may be seen to be in an anemic condition. The uterus is pushed forward and upward against the symphysis. By means of the sound it can be ascertained that the fundus lies upward and forward. If Douglas's pouch was closed before the attack, the tumor is situated in front of the uterus, and tilts it backward against the sacrum. If

it was partially closed by adhesions, the lower end of the tumor is irregular.

In the cachectic form of hematocele the bleeding may take place slowly, and in certain cases, depending on menstruation, there may be a monthly exacerbation, with increase in the size of the tumor.

Diagnosis.—The diagnosis is, as a rule, not difficult. The general condition is not so alarming as in unlimited *intraperitoneal hemorrhage*. *Hematoma* does not form so large a tumor, is not accompanied by vaginal discharge or peritonitis, is lateral and pushes the uterus over to the opposite side, and is absorbed sooner. *Pelviperitonitis* is ushered in with fever, while in hematocele it comes a day later. The well-defined tumor is formed later in peritonitis. It is often situated more laterally. The exudation remains fluid longer. But in the last stage it may be impossible to distinguish them. A *retroflexed gravid uterus* is accompanied by signs of pregnancy, a peculiar elasticity of the body of the uterus, softness of the lower uterine segment and the cervix, and a distinct angle between the two. *Extra-uterine* pregnancy is accompanied by signs of pregnancy, and is rarely developed in Douglas's pouch. As we have seen above, the two are frequently combined.

Prognosis.—The prognosis is much better than in cases of free hemorrhage. Most patients recover if not interfered with, but the process is a slow one. Absorption takes from three weeks to six months. Some succumb, however. The rupture into the peritoneal cavity ends speedily in death from shock or septic peritonitis. After rupture through the rectum suppuration may continue and slowly exhaust the patient's vitality.

Treatment.—During the first stage the indications are to arrest hemorrhage, combat shock, and relieve pain. The patient should be moved as little as possible; her head should be low; bottles with hot water should be applied to the extremities; morphine should be given hypodermically, and brandy by the mouth. An ice-bag should be placed over the symphysis, and ice-water injected into the vagina and rectum, unless the vitality is low, when very hot water is to be preferred.

In the inflammatory stage ice-bags, hot-water injections, and opium are indicated.

In the third stage absorption should be promoted by the use of Priessnitz's compress (p. 183), ichthyol, iodine (internally and externally), mercury ointment or plaster, and the galvanic current, with a large negative pole in the vagina and Engelmann's electrode (p. 222) on the abdomen. The vagina should be kept clean by means of antiseptic injections, in order to avoid possible infection.

In fresh cases all operative interference is absolutely counterindicated. If there is any likelihood of a fluid collection in the pelvis

being a hematocele, the doctor should abstain even from a puncture with a hypodermic syringe. Even if his instrument is aseptic and he disinfects the vagina, germs of suppuration and putrefaction may enter into this mass, which is so particularly favorable for their propagation, and cost the patient her life.

If, on the other hand, softening of the tumor, with high temperature, frequent pulse, dry skin, chills, and pain in loins and legs denote that suppuration has taken place, an opening should be made in the vagina large enough to introduce one or two fingers; the sac should be emptied and washed out with antiseptic fluid, and a finger-thick T-shaped soft-rubber tube introduced. If there is any bleeding, the cavity is packed with iodoform gauze for forty-eight hours before using the tube. The end of the tube is surrounded with iodoform gauze and rubber tissue, and the vagina packed loosely with gauze. Once or twice a day mild antiseptic injections are made through the tube (thymol is particularly appropriate on account of its blandness).

The *incision in the vagina* may be made in the median line, where there is the least chance of wounding vessels and the accumulated blood keeps the rectum away; but of late most operators prefer a transverse incision just behind the cervix.

If the blood-cyst has ruptured into the rectum, and suppuration continues, exhausting the patient, it is best to make a *counter-opening in the vagina* and insert a drainage-tube. The sac may be so thick and stiff that a soft tube is compressed. Then it is necessary to have one of hard rubber closed with a stopcock.

Another indication for operation is a very slow absorption. If the collection is large, and at the end of a month no perceptible diminution has taken place, the patient may be spared the annoyance of spending many months in bed by evacuating the contents of the sac. Operation is also indicated in repeated relapses. As in such a case we may expect some bleeding, the sac should be tightly packed with iodoform gauze, which may be left in for a week.

Vaginal incision is much safer than abdominal, on account of the danger of septic peritonitis in the latter. But if the extravasation cannot be reached from the vagina, *laparotomy* is indicated. The incision may be *subperitoneal* or *transperitoneal*. For the former an incision is made above and parallel to Poupart's ligament, the peritoneum lifted up, and an incision made into the sac without opening the peritoneal cavity. If this is accidentally opened, the opening should be enlarged and tamponed with iodoform gauze for twenty-four hours, until adhesions have formed. Then the gauze is removed and the tumor opened. The cavity once emptied, a counter-opening is made in the vaginal vault and through-drainage established.

Transperitoneal laparotomy is performed in the median line. If

possible, the sac should be stitched to the abdominal wall, and drainage established in that way; but often it is impossible because there is no separate wall. Then we can only wash the cavity out with an antiseptic solution, and drain with iodoform gauze through the wound in the abdominal wall.

C. *Hematoma.*

Pelvic hematoma, or hematoma of the broad ligament, is an effusion of blood in the pelvic connective tissue above the levator ani muscle, most frequently between the layers of the broad ligament, whence it may extend under the pelvic peritoneum, up under the abdominal peritoneum, and down on the side of the vagina.[1]

Pathological Anatomy.—The blood is situated in the loose connective tissue between the two layers of the broad ligament and between the peritoneum and the underlying fascia. In most cases it is not a very large collection, but the sac may contain several pints of blood, and form a tumor that nearly mounts to the umbilicus. As a rule, it is unilateral, but both sides may be affected, and then the two lateral tumors are united by an isthmus in front of and behind the uterus, and the rectum is narrowed by a ring-shaped stricture. The flow is arrested by the resistance offered by the surrounding sac, and the blood does not coagulate so rapidly as in hematocele. There may develop some peritonitis, but less than in hematocele. The sac may rupture, with the formation of a secondary hematocele, or it may suppurate, so as to become a pelvic abscess. (See Cellulitis.)

Etiology.—Since the connective tissue of the pelvis becomes laxer by pregnancy, multiparous and pregnant women, as well as puerperæ, are more apt to be affected. A varicocele or the fetal sac in tubal pregnancy may rupture in such a place that the blood escapes between the layers of the broad ligament, and not into the peritoneal cavity. Excessive coition may be the exciting cause. The accident happens most frequently during menorrhagia or the pseudo-menstruation following oöphorectomy and ovariotomy. The patient may be in perfect health.

Symptoms.—Suddenly the patient feels pain in the pelvis, with faintness and rapid, small pulse, but the attack is less alarming than in hematocele.

The vagina, and even the skin, may have a bluish color. A doughy tumor is felt on one side of the uterus, which it pushes over to the opposite side and upward. If the affection is bilateral, the uterus is lifted up. The tumor is in close connection with the uterus,

[1] According to W. A. Freund (*Gynäkologische Klinik*, Strasburg. 1885, vol. i. p. 219) the pelvic hematoma may in non-puerperal cases form between the rectum and the vagina, and in puerperal cases extend from the sides of the vagina to the anterior abdominal wall, the kidneys, and into the mesentery, *without entering the broad ligament.*

which is rendered immobile. As a rule, the tumor does not rise beyond the pelvic brim, but it may, as stated above, ascend to the neighborhood of the umbilicus and be distinctly fluctuating.

Diagnosis.—The effusion is less rapid, causes less pain and shock, and forms a distinct tumor sooner than in *hematocele.* The upper surface is convex, the lower more or less irregularly concave, so that the whole reminds one of a jellyfish, while hematocele bulges into the vagina with a convex end like a dilated bag. The ring-shaped stricture of the rectum is characteristic. The tumor is found just within the vulva, while in most cases of hematocele its base is situated higher up. It is found on one or both sides of the vagina—in hematocele, behind. It remains longer fluid. The uterus is sooner rendered immobile. Fever sets in later. In *cellulitis* the fever precedes the formation of the tumor, the uterus is not immobilized so soon, and the inflammation is referable to childbirth, abortion, or operative interference.

Prognosis.—Nearly all patients recover in from ten to fourteen days. Only when occurring in pregnancy, childbirth, or the puerperium is it dangerous. As a rule, the blood, and even the fetus in extra-uterine pregnancy, is absorbed. Suppuration is rare. But the sac may rupture into the peritoneal cavity, and in extra-uterine pregnancy the fetus may continue to grow.

Treatment.—As a rule, no operation should be performed, but the same measures be adopted as for hematocele. If the bleeding is severe or the tumor very large, and does not become absorbed or is changed into an abscess, one of the operations described under Hematocele should be performed.

In laparotomy the sac, if possible, should be stitched to the abdominal incision, but it may be so brittle that it cannot be lifted so far even when pressure is made against the vaginal roof. In such cases the uterus may sometimes be used to fill the gap. A suture is carried through the abdominal wall, the edge of the sac, the peritoneal cover of the uterus, the other edge of the sac, and the other side of the abdominal wall. If it appears desirable, a second suture may be inserted in a similar way. When these sutures are drawn taut, the sac is closed by the uterus, and the latter brought in contact with the abdominal wall.[1]

Galvanopuncture through the vagina, with a fine platinum-pointed needle connected with the positive pole, and with a current of 50 milliampères, used from five to ten minutes, has been recommended. In a small hematoma one application suffices; in larger it may be repeated in from three to six days.[2]

[1] Marcus Rosenwasser of Cleveland, O., *Annals of Gynecology,* March, 1891, vol. iv. p. 325.

[2] A. H. Goelet, *N. Y. Med. Record,* March 8, 1890, vol. xxxvii. p. 279.

CHAPTER VII.

Perimetric Inflammation.

By "perimetric inflammation" is understood the inflammation of the pelvic peritoneum, the pelvic connective tissue, the veins, and the lymphatic vessels and glands in the pelvis. On account of the intimate connection between these different structures and with the neighboring organs, it is quite common that more than one of them is affected at a time, and it is evident that there must be a certain similarity between all pelvic inflammations; but according to the tissue from which the inflammation starts or the one that is most affected we distinguish perimetric inflammations by different names, and these different diseases present also sometimes peculiarities as to frequency, physical signs, prognosis, and indications for treatment. Our old knowledge, based only on clinical observations and post-mortem examinations, has been greatly extended and corrected by the numerous laparotomies that have been performed of late years in these conditions. Thus we describe separately *pelvic peritonitis, pelvic cellulitis, pelvic lymphangitis,* and *pelvic phlebitis.*

A. *Pelvic Peritonitis.*

Pelvic peritonitis is the inflammation of that part of the peritoneum which covers more or less of the uterus, the tubes, the bladder, the rectum, the vagina, and the walls of the pelvis, and which forms the broad ligaments.

Pelvic peritonitis is sometimes called *perimetritis* as a companion name to *parametritis,* which is used to designate inflammation of the connective tissue; but since these names are not very characteristic in regard to their derivation,—*peri* meaning "around," and *para,* "at the side of,"—since their sound, especially in English, is so much alike that there is little for the memory to take hold of, and since most excellent treatises have been written about them under their old names, we take it to be more practical to preserve the words "peritonitis" and "cellulitis," although the latter leaves much to be desired from an etymological standpoint, being a combination of a Latin root and a Greek suffix, and the root itself being a remnant from the time when what we now call connective tissue was designated as cellular tissue.

Of all the perimetric inflammations, peritonitis is by far the most common.

Pathological Anatomy.—Different forms of pelvic peritonitis have been distinguished—namely, the *serous,* the *adhesive,* and the *suppurative*—which are sometimes only different stages of the same disease. The inflammation may be *acute* or *chronic.*

In nearly all these cases are found diseased tubes, and usually the ovary is implicated. Often the inflammation of the tubes can be traced back to the corresponding condition in the uterus. First the peritoneum becomes injected, its endothelium is lost, and serum is secreted from the denuded surface. The neighboring organs are agglutinated by a yellow fibrinous mass that becomes organized, and forms a false membrane which encapsulates the serous exudation. Serum may also be enclosed in the meshes of the adjacent connective tissue, forming an inflammatory edema. The serum may gravitate down into Douglas's pouch or be found in one of the para-uterine fossæ, or the quantity may be large enough to fill the whole pelvis, and even surmount the iliopectineal line. As a rule, the fluid is found behind the uterus and pushes it forward, sometimes also to one side, but in exceptional cases the uterus being already bound down with adhesions, the fluid is found above and in front of it.

Later this serum in the peritoneal cavity becomes inspissated, forming a yellow mass like orange-jelly,[1] the more watery part being reabsorbed and connective tissue being formed. Finally, the whole may be absorbed, or, as it is called, the disease ends in resolution.

Even solid adhesions can probably disappear without leaving any trace; at least a uterus that at one time is immovably moored to the surroundings may regain entire mobility. This absorption is doubtless favored by the constant movement in which the pelvic organs are kept by respiration, the different degrees of fullness of the bladder and intestine, their evacuation, sneezing, coughing, muscular exertion, and sometimes an intervening pregnancy in which the adhesions are softened and stretched. But, as a rule, adhesions remain indefinitely. The serous cyst may remain unchanged for many months. Sometimes the contents become bloody in consequence of rupture of vessels in the adhesions, and in rare cases they become purulent. In the adhesive form we find on one or both sides of the uterus a tumor composed of the tube, the ovary, and, perhaps, a knuckle of intestine or a part of the omentum, all matted together with plastic lymph or organized adhesions. As a rule, this mass is bound in the same way to the posterior surface of the broad ligament, or, more rarely, to the posterior surface of the uterus, the anterior surface of the rectum, the superior surface of the bladder, or the pelvic wall. Serum may extravasate into such a mass. The ovary is covered with a false membrane. The tube is contorted, and its sinuosities bound together; the abdominal ostium is often closed; the fimbriæ may have grown together; bands of adhesions form constrictions which cause adhesive salpingitis and strictures or total partitions in the interior of the tube. The uterus may be retroflexed or retroverted, and bound to the rectum, or, more rarely, anteflexed or anteverted, and bound to the bladder. The condition

[1] John Williams, *Obst. Trans. of London*, June 3, 1885, vol. xxvii.

we here describe, as it presents itself in laparotomies, is in most cases probably a late stage of the preceding form, but in some cases there is little serous effusion from the beginning, and the exuded fibrinous lymph is soon transformed into connective tissue by a process similar to that causing dry pleurisy. This dry chronic form is particularly frequent in connection with tuberculosis, while the common acute form is ordinarily accompanied by more or less serous exudation.

Pelvic peritonitis may be suppurative from the beginning, as when gonorrhea extends through the uterus and tubes, or a serous exudate may in the course of time, instead of being absorbed, become purulent. Fortunately, this is a comparatively rare occurrence.

Pus in the pelvis may be found in the tube (pyosalpinx), in the ovary (ovarian abscess), in the peritoneal cavity, or in the subperitoneal connective tissue. Often it is found in all these localities at the same time. We have described the first two in dealing with the Diseases of the Tube and the Ovary. Here we will only add that the pus-filled tube may become so distended that it occupies the whole pelvis, where it may adhere, so that it cannot be separated from the peritoneum. The pelvic abscess of the connective tissue will be described below. Here we have only to do with the intraperitoneal collection of pus. On account of the preëxisting wall formed by adhesions and the new irritation caused by the acrid contents, this abscess, although situate in the peritoneal cavity, is in reality, as a rule, separated from it by a complete partition of varying thickness. This intraperitoneal abscess may open into a hollow organ, most frequently the rectum, less often the vagina, and rarely the bladder. It may rupture into the peritoneal cavity, which, fortunately, is a rare occurrence, and it may find its way out through the peritoneum, the connective tissue, and the skin above or below Poupart's ligament, or burst in the gluteal region, which it reaches through the great sacro-sciatic foramen.[1]

Often the abscess is only partially emptied through a long, narrow, and devious canal surrounded by indurated tissue, or refills again when the outlet becomes blocked up. Such fistulous abscesses may remain indefinitely as a source of fresh attacks of peritonitis or as a drain on the patient's constitution, which makes her an invalid or causes death by exhaustion.

In contact with the purulent collection the muscular fibers of the uterus are apt to undergo fatty degeneration. The inflammation may follow the lymphatics through the infundibulopelvic ligament up to

[1] W. M. Polk thinks this is brought about by agglutination of the fimbriated end of the tube to some point of the peritoneum, which yields and allows the migration of the pus ("Peri-uterine Inflammation," *N. Y. Med. Record*, Sept. 18, 1886, vol. xxx. p. 315).

the diaphragm, and cause diaphragmatic pleuritis; but this is of the dry variety and of minor importance.

Microscopical investigations[1] have shown that in peritonitis the endothelia of the peritoneum and blood-vessels, the epithelium of the ovary, the fibrous connective-tissue bundles, and the smooth muscle-fibers all break up, forming inflammatory corpuscles—*i. e.* small round cells—which, if they continue in connection with one another, become spindle-shaped and form new connective tissue (adhesive peritonitis), or, if the connection between them is interrupted, form pus-corpuscles (suppurative peritonitis). The latter is due to the influence of gonococci, staphylococci, or streptococci. The most common cause is gonococci. The other microbes may be introduced by unclean fingers and instruments, or may be due to rupture of vessels in injuries, since they circulate in the blood, or be derived from a suppurating surface in a remote part of the body.

False membranes consist of connective tissue with interspersed cells and blood-vessels, and contain sometimes miliary abscesses.

According to the bacteriologists,[2] gonococci do not affect the lymphatics, but travel along the mucous membrane of the uterus and the tubes, while staphylococci are carried more rapidly by the lymphatics than in following the mucous membrane, and do not invade the veins until the lymph-vessels are choked. Streptococci are only found extensively in puerperal cases, and are transmitted in the same manner as the staphylococci.

Etiology.—Pelvic peritonitis may develop in the fetus. In adults it is in most cases added to preëxisting disease of some pelvic organ, especially salpingitis. A serous peritonitis may accompany purulent salpingitis, for which an explanation may be sought by supposing the adhesions to serve as a filter, retaining the pyogenic microbes. Metritis may spread from the endometrium through the muscular wall out to the peritoneum, or it may first reach the connective tissue, the lymphatics, or veins of the broad ligament, and secondarily the peritoneum. Enlargement, displacement, fibroids, and cancer of the uterus are all very apt to be accompanied by peritonitis. Hematocele is limited by adhesive inflammation. Peritonitis may be due to rupture of a tubal pregnancy or an ovarian hematoma or abscess.

Tubercular peritonitis is usually propagated from the same affection in the tube. It is commonly preceded by simple peritonitis.

Peritonitis is chiefly the result of gonorrhea, trauma, childbirth, or disturbance of the menstrual flow, in all or most of which cases the real morbific cause is infection with microbes.

Traumatic peritonitis is often brought about by gynecological treatment, such as the passing of the uterine sound, application of caustics,

[1] Dr. M. Dixon Jones, *Medical Record*, May 28, 1892, vol. xli. p. 599.
[2] W. R. Pryor, *Amer. Jour. Obst.*, May, 1891, vol. xxv. p. 603.

curetting, intra-uterine injections, tents, stem-pessaries,[1] incision of the cervix, or trachelorrhaphy.

Puerperal peritonitis may be gonorrheal or traumatic, in the latter case beginning as a hematoma or being due to microbes deposited on wounds by unclean fingers or instruments and similar carriers of infection.

Menstrual peritonitis may be due to a malformation of the tubes or to flexion or stenosis of the uterine canal, but is in most cases brought on by exposure to cold or by coition. It is not rare in washerwomen who get wet feet, or prostitutes who bathe the genitals with cold water in order to stop the inconvenient flow.

Perhaps also masturbation may cause peritonitis.

Symptoms.—The symptoms of an acute attack of pelvic peritonitis are much like those of acute inflammation of the pelvic organs. The patient experiences a sudden severe pain in one side of the pelvis, which may extend over to the opposite side or down the anterior surface of the thigh. She feels faint and sometimes nauseated, and may vomit. As a rule, she has a chill, followed by rise in temperature, and a frequent small pulse. Very commonly she complains of rectal and vesical tenesmus. Her face has an expression of anxiety, and she may become delirious. The abdomen is distended and tender. Metrorrhagia is of frequent occurrence. On vaginal examination is found an exquisitely tender swelling occupying Douglas's pouch or situated to one side of the uterus, and pushing the latter up against the symphysis, and sometimes over to the opposite side, but at the same time canting the edge forward. It is immovable. Sometimes crepitation is heard and felt, but the swelling is too tense to give fluctuation.

As a rule, the fluid is absorbed, the tumor becomes smaller and disappears, and the uterus may regain its normal mobility. In other cases induration and adhesions remain, and the uterus continues more or less immobile. In other cases, again, recurring fever, chills, night-sweats, and a yellowish hue of the skin indicate the formation of pus; but all these symptoms may be absent and, nevertheless, the exudate become purulent. Sometimes the transformation is marked by an extension of the inflammation up into the abdomen, by the occurrence of persistent diarrhea due to ulcerative enteritis, or by bronchopneumonia with mucopurulent expectoration.

While the above description applies to most cases of acute pelvic peritonitis, there are others that present some peculiarities. Thus the temperature may be normal, or even subnormal, or fluctuate between a high and a low mark; which are bad signs. Pain and tumor may be absent in particularly dangerous cases. The tumor may fill

[1] I have described a case of this last kind in *Amer. Jour. Obst.*, 1870, vol. xii. p. 756.

the whole pelvis, extend considerably above the brim, or be as small as a pigeon's egg. It may change in position and size on account of the presence or disappearance of the accompanying edema or congestion.

The *chronic* form may be really chronic from the beginning, but oftener it is a succession of acute attacks brought on by bodily exertion, trickling of tube-contents into the peritoneal cavity, rupture of a follicular cyst or a distended tube. In this form the patient is often able to be up and about, and even to do some work, but she has more or less constant pain, with menstrual exacerbations. Menorrhagia or amenorrhea is common. By bimanual examination we feel on the side of the uterus the tumor described above in speaking of the pathological anatomy, or a large tumor that mounts into the abdomen simulating an ovarian cyst. Sometimes a fibrinous discharge from the uterus accompanies a serous collection in the pelvis.

Prostitutes suffer often from a condition called *colica scortorum.* Its symptoms are pelvic pain, fever, and purulent discharge, and it is due to slight attacks of peritonitis, and probably to painful contractions of the inflamed tubes.

Diagnosis.—It may be impossible to differentiate pelvic peritonitis from other conditions, but in most cases the diagnosis is easy. In fresh cases the bulging tumor filling Douglas's pouch and pressing the uterus up against the symphysis is characteristic. *Hematocele* occupies, however, the same position, but it begins more suddenly and with greater violence, and the tumor is at first fluid, and becomes harder (p. 623), whereas peritonitis takes an opposite course. Hemorrhage may take place into a serous pseudocyst, but the red blood-corpuscles are then changed into pale spherical bodies, while in hematocele the fluid is pure blood with well-preserved or shrunken blood-corpuscles. In *cellulitis* the symptoms are less severe, the tumor is situated close up to the side of the uterus, and pushes it, together with the cervix, over to the other side. It may form two tumors, one on either side, connected by a bridge in front and behind the cervix. In peritonitis the whole vaginal vault presents one smooth, hard mass. The immobility of the uterus is less pronounced than in peritonitis. If cellulitis extends above the brim, it always follows the bone closely, while the peritonitic tumor, as a rule, is situated farther in, and allows us to insert the fingers between it and the bony pelvis. If cellulitis involves the psoas and iliacus muscles, relief is found by flexing the corresponding limb; in peritonitis both must be drawn up to obtain the same effect. In chronic *oöphoritis* the ovary may be movable, its shape is more or less recognizable, and it shows an unusual tenderness. In *salpingitis* the tumor is sausage-shaped, often bilateral, and follows the edge of the uterus. In cases of long standing the tube, may, however, be so distended as to fill the pelvis,

and adapt itself to the peritoneum, and then the diagnosis between this condition and a collection situated directly in the peritoneal cavity becomes impossible. In *extra-uterine pregnancy* there are signs of pregnancy, and the tumor is situated laterally. In cases of *fibroid* or *fibrocystic* tumors of the uterus this is, as a rule, movable, and the tumor moves with it. Fibroids are felt as solid nodular masses, and there is no history of acute inflammation. The uterine cavity is, as a rule, enlarged. In *ovaralgia* there is neither tumor nor inflammation. An old encysted serous collection is easily mistaken for an immovable *ovarian cyst*, but there is the history of the acute beginning, and exploratory puncture shows a citrine fluid containing leucocytes and forming a small coagulum by exposure to the air. In the same way a peritonitic cyst is distinguished from a *cyst of the broad ligament* or a *hydatid*. In tubercular peritonitis the lungs are, as a rule, affected.

Prognosis.—When the disease is of traumatic or menstrual origin the prognosis is good, both as to life and complete recovery, but absorption may be very slow. The gonorrheal form is much more dangerous, and may in short time lead to death by general peritonitis or give rise to chronic peritonitis, which may end fatally through exhaustion, embolus, or tuberculization. The puerperal form is very grave.

Often the patient is left with impaired health. Uterine displacements are a common sequel. Hematocele may develop in the adhesions (p. 624). Intestinal adhesions may cause constipation, alternating with diarrhea, or occlusion of the bowel. Pressure on the nerves of the pelvis may cause sciatica or reflex paralysis. Sterility is very common, the ovary being covered with a false membrane that prevents the ovum from escaping, or the tubes being sealed by adhesions. If impregnation takes place, there is danger of the ovum being arrested in the tube, or if it reaches the uterus, the presence of a layer of old, unyielding false membrane around this organ or its fixation by adhesions in an untoward position may lead to abortion.

Treatment.—In regard to prophylaxis the reader is referred to what has been said in speaking of Salpingitis (p. 509). The patient must lie quietly in bed, and be kept on fluid diet (p. 216). Often a pillow rolled up, tied, and placed under her knees is grateful to her. In the acute stage an ice-bag or ice-water coil should be applied over the uterus, or, if cold is not well borne, a hot poultice or stupe (p. 183) may be substituted. Frequent hot vaginal injections should be ordered, to which in infectious cases antiseptics should be added (p. 168). Heat may be used continually by combining the poultice on the abdomen with one in the vagina, or placing a colpeurynter with hot water in the latter. Pain should be subdued by opiates. If it is severe, it is charitable to begin with a hypodermic injection of $\frac{1}{4}$ to

¼ of a grain of morphine. Later, the drug is given by the mouth in doses of ⅛ of a grain, repeated often enough to keep the patient comfortable, for which purpose in most cases not much is required,[1] or suppositories with 1 grain of opium are administered by the rectum every two or three hours.

I prescribe in this as in all inflammations 5 grains of quinine every four hours, not as an antipyretic, but as an antiphlogistic. If the temperature rises above 102° Fahr., antipyretics (p. 220) are indicated. Bacteriological researches having shown that bacilli find their way from the intestine, and change a comparatively harmless simple peritonitis into a dangerous septic one, it is a wise precaution to keep the bowels open from the beginning with enemas (p. 169) or aperients, preferably sulphate of sodium (a heaping teaspoonful, repeated, if necessary, every three hours), or, if salts cause vomiting, calomel (gr. j every three hours, repeated three or four times).

When the disease after eight or ten days enters on a more subacute stage,—that is to say, when spontaneous pain and fever have ceased and the tenderness is diminished,—the patient is allowed more substantial food, and Priessnitz's compress (p. 183) should replace the ice. A few days or a week later the abdomen should be painted with tincture of iodine, followed by a glycerin compress (p. 185). When the tenderness has abated sufficiently to warrant the introduction of a speculum, the iodine is applied with greater effect to the vaginal roof every three days (p. 165), and combined with pledgets with ichthyol-glycerin (p. 173), abdominal inunction with ichthyol ointment (10 per cent.), and the internal use of iodide of potassium. By this time —about three weeks since she was taken sick—the patient will, as a rule, be well enough to get up cautiously and spend most of the day on a lounge. Still later, when she is well enough to be on her feet, galvanism with the negative pole in the uterus or vagina (p. 222), faradization with the high tension secondary current for ten minutes every day (p. 221), massage (p. 187), warm entire baths, sitz-baths (p. 183), and the constant use of a wet abdominal bandage well covered with water-proof material, are valuable means of causing absorption of exudation and inflammatory tissue. Finally, the treatment in places where they have mineral dirt, so-called "moor," such as Franzensbad or Marienbad in Germany, and Sandefjord in Norway, may be recommended.

If serous pseudocysts remain after the acute symptoms have subsided, and do not yield readily to the absorbent treatment described, much time may be saved by aspirating the fluid (p. 157) from the

[1] In this respect, as in many others, pelvic peritonitis differs from general peritonitis, in which often enormous doses are not only well borne, but beneficent. (See Garrigues, "The Opium Plan in Puerperal Peritonitis," *N. Y. Med. Jour.*, Jan. 24, 1885, vol. xli. p. 98.)

vagina; but the utmost care should be taken in disinfecting both aspirator and vagina, as otherwise the inoffensive serum may be followed by pus; and bladder, ureters, and blood-vessels must be carefully avoided, which limits the safe field to the posterior part of the pelvis and a moderate distance from the median line.

In the chronic form of peritonitis, or when the acute and subacute stages have passed, the patient is allowed moderate exercise; her diet should be nutritious and mildly stimulating (p. 216); but sexual intercourse should be avoided or restricted to narrow limits.

To the therapeutic measures already mentioned may be added packing of the vagina (p. 173), which may help to stretch adhesions and further their absorption. The internal use of resolvents (p. 218) hastens absorption, and an abdominal belt (p. 186) often gives comfort by removing pressure from the inflamed peritoneum.

Pelvic Abscess.[1]—If the fluid in the sac formed by the peritoneum, pelvic organs, and false membranes is purulent, it should be evacuated; and the question arises, from what side is it best to attack the sac—from the rectum, the vagina, or the abdominal wall? To make an opening in the rectum, be it with trocar, aspirator, or knife, is not advisable, as the abscess inevitably becomes infected with the contents of the bowels. If there already is a communication with the rectum, opinions about the best way of treating the abscess differ. Some[2] anesthetize the patient, dilate the sphincter ani muscle to over-distention, tear the opening in the rectum down to the bottom of the abscess, scoop out with finger or curette all granulations and old bands, wash out the cavity, and treat it exclusively through the anus till it is healed, which often necessitates a repetition of the operation and the use of sponge tents to keep open the entrance to the abscess. Most operators prefer to introduce a sound through the opening in the rectum, bend it well down against the vaginal roof, and make a counter-incision there, through which a drainage-tube may be drawn, and left until the cavity is closed. It is, of course, kept clean with daily injections of antiseptic fluid. More rarely the counter-opening is made in the abdominal wall.

If the purulent collection is near the vaginal roof, and does not contain over two ounces of pus, some advise to aspirate. Others use a trocar and canula. But it is better to make a large opening, so as to be sure to have a free outlet and be able to insert a drainage-tube. Some make this opening by plunging a pointed curved pair of scissors,

[1] The term "pelvic abscess" is taken in different senses by different authors. Some use it for a collection of pus anywhere in the pelvis; others restrict it to collections the sac of which cannot be removed (Pozzi); and others, again, use it only to designate the suppuration of the connective tissue of the pelvis (Thomas-Mundé). I use it for intra- or extra-peritoneal purulent collections in the pelvis, except those situated in the tube or the ovary.

[2] H. T. Byford, *A Case of Pelvic Abscess*, Chicago, 1886.

through the posterior vault of the vagina into the abscess and withdrawing them open. Then they enlarge the opening with an expanding dilator, clean out the cavity with finger and curette, removing granular masses, tags, and partitions, wash out, and leave a stiff soft-rubber drainage-tube with cross-bar. Special forceps have been made with which the abscess may be opened and the drainage-tube carried in.[1] This method is simple and effective, and, as a rule, successful, but has the drawback that one is never sure of not wounding a blood-vessel or the intestine. It is much safer to cut layer after layer with a scalpel, arresting hemorrhage, if necessary, by carrying a suture round the bleeding vessels. (Compare Hematocele, p. 627.) As to the direction of the incision, if the collection is central, it may be made in the sagittal or coronal plane. If it is lateral, the incision should go outward and backward, never depassing the prolongation of a transverse line drawn from side to side through the cervical canal, in order to steer clear of the ureter and the uterine artery.

If the abscess points near Poupart's ligament, a large incision is made parallel to the ligament, cutting layer by layer, and when an opening has been made a finger is introduced to the bottom, counterpressure is made from the vagina, and, if there is not too much tissue, a counter-opening is made here and a soft rubber drainage-tube with side holes drawn through the cavity.

This incision may even be used if the abscess does not point, but is at some distance from the ligament: the peritoneum is then lifted until the abscess can be entered from behind without opening the peritoneal cavity.

When the pus extends upward and backward (in puerperal cellulitis), the most favorable point at which to cut deep is above the crest of the ilium, between the attachments of the latissimus dorsi and obliquus abdominis externus muscles (*Petit's triangle*). Here a vertical incision is made, which leads to the external border of the quadratus lumborum muscle.

With the increasing familiarity with laparotomy it becomes, however, more and more customary to perform that operation. It has the great advantage of allowing the operator to see, of giving him room to tie bleeding vessels, to remove the appendages if they are found to be the source of the suppuration, and to empty separate pus-foci wherever they may be, and of preventing subsequent infection. The pus should be aspirated and the abscess-cavity washed out with antiseptic fluid before opening it. Even then the place where the incision is to be made should be surrounded by sponges or gauze pads in order to catch the contents. If the abscess unfortunately bursts and pus enters the peritoneal cavity, this should be flooded with a warm

[1] Dr. Bache Emmet has described and delineated one in *N. Y. Med. Record*, March 19, 1892.

solution of salt (p. 481) or thymol or with Thiersch's solution (p. 200). If possible, the sac is stitched to the edges of the incision; if not, an opening is made in the vaginal vault, drainage is established in that way, and the abscess-cavity is closed over it; and if that too is impossible, the focus is simply opened and disinfected, and a drainage-tube or iodoform gauze drain is brought out through the abdominal incision.

Even when laparotomy is performed, it may be found to be advantageous to open the abscess above Poupart's ligament by lifting the peritoneum and getting in from behind, so that it does not connect with the peritoneal cavity.

It has been advised to open abscesses in two sittings (Hegar's method). An incision is made down to the sac without opening it; the wound is packed with iodoform gauze, which is left in for four or five days until strong adhesions have formed all around, and then the abscess is opened. This method is applicable both to abdominal and vaginal incision.

Other methods have been proposed in order to reach deep abscesses from the perineal or sacral region, such as vertical perineotomy, transverse perineotomy, and sacrotomy.

Vertical Perineotomy.—An incision is made from a point between the posterior and middle third of the labium majus, going midway between the anus and the tuberosity of the ischium, and ending somewhat beyond the tuberosity. In this way the levator ani muscle is exposed and incised in order to reach the abscess.

Transverse Perineotomy.—An incision is made from one tuberosity to the other, and carried up through the rectovaginal septum.

Sacrotomy.—This is Kraske's method for extirpation of the rectum or Hegar's modification of it applied to the opening of a deep abscess. (See Hysterectomy, p. 499.)

None of these methods allows the operator to explore the pelvis to any great extent, and still less to remove diseased tissues or organs with anything like the facilities afforded by laparotomy.

To use the blunt curette in the abscess, except in cases of old standing, is hazardous, since we have seen above that the thickness of the sac varies much in different parts, and a perforation might be made unawares into the peritoneal cavity.

If the abscess has opened into the bladder, a counter-opening has been made in this viscus, either by suprapubic cystotomy (Schroeder) or from the vagina (Buckmaster[1]), in order to establish good drainage. But it often closes without operation by simply washing out the bladder.

If the abscess opens into the ureter, it may perhaps be possible to repair the defect by laparotomy.

[1] A. H. Buckmaster, "Pelvic Abscess," *Brooklyn Medical Jour.*, April, 1891.

After an abscess has been emptied and well drained, the surrounding hard masses soon disappear.

Fistulous Tracts.—After spontaneous opening into the vagina the abscess heals in most cases, but if a fistula remains and constant suppuration exhausts the patient, it must be dilated with the knife, dilator, or tents; or perhaps a laparotomy may give the best access to the cavity. Spontaneous opening near Poupart's ligament or the iliac crest often leaves long sinuous fistulæ that have to be dilated with laminaria or laid open with the knife, and good drainage established, sometimes by means of a counter-opening in the vagina, before recovery can take place.

Sometimes it suffices to curette the fistulous tracts and old abscess-cavities that will not close, and inject them daily with peroxide of hydrogen, carbolized water (2 per cent.), Labarraque's solution diluted with 8 or 10 parts of water, Villate's solution[1] mixed with 2 parts of water, or to use two or three times a week injections with tincture of iodine, in the beginning mixed with water, or a solution of nitrate of silver (2 per cent.).

In some cases of adhesive peritonitis laparotomy is performed with the sole aim of breaking up adhesions (compare Salpingitis, p. 511); but if it is done for a pelvic abscess, the tubes and ovaries should, if possible, be removed as the source of the suppurative peritonitis.

B. *Pelvic Cellulitis.*

Pelvic cellulitis is the inflammation of the connective tissue in the pelvis above the pelvic diaphragm. We have seen in the anatomical part (p. 93) that there is a large amount of such tissue in this locality, and especially around and in the broad ligaments, and that it is in direct connection with the same kind of tissue outside of the abdominal peritoneum and under the skin. Some modern gynecologists would have us believe that inflammation is rare in this tissue, and that, when it does occur, it rarely runs into suppuration. It is an unfortunate, but common, quality of the human mind to be engrossed by one idea to the exclusion of others. When a new discovery is made we are apt to be dazzled by it to such a degree that we overlook other equally well-established facts. There was a time when every pelvic inflammation was looked upon as cellulitis; then there came a reaction and it was all peritonitis; and of late many exclusively lay stress on salpingitis.

As a matter of fact, connective tissue in the pelvis, just as anywhere else in the body, is prone to become inflamed; but, as a rule, we have

[1] ℞. Cupri sulphat., Plumbi sulphat., āā 15.0; Liq. plumbi subacetat., 30.0; Aceti, 200.0.—M.

solution of [illegible]. Since the patients usually
If possible [illegible] our argument with. Yet
opening, [illegible] in which the inflammation was
way, and [illegible] without implicating perito-
sible, the [illegible] still more convincing case of
iodoform [illegible] and in whose pelvic connective
Even [illegible] peritoneum was entirely free.[1]
tageous [illegible] influence could be invoked, nor
peritoneum [illegible] uterus, tubes, or ovaries.
with the [illegible]
It [illegible] themselves as if the disease did not
[illegible] with childbirth and abortion; but,
[illegible] they are very likely to be called
the [illegible] performed, and science is one inde-
or by [illegible] which the physician may find it con-
the [illegible] But, even independently of puerperal
and [illegible] if we do not see it in laparotomies as
[illegible] for the simple reason that few lapa-
from [illegible] the inflammation is limited to the pelvic
yet [illegible]

[illegible] in the Male," paper read before the N. Y. [illegible]

[illegible] work to enter into controversies or to give a com- [illegible] to study the question of pelvic inflammation [illegible] advantage to examine, among others, besides [illegible] papers: "On the Character and Types of Pelvic [illegible] Henry S. Stark, *Med. Record*, Aug. 15, 1891; [illegible], *Amer. Jour. Obst.*, Jan., 1892, vol. xxv. p. 18; [illegible] Ruptur eines Ovarialhämatoms," by H. J. Boldt, [illegible] "Unusual Cases of Abdominal Section," by Henry [illegible] Dec. 7, 1891; "Pus in the Pelvis, and How to Deal [illegible] *Surgical and Gynecological Trans.*, vol. ii.; "Ob- [illegible] Treatment of Peritonitis," by T. H. Burchard, [illegible]; "Recurrent Pelvic Peritonitis," by B. F. Baer, [illegible] 1888; "Chronic Adhesive Perimetritis," by James [illegible] pamphlet without date); "Remarks on Peri-uterine Cel- [illegible]," by H. T. Hanks, Albany, 1885; "Electrolysis in [illegible] Ford, *Med. Press of Western New York*, April, 1888; [illegible] General Peritonitis," by W. E. B. Davis, *Med. Asso-* [illegible] April 13, 1890; "Early Operations in Purulent Peri- [illegible] *Med. Assoc.*, May, 1890; "The Exaggerated Im- [illegible] Inflammations," by H. C. Coe, *N. Y. Med. Jour.*, May 15, [illegible] the Products of Inflammation in the Female Pel- [illegible] *of Gynecology and Pædiatrics*, July, 1891; "Cases [illegible] the same author, *ibid.*, June, 1893, p. 535; "Cases of [illegible]" by T. Johnson Alloway, *Canada Med. and Surgical* [illegible] matic Pelvic Cellulitis," by Thomas H. Allen, *Gail-* [illegible]; "Some Observations upon Pelvic Cellulitis," by Vir- [illegible] *and Surgical Jour.*, 1887; "Pelvic Abscess," by A. [illegible] *Jour.*, April, 1891; "Case of Pelvic Abscess," by H. [illegible], Dec. 18, 1885, Chicago, 1886; "Treatment of Pelvic [illegible] F. Mundé, *Amer. Jour. Obst.*, 1886, vol. xix. p. 113; [illegible]," by W. M. Polk, *Med. Record*, Sept. 18, 1886, vol.

Cellulitis not only exists, but it is a rather common occurrence, and used especially to be so before antiseptic midwifery and surgery were so much practised as they are now-a-days. Certain localities are more liable to be affected than others, because they contain a larger amount of connective tissue, and because they are more exposed to injury—viz. the broad ligaments, the surroundings of the lower uterine segment and the fornix of the vagina, the sacro-uterine ligaments, and the space between the cervix and the bladder.

Cellulitis may be *acute* or *chronic*.

Acute cellulitis may arise by propagation of the inflammation from a tear or ulcers in the cervix or from corporeal endometritis, the inflammation spreading through the intermuscular connective tissue. It may also begin directly in a tear extending into the parametrium, or it may begin anywhere in the depth of bruised tissue. In most cases it is combined with pelvic peritonitis, lymphangitis, or phlebitis.

That peritonitis and cellulitis go together, whether one or the other is the primary affection, is easy to understand, since the peritoneum and the connective tissue are not only in contact, but the peritoneum is only a modification of connective tissue.

When cellulitis is combined with lymphangitis, the latter is the primary lesion, the lymph-vessels becoming inflamed in the uterus or in the tear of the cervix, and carrying the infection through and into the connective tissue.

Phlebitis may be primary, extending from inflamed uterine sinuses, or secondary, beginning as periphlebitis by contact with inflamed connective tissue, and gradually gaining the deeper coats of the vein.

Cellulitis is seldom bilateral.

We may distinguish between a simple *traumatic* form and a *septic* form. Both are due to infection with bacteria, but in the first simple bacteria of putrefaction are at work; in the second we have to deal with specific pathogenic bacteria.

Either of these forms may, again, be *puerperal* or *non-puerperal*. The traumatic extends in the loose connective tissue, following the interstices between sheets of hard connective tissue; the septic respects no boundaries.

As in other inflammations, we may distinguish different stages, one of infiltration, followed by one of resolution, suppuration, or organization.

During the stage of infiltration the connective tissue is swollen by exudation of serum and formation of small round cells, which change

xxx., p. 309; Pelvic Peritonitis—Microscopical Studies," by Mary Dixon Jones, *Med. Record*, May 28, 1892; "Septic Endometritis and Peritonitis," by W. R. Pryor, *Amer. Jour. Obst.*, vol. xxv. p. 598, May, 1892; "Remarks upon Parametritis," by Geo. T. Harrison, *Amer. Jour. Obst.*, April, 1891, vol. xxiv. p. 460; "How shall we Treat our Cases of Pelvic Inflammation?" by Richard B. Maury, *Amer. Jour. Obst.*, vol. xxiv., Jan., 1891.

only clinical evidence of its exist... recover, we have only few autopsies to ... we have some performed on women ... strictly confined to the connective ti... neum, tube, or ovary; and there is ... a man who fell asleep on a wet brid... tissue a large abscess formed, while ... In this case certainly no puerper... could the cellulitis be attributed to ...

Some gynecologists express th... concern them when it is connecte... even if they do not practice obste... in when an operation has to be ... pendently of the limits within ... venient to confine his work. ... influences, cellulitis exists, an... often as we find peritonitis, ... rotomies are performed when ... connective tissue.[2]

[1] T. H. Burchard, "Pelvic Al... Academy of Medicine, April ...

[2] It is beyond the scope of th... plete bibliography, but those ... more in detail will find it ... those already quoted, the fol... Inflammations in the Fen... "Perimetric Cysts," by J... "Peritonitis hervorgeruf... *Deutsche med. Wochensch...* T. Byford, *Chicago Med. ...* with It," by Joseph Pri... servations on the Medi... *N. Y. Med. Jour.*, A... *Med. and Surg. Repo...* H. Etheridge, Chicag... lulitis and Peri-uteri... Peritoneal Adhesion... "The Treatment o... *...ation of the State...* tonitis," by Jose... portance of Min... 1886; "The D... vis," by Chas. ... of Neglected P... Post-partum P... *J...*, Montreal... *...'s Med. Jo...* gil O. Hardon, ... H. Buckmaste... T. Byford, *Ch...* Abscess in W... "Peri-uterine ...

... the serous fluid ... of two or three ... inflammations ... suppuration. ... points, and ... unite into one ... the pus and the ... what has been ... p. 632). Here ... only finds an ... ment or, more ... the labium ... ramen or the ... ment through ... rates the skin, ... in the pelvis. ... into the peri- ... ple extension ... retraction ... , and that ... rm in the ... of the ... charging ... chronic ... later. ... is rare ... rity, and ... an other- ... rations, ... child ... ation of ... peral or ... distention ... or the ... these cases ... ends on the ... between ... micro-

Symptoms.—The symptoms are much like those of peritonitis, but with certain differences. The patient may have a chill; there is a rise in temperature; her pulse becomes frequent; her tongue is furred; she feels weak; she has no appetite; she has pain in the lower part of the abdomen, and, perhaps, vesical or rectal tenesmus; but the pain is not so sudden nor so severe as in peritonitis; there is less tendency to vomiting, and no distention of the abdomen. On vaginal examination we find heat, swelling, and considerable tenderness. If the broad ligament is the seat of the disease, we feel a tumor varying in size between a walnut and an apple. If sufficiently large, it pushes the uterus over to the opposite side. If the inflammation is bilateral, the uterus is lifted up, and often the two lateral tumors may be felt connected by a bridge in front and behind the cervix. If the connective tissue around the sacro-uterine ligaments is affected, we feel the semilunar fold forming the upper limit of Douglas's pouch swollen on one or both sides. Occasionally the swelling may be limited to the connective tissue behind or in front of the cervix (*posterior* or *anterior cellulitis*). If the inflammation extends to the iliac fossa, the corresponding leg is drawn up.

Transition to pus is marked by the swelling becoming soft, but hardly distinctly fluctuating.

Induration of the tissue may last for many months. Often irritability of the bladder continues after the fever and swelling have subsided—a symptom which is referable to shortening of the sacro-uterine ligaments, which pull on the cervix and indirectly on the base of the bladder, which is bound to it with a thin layer of connective tissue.

As to other sequels, we may find amenorrhea, menorrhagia, or dysmenorrhea.

Diagnosis.—Enough has been said under the Symptomatology and in speaking of *pelvic peritonitis* (p. 635) about the difference between cellulitis and the latter disease. *Hematoma* begins suddenly without fever and with great pain. An *inflamed ovarian tumor* may be very hard to differentiate except by the history and later course of the disease. A *common ovarian tumor* is movable. A *uterine fibroid* forms one mass with the uterus and moves with it, whereas in cellulitis it is possible to feel a groove between that organ and the swelling in the broad ligament, and the uterus is more or less immovable. *Retroperitoneal sarcoma* is a chronic disease, in which the constitution soon suffers.

Prognosis.—The prognosis of cellulitis is less grave than that of peritonitis. It may, however, become fatal in a short time through septicemia or develop into the more dangerous peritonitis. As a rule, the prognosis is good as to life, but very uncertain as to time and complete recovery.

Treatment.—All that has been said above about the treatment of peritonitis (p. 636, *et seq.*) applies to cellulitis, whether an abscess is formed or not. I shall, therefore, limit myself to a few additional remarks bearing especially upon cellulitis.

Prophylaxis consists in avoidance of refrigeration and in antiseptic midwifery and surgery. Slowly dilating tents should, as far as possible, be discarded, and replaced by rapid dilatation with steel dilators.

Instead of the hot douche, some recommend a continuous current of ice-water, beginning at a pleasantly warm temperature and diminishing the heat gradually; and, to judge by the superiority of the ice-bag over the poultice in other inflammations, the advice seems worthy of trial. This injection can easily be administered through

Fig. 310.

Frost's Vaginal Syringe.

Frost's vaginal syringe (Fig. 310), which plugs the vagina and has an efferent tube leading down to a vessel under the bed.

If pus begins to form, the maturation of the abscess should be furthered by the use of warm abdominal poultices and warm vaginal injections.

Some recommend early aspiration in several places through the vaginal roof, by which a small amount of bloody serum is withdrawn, but the discomfort unavoidably connected with the operation and the danger of infection make other means of promoting absorption preferable. If pus is formed, aspiration is hardly radical enough to produce a cure.

When pus begins to form in several foci, it is best to give them time to unite before opening the abscess.

If pus follows the round ligament, the operator may succeed in introducing a glass drainage-tube through the inguinal canal.

If an abscess forms between the uterus and the bladder, it must be opened very cautiously by a T-shaped incision in the vagina.

An abscess in the broad ligament may be reached by partial excision of the uterus.[1] First the cervix is removed, and then so much of the body cut away that the finger can be introduced into the

[1] Landau, *Centralblatt für Gynäkologie*, 1892, No. 35, vol. xvi. p. 689.

abscess-cavity. Hemorrhage is exclusively controlled by hemostatic forceps, which are left in place for forty-eight hours. This method would only be available in women with a large vagina.

Some go even so far as to perform total vaginal hysterectomy in order to reach a purulent collection in the pelvis, whether situated in the connective tissue or elsewhere.[1]

Chronic Atrophic Cellulitis.[2]—It consists in a cirrhotic contraction and hardening of the pelvic connective tissue, like that taking place in the kidneys, liver, spleen, lungs, and other organs. It appears in a *circumscribed* and *diffuse* form. The circumscribed is due to ulcers in the bladder and the rectum, laceration of the cervix, or chronic metritis. The induration is situated on a level with the so-called superior sphincter. On the anterior wall of the vagina, corresponding to the base of the bladder, is found a stellate cicatrice, from which the induration can be followed more or less far into the surrounding parts. This condition is combined with congestion of the hemorrhoidal veins. The diffuse form starts from the base of the broad ligament, and may extend through the whole pelvis. The arteries are diminished in size; the veins are either narrowed or dilated, and contain often thrombi or phleboliths. It leads to venous congestion and varicosities, atrophy and sclerosis of the uterus, and synechiæ between the walls of the cervix. The vagina is shortened, and often funnel-shaped. The cervical ganglion (p. 62) is covered and interspersed with cicatricial tissue.

The *causes* of the diffuse form are the same as those of the circumscribed or too great or too frequent sexual excitement, especially masturbation, and losses through hemorrhage and leucorrhea. Chlorotic women with hypoplasia of the genitals and the circulatory system are particularly predisposed to it.

Symptoms.—Patients affected with chronic atrophic cellulitis have a decided propensity to masturbation, with indifference, or even aversion, for coition. They suffer often from erotic dreams, with emissions of mucus. They complain of pain in the iliac fossa, dyschezia, dysuria, dysmenorrhea, often intermenstrual pain (p. 404), and the disease is always accompanied by hysterical symptoms, among others copiopia hysterica (p. 238).

Prognosis.—The circumscribed form may be cured when the cause is removed, and especially if pregnancy supervenes. The diffuse is incurable, but may remain stationary for long periods.

Treatment.—The causes must be removed, the vagina treated with

[1] Péan, *Bulletin de l'Académie de Médecine*, No. 27, 1890; Segond, "De l'Hystérectomie vaginale dans le Traitement des Suppurations pelviennes," *Revue de Chirurgie*, 1891, No. 4.

[2] This disease has been described by Wilhelm A. Freund in *Gynäk. Klinik*, vol. i. pp. 239–326.

iodine glycerin or ichthyol glycerin and packing, and cicatrices cut out or incised and stretched (p. 345). The many reflex neuroses are treated as hysteria, especially with nitrate of bismuth, nitrate of silver, acetate of zinc, ammonia, castoreum, and valerian. During the hysterical attack nothing should be done, as any interference only serves to make the condition worse.[1]

C. *Pelvic Phlebitis.*

Pelvic phlebitis is a rare disease. It is primary in puerperal cases, the inflammation starting in the sinuses of the uterus. In this variety the inflammation begins in the internal coat, and soon a thrombus forms in the lumen. The inflammation spreads outward, and may implicate the connective tissue.

In non-puerperal cases it is exceedingly rare, and begins as periphlebitis, an affection following secondarily on acute cellulitis.

Congestion of the pelvic veins is very common, and the presence of phleboliths in the veins at the base of the broad ligament is not a rare occurrence. This congestion, which must not be confounded with phlebitis, is often much relieved by lifting the uterus with a pessary, and thereby giving a straighter course to the veins.

Pelvic phlebitis blends always with cellulitis, and clinically they cannot be distinguished.

D. *Pelvic Lymphangitis and Lymphadenitis.*

In the anatomical part (p. 62) we have seen that the uterus is exceedingly rich in lymph-spaces and lymph-vessels, uniting in trunks which traverse the broad ligament and lead to the different glands in the pelvis. The lymphatics from the upper three-fourths of the vagina go the same way, while those from the vulva and the lower fourth of the vagina go to the superficial inguinal glands, that communicate with the deep inguinal glands, from which other vessels go to the external iliac glands. Those from the tube and the ovary traverse the broad ligament, and go through the infundibulopelvic ligament to the lumbar glands.

The inflammation may extend from any part of the genital tract into the broad ligament and the peritoneum, causing lymphangitis, lymphadenitis, cellulitis, or peritonitis.

The lymphatic vessels play a very important part in the propagation of infection in the puerperal state,[2] and the inflammation following is then acute.

[1] In this connection it is quite interesting that Freund states that in Strassburg they do not see the attacks described by Charcot in Paris—an experience which is shared by many others in other places.

[2] See Garrigues, "Puerperal Infection," Hirst's *Amer. System of Obstetrics*, vol. ii. pp. 290–378.

In non-puerperal cases lymphangitis and lymphadenitis also exist, but seem to be rare, or so blended with other pelvic inflammations that they seldom can be discovered. Many authors do not mention the affection at all; others have little to say about it or are doubtful as to its existence. In a gynecological practice extending over more than twenty years, in which I have examined I do not know how many thousand women, I have never found a case myself, unless a few in which the gland on the side of the isthmus was swollen belonged to this category. One was kindly demonstrated to me by Dr. P. F. Mundé in 1883, but, although I felt the small tumors behind the uterus, I am not sure that they were swollen lymphatic glands. But the disease having been described by such excellent observers as Courty, Championnière, Mundé, A. Martin, and others, each of whom claims to have seen, if not many, at least a certain number of cases, I do not doubt its existence, and shall here give a résumé of their descriptions.

The non-puerperal form is either *acute* or *chronic*, more frequently the latter. Lymphadenitis is characterized by the occurrence of small, rounded, irregular, uneven tumors, varying in size from a pea to a small hazelnut, and situated to the sides of the isthmus of the uterus, more frequently on the right, or on the posterior surface of the uterus. They are loosely connected with the latter and the vagina. Most authors claim only to have felt from one to three such tumors, but Mundé has found at least twenty[1] on the posterior surface of the uterus, and Martin speaks of glands in the broad ligaments forming rows like strings of pearls of moderate size.[2]

Now, there is this objection to the theory of looking upon these tumors as glands, that only those glands which I have mentioned in the anatomical part have been found in the pelvis by anatomists—namely, Championnière's gland at the side of the isthmus, the obturator gland, the external iliac glands, the internal iliac glands, and the sacral glands. On the posterior surface of the uterus there are none; but, on the other hand, there are large plexuses of lymphatic *vessels;* and those small tumors felt clinically above the posterior vault of the vagina are probably clusters of swollen lymph-vessels or pouch-like dilatations of such vessels, just as we find them in puerperal cases, in which they may reach the size of a cherry. The same explanation holds good for the rows of swellings felt in the broad ligament.

A third possibility is that the small tumors may be due to localized perilymphatic inflammation.

A. Martin thinks that cellulitis often begins as lymphadenitis, the gland suppurating and pouring its contents into the connective tissue

[1] P. F. Mundé, *Amer. Jour. Obst.*, 1883, vol. xvi. p. 1018.
[2] A. Martin, *Frauenkrankheiten*, p. 323.

of the broad ligament. Even without such suppuration and rupture it is very likely that cellulitis often starts from perilymphangitis.

Etiology.—The inflammation of the lymphatics is caused by endometritis—either catarrhal or non-specific purulent or gonorrheal. Lymphadenitis may also be due to syphilis or scrofula, when it is apt to be combined with adenitis in other parts of the body.

Symptoms.—The patient complains of a pain deep in the pelvis, rather to one side, especially the right, extending to the pubes and the obturator foramen or downward and backward to the coccyx, and of a tenderness rendering coition painful. There is no rise in temperature. The parametrium is swollen and tender, but without effusion. The uterus is movable, but its movement causes pain. It is enlarged, tender, and often retroflexed. The ovaries are also swollen and tender. Behind and to the sides of the uterus are felt the above-described small tumors, which are very tender and somewhat movable, or a bundle of tender, movable cords which impart a feeling like a bunch of angle-worms.[1]

Diagnosis.—The tumors are much smaller and situated lower down than the *ovary*, not so movable, and when pressed do not cause the sickening pain elicited by pressure on the sexual gland.

Their own mobility and the mobility of the womb distinguish them from cellulitis.

The movable, worm-like cords are pathognomonic of lymphangitis.

Treatment.—When endometritis is the cause, it should be treated according to the rules laid down for that disease (pp. 392 and 399). Iodine (p. 165) and ichthyol glycerin (p. 173) should be used in the vagina. Packing of the vagina (p. 173) gives much relief and makes the swelling disappear. Iodoform suppositories (p. 218) are useful both as anodynes and as resolvents. It is recommended to use inunctions of Ung. hydrargyri (20 parts) and Ext. belladonnæ (1 part) on the hypogastric region. Galvanism has also proved beneficial. In extreme cases it may be justifiable to try to favor involution of the hyperplastic uterus by amputation of the cervix (p. 428). If the patient is affected with scrofula or syphilis, the usual remedies for those diseases should be combined with the local treatment.

[1] The great tenderness of the tumors, even in chronic cases, speaks also against their being glands, for chronically inflamed lymph-glands, which are so common in scrofula and syphilis, are not sensitive to touch.

CHAPTER VIII.

SARCOMA AND CARCINOMA OF THE PELVIC PERITONEUM AND CONNECTIVE TISSUE.

CANCER of the pelvis is usually only part of a similar affection spread over a larger territory or a direct propagation by continuity from neighboring organs. Thus, carcinoma of the broad ligament appears in connection with the same affection in other parts of the peritoneum, or begins as carcinoma of the uterus or the ovary. But both sarcoma and carcinoma may start as a primary disease in Douglas's pouch, and carcinoma may begin in the lymphatic glands.

Sarcoma may form a large tumor behind the uterus, pushing this organ forward. Medullary carcinoma often appears as a relapse in the cicatrix after removal of the carcinomatous uterus.

The malignant nature of these affections is proved by the cachexia which rapidly follows their advent. It is rarely possible to do anything of therapeutical value for them, except in the cases of relapse after hysterectomy. A patient who has had her uterus extirpated should be examined every few months for many years, and as soon as a local relapse appears the diseased tissue should be cut away and the wound cauterized.[1]

CHAPTER IX.

HYDATIDS (ECHINOCOCCI) OF THE PELVIS.

HYDATIDS are so rare that few physicians have had opportunity to see a case,[2] but of the entire number reported 4 per cent. were situated

[1] Dr. M. D. Jones has reported a case in which a carcinomatous tumor of the size of an orange in the pelvic floor was combined with a similar affection of the ovaries. She removed all the diseased tissue, and made a microscopical examination that is of great interest, because it proves that the so-called inflammatory infiltration that surrounds a carcinoma to a distance of a quarter to half an inch is in reality a precursory stage of carcinomatous infiltration, the inflammatory corpuscles shaping themselves into the epithelial cells characteristic of carcinoma, and that the disease spreads by such cancer-cells being transmitted into the lymphatics and causing thrombosis of, and carcinomatous infection around, them (*Medical Record*, March 11, 1893, vol. xliii. p. 292).

[2] Personally, I have only seen one case, and that was in the liver (*Proceedings of the Medical Society of Kings*, Brooklyn, N. Y., 1876, vol. i. No. 5, p. 123). In the above description I chiefly follow W. A. Freund, who, living for many years in an echinococcus district, has had the rare opportunity of treating eighteen cases of hydatid disease in the true and false pelvis, and who has described them in his *Klinik der Gynäkologie*, vol. i. pp. 299–326. Four of these he has previously described, conjointly with J. R. Chadwick of Boston (*Amer. Jour. Obst.*, Feb., 1875, vol. vii. pp. 668–679).

in the pelvis; and the disease is by far more common in women than in men.[1]

Pelvic hydatids are most common in the connective tissue of the posterior part of the pelvis near the rectum, but are also found in the uterus, the ovaries, the broad ligaments, the anterior part of the pelvis, and anywhere in the bones. As a rule, the animal consists of a mother-cyst with endogenous or exogenous daughter-cysts. The multilocular, or alveolar, form has never been found in the pelvis.

The echinococcus may enter the pelvis as a germ or reach it by extension from another part of the abdomen. Beginning in the pelvis, the cyst may rise above the superior strait or follow the connective tissue of the pelvis, press down on the perineum, grow out through the great sacro-sciatic foramen or the crural canal, and extend up on the anterior wall of the abdomen. In consequence of pressure from neighboring organs the animal may die, the fluid become turbid, purulent, or sanious, and the vesicles be broken up into shreds. Rupture may take place into the bladder, or exceptionally into the uterus or the vagina, but never into the peritoneal cavity—the peritoneum, on the contrary, always becoming thickened. Such rupture may lead to a cure.

Etiology.—The disease is due to the entrance into the body of the eggs of the *Tænia echinococcus* of the dog. As a rule, the entrance takes place through the mouth, but some women allowing their genitals to be licked by dogs for libidinous purposes, it is not impossible that the germs might be brought directly into the genital tract instead of passing through the alimentary canal. The disease is endemic in certain parts of the world, such as Australia, Iceland, Mecklenburg, and Silesia.

Symptoms.—The disease may exist for years without impairing the general health or even causing much local trouble. Attention is first called to it when it causes dyschezia, dysuria, or dystocia, and often it gives rise to leucorrhea or menorrhagia. Later the nutrition suffers, the patient loses flesh, and she may become feverish, either when suppuration sets in or when the constitution becomes undermined. In consequence of pressure her feet may swell, her legs become paralyzed, she may have sciatic neuralgia or hydronephrosis, and even intestinal obstruction may develop. Death is often due to the presence of an echinococcus cyst in another organ.

Diagnosis.—The disease being nearly exclusively limited to certain regions, geographical considerations may give a hint as to its exist-

[1] The Icelandic physician Jon Finsen personally treated 245 cases of echinococcus disease. Of these, 172, or more than 70 per cent., were in the female sex (*Ugeskrift for Læger*, 3d series, 3d vol. Nos. 5–8, Copenhagen, 1867). A French translation, made by myself from the Danish original, is found in *Archives générales de Médecine*, Jan. and Feb., 1869, vol. i. pp. 23–46 and 191–210).

ence. Early in its course the presence of one or more round, remarkably smooth, tensely elastic tumors in the connective tissue of the posterior part of the pelvis, with a thin homogeneous wall, little movable, insensitive, unconnected with the uterus or the ovaries, and not causing any local or general disturbance, makes it very likely that one has to deal with one or more echinocóccus cysts in the connective tissue. The last point is the basis of the differential diagnosis from *intraligamentous ovarian cysts*, which very early become the source of such disturbances. The cervix is also very characteristic in hydatids, being situated in a depression surrounded by an elastic mass like an air-cushion.

The fluid contained in the cyst is colorless, opalescent, or yellow; clear or turbid. It does not contain albumin or only traces of it, but succinic acid, leucin, grape-sugar, inosite, and sometimes urea and uric acid. A single hooklet from the scolices (young tape-worms) or the smallest piece of cuticula (the tunica propria of the sac) which shows parallel structureless layers arranged with the utmost regularity, and which is not affected by acetic acid, is pathognomonic of a hydatid.[1] If exploratory puncture is resorted to, it must, however, be made with the strictest antiseptic precautions.

A *vesicular mole* always forms one continuous body, and has characteristic appendages, while the echinococcus often is multiple, and has a smooth surface. *Fibroma* is harder and nodular.

The hydatidic thrill cannot be utilized for the diagnosis, as it cannot be felt in pelvic hydatids.

Treatment.—If the tumor is confined to the pelvis, and does not cause much discomfort, it is better to leave it alone. But if it is necessary to interfere, it is best to make a large incision in the vagina. If there are numerous tumors, the internal use of potassium iodide and tincture of kamala (ʒj–℥ss) has been recommended. Electrolysis may, perhaps, kill the animal and cause absorption. A submucous uterine hydatid may be treated with ergot in the hope of its becoming pedunculated like a fibroid polypus. If the tumor rises into the abdominal cavity, laparotomy should be performed, the tumor enucleated, and the cyst-wall of connective tissue formed around the animal, the so-called ectocyst, treated as after enucleation of a fibroid (p. 479). Often it is not possible to remove the whole mother-cyst, and then the edges of the opening made in the cyst should be stitched to those of the abdominal incision and packed with iodoform gauze. After spontaneous rupture of an echinococcus cyst it is necessary to dilate the opening or make a counter-opening.

[1] Garrigues, *Diagnosis of Ovarian Cysts*, p. 74.

APPENDIX.

STERILITY.

[illegible] proper to begin the description of the diseases [illegible] chapters on the two symptoms hemorrhage and [illegible] advisable for practical purposes to finish with [illegible] as a symptom that often impels the patient [illegible] depends upon a great variety of conditions, [illegible] treatment, part of which has not been described [illegible]

[illegible] the physiological part of this work (p. 120) that [illegible] the union of the male and the female genera- [illegible] many obstacles may prevent such union or, if it [illegible] the development that results in the formation of [illegible] premature expulsion of the fetus by abortion or mis- [illegible] leads to childlessness, belongs to the domain of [illegible]

[illegible] ness, or infecundity we understand the lack of [illegible] or impregnation. One marriage out of every [illegible] is commonly believed that the fault is always [illegible] found in the wife, and with some people it has [illegible] cause for repudiation; but modern investiga- [illegible] the husband is at fault in about one case out of [illegible]

[illegible].—Infecundity in man may be due to *impotence*, [illegible] the sexual act; to *aspermatism*, absence of [illegible] *azoospermia* (also called azoöspermatism or azoö- [illegible] condition in which the ejaculated semen does not con- [illegible] zoids, and, therefore, has no fertilizing power. It [illegible] man may produce healthy semen in his testicles, [illegible] nature with abnormal secretions during the passage [illegible] deferens, the canalis ejaculatorius, and the urethra a [illegible] in consequence of which the spermatozoids soon die. [illegible] cause of sterility in the male is latent gonorrhea. A [illegible] been free from gonorrheal discharge for years, and

[illegible] *Impotence, Sterility, and Allied Disorders in the Male Sexual* [illegible] 1881, p. 88.

still an olive-pointed bougie may discover wide strictures in the membranous part of the urethra, and bring to light a drop of muco-pus, while at the same time spermatozoids are absent, a condition which is supposed to be due to the action of micrococci.[1]

Sterility in the Female.—The female genital tract being so much longer than that of the male, and subject to such numerous diseases, it is quite natural that the cause of barren marriages is found so much more frequently in woman than in man.

It should be borne in mind that fecundity in women is limited to a certain period of their lives. Before puberty and after the climacteric sterility is normal.

Sterility may be *primary* or *secondary*. It is primary when a woman, in spite of frequent intercourse, never conceives; it is secondary if it appears after she has had one or a few children.

The sexual element (the ovum) may be absent or it may be prevented from contact with the male element, the spermatozoid, by incapacity for copulation, which, again, may be mechanical or nervous; by incapacity for conception, which may be due to local tissue-changes or constitutional disturbances; or by incapacity for gestation.

1. *Absence of Ova.*—In chronic oöphoritis the ovisacs and ova are often diseased and disappear (p. 536).[2] By the development of cysts and solid tumors of the ovaries the ovisacs may disappear, but the sterility so common in these cases is often due to other causes (p. 565).

2. *Incapacity for Copulation.*—Incapacity for copulation may be mechanical or nervous.

a. Mechanical incapacity may either be *absolute*, as in cases of the absence of the vulva (p. 247), coalescence of labia (p. 250), or atresia of the hymen (p. 317) or vagina (p. 319); or it may only be *relative*, opposing a more or less important obstacle to the perfect union of the sexes, such as solid or cystic tumors of the vulva (pp. 267–279), kraurosis (p. 280), or cysts, fibroids, mucous polypi, or carcinoma of the vagina (pp. 348, 350, 352). A tear of the perineum, allowing the semen to flow out, may also be a cause of sterility, but is of comparatively small importance.

(*b*) *Nervous incapacity* is connected with hypæresthesia of the vulva (p. 267), painful urethral caruncle (p. 274), and, in its worst form, with vaginismus (p. 345).

3. *Incapacity for conception* may either be *local* or *constitutional*.

(*a*) *Local incapacity* may, again, constitute an absolutely insur-

[1] E. Noeggerath was the first to call attention to latent gonorrhea in both sexes, and its influence on fertility (*Trans. Amer. Gyn. Soc.*, 1876, vol. i. p. 268, *et seq.*).

[2] These retrograde processes have been carefully studied and delineated by Mary Dixon Jones (*Med. Record*, Sept. 19, 1891, vol. xl. p. 324).

mountable obstacle to conception, as in cases of absence of the uterus (p. 375), a rudimentary uterus (p. 376), atresia of the genital canal (pp. 317, 319, 378, 407), or only a more or less serious hindrance. Vaginal catarrh (p. 335) may cause sterility through the hyperacidity of the discharge, which kills the spermatozoids. Women with urinary fistulæ rarely conceive, partly on account of mutual disinclination to copulation, partly in consequence of concomitant diseased conditions.

Most of the malformations and diseases of the uterus, tubes, ovaries, and pelvis are accompanied by or have a tendency to produce sterility, such as the fetal, infantile, or pubescent uterus (pp. 379–380), congenital or acquired displacements of the uterus (pp. 381, 419–452), elongation and hypertrophy of the cervix (pp. 381, 411), stenosis of the cervical canal (pp. 381, 408), superinvolution of the uterus (p. 417), chronic endometritis (p. 394), or a polypus obstructing the cervix or the tube (p. 453). Women with sessile fibroids are, as a rule, also sterile, and their barrenness is probably due more to the accompanying catarrh than to the mechanical obstruction. In carcinoma of the cervix (p. 486) infecundity may be due to the constitutional disturbance as well as to mechanical obstacles.

In regard to the Fallopian tubes congenital contortions (p. 502) or acquired displacements (p. 522) may oppose an impediment to the free movement of the ovum or the spermatozoids. They may be impervious (p. 502), or their inflammation (p. 505) or neoplasms (p. 522) may prevent conception.

The surface of the ovaries may be so covered with inflammatory products that the ovum cannot escape (p. 536).

The presence of hydatids in the pelvis (p. 652) or a mole in the uterus, uterine hemorrhage, or leucorrhea from whatever cause, may render the woman sterile.

(*b*) *Constitutional Incapacity.*—Anemic women are less likely to conceive than healthy women. Great obesity is quite frequently accompanied by barrenness. Tuberculosis, syphilis, and cancer, all diminish fecundity. The same applies to masturbation (p. 292) and to too frequent or violent coition, as in prostitutes. It is not unlikely that in the last-named condition impregnation often takes place, but that the ovum is expelled at so early a date that not even menstruation is interrupted.

Bisulphide of carbon seems to exercise a highly deleterious influence on procreation in both sexes among those whose calling exposes them to its influence. It is used much in the arts as a solvent for vegetable oil and rubber. In the male it lessens the desire and the power for sexual intercourse. In females conception is rare, and, when it takes place, they almost always abort.

4. *Incapacity for Gestation.*—This condition is often combined with the incapacity for conception, barrenness alternating with abortions

and miscarriages. An inflamed endometrium, for instance, offers a poor soil for the growth of an ovum, so that fetal development is likely to be arrested, the pregnancy ending in a miscarriage; but the ovum may also be washed out by hemorrhagic and leucorrheal discharges, before it ever becomes imbedded, and perhaps before it is fertilized.

Diagnosis.—Fecundity depending upon the union of elements derived from two individuals, it is proper in a case of sterility to look for the cause or causes in both persons concerned; but, unfortunately, it happens that the husband, while he is quite willing to submit his wife not only to the most searching physical examination, but even to operative procedures, absolutely refuses to be examined himself. There is, sometimes, a lingering doubt in his mind that the fault might be on his side, and he dreads above all to acquire this certainty, or at least to let his wife know it. If he is willing to give the necessary information, he should, first of all, be questioned in regard to copulation, ejaculation, syphilis, and gonorrhea. The proper position of his meatus urinarius should be ascertained. His urethra should be carefully examined with a bougie-à-boule or an endoscope as to caliber and small pus-secreting surfaces lurking behind strictures. Finally, his semen must be examined microscopically. The proper way of obtaining it unmixed with foreign substances is to let him have intercourse with his wife, using a condom. Immediately after copulation this bag with its contents is thrown into a wide-mouthed bottle and brought to the physician, who examines it without delay. If the man's semen is full of living spermatozoids, the examination may be extended to the woman, in order to find out if there is any discharge in the vagina that kills the spermatozoids. For this purpose the husband should be allowed to have normal intercourse with his wife, and shortly after the act a little semen should be removed from the posterior vault of the vagina with a Simon's spoon and examined microscopically. Often it suffices, however, to examine the woman without having recourse to this somewhat repugnant procedure.

In examining the woman the physician will bear in mind all the malformations and diseases just enumerated that may entail sterility. The vaginal secretion should be tested with litmus-paper. It is normally acid, but it may be so to such a degree that it kills the spermatozoids. It should also be examined microscopically for pus-corpuscles, the presence of which always shows inflammation. The utero-tubal mucus is obtained by introducing a speculum and taking the mucus directly out of the cervical canal. This is normally alkaline, and any acid fluid is deleterious to the spermatozoids.

Treatment.—In regard to the treatment of the man the reader is referred to works on venereal diseases.

Often a certain mutual adaptation seems to be necessary. Nothing is more common than that impregnation does not take place immediately upon entering upon marital relations. Many months may even elapse before it occurs between perfectly healthy individuals. A little patience is, therefore, always to be recommended. But, on the other hand, accurate statistics have shown that three-fourths of married women get a child in the course of the first year of their marriage, and that if three years elapse without offspring the chances of having children become very small. As a practical rule, we may say that if a woman does not conceive during the first year of her marriage, and wishes to become a mother, she had better seek medical advice.

The entrance of the semen into the uterus may be favored by raising the pelvis during copulation or by coition *modo brutorum*. Traveling has a marked influence, which may be due to climatic influences, change of diet, or, more likely, the diversity of couches.

The causes of sterility in the female being so manifold and comprising most of the malformations and diseases treated of in this work, the treatment will, of course, also vary much, the general rule being to remove, if possible, whatever cause or causes we may find by the means indicated in the preceding chapters.

Anemia is treated with iron, manganese, strychnine, cod-liver oil, terraline, and a diet in which albuminoids preponderate, and into which enters the use of milk, beer, or wine. Adipose tissue is reduced by iodine, fucus marina, exercise, massage, Turkish baths, and a diet from which sweets and cereals are nearly excluded, and in which liquids are limited as much as possible.[1]

A too small uterus may sometimes be enlarged by the galvanic current.

Many different operations may be called for in order to remedy sterility. The labia may have to be separated; a resistant hymen removed; a painful caruncle destroyed; a vagina made; or an elongated cervix amputated. The cervical canal may require dilatation, which may be kept up by the use of Outerbridge's permanent dilator (p. 181); a polypus may have to be cut off; a spongy endometrium may need curetting, etc. Sometimes the operation required is not one of division, but of union, as when a torn perineum and vagina are repaired or trachelorrhaphy is performed. A torn cervix would seem to favor impregnation by offering freer entrance to

[1] Such a diet should be composed of beef, mutton, veal, pork, game, poultry, eggs, fish, lobsters, crabs, shrimps, oysters, clams, scollops, muscles, cheese, green vegetables, lettuce salad, and a small amount of juicy fruit, with a pint of claret or Moselle wine, a cup of black coffee, a cup of tea without milk, and four ounces of bread per day. Butter and other fats are harmless. Forbidden, on the other hand, are soups, water, milk, beer, potatoes, beets, puddings, pies, and other sweet dishes, as well as bananas.

the interior of the womb; but, on the other hand, the endometritis following the tear is a barrier to conception; and, as a matter of fact, I may state that I have repeatedly removed sterility by this operation.

Laparotomy will hardly be undertaken for sterility alone, since it would risk an existing life in the uncertain hope of rendering another possible; but when it is undertaken for legitimate causes, it may perhaps even cure sterility, if the operator finds it possible to leave one or both ovaries, and render the tubes permeable (p. 511).

When all other means fail, or no cause for the sterility can be found, or the woman refuses any kind of cutting operation, we may yet try *artificial impregnation.* Since the fundamental condition of fecundity is the union of a spermatozoid and an ovum (p. 120), since in most cases it is an easy matter to introduce semen all the way up to the fundus of the uterus, and since artificial fertilization is used on a large scale in pisciculture, one would think that artificial impregnation of a woman could likewise be performed without difficulty. But it is not so. It has been tried many times, but has nearly always proved a failure.

The operation is very simple. The semen of the husband having been found normal, and especially after ascertaining that it does not contain pus-corpuscles, he has intercourse with his wife, using a condom. This he brings to the physician waiting in another room. The latter has in readiness an intra-uterine syringe (p. 168) properly disinfected and kept warm. He sucks a small amount of semen up with the syringe, exposes the os uteri with a speculum, wipes it off with cotton dipped in some antiseptic fluid, introduces the nozzle up to the fundus, and expresses a few drops slowly into the interior of the womb. The woman should stay in bed on her back, and if she feels any pain an ice-bag should be applied to the hypogastric region. The most favorable time for performing the operation is shortly before menstruation is expected, and the next best period is immediately after the catamenia (p. 118). It may, of course, be repeated during several months, if the first attempt does not succeed.

Lack of Orgasm.—A condition for which we are not infrequently consulted is lack of the normal feeling of the highest sexual excitement called orgasm (p. 120). Both the husband and the wife deplore a defect which deprives the marital relation of its highest physical satisfaction, and some knowing women, in order to retain their husbands' affection, simulate a state which does not exist in reality. Some women have never felt this sensation. With them the fault is congenital, and is probably due to some imperfection in the central nervous system. Others know the sensation from previous experience, but have lost the faculty of having it. Some have it dreaming, but never during intercourse. The lack of orgasm,

[illegible] may be found in [illegible] a barrier to conceptio[illegible] [illegible]rable, and it is very [illegible] a better prognosis. [illegible] with the use of toni[illegible] such as damiana, pl[illegible]

ILLUSTRATIONS.

DEVELOPMENT.

FIG. PAGE

1. Wolffian Ducts 19
2. Urogenital Sinus 20
3. Wolffian Bodies 21
4. Beginning of the Round Ligament 22
5. Lateral Canals of Wolffian Body 23
6. Transformation of the Wolffian Body in the Male 24
7. Transformation of the Wolffian Body in the Female 24
8. Transverse Section of Ovary of Human Embryo three months old 24
9. Transverse Section through Region of Ovary of Human Embryo five months old 25
10. Ovary of Human Fetus ten to eleven weeks old 25
11. Part of Ovary of Human Fetus sixteen weeks old 26
12. Part of Ovary of Human Fetus twenty-eight weeks old 26
13. Part of Ovary of Human Fetus thirty-six weeks old 26
14. Part of Ovary of a Girl three days old 27
15. Perpendicular Section of Ovary of a Bitch six months old, showing tubes with primordial ova 28
16. Graafian Follicles of New-born Girl 28
17. Graafian Follicle of a Girl seven months old 29
18. Primordial Ova undergoing Division 29
19. Transverse Section of Embryo of Rabbit fourteen days old, showing the formation of the Müllerian Ducts 30
20. Transverse Section through the Genital Cord of Embryo of Cow 31
21. Ovaries, Tubes, and Horned Uterus of Human Embryo in the tenth week . . 31
22. Entrails of Abdomen and Pelvis of a Female Human Embryo five months old 32
23, 24, 25. Formation of Anus, Cloaca, and Urogenital Sinus 32
26. Urogenital Sinus and Organs opening into it 33
27. Development of the External Sexual Organs in the Male and the Female . . 34

ANATOMY.

28. External Genitals 36
29. Hottentot Apron (colored plate) 37
30. Front View of Perineal Septum, showing entire Clitoris 38
31. Nerves of Pelvic Viscera (colored plate) 39
32. The Vestibulovaginal Bulbs 40
33. The Vulvovaginal Gland 41
34. Sagittal Section of Pelvis 42
35. Horizontal Section of the Soft Parts in the Inferior Strait of the Pelvis . . . 43

FIG. PAGE
36. Microscopical View of Longitudinal Section of the Vagina of a Girl twenty-four years old . . . 44
37. Transverse Section of the Same . . . 44
38. The Arteries of the Uterus, the Ovaries, and the Vagina (colored plate) . . . 44
39. The Venous Plexuses of the Vagina and Vulva, as seen in mesial section . . 45
40. Hymen with Linear Opening . . . 46
41. Annular Hymen . . . 46
42. Crescent-shaped Hymen . . . 47
43. Indented Hymen . . . 47
44. Virgin Uterus . . . 48
45. The Utricular Glands . . . 50
46. Section of the Mucous Membrane of the Uterus, parallel to the surface . . . 51
47. Fiber of Endometrium, showing different degrees of corpuscular development 52
48. Uterine Epithelial Cells . . . 52
49. Mesial Section of the Pelvis of a Girl seventeen years old . . . 53
50. Diagram of Mesial Section of the Pelvis of a Living Woman . . . 54
51. Endometrium of a Woman sixty years old . . . 54
52. Diagram of the Ligaments of the Uterus . . . 55
53. The Pelvic Viscera, seen from above . . . 56
54. The Right Wall of the Pelvis, showing insertion of the broad ligament . . . 57
55. The Vessels of the Vagina and the Internal Genitals in their relation to the superficial muscular structures . . . 58
56. Tube and Ovary of a Woman who died during Menstruation . . . 59
57. The Uterine Artery in its relation to the Ureter . . . 60
58. The Uterine Veins and the Ureter . . . 61
59. Fallopian Tube, Ovary, and Parovarium . . . 63
60. Fallopian Tube laid open . . . 64
61. Ovary and Tube of Girl nineteen years old . . . 66
62. Ovary and Tube of Girl twenty-four years old . . . 67
63. Section of Ovary of Cat . . . 68
64. Part of the Same, more highly magnified . . . 69
65. Diagram of Zones in Human Ovary . . . 69
66. Graafian Follicle of Adult Woman . . . 70
67. Ovum of Rabbit . . . 71
68. Corpus Luteum of Woman two days after menstruation (colored plate) . . . 71
69. Corpus Luteum of Woman twenty days after menstruation (colored plate) . . 71
70. Cicatrice of Corpus Luteum nine days after menstruation (colored plate) . . . 71
71. Corpus Luteum at term of pregnancy (colored plate) . . . 71
72. Microscopical Structure of Corpus Luteum of Pregnancy ten to twelve days after rupture . . . 72
73. Normal Menstrual Body . . . 73
74. False Corpus Luteum (colored plate) . . . 71
75. Ovary of Woman filled with Yellow Masses . . . 75
76. Ovary of Woman with Cystic Corpus Luteum and Numerous spread Yellow Masses . . . 76
77. Ovary of Woman with Cystic Corpus Luteum and Numerous Yellow Masses with Remnant of Central Cavity . . . 76
78. Parovarium . . . 77
79. Urethral Ducts (Skene's glands) . . . 78
80. Uterus, Ureters, Bladder, and Upper Part of Vagina . . . 79

FIG. PAGE
81. Superficial Layer of Bladder Epithelium 80
82. Deep Layers of Bladder Epithelium 80
83. The Course of the Ureters 82
84. Epithelium of Pelvis of Kidney 83
85. The Rectum inflated with Air 84
86. Vertical Section of lower end of Rectum 85
87. Muscles of Perineum 87
88. Muscular Coat of Rectum 88
89. Mesial Section of Peritoneum with Empty Bladder 89
90. Mesial Section of Peritoneum with Full Bladder 90
91. Position of Viscera at the Pelvic Brim 92
92. Coronal Section of Pelvic Cavity 93
93. The Pelvic Fascia 95
94. Levator Ani, seen from below 96
95. Side View of Levator Ani 98
96. Pelvic Floor in mesial section 99
97. Transverse Section of Pelvis through Axis of Vagina 100
98. The Muscles of the Perineum 102
99. Horizontal Section of Pelvis 109
100. Coronal Section of Body 111

PHYSIOLOGY.

101. Uterus during Menstruation 115
102. Endometrium of Menstruating Woman 116

EXAMINATION.

103. Daggett's Table 133
104. Dorsal Position 134
105. Sims's Position 135
106. Genupectoral Position 136
107. Trendelenburg's Position 137
108. Combined Vaginal and Abdominal Examination 139
109. Simon's Urethral Dilators 141
110. Ferguson's Speculum 142
111. Brewer's Speculum 143
112. Sims's Speculum 143
113. Introduction of Sims's Speculum 144
114. Sims's Depressor 145
115. Hunter's Depressor 145
116. Mundé's Speculum 146
117. Mitchell's Speculum 146
118. Ehrich's Speculum 147
119. Garrigues's Depressor 147
120. Bozeman's Dressing-forceps 148
121. Burrage's Cervical Speculum 148
122. Ashton's Rectal Speculum 149
123. Kelsey's Rectal Speculum 149
124. Jackson's Urethral Speculum 149
125. Skene-Folsom's Urethral Speculum 150

FIG.
126. Simpson's Uterine Sound . . . . . .
127. Sims's Sharp Curette . . . . . .
128. Simon's Sharp Curette . . . . . .
129. Thomas's Dull Wire Curette . . . . . .
130. Barnes's Tent-carrier . . . . . .
131. Hanks's Small Uterine Dilators . . . . . .
132. Garrigues's Uterine Dilator . . . . . .
133. Hanks's Large Uterine Dilators . . . . . .
134. Aspirator . . . . . .
135. Epithelial Cells found in Urine . . . . . .
136. Simon's Method of Catheterization of the Ureters . . . .
137. Pawlik's Furrows on the Anterior Vaginal Wall, correspondi
138. Pawlik's Ureteral Catheter . . . . . .

TREATMENT.

139. Budd's Uterine Applicator . . . . . .
140. Bed-pan . . . . . .
141. Braun's Uterine Syringe . . . . . .
142. Bozeman's Double-current Uterine Tube . . . . . .
143. Keyes's Irrigator for Bladder . . . . . .
144. Nott's Double-current Catheter . . . . . .
145. Rubber Bag with Stopcock for injecting Bladder . . . . . .
146. Récamier's Curette . . . . . .
147. Packing the Vagina . . . . . .
148. Garrigues's Intra-uterine Packing-forceps . . . . . .
149. Paquelin's Thermocautery . . . . . .
150. Clinton Cushing's Instrument for Ligating the Uterine Art
151. Koeberlé's Artery-clamp . . . . . .
152. Outerbridge's Permanent Dilator of Cervix . . . . . .
153. Carrier for the Same . . . . . .
154. Abdominal Glass Drainage-tube . . . . . .
155. Reese's Artificial Leech . . . . . .
156. Buttle's Uterine Scarificator . . . . . .
157. Bath-Speculum . . . . . .
158. Trocar with Blunt Stylet . . . . . .
159. Abdominal Belt . . . . . .
160. Fitch's Abdominal Supporter . . . . . .
161. Howard Kelly's Perineal and Ovariotomy Cushions . . . .
162. Clover's Crutch . . . . . .
163. Robb's Leg-holder . . . . . .
164. Nozzle with Stopcock . . . . . .
165. Greig Smith's Ligature-box (modified) . . . . . .
166. Dowd's Condenser . . . . . .
167. Allis's Ether Inhaler . . . . . .
168. Esmarch's Chloroform Mask . . . . . .
169. Schroeder's Lateral Vaginal Retractors . . . . . .
170. Emmet's Tenaculum . . . . . .
171. Volsella . . . . . .
172. Thomas's Tissue-forceps . . . . . .

FIG. PAGE
173. Sims's Sponge-holder 206
174. Needles 207
175. Needles with Handles 207
176. Sims's Needle-holder 208
177. Emmet's Needle-holder 209
178. Hagedorn's Needle-holder 209
179. Bringing Pared Surfaces together with Sutures 211
180. Emmet's Counter-pressure Hook 211
181. Emmet's Wire-twister 212
182. Shouldering Wire Sutures 212
183. Sims's Suture-shield 212
184. Beginning a Catgut Tier-suture 213
185. Second Deep Row of Tier-suture 214
186. Apostoli's Bipolar Vaginal and Uterine Excitors 221
187. Garrigues's Intra-uterine Electrode 223

VULVA.

188. Hypospadias 248
189. Epispadias 249
190. Follicular Vulvitis 259
191. Epithelioma of Vulva 276
192. Lupus of Vulva 278

PERINEUM.

193. Garrigues-Vidal's Serrefines 295
194. Recent Tear of the Vaginal Entrance 298
195. Tait's Flap-splitting Operation for Incomplete Laceration of Perineum . . 300
196. Tait's Flap-splitting Operation for Complete Laceration of Perineum . . . 301
197. Diagrams illustrating Incisions and mode of Suturing in Tait's Operation . 302
198. Garrigues-Hegar's Colpoperineorrhaphy for Incomplete Laceration 304
199. Hegar's Colpoperineorraphy for Complete Laceration 306
200. Submucous Sutures 308
201. Emmet's Operation for Incomplete Laceration (Rectocele) 309
202. Emmet's Suture for Lifting Pelvic Floor 309
203. Cleveland's Suture 310
204. Diagram showing Retraction of Fibres after Rupture of Sphincter Ani Muscle 311
205. Sutures for Repair of Torn Sphincter Ani[1] 312
206. Diagram of Emmet's Operation for Complete Laceration of the Perineum . 312

VAGINA.

207. Vaginal Glass Plug 322
208. Sims's Operation for Cystocele 328
209. Stolz's Operation for Cystocele 329
210. Bozeman's Operating-Table 358
211. Bozeman's Speculum 358
212. Bozeman's Button 359
213. Walcher's Fistula Operation 361
214. Bandl's Operation for Ureterovaginal Fistula 364

FIG. PAGE
215. Pawlik's Operation for Incontinence 368
216. I. E. Taylor's Operation for Rectolabial Fistula 372

UTERUS.

217. Uterus Bicornis 377
218. Trachelorrhaphy 386
219. Dissecting Metritis 388
220. Hegar's Amputation of the Vaginal Portion 405
221. Simon's Conemantle-shaped Excision of the Vaginal Portion 406
222. Schroeder's Single-flap Excision of the Vaginal Portion 406
223. Hegar's Funnel-shaped Excision of the Supravaginal Cervix 414
224. Schroeder's Supravaginal Amputation of Cervix 415
225. Kaltenbach's Supravaginal Amputation of Cervix 416
226. Anteversion of the Uterus 420
227. Graily Hewitt's Cradle Pessary 421
228. Thomas's Anteversion Pessary 422
229. Thomas's Horseshoe-shaped Anteversion Pessary 422
230. Gehrung's Anteversion Pessary 422
231. Thomas's Modification of Cutter's Anteversion Pessary 422
232. Anteflexion 425
233. Intra-uterine Stem-Pessary 428
234. Retroflexion of the Uterus 430
235. Emmet-Hodge's Pessary 433
236. Thomas-Cutter's Retroflexion Pessary 434
237. Fowler's Pessary 434
238. Schücking's Needle for Vaginal Hysteropexy 437
239. Procidentia Uteri 441
240. Uterine and Abdominal Supporter 443
241. Lefort's Prolapse Operation 444
242, 243. Fritsch's Vaginal Hysterectomy for Prolapsus of Uterus 445, 446
244. Section of Extreme Inversion of Uterus 447
245. Pedunculated Submucous Fibrous Tumor (fibroid polypus) enclosed in the Uterus 455
246. Pedunculated Subperitoneal Fibroid 455
247. Intramural Fibroid 456
248. Thomas's Spoon-Saw 462
249. Long Pressure-forceps 467
250. Polk's Needle 467
251. Closing Peritoneal Flap of Fibroid adherent to Intestine 469
252. Schroeder-Hofmeier's Amputation of Uterus 472
253. Schroeder-Hofmeier's Treatment of the Stump after Amputation of the Uterus 473
254, 255. Zweifel's Continuous Sectional Ligature 474, 475
256, 257. Baer's Hysterectomy without Ligature of the Cervix 475, 476
258. Schroeder's Hysterectomy Needle 476
259. Garrigues's Transfusion Apparatus 482
260. Carcinoma of Cervix extending into Body 487
261. Bernay's Uterotractor 497

TUBES.

FIG. PAGE
262. Hypertrophy of Fallopian Tube due to Interstitial Salpingitis 505
263. Tube with Alternating Wide and Narrow Places Due to Salpingitis 506
264. Staffordshire Knot 514
265. Hydrosalpinx 521

OVARIES.

266. Hematoma of Ovary 531
267. Chronic Oöphoritis, the enlarged ovary filled with Minute Cysts 536
268. Ovary with Cystic Corpus Luteum 536
269. Ovary containing a Gyroma 540
270. Gyroma Magnified 541
271. Endothelioma (Jones) 542
272. Ovary with many Dropsical Follicles 544
273. Bilateral Oligocystic Ovarian Tumor 544
274. Rokitanski's Tumor 545
275. Ovaries with Pedunculated Cysts 546
276. Epithelial Pouches on the inside of a Glandular Ovarian Cystoma 547
277. Melting of Epithelial Cells by which the nucleus is set free and fluid formed 548
278. Small Glandular Ovarian Cystoma, with beginning absorption of partition between two cysts 549
279. Large Glandular Ovarian Cystoma, with numerous secondary cysts and remnants of absorbed partitions 549
280. Enormous Glandular Cystoma 550
281. Congenital Ovarian Cystoma 551
282. Excrescence on outer surface of Glandular Cystoma 551
283–296. Form-elements in Ovarian Cyst-fluid 552
283. Red Blood-corpuscles 552
284. Epithelial Cells 553
285. Bennett's Large Corpuscles, or Nunn's Gorged Corpuscles 553
286. Colloid Corpuscles 553
287. Horn-cells 554
288. Proliferating Cells 554
289. Ameboid Bodies 554
290. Large Bennett Corpuscle with Ameboid Movement 554
291. Bennett's Small Corpuscles, or Drysdale's Corpuscles 554
292. Cells with Nucleus and Fine Dark Granules 554
293. Flake of Epithelium, the cells melting and setting the nucleus free 554
294. Fat-granules 555
295. Spindle-cells from Myxofibromatous Ovarian Cyst 555
296. Cholesterin 555
297. Papillary Ovarian Cyst 555
298. Superficial Papillomas on both Ovaries 556
299. Dermoid Ovarian Cyst 557
300. Facies Ovariana 567
301. Percussion in Ascites and Ovarian Cyst 575
302. Warren's Ovariotomy Trocar 581
303. Emmet's Ovariotomy Trocar 587
304. Nélaton's Cyst-forceps 588

FIG. PAGE
305. Spencer Wells's Pedicle-forceps 588
306. Smith's Cautery-clamp 589
307. Wallich's Chain-ligature 599
308. Robert Sanderson's Method of Ligating Pedicle 600

PELVIS.

309. Diagram of the Structures in and adjacent to the Broad Ligament 619
310. Frost's Vaginal Syringe 646

INDEX.

A.

Abdominal hysterectomy, 500
  regions, 110
  section, 585
  wall, adherent to ovarian cyst, 591
Abortion, cause of disease, 128
Abortionist, 382
Abscess after ovariotomy, deep, 607
  mural, 607
  of vulvovaginal gland, 282
  ovarian, 533
Accessory abdominal ostia of Fallopian tubes, 502
Acid—
  carbolic, 200
  hydrocyanic, 204
Adenoma—
  benign, 395
  malignant, 395, 453
  uteri, 453
Adhesions—
  ovarian, 529, 561, 592
  severance of uterine, 439
  tearing of, 436
After-treatment, 216
  after ovariotomy, 590
  complications, 605
Air-pressure, 432
Ala vespertilionis, 26, 64
Albuginea, 27, 67
Alexander's operation, 435
Alimentation, rectal, 217
Ameboid bodies, 554
Amenorrhea, 229
  proper, 230
Ampulla of Fallopian tube, 63
  rectal, 85
Amputation of cervix, 405, 415, 416, 428
  of inverted uterus, 451
  supravaginal, of uterus. (See *Hysterectomy.*)
Anatomy, 35
Anæsthesia, 200
  in Trendelenburg's position, 203
Aneurysm of uterine artery, 616
Angioma of vulva, 274
Anodynes, 218
Anteflexion, 381, 424
  cervical, 425
  cervicocorporeal, 425
  corporeal, 424
  Dudley's operation for, 428
  irreducible, 425
  reducible, 425
  salpingo-oöphorectomy, 429
  Sims's operation, 428
Anteposition, 381
Anterior commissure, 36
Anteversion, 420
  operations for, 424
Antiblennorrhagic drugs, 339
Antidysmenorrheal drugs, 234
Antipyretics, 220
Antiseptic fluids, 199
  material, 195
Anus, preternatural, 370
Aperients, 217
Apostoli's method, 225
Applications, 165
Applicator, 166
Arbor vitæ, 49
Arteries—
  helicine, 60
  ligation of internal pudic, 180
  ligature of uterine, 177
  of perineal region, 105
  of uterus, 60
Artificial impregnation, 660
Ascites, 561, 570, 575, 603
Aspermatism, 654
Aspiration, 157, 185
  combined with galvanocauterization, injection, and drainage, 227
  exploratory, 157, 571
  through vaginal vault, 510, 571
Aspirator, 157, 158
Assistants, 191
Asthenopia, 396
Atresia—
  acquired—of uterus, 407
  acquired—of vagina, 320
  ani vaginalis, 324
  ani vestibularis, 324
  case of, 322
  hymenalis, 317

Atresia—
of urethra, 363
of uterus, 378, 407
of vagina, 319
combined with double vagina, 323
complete, 319
congenital, 319
incomplete, 319
Atrophy of uterus—
acquired, 417
puerperal, 417
senile, 417
Atropine injected subcutaneously before anesthetizing, 193
Auscultation, 156
Aveling, repositor, 450
Azoöspermatism, 654
Azoöspermia, 654
Azoöspermism, 654

B.

Baer, hysterectomy, 476
Baker, operation for carcinoma of uterus, 496
Ballooning, 144
Bandl, operation for ureterovaginal fistula, 364
Bardenheuer, hysterectomy, 467
Barnes, operation for inversion, 451
replacement of inverted uterus, 450
Barton, Rhea, operation for rectolabial fistula, 371
Base of bladder, 78
Baths, 183
general, 183
Russian, 184
sea-, 184
sheet-, 184
shower-, 184
sitz-, 183
sponge-, 184
steam-, 184
towel-, 184
Turkish, 184
Battey's operation, 512
Bed, 190
Bed-pan, 167
Belt, abdominal, 186
Bernay's uterotractor, 497
Bichloride of mercury for injection, 199
internally, 218
Bimanual examination, 139
replacement of uterus, 432
Bipolar electrodes, 221
Bisulphide of carbon, 656
Bladder—
adherent to tumors, 468, 591
anatomy, 77
Bladder—
distention, 578
function, 81
irrigator, 170
irritable, 396, 400
Blasius, operation for fistula, 359
Blind canals in vagina, 324
Blister, 185
Bloodletting, 182
Blood-pressure increased before menstruation, 116
Bodies, ameboid, 554
Body, perineal, 104
of womb, 47
Boldt, table, 190
Bougies with iodoform, 394
Bozeman—
button, 359
operation for fistula, 358
speculum, 358
table, 358
urinal, 368
Brandt, Thure, 188
cure for prolapse, 442
Breisky, pessary, 442
Broad ligament—
cysts of, 618
diseases of, 617
during pregnancy, 57
varicocele, 617
Broca's pouch, 37
Bubo, 285
Burning sensation in genitals and abdomen, 266
Button, Bozeman's, 359
Byrne, inversion, 451
carcinoma uteri, 495

C.

Calcification of ovarian cysts, 562
Camphor in collapse, 204
emulsion, 342
Canal of Nuck, 37, 59, 616
Canals, blind, in vagina, 324
hematocele of, 255
carried through lymph-vessels, 613
Cancer—
definition, 483
of Fallopian tubes, 523
of peritoneum, 576
of vulva, 275. (See *Carcinoma* and *Sarcoma*.)
Cancer-cells in ascitic fluid accompanying malignant tumors, 492
Capsule of fibroid tumors, 454
Carbolic-acid wash, 285
Carbon bisulphide, 657
Carcinoma of body of uterus, 487

Carcinoma—
cervical, 486
in negro race, 489
not transmissible by coition, 490
of Fallopian tube, 523
of ovarian cysts, 552, 562
of ovary, 612
of pelvis, 651
of uterus, 486
of vagina, 352
of vaginal portion, 486
of vulva, 275
Caruncle, urethral, 274
Carunculæ myrtiformes, 47
Catamenia, 114
Catarrh of uterus, 397
of vagina, 335
Catgut, 197
buried, 305
chromicized, 199
Catheter, double-current, 171
Catheterization of bladder, 159
of Fallopian tube, 510
of ureters, 161
Cauliflower excrescence, 486
Cauterization, 177
of fistula, 356, 371
galvanochemical, 224, 226
galvanothermal, 227
hemostatic, 177, 602
Cautery-clamp, 589
Cavity, pelviperitoneal, 94
of uterus, 49
Celibacy in relation to disease, 127
in relation to uterine fibroid, 458
"Celiotomy," 585
Cells, proliferating, 551
Cellulitis, 572
anterior, 645
chronic atrophic, 647
posterior, 645
Cervical canal, 49
carcinoma, 486
ganglion, 62
stenosis, 381
Cervicitis, 390
Cervix, 47
amputation, 405, 428
cone-mantle-shaped excision, 406
conical, 408
cysts, 401, 453
discission of posterior lip, 428
elongated, 381, 411
funnel-shaped excision, 414
high amputation, 415
laceration, 383
single-flap excision, 407
stenosis, 381, 408
supravaginal amputation, 415, 416
Cervix—
ulcers, 410
wedge-shaped excision, 405
for retroflexion, 435
Chain-ligature, 600
Chancre, 285
hard, 285
mixed, 286
Chancroid, 283
chronic, 277, 284
Change of life, 121
Charts, 157
Chian turpentine, 495
Childbirth, cause of disease, 128
Chloride of zinc, 166
for cauterizing carcinoma of uterus, 493
Chloroform, 202
embrocation, 218
mask, 202
Cholesterin, 555
Chroback, hysterectomy, 477
Cicatrices in vagina, 344
Circular artery, 60
Cirrhosis of ovary, 534
Clamp, Koeberlé's, 180
Cleanliness, 138
a cure for fistula, 355, 371
Cleisis, 367
Cleveland, suture, 310
table, 190
Climacteric, 121
treatment, 123
Clitoris, abnorm, 248
absent, 248
anatomy, 87
enchondroma, 273
function, 39
horn, 274
Cloaca, persistent, 324
Cloacal opening, 33
Closure of uterus, 407
Clover's crutch, 193
Clysters, 169
Coalescence of labia, 250
Cocaine, 203
bougies, 346
Coccygodynia, 314
Coe, improvement of Lefort's operation, 443
preventive excision of cervix, 496
Coffee against vomiting, 204
Coition during menstruation, 128
modo brutorum, 658
Colica scortorum, 506
Collapse, 201, 204, 481
Collector, 224
Colpeurynter, 450, 513
Colpitis, 334

[illegible]
[illegible] of cervix,
[illegible] 33
[illegible] and husband necessary
[illegible] 312
[illegible] of arresting vomiting,
[illegible]
[illegible] of clitoris, 38
[illegible] 537
[illegible] 536
[illegible] 540
[illegible] 70
[illegible] 71, 541
[illegible]
[illegible] 553
[illegible]
[illegible] of cervix, 411
[illegible] from rodent ulcer, 491
[illegible] of ovary, 67
[illegible] 177
[illegible] 184
[illegible] hook, 211
[illegible] 451
[illegible] 200
[illegible] 38
[illegible] 172
[illegible]

Curette—
  Thomas's dull-wire, 152
Curetting, 171
  for uterine fibroids, 465
Current—
  constant, 224
  interrupted, 224
Cutter's anteversion pessary, 422
  retroflexion pessary, 434
Cyst of abdominal wall, 577
  of broad ligament, 573, 576, 618
  of cervix, 401, 453
  of Fallopian tube, 523
  of liver, 576
  of mesentery, 577
  of omentum, 571
  of pancreas, 577
  of spleen, 577
  of vagina, 348
  of vulva, 275
  of vulvovaginal gland, 281
  ovarian, 543
  parovarian, 618
  renal, 576
  tubo-ovarian, 557
Cystocarcinoma of ovary, 613
Cystocele, 326
Cystoma of ovary—
    dermoid, 557
    glandular, 548
    myxoid, 547
    papillary, 548, 556
Cystopexy, 330
Cystosarcoma of uterus, 484
Cystoscope, 150
Czerny—
  ventrofixation, 439

D.

Death after hysterectomy, 481
  after ovariotomy, 609
Decidual sarcoma, 486
Depressor—
  Garrigues's, 147
  Hunter's, 145
  Sims's, 145
  vaginal, 145
Dermoid cysts, 557
  outside of ovary, 559
Descent of ovary, 23
  of uterus, 440
Detrusor of rectum, 87
Development of the female genitals, 19
Diet—
  after operations, 216
  fluid, 216
  for reducing fat, 659
Digital pressure for replacing uterus, 432

Digitalis for reviving, 204
Dilatation of cervical canal, 152, 180, 181
of urethra, 140
of uterus, 154
Dilator—
Garrigues's, 153
Hanks's, 153, 154
Outerbridge's, 181
Discus proligerus, 28, 69
Disease, gelatinous, of peritoneum, 563
Diseases—
of broad ligament, 617
of Fallopian tubes, 502
of ovaries, 525
of pelvis, 616
of perineum, 293
of uterus, 375
of vagina, 317
of vulva, 247
Disinfection, 195
internal, 373
of laminaria tents, 152
Displacement of Fallopian tube, 522
of ovary, 526
of uterus, 419
Distribution of organs between perineal fasciæ, 108
Douche-can, 167
Douglas's pouch, 91
prolapse of intestine into, 326
Drainage—
abdominal, 176, 182, 603
after ovariotomy, 603
of uterus, 175, 181
through cervical canal after hysterectomy, 477
vaginal, 604
-tube, 182
Dress, 126
Drink, 216
Dropsy of Graafian follicle, 543
Dudley, E. C.—
operation for anteflexion, 428
Dysmenorrhea, 233
membranous, 233, 402
obstructive, 408
Dyspareunia, 120
Dyspepsia, 217

E.

Echinococci, 651
Ectropium, 383, 394
Edebohls, table, 190
Edema of abdominal wall, 577
indurating, 277
in lacerated perineum, 297
Education, 125
Elastic ligature, how to tie, 470
Elastic pressure, 450
Electricity—
Apostoli's method, 225
bipolar electrodes, 221
chemical, 222
chemical galvanocauterization of cervix, 226
different qualities of poles, 225
frictional, 220
high-tension coils, 221
inductional, 221
molecular movement 224
Electrode—
aluminium, 223
Apostoli's, 222, 223
bipolar, 221
Buckmaster's, 223
Engelmann's, 222
Fry's, 410
Garrigues's, 223
gas-carbon, 223, 224
Martin's, 222
platinum, 223
Electrolysis, 224
for stenosis of cervix, 410
Elephantiasis of vulva, 271
Elevation of uterus, 446
Elytritis, 334
Emmenagogues, 231
Emmet, Bache, trocar-forceps, 639
Emmet, T. A.—
inversion, 451
needle-holder, 208
operation for fecal fistula, 372
for lacerated cervix, 386
for uterine fibroid, 466
perineorrhaphy, 308, 311
pessary, 433
trocar, 587
Emphysema, 607
Ems, 184
Enchondroma of clitoris, 273
of uterus, 500
Encysted peritonitic exudation, 575
Endocervicitis, 390
Endometritis, 390
atrophying, 396
catarrhal, 394
chronic, 394
decidual, 396
exfoliating, 402
fungous, 395
hemorrhagic, 396
hyperplastic, 395
menstrual, 402
Endosalpingitis, 503
Endothelioma (Ackermann) of ovary, 61
(Jones) of ovary, 539, 541
Enemas, 169

Enterocele, vaginal, [illegible]
Enucleation—
  abdominal, [illegible]
  from broad ligament, [illegible]
  from pelvic floor, [illegible]
  from uterus, [illegible]
  Miller's method, [illegible]
  of uterine fibroids, [illegible]
  vaginal, [illegible]
Epididymis, [illegible]
Epidiodesis, [illegible]
Epidiadias, [illegible]
Epithelial malescence of vulva, [illegible]
Epithelioma of vulva, [illegible]
Erection, [illegible]
  of internal genitals, [illegible]
Ergot hypodermically for fibroids, 463
Erosions, [illegible]
Erysipelas of vagina, 344
Esthiomene, [illegible]
Ether, [illegible]
Etiology in general, 125
Examination, [illegible]
  chemical, [illegible]
  combined, [illegible], 140
  digital, [illegible]
  for sterility, [illegible]
  in regard to operations, 192
  intestinal, 140
  microscopical, 159
  of abdomen, [illegible]
  of pelvis, [illegible]
  of ureters, [illegible]
  of urine, [illegible]
  of uterine appendages, [illegible]
  of virgins, [illegible]
  physical, [illegible]
  rectal, [illegible]
  under anaesthesia, [illegible]
  vaginal, [illegible]
  verbal, [illegible]
  vesical, 140
Exanthematous diseases, [illegible]
Excitors—
  bipolar uterine and vaginal, 221
Excretions, 125
Exercise, 125
Exploratory aspiration, 157, 571
  incision, 157, 572
  laparotomy, 511
  puncture, 571
Extraperitoneal shortening of the round ligament, [illegible]
Extra-uterine pregnancy, 573

F.

Facies ovariana, 567
Falling of the womb, 440
Fallopian tubes—
  absence of, 502
  anatomy, [illegible]
  cancer, [illegible]
  carcinoma, [illegible]
  catheterization of, 510
  cysts, [illegible]
  development, [illegible]
  diseases of, 502
  displacement, [illegible]
  examination of, 508
  fibroma, [illegible]
  functions, [illegible]
  lipoma, [illegible]
  malformation, 502
  neoplasms, [illegible]
  palpation, [illegible]
  papilloma, 523
  relation of to menstruation, 117, [illegible]
  sarcoma, [illegible]
  tuberculosis, 523
Faradism, 221
Fascia—
  anal, 95
  deep perineal, 100
  distribution of organs between perineal fasciae, 10[illegible]
  obturator, 94
  perineal, 100
  pelvic, 94
  pyriformis, 94
  superficial perineal, 100
  vesico-rectal, 94
Fat—
  preperitoneal, 93
  retro-pubic, 93
  granules in ovarian cysts, 555
Fecal fistula after ovariotomy, 608
Feces, impacted, 575
Fecundation, 120
Fertilization, 120
Fibrocyst of ovary, 610
  of uterus, 457
    diagnosis, 574
    treatment, 482
Fibroid—
  uterine, 454, 573
    diagnosis from ovarian cyst, 574
  of vagina, 350
Fibroma—
  molluscum, 273
  of Fallopian tube, 523
  of ovary, 609
  of round ligament, 256
  of uterus, 454
  of vagina, 350
  of vulva, 272
    case of pedunculated, 273

Fibromyoma of uterus, 454
of vagina, 350
Fibrosarcoma of ovary, 611
Fimbria ovarica, 63
Fimbriæ—
anatomy, 63
development, 30
Fistula, 353
artificial vesicovaginal, 159
Bandl's method, 364
Blasius's method, 359
Bozeman's method, 358
combination of methods, 362
congenital rectovaginal, 325
denudation, 357
enterovaginal, 369, 374
fecal, 369, 608
flap-splitting methods, 357, 359
ileo-uterine, 369
ileovaginal, 369
Pozzi's method, 365
produced by coition, 257
rectolabial, 369
rectovaginal, 369
rectovulvar, 257, 369
Schede's method, 365
Simon's method, 359
Sims's method, 357
suprapubic method, 359
uretero-uterine, 366
ureterovaginal, 361, 363
ureterovesicovaginal, 366
urethrovaginal, 363
urinary, 354
uterovaginal, 384
vesico-uterine, 366
vesicovaginal, 354
Walcher's method, 360
Fistulous tract, 607
Flap-operation for atresia, 322
Flap-sliding method, 372
Flap-splitting perineorrhaphy, 299
Flatus vaginalis, 314
Fluid in cysts of broad ligament, 619
in ovarian cysts, 546, 552, 559, 571
in uterine fibro-cysts, 457
Fluids, antiseptic, 199
Foerster, table, 190
Fœtus in fœtu, 564
Fomentation, 183
Food, 126, 216
Forceps—
artery-, 180
dressing-, 148
intra-uterine packing-, 176
Nélaton's, 588
pedicle-, 588
pressure-, 207, 467
tenaculum-, 206
Forceps—
tissue-, 206
Forcipressure, 180
used in hysterectomy, 497
Foreign bodies in uterus, 390
in vagina, 333
Fornix of vagina, 42
Fossa—
ischiorectal, 101
navicularis, 40
Fourchette, 36
Fowler, pessary, 434
Franklinism, 220
Franzensbad, 184
Frenulum of clitoris, 37
Freund, hysterectomy, 500
Fritsch, enucleation, 479
hysterectomy for prolapse, 446
operation for fecal fistula, 372
Frost, vaginal syringe, 646
Fry, electrode, 410
Fundus of bladder, 78
of uterus, 47
Fusion of ovarian cysts, 561

G.

Gall-bladder, torn in ovariotomy, 593
Galvanism, 222
combined with aspiration, injection, and drainage, 227
Galvanocauterization—
chemical, 224, 226, 464
for carcinoma of uterus, 495
thermal, 227
Galvanochemical cauterization for uterine fibroids, 464
Galvanopuncture, 226
Ganglion, cervical, 62
Gangrene of uterus, 418
of vagina, 343
of vulva, 262
Gariel, air-pessary, 442
Garrigues, apparatus for transfusion, 482
colpoperineorrhaphy, 304
intra-uterine electrode, 223
intra-uterine packing-forceps, 176
perineal pad, 296
serrefines, 295
Garrulity of vulva, 314
Gärtner's canal, 20
Gas artificially developed in stomach, 156
Gauze balls, 196
pads, 169
sponges, 196
Gehrung, combined aspiration, galvanocauterization, injection, and drainage, 227

Gehrung—
pessary, 422
Gelatinous disease of peritoneum, 563
Genital cleisis, 367
cord, 31
corpuscles, 29
folds, 33
furrow, 34
tubercle, 33
Genitals—
external, 35
internal, 35
Geode, 457
Germ-epithelium, 28
Germinal spot, 70
vesicle, 70
Gestation, incapacity for, 656
Glands—
Bartholin's, 40
coccygeal, 103
Littre's, 76
mammary, 113
of vagina, 44
Skene's, 76
utricular, 50
vulvo-vaginal, 40
Glandulæ vestibulares majores, 41
vestibulares minores, 39
Glass plug for vagina, 321
Glycerin—
tampon, 173
wash, 185
Glycerite of tannin, 173
Goffe, hysterectomy, 478
Gold, 218
Goltz's experiment, 605
Gonococcus, 335, 337
Gonorrhea, 283
danger of, 129
latent, 129, 654
Gordon, excision of cervix, 405
operation for chronic metritis, 405
Gossypii radicis cortex, 219
Graafian follicles—
anatomy, 67, 68
development, 26
dropsy, 543
Granular os, 395
Greenhalgh's metrotome, 409
Gymnastics, 188
Gynecological treatment, cause of disease, 129
Gyroma, 539

H.

Hagedorn, needles, 207
needle-holder, 208
Hanks, dilators, 153, 154
Hanks—
needle-holder, 208
Heart, artificial contraction, 201
examination in regard to operation, 192
Heat, 183
Heels, 126
Hegar, amputation of cervical portion, 405
colpoperineorraphy, 303, 306
extraperitoneal treatment of pedicle, 470
funnel-shaped excision of cervix, 414
operation for chronic metritis, 405
operation for fecal fistula, 373
sacral hysterectomy, 499
Helicine arteries, 60
Hematocele, 573
of the canal of Nuck, 255
Hematocolpos, 317
Hematoma of broad ligament, 573
of ovary, 530
of round ligament, 255
of vulva, 268
Hematometra, 317, 376, 408
Hematosalpinx, 317, 503, 521
Hemorrhage at climacteric, 124
from torn hymen, 332
in hysterectomy, 481
in ovarian cysts, 561, 569
in perineal region, 106
internal, after ovariotomy, 605
Hemostasis, 176
after ovariotomy, 602
Hemostatic drugs, 218
vaginal plug, 174
Heredity, 125
Hermaphrodism, 250
Hermaphroditism, 250
Hernia—
anterior labial, 252
crural of ovary, 527
inguinal of ovary, 526
inguinolabial, 252
posterior labial, 253
umbilical, complicating ovarian cyst, 603
uteri, 381, 452
vaginal, 325
vaginolabial, 253
Herpes progenitalis, 263
Hewitt, cradle pessary, 422
High-tension current, 221
Hilum, 66
Hodge, pessary, 433
Hofmeier, enucleation, 479
hysterectomy, 472
Horn of clitoris, 274
Horns of uterus, 31

Horn-cells, 554
Hot water, 177
Hottentot apron, 37
Houston's valves, 87
Hydatid of liver, 576
  of Morgagni, 30, 502
  of pelvis, 651
Hydramnion, diagnosis from ovarian cyst, 574
Hydrobromate of hyoscine, 218
Hydrocele, 254
  of ovary, 559
    intermittent, 503, 560
Hydrometra, 123, 379, 408, 574
Hydronaphthol, 200
Hydronephrosis, 576
Hydrops folliculi, 543
  tubæ profluens, 503, 560
Hydrorrhea, 397
  puerperal, 397
  gravidarum, 397
Hydrosalpinx, 503, 520, 573, 577
Hydrotherapy, 184
Hygroma, 316
Hymen—
  abnormal openings in, 317
  absent, 317
  anatomy, 46
  bifenestratus, 319
  biforis, 319
  cribriformis, 319
  development, 33
  double, 319
  fleshy, 319
  hemorrhage from torn, 332
  malformations, 317
  septus, 319
  subseptus, 319
Hyperæsthesia of vulva, 267
Hyperemia of ovaries, 530
  of pelvis, 125
Hyperplasia of vulva, 267, 277
Hypertrophy of uterus, 411
    infravaginal, 411
    supravaginal, 413
Hypnotics, 218
Hypospadias, 247
Hysteralgia, 418
Hysterectomy, 500
  abdominal, 417, 466
  Baer's method, 476
  Bardenheuer's method, 467
  causes of death, 481
  Chroback's method, 477
  extraperitoneal treatment of pedicle, 470
  for carcinoma uteri, 496
  for supravaginal hypertrophy of cervix, 417
Hysterectomy—
  Goffe's method, 478
  intraperitoneal treatment of pedicle, 471
  laparovaginal, 500
  Martin's method, 468
  mortality, 480
  Outerbridge's expander, 478
  perineal, 499
  Polk's method, 468
  retroperitoneal treatment of pedicle, 478
  sacral, 499
  Schroeder-Hofmeier's method, 472
  Treub's method, 471
  vaginal, 417, 444, 496
  with ligatures, 498
  with pressure-forceps, 497
  Zweifel's method, 473
Hysterocele, 452
Hysterocleisis, 367
Hysteropexy, 437
  abdominal, 438
  vaginal, 437
Hysterotrachelorrhaphy, 386

I.

Ice-bag, 183
Ichthyol glycerin, 173
Impotence, 654
Impregnation, artificial, 660
Incision, exploratory, 157, 572
  of vaginal vault, 511
Incontinence of urine, operation for, 330, 368
Incubation, 286
Indurating edema of syphilis, 277
Induration, absent, 286
Inhaler—
  Allis's, 201
  Esmarch's, 202
  Ormsby's, 202
Injections, 166
  antiseptic, 168
  astringent, 167
  cleansing, 167
  emollient, 168
  hot-water, 177
  intestinal, for diagnosis, 156
  intraperitoneal, 171
  intra-uterine, 168
  intravenous, 171
  rectal, 169
  subcutaneous, of hot water, 171
  vaginal, 166
  vesical, 170
Injuries of body of uterus, 381
  of cervix, 383

Injuries—
of intestine, 592
of perineum, 293
of uterus, 381
of vagina, 332
of vulva, 257
Inspection of abdomen, 155
of genitals, 137
Instruments—
how to clean, 215
selection, 215
those needed in all operations, 204
Intermenstrual pain, 404
Intermittent hydrocele of ovary, 503
Intestinal obstruction, 482, 570, 606
Intestine—
adherent to tumors, 469, 592
injury during ovariotomy, 593
laid on abdominal wall, 513, 595, 602
Invagination, 564
Inversion—
instrumental replacement, 451
manual replacement, 451
of uterus, 446
of vagina, 331
operations for, 451
partial, 446
total, 446
Iodoform, 199
bougies, 394
ointment, 173
suppositories, 218
Iodol, 210
Iron contraindicated in uterine hemorrhage, 220
Irrigation with hot antiseptic solutions, 177, 215
Irrigator for bladder, 170
Irritable bladder, 396, 400
vascular excrescence of urethra, 274
Isthmus of Fallopian tube, 63
of uterus, 49

J.

Jay, urinal, 368

K.

Kaltenbach, supravaginal amputation of cervix, 416
ventrofixation, 439
Kelly, rubber cushions, 191
ventrofixation, 438
Keith's opinion about Apostoli's method, 464
Kidney—
extirpation, 594
floating, 576
Knife, uterine, 409
Knot, Staffordshire, 514
Koenig's method of reviving, 201
Kraske, hysterectomy, 499
Kraurosis vulvæ, 280
Kreuznach, 184
Krug, apparatus for Trendelenburg's position, 191
Küchenmeister's scissors, 409
Küstner, flap-operation for atresia, 322

L.

Labia majora—
abnorm, 250
anatomy, 36
function, 37
Labia minora—
abnorm, 250
anatomy, 37
function, 37
Labor, ovarian cyst during, 603
Laceration of cervix, 383
of perineum, 293
complete, 294, 297, 302, 306, 311
incomplete, 294, 295, 299, 303, 308
intermediate operation, 299
primary operation, 295
secondary operation, 299
of vaginal entrance, 297
Lack of orgasm, 659
Laminaria, disinfection of, 152
Lamp, electric, 603
Laparotomy, 585
for sterility, 660
Laparovaginal hysterectomy, 500
Late hours, 127
Lateroflexion, 381, 440
Lateroposition, 381
Lateroversion, 381, 440
Leech, artificial, 182
Leeches, 182
Lefort's operation, 442
Leg-holder, 193
Leggings, 193
Leopold, ventrofixation, 438
apparatus for Trendelenburg's position, 137, 190
Leptothrix vaginalis, 340
Leucorrhea, 241
in phthisis, 243
Ligaments—
broad, 56, 617
infundibulopelvic, 25, 64
ischioperineal, 101
of bladder, 80
anterior true, 80, 95
false, 80
lateral false, 80

Ligaments—
lateral true, 80, 95
posterior false, 80
superior false, 80
suspensory, 80
true, 80
vesico-uterine, 55, 80
of ovary, anatomy, 66
development, 22
of rectum, 96
of uterus, 54
perineal, 100
pubovesical, 95
round, 58
sacro-uterine, 55
subpubic, 100
superior round, 57
suspensory, of clitoris, 38
transverse, of pelvis, 100
triangular, of urethra, 100
vesico-uterine, 55, 80
Ligamentum suspensorium of bladder, 80
Ligature—
chain-, 600
continuous sectional, 473
elastic, 209, 470
for fecal fistula, 371
in ovariotomy, 602
mass-, 177
material, 209
of arteries, 177
of internal pudic artery, 180
of uterine artery, 177
-box, 196
Lipoma of Fallopian tube, 523
of vulva, 273
Lips of cervical portion, 48
Liquor ferri chloridi, 175
folliculi, 28, 70
Liver adhesions, 593
floating, 576
Lotion to be used with tincture of iodine, 185
Lubricant, 138
Lungs, examination in regard to operations, 192
Lupus of vulva, 277
Lymphadenitis, pelvic, 648
Lymphangitis, pelvic, 648
Lymphatics of perineal region, 107
of uterus, 62

M.

Malformations of Fallopian tubes, 502
of hymen, 317
of ovaries, 525
of pelvic peritoneum, 616
of uterus, 375
Malformations—
of vagina, 317, 319
of vulva, 247
Malignant tumor diagnosticated by cancer-cells in ascitic fluid, 492
Malposition of uterus, 381
Mammary gland, normal development simulating tumor, 113
Manual replacement of inverted uterus, 451
Marienbad, 184
Marriage as a cure, 235
in relation to disease, 127
Marsupialization, 598
Martin, A., enucleation, 479
hysterectomy, 468
Martin, F. H., electrode, 222
Massage, 187
for adhesions, 437
Masturbation, 289
Mayer's pessary, 442
Mayhem, 512
Meatus urinarius, 39
Medullary substance of ovary, 67
Membrana granulosa, 28, 69
Menopause, 121
Menorrhagia, 236
Menses, 114
suppression of, 229
Menstrual disorders, 238
period, 114
Menstruation, 114
abnormal, 229
influence of operations, 118, 515
neglect during, 127
operations during, 189
precocious, 235
scanty, 232
supplementary, 232
tardy, 236
theory of, 119
vicarious, 232
Mensuration, 156
Mental aberration after ovariotomy, 608
Mesentery, adhesions, 593
Mesoarium, 23
Mesorchium, 23
Mesorectum, 86
Mesosalpinx, 25, 64
Metastasis from ovarian cysts, 562
from uterine carcinoma, 488, 490
Methyl blue, 495
Metritis, 390
acute, 390
chronic, 394
parenchymatous, 403
diphtheritic, 393
dissecting, 393
gonorrheal, 392

Metritis—
operations for, 405
parenchymatous, 390
Metrorrhagia, 238
Metrotome, Greenhalgh's, 409
Simpson's, 409
Mikulicz, abdominal tamponade, 176
Milliampèremeter, 224
Miner, enucleation, 596
Mirror, concave, for throwing light into abdominal cavity, 603
Mitchell's rest-cure, 217
Molecules moved by electric current, 224
Mons Veneris—
anatomy, 35
function, 35
Monsel's solution in ovariotomy, 602
Monthly flow, 114
sickness, 114
Morgagni, hydatid of, 502
lacunæ of, 76
Morphine injected subcutaneously before anesthetizing, 193, 202
Müllerian duct, 29
Muscles—
bulbocavernosus, 102
coccygeus, 97
constrictor urethræ, 103
vaginæ, 104
deep transversus perinæi, 104
depressor urethræ, 103
detrusor recti, 87
external sphincter ani, 87
Guthrie's, 103
internal sphincter ani, 87
ischiocavernosus, 102
ischiococcygeus, 97
Jarjavay's, 103
levator ani, 97
obturatococcygeus, 97
perineal, 102
pubococcygeus, 97
superficial transversus perinæi, 103
third sphincter of rectum, 87
transversus urethræ, 103
Myofibroma of uterus, 454
of vagina, 350
Myoma, cavernous, of uterus, 454
complicating ovarian cyst, 603
lymphangiectodes, 454
of uterus, 454
of vagina, 350
of vulva, 273
teleangiectodes, 454
Myxoid cystoma, 547
Myxoma of vulva, 273
Myxosarcoma of ovary, 611
of uterus, 483

N.

Naboth, ovula, 395, 398
Neck of womb, 47
Needles, 207
handled, 209
perineum, 209
Polk's, 467
Schroeder's, 476
Needle-holder—
Emmet's, 208
Hagedorn's, 208
Hanks's, 208
Sims's, 208
Neglect of skin, 125
Negro, carcinoma, 489
uterine fibroid, 458
Nélaton, cyst-forceps, 588
Neoplasms of Fallopian tubes, 522
of ovary, 543
of uterus, 453
of vagina, 348
Nerves of perineal region, 107
Neuralgia—
lumbo-abdominal, 398
of uterus, 418
Neuroma of vulva, 274
Noeggerath, inversion, 451
latent gonorrhea, 129
Nozzle with stopcock, 195
Nubility, 113
Nuck, canal of, 37, 59, 255, 616
Nunn's gorged corpuscles, 553
Nussbaum, suprapubic urethra, 367
Nymphæ, anatomy, 37
progressive atrophy, 280

O.

Obliquity of uterus, 381
Occlusion dressing, 296
Oïdium albicans, 340
Ointment-carrier, 166
Olshausen, ventrofixation, 438
Omentum adherent to tumors, 469, 593
Oöphoralgia, 614
Oöphorectomy for atresia, 323
for uterine fibroids, 466. (See *Salpingo-oöphorectomy.*)
Oöphoritis, 533
acute, 533
chronic, 535
follicular, 533
interfollicular, 533
transition to cyst, 536
Oozing tumor, 270
Operating-room, 190
Operating-table, 190
Boldt's, 190

Operating-table—
Bozeman's, 358
Cleveland's, 190
Edebohls's, 190
Foerster's, 190
Lapthorn Smith's, 191
Operations—
assistants, 191
combined, 215
diet after, 216
disinfection, 195
during hot season, 188
during lactation, 189
during menstruation, 189
during pregnancy, 188
in general, 188
instruments which are used in nearly all, 204
preparation for, 190
preparation of patient, 192
room, 190
rubber cushions, 191
spectators, 192
table for, 190
time of day for, 189
vessels needed, 194
Opium suppositories, 218
Organ of Giraldez, 22
Orgasm, 120
lack of, 659
Os externum, 48
granular, 395
internum, 49
pinhole, 408
tincæ, 48
uteri, 48
Ossification of ovarian cysts, 562
Ostium abdominale of Fallopian tube, 63
accessory abdominal of Fallopian tube, 502
uterinum of Fallopian tube, 63
Outerbridge, instrument for uterine dilatation and drainage, 181
instrument used in hysterectomy, 478
Ova, absence of, 656
Ovarian abscess, 533
Ovarian cyst—
adherent everywhere, 594
adhesions, 561, 592, 594
ascites, 570
blood-corpuscles in fluid, 552
calcification, 562
cancerous degeneration, 552, 562
cholesterin in, 555
complicated with labor, 603
complications, 578, 603
congenital, 550
contents, 552, 559
Ovarian cyst—
cut off blood-supply from, 598
dermoid, 557
diagnostic value of examination of fluid, 571
differential diagnosis, 572
epithelial cells in fluid, 553
etiology, 564
explorative incision, 572
puncture, 571
extraperitoneal, 561
diagnosis, 578
fluid, 546, 552, 559, 571
fusion, 561
glandular, 548
hemorrhage, 561, 569
in mesentery, 596
inflammation, 569
intestinal obstruction, 570
intraligamentous, 561, 595
irremovable, with colloid contents, 594
metastasis, 562
mixed proliferating, 557
multilocular, 550
myxoid, 547
origin, 563
originating in chronic oöphoritis, 536
in corpus luteum, 536
ossification, 562
papillary, 556
relation to carcinoma, 552
part of, imbedded in pedicle, 596
pedicle, 560, 600
peritonitis, 570
prognosis, 579
proliferating, 547
pseudo-intraligamentous, 597
relation to carcinoma, 552
retroperitoneal, 561
rupture, 562, 569
spindle-cells in fluid of, 555
suppuration, 562, 569
symptoms, 564
torsion of pedicle, 560, 569
treatment, 579
tubo-ovarian, 559
unilocular, 550
wall, 546, 550, 558
with pregnancy, 579
Ovarian tumor—
oligocystic, 545
solid, 573
Ovaries—
abscess, 533
absence, 525
alternate swelling at menstruation, 119
anatomy, 65
carcinoma, 612

Ovisacs, 67
Ovum—
anatomy, 70
development, 26
expulsion, 74, 117
primordial, 28
Ox-gall, 169

P.

Pachydermia of vulva, 271
Pachysalpingitis, 503
Pack, hot, 184
Packings, vaginal, 173
Pad, perineal, 296
Pain, 132
intermenstrual, 404
Palmæ plicatæ, 49
Palpation of abdomen, 155
of ureters, 163
Papilloma—
growing from ovarian cyst into other organs, 597
in ovarian cysts, 556
of Fallopian tubes, 523
of uterus, 500
of vulva, 269
on outer surface of myxoid proliferating cystoma of ovary, 551
on outer surface of ovary, 557, 611
Paquelin, thermocautery, 177
Parametric connective tissue, 56
Parametrium, 56
Parenchymatous zone of ovary, 67
Paring, 206
Parotitis after ovariotomy, 608
Parovarian varicocele, 617
Parovarium—
anatomy, 74
development, 22
Partitioning the vagina, 442
Parturition—
pelvic floor during, 110
results in regard to pelvic floor, 110
Patients, preparation of, for operations, 192
Pawlik, catheterization of ureter, 161
operation for incontinence, 368
Péan's position, 585
Pectiniform septum, 38
Pedicle of ovarian cyst—
composition, 560
ligation, 588, 600
torsion of, 561, 569
Pelvic carcinoma, 651
Pelvic diaphragm—
anatomy, 97
function, 97
Pelvic floor—
anatomy, 94

Pelvic floor—
during parturition, 110
entire displaceable portion, 109
entire fixed portion, 109
functions, 110
projection, 105
pubic segment, 108
results from parturition, 110
sacral segment, 108
sarcoma, 651
structural anatomy, 108
Pelvic lymphadenitis, 648
Pelvic lymphangitis, 648
Pelvic phlebitis, 648
Pelvis—
adhesions in, 593
diseases of, 616
malformations of, 616
three spaces of, 94
Penis captivus, 346
Percussion, 156
Perineal body, 104
cystic hygroma, 316
hysterectomy, 499
pad, 296
Perineorrhaphy—
after-treatment, 313
Cleveland's, 310
for retroflexion, 434
intermediate, 299
preparation for, 313
primary, 295
secondary, 299
Perineum—
complete laceration, 297
development, 31
diseases, 293
incomplete laceration, 294
injuries, 293
old lacerations, 299
recent lacerations, 293
Perioöphoritis, 533
Perisalpingitis, 503
Peritoneum—
function, 92
gelatinous disease, 563
pelvic, 90
pseudomyxoma of, 563
taken for ovarian cyst-wall, 591
toilet, 601
Peritonitis—
diagnosis from ovarian cyst, 572
septic, 606
with ovarian cyst, 570
Pessary—
after ventrofixation, 440
Breisky's, 442
Cutter's anteflexion, 422
Cutter's retroflexion, 434
Pessary—
Emmet's, 433
Fowler's, 434
Gariel's, 442
Gehrung's, 422
general remarks, 422
Hewitt's cradle, 421
Hodge's, 433
Mayer's, 442
retroflexion, 433
stem-, 428
Thomas's anteversion, 422
Thomas's retroflexion, 434
whalebone, 434
Phagedena, 284
Phantom tumor, 578
Phlebitis—
after ovariotomy, 608
pelvic, 648
Physiology, 113
Physometra, 123, 379, 574
Pilimiction, 558
Pinhole os, 408
Pinworms, 265
Pistol, E. Martin's, 166
Platysma, 57
Pledgets. vaginal, 173
Plicæ palmatæ, 49
Plombières, 184
Plug, vaginal, 174
Polk, hysterectomy, 468
needle for hysterectomy, 467
shortening of round ligaments, 440
Polypus—
fibrinous, 454
fibroid, uterine, 455
fibroid, vaginal, 350
glandular, 453
hollow, 449, 452
intermittent, 457
mucous of uterus, 395, 453
mucous, vaginal, 351
myxomatous, 453
Position, 134
breech-back, 135, 193, 359
dorsal, 134
erect, 136
genupectoral, 136
high pelvic. (See *Trendelenburg's*.)
Simon's, 135, 193, 359
Sims's, 135
Trendelenburg's, 136
ventral, 136
Posterior commissure, 36
Postural treatment of retroflexion, 434
Pouch—
Douglas's, 91
obturator, 91
para-uterine, 91

Pouch—
paravesical, 91
recto-abdominal, 91
recto-uterine, 91
vesico-abdominal, 91
vesico-uterine, 91
Poultice, 183
Pozzi, injecting cysts with spermaceti, 282
injury to ureters, 594
operation for ureterovaginal fistula, 365
ventrofixation, 439
Pregnancy—
diagnosis from ovarian cyst, 574
in relation to uterine fibroids, 480
operations during, 188
with ovarian cyst, 579
Pregnant cancerous uterus removed by vaginal hysterectomy, 498
Prepuce, 37
adherent, 249
Pressure—
as hemostatic, 602
symptoms, 458
Priesznitz's compress, 183
Primary follicles, 28
Primordial ova, 28
Probe, 151
Procidentia of uterus, 440
Progressive atrophy of nymphæ, 280
Prolapse, acute, of uterus, 441
of anterior wall of vagina, 326
Brandt's cure, 442
chronic, 441
complete, 441
incomplete, 441
Lefort's operation, 442
of intestine into deep Douglas's pouch, 326
of ovaries, 527
of posterior wall of vagina, 331
of urethra, 288
of uterus, 440
of vagina, 331
operations, 442
Prolapsus of uterus, 440
Proliferating cyst, 547
Pruritus, 264
Pseudo-intraligamentous tumors, 597
Pseudomyxoma of peritoneum, 563
Puberty, 113
difference between, and nubility, 113
Puncture, explorative, 571
Pus, inspissation of, 512
Pyocolpos, 317
lateral, 324
Pyometra, 317, 379, 408
lateral, 324
senile, 396
Pyosalpinx, 503, 519, 573
saccata, 503

R.

Raphe anococcygea, 97
perineal, 101
Receptaculum seminis, 63
Rectal alimentation, 217
ampulla, 85
Rectocele, 331
Emmet's operation, 308
Rectum—
anatomy, 83
function, 89
Regions—
abdominal, 110
anal, 99
perineal, 99
urogenital, 99
Repositor—
Aveling's, 450
for replacing uterus, 432
Resolution, 218
Respiration, artificial, 201
Rest-cure, 217
Retractor muscles of uterus, 55
Retractors—
lateral vaginal, 205
vaginal, 205
Retroflexed gravid uterus, 573
Retroflexion, 429
Retro-ovarian shelf, 91
Retroposition, 381
Retroversion, 429
Reverdin, apparatus for lifting large tumors, 470
Reviving from effect of anesthetics, 201, 204
Rheophores, 224
Rheostat, 224
Richardson's bellows, 201
Rima pudendi, 36, 43
Robb's leg-holder, 194
Rodent ulcer, 486
different from corroding ulcer, 491
Rokitanski's tumor, 546
Roof of vagina, 42
Room, operating-, 190
Rosenmüller's organ, 22
Round ligament—
anatomy, 58
fibroma of, 256
function, 59, 60
hematoma of, 255
shortening of, 435, 440
tumors connected with extrapelvi portion of, 254
Rubber bag for injecting bladder, 171

Rubber—
cushions for operations—
Kelly's, 191
Marcy's, 191
ligatures, preservation of, 210
Rudimentary horn of uterus, 376
Rugæ of vagina, 43
Rupture of ovarian cyst, 562, 569
Ruptures (herniæ), 252

S.

Sacral hysterectomy, 499
Salpingitis, 503
acute catarrhal, 503
acute purulent, 503
chronic interstitial, 503
conservative treatment, 511
cystic, 503, 517
infectious, 503
interstitial, 504
isthmica nodosa, 503
mural, 503
non-infectious, 503
parenchymatous, 503
profluent, 503
Salpingo-oöphorectomy, 511
abdominal, 512
for anteflexion, 429
mortality, 515
results, 515
vaginal, 516
with ventrofixation, 439
Salt, solution of, 481
Sand-bodies, 557
Sanderson, Robert, ligation of pedicle, 601
Sarcoma—
carcinomatosum of ovary, 611
decidual, 486
of Fallopian tubes, 523
of ovary, 611
of pelvis, 651
of uterus, 483
of vagina, 351
of vulva, 275
Scarification of vaginal portion, 182
Scarificator, Buttle's uterine, 183
Schede, operation for ureterovaginal fistula, 365
Schroeder, hysterectomy, 472
lateral vaginal retractor, 205
needle for hysterectomy, 476
single-flap excision of cervical portion, 407
supravaginal amputation of cervix, 415
Schücking's operation, 437
Schultze, disinfection of laminaria tent, 153
Schultze, method of tearing adhesions of ovary, 529
method of tearing adhesions of uterus, 436
Scirrhus of vulva, 275
Scissors, 206
Küchenmeister's, 409
Sedatives, 218
Segmental vesicles, 21
Septicemia, 482
Septum—
pectiniform, 38
retrohymenale, 319
transverse perineal, 101
Serrefines, 295
Shock, 481, 604, 605
Shortening of round ligament—
extraperitoneal, 435
intraperitoneal, 440
Shouldering, 212
Silk, 196
Silkworm gut, 199
Silver wire, 199, 210
Simon, conemantle-shaped excision of cervical portion, 406
curette, 152
intestinal examination, 140
operation for fistula, 359
position, 359
Simpson, J. Y., metrotome, 409
Sims, Harry, drainage-tube, 182
Sims, Marion, discission of posterior lip of cervix, 428
needle-holder, 208
operation for anteversion, 424
for cystocele, 327
for rectovaginal fistula, 373
for urinary fistula, 357
sponge-holder, 206
uterine knife, 409
Sinus copularis, 30
Sinuses of Morgagni, 87
Smith, cautery-clamp, 589
Smith, Lapthorn, table, 191
Sodium sulphate, 220
Solution—
boro-salicylic, 200
Thiersch's, 200
Solutions, antiseptic, 199
Souffle, uterine, 156
Sound, uterine, 150
Space—
subcutaneous, of pelvis, 94
subperitoneal, of pelvis, 94
Spanish-fly blister, 189
Spectators, 192
Speculum—
Ashton's, 148
bath-, 184

broken, 311
for carcinoma, 490
wound after ova-
cervical canal, 233, 381, 408
ovariotomy, 609
catgut, 198
for cystocele, 328
dilatation of, 577
membrane of Graafian fol-
collapse, 204
Styptics, 177, 602
Summit of bladder, 78
Superfetation, 378
Superinvolution of uterus, 417
Supporter—
abdominal, 187
uterine, 442
Suppositories with iodoform, 294
Suppuration of ovarian cyst, 562
Suture, 210
buried catgut, 305
button-, 359
catgut, 197
chain-, 215
Cleveland's, 310
continuous, 213
for fecal fistula, 372
for hemostasis, 180
for inversion, 451
for urinary fistula, 356
how to remove, 211
interrupted, 213
mattress-, 180
quilled, 180, 213
secondary infection of, 210
-shield, 212
shouldering, 212
silk, 196, 210
silkworm gut, 199
silver wire, 199, 210
submucous, 308
tier-, 213
twisting, 212
Swedish movement cure, 188
Sylvester's artificial respiration, 201
Syphilis—
indurating edema, 277
initial lesion, 285
secondary, 287
tertiary, 288
Syringe—
bulb-and-valve, 167
Davidson's, 167
for bladder, 170, 171
fountain, 167
Frost's, 646
uterine, 168

T.

Table—
Daggett's, 133
examining, 133
operating-. (See *Operating-table.*)
Tait, flap-splitting operation for perineal laceration, 299
operation for fecal fistula, 372, 373
operation for urinary fistula, 359
shortening of round ligaments, 440
"Tait's operation," 512

Tampon—
abdominal, 176
vaginal, 174
Tamponade, 172
of uterus, 175
Tapping, 185, 580
Tate, inversion, 451
Taylor, I. E., operation for rectolabial fistula, 371
Temperature after ovariotomy, 606
Tenaculum, 205
Emmet's, 205
-forceps, 206
Tendinous arch, 94
Tents, 152
Tetanus, 482, 608
Thermal galvanocauterization for cancer of uterus, 495
Thermocautery, 177
Thiersch's solution, 200
Thirst, 216
Thomas, anteversion pessary, 422
classification of anteflexion, 424
drainage-tube, 182
enucleation of uterine fibroids, 465
inversion, 451
retroflexion pessary, 434
spoon-saw, 462
tissue-forceps, 206
Thompson, bladder-syringe, 171
Thrombosis, 482
Thrombus of vulva, 268
Thymol, 200
Tincture of iodine in ovariotony, 602
in the vagina, 165
on the skin, 184
Tissue-forceps, 206
Toilet of peritoneum, 601
Tonics, 217
Trachelorrhaphy, 386
for retroflexion, 435
Trachelotomy, 409
Traction, for removing uterine fibroids, 466
Transfusion, 481
Traveling, cure for sterility, 658
Treatment—
electric, 220
external, 165
in general, 164
internal, 216
preventive, 164
Trendelenburg, operation for fistula, 359
position, 136
anesthesia in, 203
apparatus for, 137, 190, 191
Treub, hysterectomy, 471
Trichiasis, 264
Trichomonas vaginalis, 335
Trigone—
Lieutaud's, 78, 161
Pawlik's, 162
Tripper faden, 509
Trocar—
Emmet's, 587
vaginal, 186
Warren's, 581
Tubercle of vagina, 43
Tuberculosis of Fallopian tubes, 523
of ovary, 614
of peritoneum, 575
of uterus, 500
of vagina, 353
of vulva, 280
Tubes—
double-current uterine, 168, 169
drainage-, 182
Fallopian, 62
single-current uterine, 168
Tubo-ovarian cysts, 559
Tumeur fluxionnaire, 404
Tumor—
fibroid of uterus, 454
of abdominal wall, 577
of round ligament, 254
of spleen, 577
of vulva, 267. (See *Cancer*, *Cyst*, *Carcinoma*, *Fibroid*, *Sarcoma*, etc.)
oligocystic, 545
oozing, 270
painful, of urethra, 274
phantom, 578
Rokitanski's, 546
solid ovarian, 609
vascular, of urethra, 274
Tunica—
fibrosa of Graafian follicle, 68
propria of Graafian follicle, 68
Turns, 114
Tympanitis, 169, 578, 606

U.

Ulcer of cervix, 410
corroding, 411, 491
rodent, 486
simple, 410
tuberculous, 280, 353, 410
venereal, 283, 285
Urachus, 80
persistent, 469, 591
Ureter—
anatomy, 81
at the base of intraligamentous tumors, 597
catheterization, 161
course during pregnancy, 82
examination, 159

Ureter—
function, 83
injury, 361, 594
ligation, 361
opening into vagina, 325
palpation, 163
Urethra—
anatomy, 75
atresia, 363
caruncle, 274
dilatation of, 140
ducts, 76
function, 77
inflammation of, 262
painful tumor, 274
painful vascular excrescence, 274
prolapse, 288
suprapubic, 367
vascular tumor, 274
Urinals, 367
Urinary analysis, 158
Urine—
examination with regard to operations, 192
suppression of, 606
Urogenital sinus, 31
persistent, 325
Uterine appendages of the other side—
in ovariotomy, 589
when one set is removed, 514
Uterine artery—
aneurysm, 616
during pregnancy, 61
ligature of, 177
Uterine cancer, 483
radical treatment, 495
Uterine carcinoma, 486
Baker's operation, 496
Uterine fibrocyst, 457
treatment, 482
Uterine fibroids—
abdominal enucleation, 479
apparatus for lifting, 470
cervical, 454
changes, 457
combined with pregnancy, 480
corporeal, 454
curetting, 465
galvanochemical cauterization, 464
hypodermic injection of ergot, 463
indications for operations, 482
in negro race, 458
interstitial, 456
intramural, 456
mortality of operations, 480
multiple, 456
oöphorectomy, 466
pedunculated, 455
sessile, 455
Uterine fibroids—
single, 456
sloughing, 480
submucous, 455
subperitoneal, 455
supravaginal amputation, 470
traction method, 465
vaginal enucleation, 465. (See *Uterus.*)
Uterotractor, 497
Uterus—
absence, 375
acollis, 380
acquired atrophy, 417
anatomy, 47
anteflexion, 381
anteposition, 381
anteversion, 420
apoplexy of, 123
artificial prolapse, 140
atresia, 378, 407
bicameratus vetularum, 123
bicornis, 377
bilocularis, 377
bimanual replacement, 432
carcinoma, 486
of body, 487
of cervix, 486
of vaginal portion, 486
catarrh, 397
cervical carcinoma, 486
closure, 407
congenitally atrophic, 380
cystosarcoma, 484
descent, 440
development, 31
didelphys, 376
digital replacement, 432
dilatation, 154
diseases, 375
displacement, 419
duplex separatus, 376
elevation, 446
enchondroma, 500
erosions, 496
excessive development, 375
fetal, 379
fibrocyst, 457, 574
fibroid, 454
fibroid tumor, 454
fibroma, 454
fibromyoma, 454
foreign bodies, 390
function, 62
gangrene, 418
hernia, 381, 452
hypertrophy, 411
infantile, 379
inflammation, 390
injuries, 381

Uterus—
inversion, 446
lateroflexion, 381, 440
lateroversion, 381, 440
ligaments, 54
male, 30
malformations, 375
malposition, 381
myofibroma, 454
myoma, 454
myxosarcoma, 483
neoplasms, 453
neuralgia, 418
obliquity, 381
papilloma, 500
parvicollis, 380
procidentia, 440
prolapse, 440
prolapsus, 440
pubescent, 380
repositors, 432
retractor muscles, 55
retroflexion, 429
retroposition, 381
retroversion, 429
rudimentary, 376
rudimentary horn, 376
sarcoma, 483
senile atrophy, 417
septus, 377
severance of adhesions, 439
shape and position, 51
subseptus, 377
superinvolution, 417
supraviganal amputation. (See *Hysterectomy.*)
tamponade, 175
total extirpation, 466
tuberculosis, 500
unicornis, 376
ventrofixation, 438
wounded in ovariotomy, 594, 596

V

Vagina—
anatomy, 41
blind canals, 324
carcinoma, 352
cicatrices, 344
cysts, 348
development, 30
diseases of, 317
double, 323
entrance, 43
erysipelas, 344
faulty communications, 324
fibroid polypus, 350
fibroid tumor, 350
foreign bodies, 333
function, 45
gangrene, 343
glass plug, 321
how to keep open after atresia operation, 322
incision, 511
injuries, 332
inversion, 331
malformations, 317, 319
mucous polypus, 351
neoplasms, 348
partitioning, 442
prolapse, 331
prolapse of anterior wall, 326
prolapse of posterior wall, 331
sarcoma, 351
tamponade, 174
tuberculosis, 353
Vaginal enterocele, 325
case of, 325
entrance, laceration, 297
glass plug, 181
hernia, 325
hysterectomy, 496
portion—
anatomy, 47
development, 32
Vaginismus, 319, 345
deep, 346
superficial, 345
Vaginitis, 334
acute, 334
adhesive, 335
catarrhal, 335
chronic, 334
diagnosis between simple and gonorrheal, 337
dissecting, 342
due to burrowing pus from pelvic abscess, 342
dysenteric, 342
emphysematous, 339
epithelial, 339
exfoliative, 339
exudative, 341
follicular, 335
glandular, 335
gonorrheal, 337
granular, 335
mycotic, 340
phlegmonous, 342
primary, 334
secondary, 334
simple, 335
Valves of rectum, 87
Varicocele of broad ligament, 617
parovarian, 617

[illegible] by Subscription only.

[illegible] Text-Book of Surgery.

[illegible] Royal Octavo Volume of over 1200 pages with nearly 500 Woodcuts in Text, and 37 [illegible] Plates, many of them Engraved [illegible] Photographs and Drawings furnished by the Authors.

[illegible] Sheep, $3 net; Half Russia, $3 net.

BY

[illegible] M.D., Emeritus Professor of [illegible]ology, Phila-[illegible]

[illegible] M.D., LL.D., Professor of Surgery, Medical Col-[illegible] Dartmouth Medical College.

[illegible] M.D., Professor of Principles and Practice of [illegible] Surgical Medical College.

[illegible] M.D., LL.D., Professor of the Principles of Sur-[illegible] Surgery, Jefferson Medical College.

[illegible] M.D., Professor of Surgery and of Clinical [illegible] of Michigan.

[illegible] M.D., Professor of Surgery, Medical Department of [illegible] of Buffalo.

[illegible] M.D., Professor of Clinical Surgery in the New [illegible] School and Hospital.

[illegible] M.D., Ph.D., Professor of Practice of Surgery and of [illegible], Rush Medical College.

[illegible]ERD, M.D., C.M., Professor of Anatomy and Lecturer [illegible] Surgery, McGill University, Montreal, Canada.

[illegible]N, B.A., M.D., Professor of Surgery in the University [illegible] New York.

[illegible]SON, M.D., Professor of Ophthalmology, Jefferson Med-[illegible]

[illegible] WARREN, M.D., Associate Professor of Surgery, Harvard [illegible]

[illegible] WHITE, M.D., Ph.D., Professor of Clinical Surgery, Uni-[illegible] of Pennsylvania.

EDITED BY

WILLIAM W. KEEN, M.D., LL.D., AND
J. WILLIAM WHITE, M.D., PH.D.

The want of a text-book which could be used by the practitioner and at the same time be recommended to the medical student has been deeply felt, especially by teachers of surgery. Hence, when it was suggested to a number of them that it would be well to unite in preparing a book of this description, great unanimity of opinion was found to exist, and the gentlemen before named gladly consented to join in its production. While there is no distinctive American Surgery, yet America has contributed very largely to the progress of modern surgery, and among the foremost of those who have aided in developing this art and science will be found the authors of the present volume. All of them are teachers of surgery in leading medical schools and hospitals in the United States and Canada.

Especial prominence has been given to Surgical Bacteriology; a feature which is believed to be unique in a surgical text-book in the English language. Asepsis and Antisepsis have received particular attention, and full details of the various methods of disinfecting instruments, hands, and the field of operations, sutures, etc., will be found. The text is brought well up to date in such important branches as cerebral, spinal, intestinal, and pelvic surgery, and the most important and newest operations in these departments are described and illustrated.

The text of the entire book has been submitted to all the authors for their mutual criticism and revision, also an entirely new and original feature in book-making. The book, as a whole, therefore, expresses on all the important surgical topics of the day the consensus of opinion of the eminent surgeons who have joined in its preparation.

One of the most attractive features of the book is its illustrations. Very many of them are original and faithful reproductions of photographs taken directly from patients or from specimens, and the modern improvements in the art of engraving have enabled the publishers to produce illustrations which it is believed are superior to those in any similar work.

For Sale by Subscription only.

A TREATISE

ON THE

Theory and Practice of Medicine.

BY

AMERICAN TEACHERS.

EDITED BY WILLIAM PEPPER, M.D., LL.D.,
Provost and Professor of the Theory and Practice of Medicine and of Clinical Medicine in the University of Pennsylvania.

To be Completed in Two Handsome Royal Octavo Volumes of about 1000 pages each, with Illustrations to Elucidate the Text wherever Necessary.

Price per vol., Cloth, $5 net; Sheep, $6 net; Half Russia, $7 net.

VOLUME I. contains:

Hygiene.

J. S. BILLINGS, Professor of Hygiene, University of Pennsylvania.

Fevers (Ephemeral, Simple Continued, Typhus, Typhoid, Epidemic Cerebro-spinal Meningitis, and Relapsing).

WM. PEPPER, M.D., Provost and Professor of the Theory and Practice of Medicine and of Clinical Medicine, University of Pennsylvania.

Scarlatina, Measles, Rotheln, Variola, Varioloid, Vaccinia, Varicella, Mumps, Whooping-cough, Anthrax, Hydrophobia, Trichinosis, Actinomycosis, Glanders, and Tetanus.

JAMES T. WHITTAKER, M.D., Professor of the Theory and Practice of Medicine and of Clinical Medicine, Medical College of Cincinnati, O.

Tuberculosis, Scrofula, Syphilis, Diphtheria, Erysipelas, Malaria, Cholera, and Yellow Fever.

W. GILMAN THOMPSON, M.D., Professor of Physiology, New York University Medical College.

Nervous, Muscular, and Mental Diseases (Including Opium Habit, etc.).

HORATIO C. WOOD, M.D., Professor of Materia Medica, Pharmacy, and General Therapeutics, and Clinical Professor of Nervous Diseases, University of Pennsylvania. And

WILLIAM OSLER, M.D., Professor of Practice of Medicine, Johns Hopkins University, Baltimore, Md.

VOLUME II. contains:

Urine (Chemistry and Microscopy).

OLLAND, M.D., Professor of Medical Chemistry and Toxi. Jefferson Medical College, Philadelphia.

Kidneys and Lungs.

LAFIELD, M.D., Professor of Pathology and Practice of College of Physicians and Surgeons, New York City.

ir-passages (Larynx and Bronchi) and Pleura.

WILSON, M.D., Professor of Practice of Medicine and of l Medicine, Jefferson Medical College, Philadelphia.

ynx, Œsophagus, Stomach, and Intestines (Including Intestinal Parasites).

PEPPER, M.D., Provost and Professor of the Theory and Prac- of Medicine and of Clinical Medicine, University of Pennsylvania.

Peritoneum, Liver, and Pancreas.

LD H. FITZ, M.D., Hersey Professor of Physics, Harvard Medi- School.

thetic Diseases (Rheumatism, Rheumatoid Arthritis, Gout, Lithæmia, and Diabetes).

M. LYMAN, M.D., Professor of Principles and Practice of Medicine, Rush Medical College, Chicago, Ill.

Heart, Aorta, Arteries, and Veins.

. JANEWAY, M.D., Professor of Principles and Practice of Medicine, Bellevue Hospital Medical College, New York City.

Blood and Spleen.

LLIAM OSLER, M.D., Professor of Practice of Medicine, Johns Hopkins University, Baltimore, Md.

Inflammation, Embolism, Thrombosis, Fever, and Bacteriology.

W. H. WELCH, M.D., Professor of Pathology, Johns Hopkins University, Baltimore, Md.

The articles are not written as though addressed to students in lectures, but are exhaustive descriptions of diseases with the newest facts as regards Causation, Symptomatology, Diagnosis, Prognosis, and Treatment, and will include a large number of approved Formulæ. The recent advances made in the study of the bacterial origin of various diseases are fully described, as well as the bearing of the knowledge so gained upon prevention and cure. The subjects of Bacteriology as a whole and of immunity are fully considered in a separate section.

Methods of diagnosis are given the most minute and careful attention, thus enabling the reader to learn the very latest methods of investigation without consulting works specially devoted to the subject.

IN PRESS—READY SHORTLY.

For Sale by Subscription only.

AN AMERICAN TEXT-BOOK

OF THE

DISEASES OF CHILDREN.

INCLUDING

Special Chapters on Essential Surgical Subjects; Diseases of the Eye, Ear, Nose, and Throat; Diseases of the Skin; and on the Diet, Hygiene, and General Management of Children.

BY

AMERICAN TEACHERS.

EDITED BY

LOUIS STARR, M.D.,

Physician to the Children's Hospital and Consulting Pediatrist to the Maternity Hospital, Philadelphia; late Clinical Professor of Diseases of Children in the Hospital of the University of Pennsylvania, etc., etc.,

ASSISTED BY

THOMPSON S. WESTCOTT, M. D.,

Attending Physician to the Dispensary for Diseases of Children, Hospital of the University of Pennsylvania, etc.

Forming a handsome imperial 8vo vol. of more than 1200 pages, profusely illustrated with wood-cuts, half-tone and colored plates.

ANNOUNCEMENT.

An American Text-book of the Diseases of Children will be issued as a handsome imperial octavo volume of about 1200 pages, uniform with an American Text-book of Surgery, containing numerous wood-cuts, half-tone plates, and colored illustrations. The plan contemplates a series of original articles written by some sixty well-known pædiatrists, representing collectively the present teachings of the most prominent medical schools and colleges of America. The work is not intended to be encyclopædic in character, but to be a practical book suitable for constant and handy reference by the practitioner and advanced student.

One decided innovation for a book of its size is the large number of authors, nearly every article being contributed by a specialist in the line on which he writes. This, while entailing considerable labor upon the editors, has resulted in the publication of a work thoroughly new and abreast of the times. The entire work has been practically written in a few months, thus removing the usual objection to treatises of this class, that they are out of date before they are published.

Especial attention is given to the consideration of the latest accepted teaching upon the Etiology, Symptoms, Pathology, Diagnosis, and Treatment of the disorders of children, with the introduction of many special formulæ and therapeutic procedures.

Special chapters embrace at unusual length the diseases of the Eye, Ear, Nose and Throat, and the Skin; while the introductory chapters cover fully the important subjects of Diet, Hygiene, Exercise, Bathing, and the Chemistry of Food. Tracheotomy, Intubation, Circumcision, and such minor surgical procedures coming within the province of the medical practitioner are carefully considered.

NOW READY.

For Sale by Subscription only.

An American Text-Book of Gynecology

MEDICAL AND SURGICAL.

FOR THE USE OF

STUDENTS AND PRACTITIONERS.

BY

JOHN M. BALDY, M.D., HENRY T. BYFORD, M.D.,
EDWIN CRAGIN, M.D., J. H. ETHERIDGE, M.D.,
WILLIAM GOODELL, M.D., HOWARD A. KELLY, M.D.,
FLORIAN KRUG, M.D., E. E. MONTGOMERY, M.D.,
WILLIAM R. PRYOR, M.D., GEORGE M. TUTTLE, M.D.

Forming one handsome royal 8vo. volume, profusely illustrated.

Price, Cloth, $6; Sheep, $7; Half Russia, $8.

In this volume all anatomical descriptions, excepting those essential to a clear understanding of the text, have been omitted, the illustrations being largely depended upon to elucidate the anatomy of the parts. The work will be found thoroughly practical in its teachings, and is intended, as its title implies, to be a working text-book for physicians and students. A clear line of treatment has been laid down in every case, and although no attempt has been made to discuss mooted points, still the most important of these have been noted and explained. The operations recommended are fully illustrated, so that the reader may have under his eye a picture of the procedure described in the text, and cannot fail to grasp the idea.

All extraneous matter and discussions have been carefully excluded, the attempt being made to allow nothing to cumber the text.

The subject-matter has been brought fully up to date at every point, and the work is as nearly as possible the combined opinions of the ten specialists who figure as the authors.

The work is well illustrated throughout with wood-cuts, half-tone and colored plates, mostly selected from the authors' private collections.

For Sale by Subscription only.

NOW READY.

[illegible]SEASES OF THE EYE.

[illegible] Hand-Book of Ophthalmic Practice.

[illegible] E. DE SCHWEINITZ, MD.,

[illegible] the Eye, Philadelphia Polyclinic; Professor of Clinical [illegible] Medical College, Philadelphia; Ophthalmic Surgeon [illegible] to the Philadelphia Hospital; Ophthalmologist [illegible] Hospital and Infirmary for Nervous Diseases; late [illegible] Ophthalmoscopy, University of Pa., etc.

[illegible] royal 8vo. vol. of more than 600 pages.

[illegible] wood-cuts, many of which are original, and two chromo-lithographic plates.

[illegible] $4 net; Sheep, $5 net; Half Russia, $5.50 net.

PROFESSIONAL OPINIONS.

[illegible] with the requirements not only of the specialist, but [illegible] in a rare degree. I am satisfied that unusual success [illegible]

(Signed) WILLIAM PEPPER, M.D.,
[illegible] *Professor of Theory and Practice of Medicine and Clinical Medicine in the University of Pennsylvania.*

[illegible] and reliable form the accepted views of Ophthalmic Sci-

(Signed) WILLIAM THOMSON, M.D.,
[illegible] *of Ophthalmology, Jefferson Medical College, Philadelphia, Pa.*

[illegible] hand-books now extant on the subject."

(Signed) J. O. STILLSON, M.D.,
[illegible] *and Ear, Central College of Physicians and Surgeons, Indianapolis, Ind.*

[illegible] to any book on the subject with which I am familiar."

(Signed) FRANCIS HART STUART, M.D.,
Brooklyn, N. Y.

[illegible] the most attractive and easily understood form just the sort of [illegible] necessary to the intelligent practice of general medicine and

(Signed) J. WILLIAM WHITE, M.D.,
Professor of Clinical Surgery in the University of Pennsylvania.

[illegible] reliable guide to the study of eye diseases, presenting the latest facts [illegible]"

(Signed) SWAN M. BURNETT, M.D.,
[illegible] *and Otology, Med. Department Univ. Georgetown, Washington, D. C.*

Second Revised Edition. For Sale by Subscription only.

A NEW PRONOUNCING DICTIONARY OF MEDICINE.

WITH

Phonetic Pronunciation, Accentuation, Etymology, etc.

BY JOHN M. KEATING, M.D., LL.D.,
Fellow of the College of Physicians of Philadelphia; Vice-President of the American Pædiatric Society; Ex-President of the Association of Life Insurance Medical Directors; Editor "Cyclopædia of the Diseases of Children," etc.;

AND

HENRY HAMILTON,
Author of "A new Translation of Virgil's Æneid into English Rhyme;" Co-Author of "Saunders' Medical Lexicon," etc.

WITH AN APPENDIX

CONTAINING IMPORTANT TABLES OF BACILLI, MICROCOCCI, LEUCOMAÏNES, PTOMAÏNES; DRUGS AND MATERIALS USED IN ANTISEPTIC SURGERY; POISONS AND THEIR ANTIDOTES; WEIGHTS AND MEASURES; THERMOMETRIC SCALES; NEW OFFICINAL AND UNOFFICINAL DRUGS, ETC. ETC.

Forming One very Attractive Volume of over 800 pages.

Price, Cloth, $5 net; Sheep, $6 net; Half Russia, $6.50 net.

With Denison's Patent Index for Ready Reference.

"I am much pleased with Keating's Dictionary, and shall take pleasure in recommending it to my classes." (Signed) HENRY M. LYMAN, M.D.,
Professor of Principles and Practice of Medicine, Rush Medical College, Chicago, Ill.

"I am convinced that it will be a very valuable adjunct to my study table, convenient in size and sufficiently full for ordinary use."
(Signed) C. A. LINDSLEY, M.D.,
Professor of Theory and Practice of Medicine, Medical Dept. Yale University, Secretary Connecticut State Board of Health, New Haven, Connecticut.

"I will point out to my classes the many good features of this book as compared with others, which will, I am sure, make it very popular with students."
(Signed) JOHN CRONYN, M.D., LL.D.,
Professor of Principles and Practice of Medicine and Clinical Medicine; President of the Faculty, Medical Dept. Niagara University, Buffalo, N. Y.

"My examination and use of it have given me a very favorable opinion of its merit, and it will give me pleasure to recommend its use to my class."
(Signed) J. W. H. LOVEJOY, M.D.,
Professor of Theory and Practice of Medicine, and President of the Faculty, Medical Dept. Georgetown University, Washington, D. C.

Second Edition, for Sale by Subscription.

AUTOBIOGRAPHY

OF

SAMUEL D. GROSS, M.D.,

D. C. L. OXON., LL.D. CANTAB., EDIN., JEFFERSON COLLEGE, UNIV. PA., EMERITUS PROFESSOR OF SURGERY IN THE JEFFERSON MEDICAL COLLEGE OF PHILADELPHIA.

WITH REMINISCENCES OF

HIS TIMES AND CONTEMPORARIES.

Edited by his Sons, SAMUEL W. GROSS, M.D., LL.D., late Professor of Principles of Surgery and of Clinical Surgery in the Jefferson Medical College, and A. HALLER GROSS, A.M., of the Philadelphia Bar.

Preceded by a Memoir of Dr. Gross by the late Austin Flint, M.D., LL.D.

In two handsome vols., each containing over 400 pages, demy 8vo., ex. cloth, gt. tops, with fine Frontispiece engraved on steel.

Price . . . $5.00 net.

This AUTOBIOGRAPHY, which was continued by the late eminent Surgeon until within three months before his death, contains a full and accurate history of his early struggles, trials, and subsequent successes, told in a singularly interesting and charming manner, and embraces short and graphic pen portraits of many of the most distinguished men—surgeons, physicians, divines, lawyers, statesmen, scientists, etc. etc.—with whom he was brought in contact in this country and in Europe; the whole forming a retrospect of more than three-quarters of a century.

SAUNDERS'

Pocket Medical Formulary

BY

WILLIAM M. POWELL, M.D.,

Attending Physician to the Mercer House for Invalid Women, at Atlantic City.

CONTAINING

1750 Formulæ, selected from several hundreds of the best known authorities.

Forming a handsome and convenient Pocket Companion of nearly 300 printed pages, and blank leaves for additions.

WITH AN APPENDIX

Containing Posological Table; Formulæ and Doses for Hypodermic Medication: Poisons and their Antidotes; Diameters of the Female Pelvis and Fœtal Head; Obstetrical Table; Diet List for various diseases; Materials and Drugs used in Antiseptic Surgery: Treatment of Asphyxia from Drowning; Surgical Remembrancer; Tables of Incompatibles; Eruptive Fevers; Weights and Measures, etc.

Third Edition, Revised and greatly Enlarged.

Handsomely bound in Morocco, with Patent Index, Wallet, and Flap.

Price, $1.75 net.

THERAPEUTIC GAZETTE, January, 1892.—"The prescriptions have been taken from the writings or practice of Physicians whose experience qualifies them to be worthy of trial. We heartily recommend this volume to all who desire to purchase such a work."

NEW YORK MEDICAL RECORD, February 27, 1892.—"This little book, that can be conveniently carried in the pocket, contains an immense amount of material. It is very useful, and, as the name of the author of each prescription is given, is unusually reliable."

NOW READY.

A SYLLABUS

OF

Lectures on the Practice of Surgery.

ARRANGED IN CONFORMITY WITH

THE AMERICAN TEXT-BOOK OF SURGERY.

BY N. SENN, M.D., PH.D.,

Professor of Surgery in Rush Medical College, Chicago, and in the Chicago Polyclinic.

PRICE . . . $2.00.

This the latest work of its eminent author, himself one of the contributors to the "American Text-Book of Surgery," will prove of exceptional value to the advanced student who has adopted that work as his text-book. It is not only the syllabus of an unrivalled course of Surgical Practice, but an epitome or supplement to the larger work.

NOW READY.

Notes on the Newer Remedies,

THEIR

Therapeutic Applications and Modes of Application

BY DAVID CERNA, M.D., PH.D.

Demonstrator of and Lecturer on Experimental Therapeutics in the University of Pennsylvania.

Forming a small octavo volume of about 175 pages (7 x 5) inches.

PRICE - - - $1.25.

The work will take up in alphabetical order all the Newer Remedies, giving their physical properties, solubility, therapeutic applications, administration, and chemical formula. It will in this way, form a very valuable addition to the various works on Therapeutics now in existence.

Chemists are so multiplying compounds that if each compound is to be thoroughly studied, investigations must be carried far enough to determine the practical importance of the new agents.

Brevity and conciseness compel the omission of all bibliographical references.

SAUNDERS'

POCKET MEDICAL LEXICON;

OR,

Dictionary of Terms and Words used in Medicine and Surgery.

BY JOHN M. KEATING, M.D.,

Editor of "Cyclopædia of Diseases of Children," etc.; Author of the "New Pronouncing Dictionary of Medicine,"

AND

HENRY HAMILTON,

Author of "A New Translation of Virgil's Æneid into English Verse;" Co-author of a "New Pronouncing Dictionary of Medicine."

Price, 75 Cents, Cloth. $1.00, Leather Tucks.

"Saunders' Pocket Medical Lexicon—a very complete little work, invaluable to every student of medicine. It not only contains a very large number of words, but also tables of etymological factors common in medical terminology; abbreviations used in medicine, poisons and antidotes, etc."—*Annals of Gynæcology*, Philadelphia.

IN ACTIVE PREPARATION.

METHODS OF

PREVENTING AND CORRECTING

Deformities of the Bones and Joints.

A Handbook of Practical Orthopædic Surgery.

BY H. AUGUSTUS WILSON, M.D.,

Professor of General and Orthopædic Surgery, Philadelphia Polyclinic; Clinical Professor of Orthopædic Surgery, Jefferson Medical College, Philadelphia, etc., etc.

The aim of the author will be to provide a book of moderate size, containing comprehensive details that will enable general practitioners to thoroughly understand the mechanical features of the many forms of congenital and acquired deformities of the bones and joints.

Mechanical and operative procedures will be given in detail, and prominence will be given to the mechanical requirements for braces and artificial limbs, etc., with description of their methods of construction. A large number of original illustrations will be used to make descriptions clearer.

IN PRESS. READY SHORTLY.

DISEASES OF WOMEN.

BY HENRY J. GARRIGUES, A.M., M.D.,

Professor of Obstetrics in the New York Post-Graduate Medical School and Hospital; Gynæcologist to St. Mark's Hospital, New York City; Gynæcologist to the German Dispensary in the City of New York; Consulting Obstetrician to the New York Infant Asylum; Obstetric Surgeon to the New York Maternity Hospital; Fellow of the American Gynæcological Society; Fellow of the New York Academy of Medicine; President of the German Medical Society of New York, etc. etc.

In One Very Handsome Octavo Volume, of about 700 pages, profusely Illustrated by Woodcuts and Colored Plates.

PRICE, CLOTH, $4.00. SHEEP, $5.00.

A practical work on Gynæcology for the use of students and practitioners, written in a terse and concise manner. The importance of a thorough knowledge of the anatomy of the female pelvic organs has been fully recognized by the author, and considerable space has been devoted to the subject. The chapters on operations and treatment will be thoroughly modern, and are based upon the large hospital and private practice of the author. The text is elucidated by a large number of illustrations and colored plates, many of them being original.

SYLLABUS OF OBSTETRICAL LECTURES

In the Medical Department University of Pennsylvania.

BY RICHARD C. NORRIS, A.M., M.D.,

Demonstrator of Obstetrics in the University of Pennsylvania.

Third Edition, thoroughly revised and enlarged.

PRICE, CLOTH, INTERLEAVED FOR NOTES, $2.00 Net.

The New York *Medical Record* of April 19, 1890, referring to this book, says: "This modest little work is so far superior to others on the same subject that we take pleasure in calling attention briefly to its excellent features. Small as it is, it covers the subject thoroughly, and will prove invaluable to both the student and the practitioner as a means of fixing in a clear and concise form the knowledge derived from a perusal of the larger text-books.

NOW READY. SECOND EDITION.

AN OPERATION BLANK,

With List of Instruments, etc.,

REQUIRED IN VARIOUS OPERATIONS.

PREPARED BY W. W. KEEN, M.D., LL.D.,

Professor of the Principles of Surgery in the Jefferson Medical College, Philadelphia.

Price per Pad, containing Blanks for 50 Operations, 50 Cents, net.

A convenient blank, suitable for all operations, giving complete instructions regarding necessary preparation of patient, etc., with full list of dressings and medicines to be used.

Saunders' Question Compends.

Now the Standard Authorities in Medical Literature

WITH

Students and Practitioners in every City of the United States and Canada.

THE REASON WHY!

They are the advance guard of "Student's Helps"—that DO HELP; they are the leaders in their special line, *well and authoritatively written by able men, who, as teachers in the large colleges, know exactly what is wanted by a student preparing for his examinations.* The judgment exercised in the selection of authors is fully demonstrated by their professional elevation. CHOSEN FROM THE RANKS OF DEMONSTRATORS, QUIZ-MASTERS, AND ASSISTANTS, MOST OF THEM HAVE BECOME PROFESSORS AND LECTURERS IN THEIR RESPECTIVE COLLEGES.

Each book is of convenient size (5 by 7 inches), containing on an average 250 pages, profusely illustrated and elegantly printed in clear, readable type, on fine paper.

The entire series, numbering twenty-three subjects, has been kept thoroughly revised and enlarged when necessary, many of them being in their third and fourth editions.

TO SUM UP.

Although there are numerous other Quizzes, Manuals, Aids, etc., in the market, none of them approach the "Blue Series of Question Compends," and the claim is made for the following points of excellence:—

1. Professional standing and reputation of authors.
2. Conciseness, clearness, and standard of text.
3. Size of type, quality of paper and binding.

No. 3.

ESSENTIALS OF ANATOMY,

Including the Anatomy of the Viscera.

By CHARLES B. NANCREDE, M.D.,

Professor of Surgery and Clinical Surgery in the University of Michigan, Ann Arbor; Corresponding Member of the Royal Academy of Medicine, Rome, Italy; Late Surgeon Jefferson Medical College, etc. etc.

Fourth edition. Crown 8vo., 380 pages, 180 Illustrations.

Enlarged by an Appendix containing over Sixty Illustrations of the Osteology of the Human Body.

The whole based upon the last (eleventh) edition of GRAY'S ANATOMY.

Price, Cloth, $1.00. Interleaved for Notes, $1.25.

"Truly such a book as no student can afford to be without."—*American Practitioner and News*, Louisville, Kentucky.

No. 4.

Essentials of Medical Chemistry

ORGANIC AND INORGANIC.

CONTAINING, ALSO,

Questions on Medical Physics, Chemical Physiology, Analytical Processes, Urinalysis, and Toxicology.

By LAWRENCE WOLFF, M.D.,

Demonstrator of Chemistry, Jefferson Medical College; Visiting Physician to German Hospital of Philadelphia; Member of Philadelphia College of Pharmacy, etc. etc.

Fourth and revised edition, with an Appendix. Crown 8vo., 212 pages.

Price, Cloth, $1.00. Interleaved for Notes, $1.25.

"We could wish that more books like this would be written, in order that medical students might thus early become more interested in what is often a difficult and uninteresting branch of medical study."—*Medical and Surgical Reporter.*

"The author is thoroughly familiar with his subjects. A useful addition to the medical and pharmaceutical library."—*Registered Pharmacist*, Chicago.

No. 5.

ESSENTIALS OF OBSTETRICS.

BY W. EASTERLY ASHTON, M.D.,

Professor of Gynæcology in the Medico-Chirurgical College of Philadelphia; Obstetrician to the Philadelphia Hospital.

Third Edition, thoroughly revised and Enlarged.

Crown 8vo., 244 pages, 75 illustrations.

Price, Cloth, $1.00. Interleaved for Notes, $1.25.

"An excellent little volume containing correct and practical knowledge. An admirable compend, and the best condensation we have seen."—*Southern Practitioner.*

"Ashton's Obstetrics. Of extreme value to students, and an excellent little book to freshen up the memory of the practitioner."—*Chicago Medical Times.*

"A work thoroughly calculated to be of service to students in preparing for examination."—*Medical and Surgical Reporter.*

"Ashton's Obstetrics should be consulted by the medical student until he can answer every question at sight. The practitioner would also do well to glance at the book now and then, to prevent his knowledge from getting rusty."—*New York Medical Abstract*

No. 6.

ESSENTIALS OF Pathology and Morbid Anatomy.

BY

C. E. ARMAND SEMPLE, B.A., M.B., Cantab., L.S.A., M.R.C.P., Lond.,

Physician to the Northeastern Hospital for Children, Harkney; Professor of Vocal and Aural Physiology and Examiner in Acoustics at Trinity College, London, etc. etc.

Crown 8vo., illustrated, 174 pages.

Price, Cloth, $1.00. Interleaved for Notes, $1.25.

"An excellent compend of the subject from the points of view of Green and Payne."—*Indiana Medical Journal.*

"A valuable little volume—truly a *multum in parvo.*"—*Cincinnati Medical News.*

No. 7.

ESSENTIALS OF
MATERIA MEDICA, THERAPEUTICS,
AND PRESCRIPTION WRITING.

BY HENRY MORRIS, M.D.,

Late Demonstrator, Jefferson Medical College; Fellow College of Physicians, Philadelphia; Co-editor Biddle's Materia Medica; Visiting Physician to St. Joseph's Hospital, etc. etc.

Second Edition. Crown 8vo., 250 pages.

Price, Cloth, $1.00. Interleaved for Notes, $1.25.

"One of the best compends in this series. Concise, pithy, and clear, well suited to the purpose for which it is prepared."—*Medical and Surgical Reporter.*

"The very essence of Materia Medica and Therapeutics boiled down and presented in a clear and readable style."—*Gaillard's Medical Journal.*

"A well-arranged quiz-book, comprising the most important recent remedies."—*Sanitarium*, New York.

"The subjects are treated in such a unique and attractive manner that they cannot fail to impress the mind and instruct in a lasting manner."—*Buffalo Medical and Surgical Journal.*

Nos. 8 and 9.

Essentials of Practice of Medicine.

BY HENRY MORRIS, M.D.,

Author of "Essentials of Materia Medica," etc. etc.

With an Appendix on the Clinical and Microscopical Examination of Urine.

BY LAWRENCE WOLFF, M.D.,

Author of "Essentials of Medical Chemistry," etc.

Colored (Vogel) Urine Scale and numerous fine Illustrations.

Third Edition, enlarged by some THREE HUNDRED Essential Formulæ, selected from the writings of the most eminent authorities of the Medical Profession.

COLLECTED AND ARRANGED BY WILLIAM M. POWELL, M.D.,

Author of "Essentials of Diseases of Children."

Post 8vo., 460 pages. Price, Cloth, $2.00. Medical Sheep, $2.50.

"Of material aid to the advanced student in preparing for his degree, and to the young practitioner in diagnosing affections or selecting the proper remedy."—*Southern Practitioner.*

"The teaching is sound, the presentation graphic, matter as full as might be desired, and the style attractive."—*American Practitioner and News.*

No. 14.

ESSENTIALS OF

Refraction and Diseases of the Eye.

By EDWARD JACKSON, A.M., M.D.,
Professor of Diseases of the Eye in the Philadelphia Polyclinic and College for Graduates in Medicine, etc. etc.

AND

Essentials of Diseases of the Nose and Throat.

By E. BALDWIN GLEASON, M.D.,
Surgeon in charge of the Nose, Throat, and Ear Department of the Northern Dispensary; Assistant in the Ear Department of the Philadelphia Polyclinic and College for Graduates in Medicine, etc. etc.

Two vols. in one, crown 8vo., 268 pages, profusely illustrated.

Price, Cloth, $1.00. Interleaved for Notes, $1.25.

"A valuable book to the beginner in these branches, to the student, to the busy practitioner, and as an adjunct to more thorough reading. The authors are capable men, and as successful teachers know what a student most needs."—*New York Medical Record.*

No. 15.

ESSENTIALS OF

DISEASES OF CHILDREN.

By WILLIAM M. POWELL, M.D.,
Attending Physician to the Mercer House for Invalid Women, at Atlantic City, N. J.; Late Physician to the Clinic for the Diseases of Children in the Hospital of the University of Pennsylvania and St. Clement's Hospital, etc. etc.

CROWN 8vo., 216 PAGES.

Price, Cloth, $1.00. Interleaved for Notes, $1.25.

"This work is gotten up in the clear and attractive style that characterizes the Saunders' Series. It contains in appropriate form the gist of all the best works in the department to which it relates."—*American Practitioner and News*, Louisville, Ky.

"Dr. Powell's little book is a marvel of condensation. Handsome binding, good paper, and clear type add to its attractiveness."—*Southern Practitioner*, Nashville, Tenn.

"The book contains a series of important questions and answers, which the student will find of great utility in the examination of children."—*Annals of Gynæcology*, Philadelphia.

No. 16.

ESSENTIALS OF

EXAMINATION OF URINE.

By LAWRENCE WOLFF, M.D.,
Author of "Essentials of Chemistry," etc.

COLORED (VOGEL) URINE SCALE AND NUMEROUS ILLUSTRATIONS.

Crown 8vo. Price, Cloth, 75 Cents.

"A little work of decided value."—*University Medical Magazine.*

"A good manual for students, well written, and answers, categorically, many questions beginners are sure to ask."—*Medical Record*, New York.

"The book is practical in character, comprehensive as is desirable, and a useful aid to the student in his studies."—*Memphis Medical Monthly*, Memphis, Tenn.

No. 17.

ESSENTIALS OF DIAGNOSIS.

By SOLOMON SOLIS COHEN, M.D.,
Professor of Clinical Medicine and Applied Therapeutics in the Philadelphia Polyclinic,

AND

AUGUSTUS A. ESHNER, M.D.,
Instructor in Clinical Medicine, Jefferson Medical College, Philadelphia.

Post 8vo., 382 pages. 55 Illustrations, some of which are Colored, and a Frontispiece.

Price, $1.50 net.

"A good book for the student, properly written from their standpoint, and confines itself well to its text."—*Medical Record*, New York.

"Concise in the treatment of the subject, terse in expression of fact. . . . The work is reliable, and represents the accepted views of clinicians of to-day."—*American Journal of Medical Sciences.*

"The subjects are explained in a few well-selected words, and the required ground has been thoroughly gone over."—*International Medical Magazine.*

"We can heartily recommend this work; it is modern and complete, and will give more satisfaction than many other works which are perhaps too prolix as well as behind the times."—*Medical Review*, St. Louis.

No. 18.

ESSENTIALS OF

PRACTICE OF PHARMACY.

BY LUCIUS E. SAYRE,

Professor of Pharmacy and Materia Medica in the University of Kansas.

Crown 8vo., 171 pages.

Price, Cloth, $1.00. Interleaved for Notes, $1.25.

"Covers a great deal of ground in small compass. The matter is well digested and arranged. The research questions are a valuable feature of the book."—*Albany Medical Annals*, Albany, N. Y.

"This very valuable little manual covers the ground in a most admirable manner. It contains practical pharmacy in a nutshell."—*American Doctor*, Richmond, Va.

"The best quiz on pharmacy we have yet examined."—*National Drug Register*, St. Louis, Mo.

"A book of only 180 pages, but pharmacy in a nutshell. It is not a quiz-compend compiled to enable a grocery clerk to 'down' a board of pharmacy; it is a finger-post guiding a student to a completer knowledge."—*Western Drug Record.*

No. 20.

Second and Revised Edition.

ESSENTIALS OF BACTERIOLOGY.

A CONCISE AND SYSTEMATIC INTRODUCTION TO THE STUDY OF MICRO-ORGANISMS.

BY M. V. BALL, M.D.,

Assistant in Microscopy, Niagara University, Buffalo, N. Y.; Late Resident Physician German Hospital, Philadelphia, etc.

Crown 8vo., 150 pp. 77 Illus. and five Plates, some in Colors.

Price, Cloth, $1.00. - - Interleaved for Notes, $1.25.

"The amount of material condensed in this little book is so great, and so accurate are the formulæ and methods, that it will be found useful as a laboratory hand-book."—*Medical News*, Philadelphia.

"Bacteriology is the keynote of future medicine, and every physician who expects success must familiarize himself with a knowledge of Germ-life—the agents of disease.

"This little book with its beautiful illustrations will give the students, in brief, the results of years of study and research unaided."—*Pacific Record of Medicine and Surgery*, San Francisco.

No. 21.

ESSENTIALS OF

Nervous Diseases and Insanity.

THEIR

SYMPTOMS AND TREATMENT.

By JOHN C. SHAW, M.D.,

Clinical Professor of Diseases of the Mind and Nervous System, Long Island College Hospital Medical School; Consulting Neurologist to St. Catharine's Hospital, and Long Island College Hospital; Formerly Medical Superintendent King's County Insane Asylum.

SECOND EDITION.

Crown 8vo, 186 pages. 48 Original Illustrations.

Mostly selected from the Author's private practice.

Price, Cloth, $1.00. Interleaved for Notes, $1.25.

"Clearly and intelligently written."—*Boston Medical and Surgical Journal.*

"A valuable addition to this series of compends, and one that cannot fail to be appreciated by all physicians and students."—*Medical Brief*, St. Louis.

"Dr. Shaw's Primer is excellent as far as it goes, the illustrations are well executed and very interesting."—*Times and Register*, New York and Philadelphia.

No. 22.

ESSENTIALS OF PHYSICS.

By

FRED. J. BROCKWAY, M.D.,

Assistant Demonstrator of Anatomy at the College of Physicians and Surgeons, New York.

Crown 8vo., 320 pages, 155 fine illustrations.

Price, Cloth, - - - - - - - $1.00 net.
Interleaved for Notes, - - - - $1.25 net.

"The publisher has again shown himself as fortunate in his editor as he ever has been in the attractive style and make-up of his compends."—*American Practitioner and News*, Louisville, Ky.

"Contains all that one need know of the subject, is well written, and is copiously illustrated."—*Medical Record*, New York.

"The author has dealt with the subject in a manner that will make the theme not only comparatively easy, but also of interest."—*Medical News*, Philadelphia.

No. 22.

Essentials of Medical Electricity.

By [illegible]

[illegible]

AND

E. E. LAWRANCE, M.D.

[illegible]

Crown 8vo., 140 pages, 65 Illustrations.

Price, Cloth, $1.00. Interleaved for Notes, $1.25.

"[illegible] and affords a safe guide to the beginner in the subject."—*Medical and Surgical Journal, Boston.*

"The subject is presented in a lucid and pleasing manner."—*Medical Record, New York.*

"A little work on an important subject, which will prove of great value to medical students and trained nurses who wish to study the scientific as well as the practical points of electricity."—*The Hospital, London, England.*

In Preparation. Ready Shortly.

A DOSE BOOK

AND

Manual of Prescription Writing.

By E. Q. THORNTON, M.D.,

Demonstrator of Therapeutics, Jefferson Medical College, Philadelphia.

The volume, in size and general appearance, will be uniform with "Saunders' Pocket Medical Formulary."

No. 23.

Essentials of Medical Electricity.

By D. D. STEWART, M.D.,

Demonstrator of Diseases of the Nervous System and Chief of the Neurological Clinic in the Jefferson Medical College; Physician to St. Mary's Hospital, and to St. Christopher's Hospital for Children, etc.

AND

E. S. LAWRANCE, M.D.,

Chief of the Electrical Clinic and Assistant Demonstrator of Diseases of the Nervous System in the Jefferson Medical College, etc.

Crown 8vo., 148 pages, 65 illustrations.

Price, Cloth, $1.00. Interleaved for Notes, $1.25.

"Clearly written, and affords a safe guide to the beginner in this subject."—*Medical and Surgical Journal*, Boston.

"The subject is presented in a lucid and pleasing manner."—*Medical Record*, New York.

"A little work on an important subject, which will prove of great value to medical students and trained nurses who wish to study the scientific as well as the practical points of electricity."—*The Hospital*, London, England.

In Preparation. Ready Shortly.

A DOSE BOOK

AND

Manual of Prescription Writing.

By E. Q. THORNTON, M.D.,

Demonstrator of Therapeutics, Jefferson Medical College, Philadelphia.

The volume, in size and general appearance, will be uniform with "Saunders' Pocket Medical Formulary."

LANE MEDICAL
STANFORD UNIV.
300 PASTEUR DRIVE
PALO ALTO, CALIF.

N201 Garrigues, H.J. 17848
G242 A text-book of the
1894 diseases of women

NAME	DATE DUE
M. V. Burrill	JUN 25 1926

LANE MEDICAL
STANFORD UNIV.
300 PASTEUR DR.
PALO ALTO, CALIF.

N201 Garrigues, H.J. 17848
G242 A text-book of the
1894 diseases of women

NAME	DATE DUE
M. W. Burrill	JUN 25 1926